

Photon-counting detector CT – first experiences in the field of musculoskeletal radiology

Photon-Counting Detektor CT – Erste Erfahrungen im Bereich der muskuloskelettalen Bildgebung

Authors

Stefanie Bette¹, Franka Risch¹, Judith Becker¹ , Daniel Popp¹, Josua A. Decker¹, David Kaufmann¹, Lena Friedrich¹, Christian Scheurig-Münkler¹ , Florian Schwarz², Thomas J Kröncke^{1, 3} 

Affiliations

- 1 Department of Diagnostic and Interventional Radiology and Neuroradiology, University Hospital Augsburg, Augsburg, Germany
- 2 Institute of Conventional and Interventional Radiology, Donauisar Hospital Deggendorf, Deggendorf, Germany
- 3 Centre for Advanced Analytics and Predictive Sciences (CAAPS), University of Augsburg, Augsburg, Germany

Keywords

bones, CT-high resolution, photon-counting detector CT

received 18.9.2023

accepted after revision 12.4.2024

published online 2024

Bibliography

Fortschr Röntgenstr

DOI 10.1055/a-2312-6914

ISSN 1438-9029

© 2024, Thieme. All rights reserved.


Georg Thieme Verlag KG, Rüdigerstraße 14, 70469 Stuttgart, Germany

Correspondence

Prof. Thomas J Kröncke

Department of Diagnostic and Interventional Radiology and Neuroradiology, University Hospital Augsburg, Stenglinstr. 2, 86156 Augsburg, Germany

thomas.kroencke@uk-augsburg.de

 Supplementary Material is available at <https://doi.org/10.1055/a-2312-6914>.

ABSTRACT

Background The introduction of photon-counting detector CT (PCD-CT) marks a remarkable leap in innovation in CT imaging. The new detector technology allows X-rays to be converted directly into an electrical signal without an intermediate step via a scintillation layer and allows the energy of individual photons to be measured. Initial data show high spa-

tial resolution, complete elimination of electronic noise, and steady availability of spectral image data sets. In particular, the new technology shows promise with respect to the imaging of osseous structures. Recently, PCD-CT was implemented in the clinical routine. The aim of this review was to summarize recent studies and to show our first experiences with photon-counting detector technology in the field of musculoskeletal radiology.

Methods We performed a literature search using Medline and included a total of 90 articles and reviews that covered recent experimental and clinical experiences with the new technology.

Results and Conclusion In this review, we focus on (1) spatial resolution and delineation of fine anatomic structures, (2) reduction of radiation dose, (3) electronic noise, (4) techniques for metal artifact reduction, and (5) possibilities of spectral imaging. This article provides insight into our first experiences with photon-counting detector technology and shows results and images from experimental and clinical studies.

Key Points

- This review summarizes recent experimental and clinical studies in the field of photon-counting detector CT and musculoskeletal radiology.
- The potential of photon-counting detector technology in the field of musculoskeletal radiology includes improved spatial resolution, reduction in radiation dose, metal artifact reduction, and spectral imaging.
- PCD-CT enables imaging at lower radiation doses while maintaining or even enhancing spatial resolution, crucial for reducing patient exposure, especially in repeated or prolonged imaging scenarios.
- It offers promising results in reducing metal artifacts commonly encountered in orthopedic or dental implants, enhancing the interpretability of adjacent structures in post-operative and follow-up imaging.
- With its ability to routinely acquire spectral data, PCD-CT scans allow for material classification, such as detecting urate crystals in suspected gout or visualizing bone marrow edema, potentially reducing reliance on MRI in certain cases.

Citation Format

- Bette S, Risch F, Becker J et al. Photon-counting detector CT – first experiences in the field of musculoskeletal radiology. *Fortschr Röntgenstr* 2024; DOI 10.1055/a-2312-6914

ZUSAMMENFASSUNG

Hintergrund Mit Einführung der Photon-Counting Detektor CT (PCD-CT) vollzieht sich ein bemerkenswerter Innovationsprung in der CT-Bildgebung. Die neue Detektor-Technologie ermöglicht es, Röntgenstrahlen ohne Zwischenschritt über eine Szintillatorschicht direkt in ein elektrisches Signal umzuwandeln und die Energie einzelner Photonen zu messen. Erste Daten zeigen eine hohe Ortsauflösung, eine vollständige Elimination des elektronischen Bildrauschens und die stetige Verfügbarkeit spektraler Bilddatensätze. Insbesondere in der Bildgebung ossärer Strukturen zeigt die neue Technologie vielversprechende Ansätze. Seit ca. 3 Jahren wird die PCD-CT bereits in der klinischen Routine angewandt. Ziel dieser Übersichtsarbeit ist es, einen Überblick über aktuelle Studien und unsere ersten Erfahrungen mit der Photon-Counting Detektor-Technologie im Bereich der muskuloskelettalen Bildgebung zu geben.

Methode Es erfolgte eine Literaturrecherche auf „Medline“. Eingeschlossen wurden insgesamt 90 Übersichtsarbeiten und Originalarbeiten, die erste experimentelle oder klinische Erfahrungen mit der neuen Technologie zeigen.

Ergebnisse und Schlussfolgerung Die Übersichtsarbeit fokussiert sich insbesondere auf (1) die Ortsauflösung und Abgrenzbarkeit kleiner anatomischer Strukturen, (2) die Reduktion der Strahlendosis, (3) das Bildrauschen, (4) Techni-

ken zur Reduktion von Metallartefakten und (5) die Möglichkeiten der spektralen Bildgebung. Der Artikel gibt zudem Einblicke in unsere ersten klinischen Erfahrungen und zeigt die Ergebnisse und Bilder aus experimentellen und klinischen Studien.

Kernaussagen

- Diese Übersicht fasst aktuelle experimentelle und klinische Studien im Bereich Photon-Counting Detektor CT (PCD-CT) und muskuloskelettaler Bildgebung zusammen.
- Die PCD-Technologie hat das Potential der Verbesserung der Ortsauflösung, der Reduktion von Strahlendosis und Metallartefakten sowie einer spektralen Bildgebung bei jeder Untersuchung.
- Die PCD-CT ermöglicht eine gleichbleibende bzw. teils sogar verbesserte Ortsauflösung bei niedrigeren Strahlendosen; dies ist entscheidend für die Reduktion der Strahlendosis, insbesondere bei Patientinnen und Patienten, die regelmäßige CT-Untersuchungen erhalten.
- Die PCD-CT zeigt vielversprechende Ergebnisse in der Reduktion von Metallartefakten, beispielsweise bei Metallimplantaten in Hüfte, Wirbelsäule oder in den Zähnen; dies verbessert die Beurteilbarkeit der umliegenden Strukturen.
- Mit der Möglichkeit, routinemäßig eine spektrale Bildgebung zu akquirieren, können in PCD-CT Untersuchungen beispielsweise Urat-Kristalle bei Verdacht auf Gicht dargestellt werden. Neue Studien zeigen auch das Potential der Darstellung eines Knochenmarködems; somit könnte ggf. auf weitere Untersuchungen (z. B. MRT) verzichtet werden.

Background

In the 1970s, the first computed tomography (CT) scanner was implemented in the clinical routine. During the past decades, many innovations have continuously improved CT imaging. Conventional multi-slice detector CT (MDCT) in clinical routine is typically equipped with *energy-integrating* detectors (EID). Images result from indirect conversion of X-ray photons into visible light and then into an electric signal [1, 2, 3]. By integrating the absorbed energy over a short period of time, the information from each individual X-ray photon's energy is lost [4].

New CT scanners use photon-counting detectors (PCD). In contrast to EID, PCDs are able to directly convert X-ray photons into an electric signal using semiconductors [5]. Based on this groundbreaking technology, PCD-CT can overcome many limitations of EID-CT. The main advantages of PCD-CT are the elimination of electronic noise, the improvement of spatial resolution, the intrinsic spectral imaging capabilities, and the potential reduction of radiation dose [2, 3, 5, 6, 7, 8].

PCD-CT was introduced in clinical routine in April 2021. Two PCD systems are currently used: a commercially available system (Naeotom Alpha, Siemens Healthineers, Erlangen, Germany) and

a clinical prototype (SPCCT, Philips GmbH, Hamburg, Germany). Most studies that are covered by this review and also our personal experiences focus on the former.

The aim of this review was to summarize the first experimental and clinical experiences with PCD-CT in musculoskeletal radiology.

Methods

We performed a literature search using Medline and the keywords “photon-counting detector”, “bone”, “musculoskeletal”, “ultra-high resolution”, “radiation dose”, “metal artifact”. Articles were included if they covered experimental (including phantom studies and cadaveric studies) and first clinical results in the field of musculoskeletal radiology. ► **Table 1** summarizes the articles from this review categorized according to the body region, experimental or clinical study, and the number of subjects included in the study. All details of the original articles that were cited in this review are summarized in **Supplemental Table 1**.

For each subsection we also included our first experimental and clinical experiences and added images generated at our institution, where appropriate.

► **Table 1** Summary of included articles.

Subject	Number of articles	Total number of patients	Main topics
Reviews	13	n.a.	<ul style="list-style-type: none"> Technical principles and clinical benefits of PCD-CT First clinical experiences with PCD-CT Bone marrow edema Metal artifact reduction
Abdomen	2	150	<ul style="list-style-type: none"> Delineation of liver lesions using VMI and quantum iterative reconstruction methods
Dental imaging	1	n.a.	<ul style="list-style-type: none"> Detection of apical osteolysis
Extremities	9	12	<ul style="list-style-type: none"> Improved visualization on PCD-CT compared to EID-CT Reduced radiation dose on a PCD-CT scanner compared to an EID-CT scanner
Head	7	51	<ul style="list-style-type: none"> Improved delineation of the skull base and temporal bone on PCD-CT compared to EID-CT
Heart	3	100	<ul style="list-style-type: none"> Delineation of coronary lumen and quantification of coronary plaques on PCD-CT
Lung	6	295	<ul style="list-style-type: none"> Improved visualization of lung structures using UHR-mode on a PCD-CT scanner compared to an EID-CT scanner
Multiple myeloma/metastases	5	90	<ul style="list-style-type: none"> Superior delineation of myeloma lesions and metastases on PCD-CT compared to EID-CT
Multiple regions	7	75	<ul style="list-style-type: none"> Improved spatial resolution and reduced radiation dose on a PCD-CT scanner compared to an EID-CT scanner
Spine	6	71	<ul style="list-style-type: none"> Improved visualization and reduced radiation dose on a PCD-CT scanner compared to an EID-CT scanner
Bone marrow edema – DECT	7	448	<ul style="list-style-type: none"> DECT for the detection of bone marrow edema with a focus on scaphoid fractures, undisplaced hip fractures, and vertebral fractures
Spectral imaging	5	n.a.	<ul style="list-style-type: none"> Spectral decomposition techniques in bone and joint imaging
Metal artifact reduction	19	369	<ul style="list-style-type: none"> Different techniques for metal artifact reduction including IMAR, MAR, and VMI

DECT: dual-energy CT; EID-CT: energy-integrating detector CT; IMAR: iterative metal artifact reduction; MAR: metal artifact reduction; PCD-CT: photon-counting detector CT; VMI: virtual monoenergetic images

Results

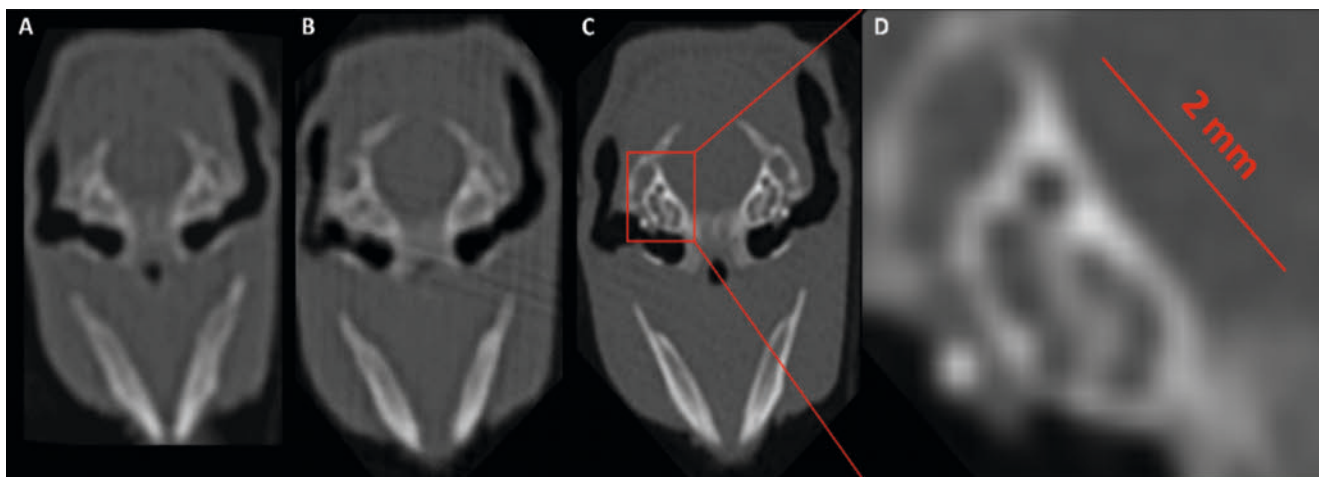
Improved spatial resolution and reduction of radiation dose

Due to the ability to directly convert X-ray photons into an electric signal and the use of smaller detector pixels, PCDs exhibit (ultra-) high resolution capabilities [9]. Especially in bone imaging, high spatial resolution is important for the imaging of fractures, bone healing, malignancies, and the visualization of tiny osseous structures [9]. Previous cadaveric studies have demonstrated the higher spatial resolution of PCD-CT compared to EID-CT [2, 3, 10, 11]. Recent studies also highlighted the higher spatial resolution even with a lower radiation dose on a PCD-CT scanner compared to an EID-CT scanner [12, 13, 14, 15]. Regarding specific body regions, previous phantom/mouse and cadaveric studies pointed out the improved visualization and delineation of tiny bone details in the following anatomical regions: shoulder [16], wrist [12, 17], temporal bone and skull base [13, 15], appendicular skeleton [18], spine [15, 19, 20, 21], paranasal sinus [22], and elbow [23]. Especially ultra-high resolution reconstructions have the ability not only to improve visualization of lung structures [24, 25, 26, 27,

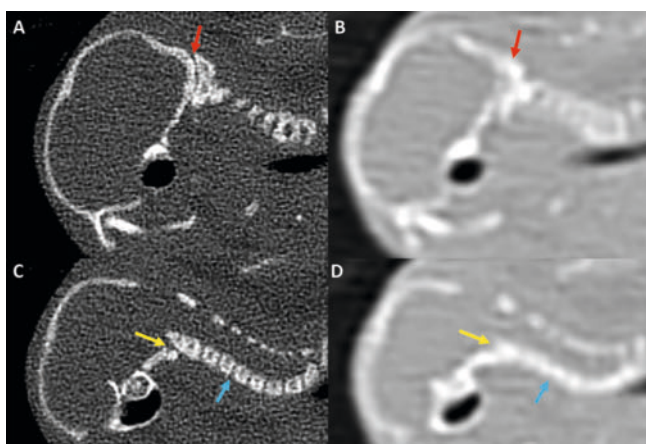
28, 29, 30] and cardiac structures [31, 32, 33, 34], but also of bones [11, 12, 13, 15, 16, 20, 35, 36, 37, 38, 39, 40, 41].

For example, using a mouse model, intervertebral spaces of the cervical spine were visible on PCD-CT at a radiation dose of 5 mGy $CTDI_{vol}$ (computed tomography dose index volume), while a dose of 20 mGy $CTDI_{vol}$ was necessary to discriminate different vertebrae on EID-CT. However, delineation was still unsharp. To clearly visualize the skull base and the inner ear of a mouse, 10 mGy $CTDI_{vol}$ was sufficient on PCD-CT, whereas sharp delineation was not possible on EID-CT even at 20 mGy $CTDI_{vol}$ [15].

► **Fig. 1** shows an example of ultra-high resolution imaging of the skull base of a mouse on different CT scanners, highlighting the capability of PCD-CT to provide sharp resolution of even tiny bone structures. In ► **Fig. 2** we provide a comparison between PCD-CT and EID-CT at a radiation dose of 20 mGy $CTDI_{vol}$. This example highlights the improved spatial resolution and detailed visualization of small bone structures. Using an ultra-sharp reconstruction kernel (Hr98) on the PCD-CT scanner, the craniocervical junction, the atlantodental space, and also the intervertebral disc were clearly visualized in a mouse model. The higher spatial resolution on PCD-CT was also shown quantitatively; our group assessed the edge sharpness at the lumbar and cervical spine. On a



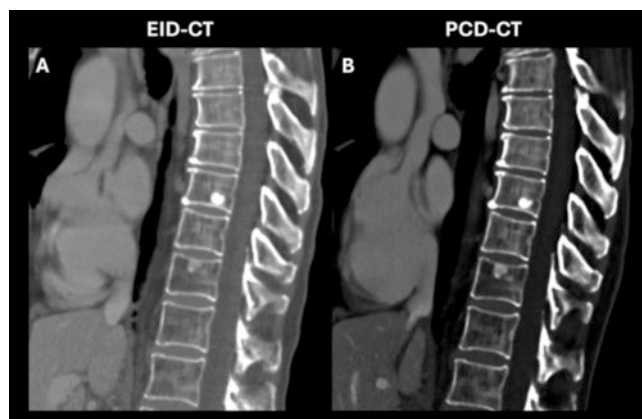
► **Fig. 1** Ultra-high resolution imaging of the skull base of a mouse on an EID-CT scanner (A: 20-slice EID-CT, B: 64-slice EID-CT), and on a PCD-CT scanner (C). Image C shows the remarkably sharp visualization of tiny structures of the skull base with a size of only about 2 mm.



► **Fig. 2** Ultra-high resolution imaging of a mouse in comparison between a 20-slice EID-CT image (B, D) and PCD-CT image (A, C), both at 20 CTDI_{vol}. Image A shows the sharp delineation of the atlantooccipital joint (red arrow) on a PCD-CT scanner. In image C, the delineation of the atlantodental space (yellow arrow) and the intervertebral discs (blue arrow) is highlighted, whereas on an EID-CT image (B, D) the described structures cannot be visualized clearly.

PCD-CT scanner, edge sharpness was significantly higher compared to an EID-CT scanner in all analyzed regions [15]. Similar results with higher cortical sharpness were also reported by Sonnow et al. using a cadaver study with an artificially created elbow fracture [23].

First clinical studies confirmed that spatial resolution is higher on a PCD-CT scanner compared to an EID-CT scanner in musculoskeletal imaging. For example, Benson et al. showed improved delineation of temporal bone compared to EID-CT [42], Rajagopal published the first clinical results in skull base imaging [43], while Baffour et al. showed results of imaging of the pelvis and shoulder [36]. Rajendran et al. shared the first results for wrist imaging [35] and Rau et al. showed improved spatial resolution for PCD-CT in spine imaging [44]. A recently published study by Marth et al.

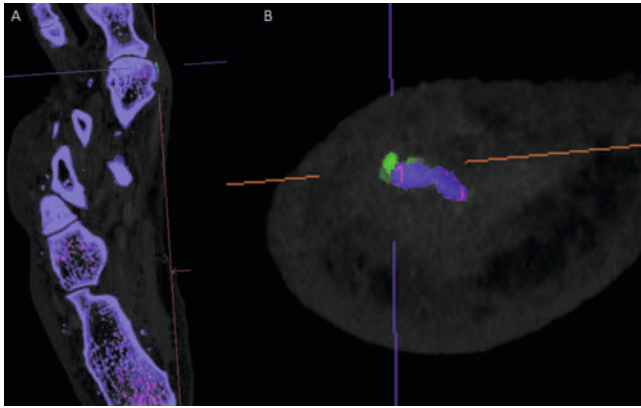


► **Fig. 3** Example of a patient with bone metastases from breast cancer and short-term follow-up on an EID-CT image (A) and a PCD-CT image (B) which allows a direct comparison of both scanners in the delineation of critical findings such as metastases.

showed comparable image quality of the lumbar spine on PCD-CT (compared to EID-CT) at significantly lower radiation doses [45].

New image reconstruction techniques including iterative reconstruction can further improve the spatial resolution of reconstructions in PCD-CT [9, 29, 46].

The first clinical studies also addressed the diagnostic performance of PCD-CT for the detection of malignant bone lesions, e. g., myeloma [47]. Recent studies in patients with myeloma showed similar lesion detection on PCD-CT compared to EID-CT, however, with a lower radiation dose [48], improved spatial resolution, and visibility on PCD-CT compared to EID-CT [49, 50]. Wherse et al. reported improved visualization of bone metastases using ultra-high resolution kernels on an experimental PCD-CT scanner in a case series of breast cancer patients [51]. ► **Fig. 3** shows an example of a patient with bone metastases of breast cancer with CT scans on a PCD-CT scanner and on an EID-CT scanner (time frame about three months between the two examinations), allowing a



► **Fig. 4** Spectral imaging in the diagnostic work-up of suspected gout. Image **A** shows tiny urate crystals (green) next to the metatarsophalangeal joint. In **B**, the joint is magnified and shown in sagittal reconstructions. Image **B** points out the possibility of PCD-CT to visualize and locate very tiny urate crystals.

direct comparison of both scanners. These images highlight the improved spatial resolution of PCD-CT for the delineation of critical findings, e. g., bone metastases.

Exploiting the ability of PCD-CT to improve spatial resolution and to reduce image noise, it has a high potential to reduce patients' radiation dose. Our first experimental studies showed the possibility to detect tiny bone structures on PCD-CT with a lower $CTDI_{vol}$ compared to EID-CT [15]. In musculoskeletal imaging, low-dose CT protocols are important for the detection of bone lesions, especially in patients with the need for repeated CT imaging [9].

Promising results for radiation dose reduction in musculoskeletal imaging were also shown in recent clinical studies. Previous studies reported improved visualization of temporal bone compared to MDCT at lower radiation doses [13, 41, 42, 52]. A similar dose saving potential was also shown for the spine [19, 44], shoulder and pelvis [36], and the wrist [35]. Other clinical and cadaver studies showed improved visualization without dose penalty [16, 23, 53].

Electronic noise and signal-to-noise ratio

Another advantage of the PCD technology is the elimination of electronic noise due to the direct conversion of X-ray photons into an electrical signal [1, 2, 5]. Consequently, images show an improved signal-to-noise ratio (SNR) as well as an improved contrast-to-noise ratio (CNR), which has also been shown, e. g., for abdominal imaging [2, 5, 54, 55]. SNR is defined as the ratio between CT values in a predefined region (e. g., trabecular bone) and the image noise (standard deviation of CT values). In first experimental studies, we showed that image noise was significantly lower on PCD-CT compared to EID-CT at various $CTDI_{vol}$ values with a consequently significantly improved SNR (ratio between CT values in bone and standard deviation of CT values in air), which resulted in a relative improvement in SNR of up to 36% [15].

Other PCD-CT studies assessed the CNR, calculated as the ratio between the difference between CT values in bone and fat and

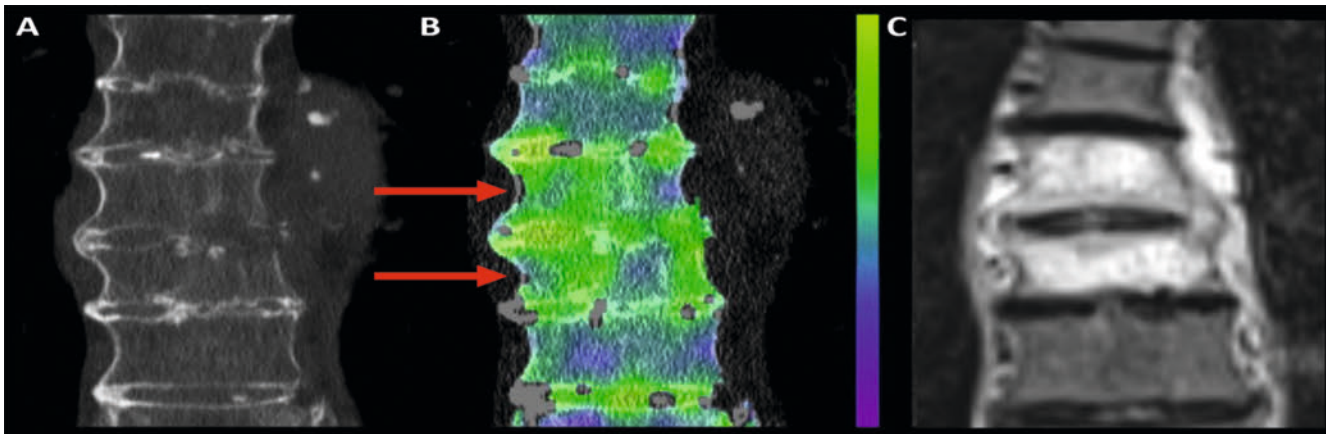
image noise (standard deviation measured in bone or fat) [17, 23]. Previous studies showed that CNR is significantly higher in PCD-CT compared to EID-CT, resulting in an improved delineation and visualization of bone structures [11, 16, 17, 19, 23, 43, 56].

Spectral imaging

Due to the multi-energy acquisition capability of PCD, all images are acquired in spectral mode – without adding radiation dose. Therefore, spectral image postprocessing can be performed for each scan [9]. In bone imaging, material classification (for example, the detection of urate crystals or calcium pyrophosphate crystals) is an important issue in the clinical routine [9, 57]. Dual-source dual-energy CT is an established proven technique in order to visualize urate crystals in patients with suspected gout [58]. However, this often implies a trade-off between using spectral imaging or a high-resolution technique [9]. In clinical routine and in patients with suspected gout, a combination of high-resolution and multi-energy imaging would be desirable. Using PCD-CT, both UHR mode and spectral imaging can be combined. ► **Fig. 4** shows a case with evidence of a small amount of urate crystals in the metatarsophalangeal joint and points out the value of PCD-CT for imaging in suspected gout. Spectral imaging can also be used for imaging of joint spaces and delineation of small cartilage defects after intraarticular contrast injection [9, 59, 60]. A recently published study by Garcelon et al. showed the ability of spectral imaging to visualize cartilage and subchondral cysts on knee CT without using contrast agent in cases with osteoarthritis [61].

Spectral imaging is also important in the diagnosis of acute trauma and in the detection of fractures. In most cases of suspected fractures, radiography is performed with additional CT in unclear cases or in cases with a need for further visualization of fracture morphology. However, there are a few cases (especially in fractures not involving the bone cortex) in which CT cannot detect the fracture. Then, further MRI is necessary to detect edema-like signal intensity as an indirect sign of a fracture [62]. However, access to MRI may be limited in clinical routine and in the emergency setting due to its availability, the long duration of the examination, and potential contraindications (e. g., pacemaker, metal implants). Previous studies on dual-energy CT (DECT) delivered promising results in the detection of bone marrow edema using virtual non-calcium images (VNCA) [63, 64, 65, 66, 67, 68]. This virtual spectral postprocessing enables the detection of discrete changes in the bone marrow by suppressing the high attenuation of bone structures and thereby enhancing the visualization of water (edema) in the bone marrow. This postprocessing can be routinely performed in PCD-CT [69].

Preliminary data from our department showed promising results with detection of bone marrow edema in patients with fractures of the spine ► **Fig. 5**). In this case, we showed CT of the thoracic spine of a patient with acute back pain. Conventional CT images were not able to detect an acute fracture. After postprocessing of the images using spectral data, we were able to show bone marrow edema (shown in green) in thoracic vertebrae 6 and 7 but not in the other visualized vertebrae. The bone marrow edema was confirmed with the gold standard imaging method, MRI, within 24 hours after the CT scan. Postprocessing



► **Fig. 5** CT imaging of the thoracic spine in a patient with acute upper back pain. Conventional CT images show no acute fracture (A); image postprocessing (virtual noncalcium, VNCa) shows bone marrow edema in thoracic vertebrae 6 and 7 (B). Increases in attenuation (e. g., bone marrow edema) are shown in green, whereas fat is visualized in purple. Bone marrow edema was confirmed by MRI within 24 hours (C).

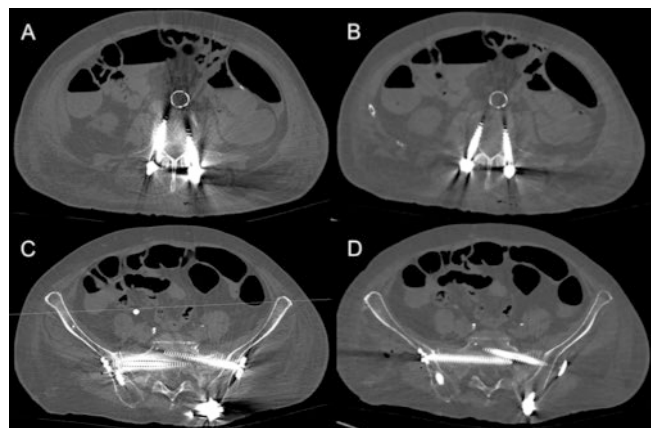
is based on virtual non-calcium (VNCa) imaging, a three-element decomposition technique that is known from DECT [69, 70]. In this technique, the typical attenuation of yellow and red bone marrow is defined as the baseline. It enables the generation of calcium images and VNCa images separately. Bone trabeculae are removed, which permits direct visualization of the bone marrow [69]. Also, for imaging of pelvic fractures, this new technique shows promising results in our first clinical experiences. Using VNCa, bone marrow edema was also detected in the pelvis in two examples.

These findings open up new possibilities and might obviate MRI in the near future in selected cases. Further prospective studies are necessary to evaluate the diagnostic accuracy of spectral imaging for the detection of bone marrow edema in different regions of the body and to compare it to MRI as the gold standard imaging method.

Metal artifact reduction

Trauma surgery often requires the use of metal implants in the spine or the extremities. In the postoperative setting and also during follow-up, further CT imaging is often necessary. However, due to the formation of metal artifacts, interpretation of adjacent structures is often not possible. Many patients also have dental implants which often have strong beam hardening artifacts. This renders the visualization of neighboring structures nearly impossible. Modern CT scanners employ algorithms for the reduction of beam hardening artifacts using iterative metal artifact reduction techniques [9, 71].

However, spectral imaging was also shown to have great potential for metal artifact reduction. With the multi-energy acquisition of PCD-CT with each scan, spectral postprocessing can be routinely performed. Spectral postprocessing enables the generation of virtual monoenergetic images (VMI) [1, 2, 5, 9]. Many previous studies assessed techniques of metal artifact reduction. DECT showed promising results with a reduction of beam hardening effects at higher keV levels [9, 72]. The most convincing results were shown for the combination of iterative



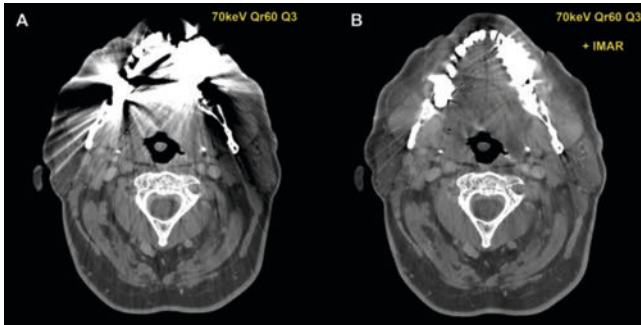
► **Fig. 6** Patient with screws in the lumbar spine and the pelvis. The left column (A, C) shows conventional 70 keV reconstructions. 110 keV reconstructions show a significant reduction of metal artifacts both in the spine and in the pelvis (B, D).

metal artifact reduction (IMAR) and higher keV levels on DECT [73, 74, 75, 76, 77].

The first phantom-based studies on a PCD-CT scanner assessed the value of IMAR [78], tin filtration [79], VMI [80], projection-based material decomposition [81, 82, 83], as well as the combination of IMAR and VMI [84, 85].

The first clinical studies on PCD-CT also showed promising results for metal artifact reduction, for IMAR, as well as for VMI and/or the combination of both methods.

A recently published study by Popp et al. showed that VMI enables metal artifact reduction after spine surgery and determined 110 keV as the optimal energy level for artifact reduction [86]. As spectral imaging is assessed routinely on a PCD-CT scanner, automatic 110 keV reconstruction can be easily performed and can help radiologists and clinicians evaluate CT images after spine surgery (► **Fig. 6**). Similar results were also shown for artifact reduction after total hip replacement [87].



► **Fig. 7** Contrast-enhanced CT of the neck in a patient with dental implants. **A** shows conventional 70 keV reconstructions with a Qr60 Q3 kernel. Using IMAR, there was a significant reduction of metal artifacts with consequently better delineation of surrounding structures (**B**).

For the reduction of dental metal artifacts, IMAR showed promising results. This effect could further be enhanced with high keV VMIs on a PCD-CT scanner, as recently published by Risch et al. [88] (► **Fig. 7**). The reduction of dental metal artifacts is very important in clinical routine. It is very common, and it often limits the assessment of cervical structures or structures in the brain. Other clinical studies also suggested the combination of IMAR and VMI for metal artifact reduction in the hip [89] and for dental implants [90].

Critical assessment

In the following paragraph, we aim to perform a critical assessment of the new technology. Despite the many advantages that were presented above, there might also be some limitations in clinical routine and musculoskeletal imaging at this time. Due to the rapid technical development, there are many different reconstruction algorithms and reconstruction kernels available. These differences between the centers might lead to confusion. Therefore, standardization of protocols for musculoskeletal imaging and specific issues is mandatory.

Due to the possibility of reconstructing spectral data within each scan, huge data sets are generated. This requires not only significant computational power, but also requires radiologists to examine the rapidly growing number of images and to write the reports. To avoid a loss of information, more technical and also human resources might be necessary. This might be challenging, especially in times of shrinking resources.

Due to the novelty of the PCD technology, large studies and especially multi-center trials are currently not available. Regarding various clinical scenarios, data about the sensitivity and specificity of the new reconstruction algorithms or spectral data sets is lacking. Therefore, many applications (e. g., detection of bone marrow edema) are undergoing clinical testing at the moment and the diagnostic accuracy must be demonstrated in clinical trials.

Summary

This review summarizes recent clinical and experimental studies as well as our personal experiences with a new PCD-CT scanner regarding advances in musculoskeletal imaging.

In summary, this new groundbreaking technology has many advantages compared to conventional CT: reduction of image noise and elimination of electronic noise, improved spatial resolution combined with reduction of radiation dose, spectral imaging with the potential to detect bone marrow edema and gout, as well as metal artifact reduction.

Based on previous studies, PCD-CT is a very promising technology in musculoskeletal imaging that will be introduced in a wider range of clinical applications and might have the potential to improve imaging combined with a reduction of radiation dose.

However, further studies are necessary to assess the manifold possibilities of PCD-CT in musculoskeletal imaging, to examine new reconstruction and postprocessing methods, and to improve diagnostic accuracy.

Funding Information

Siemens Healthineers | <http://dx.doi.org/10.13039/501100011699>

Conflict of Interest

The Department of Radiology received research funding from Siemens Healthineers for research in the field of photon-counting CT.

References

- [1] Flohr T, Petersilka M, Henning A et al. Photon-counting CT review. *Phys Med* 2020; 79: 126–136. doi:10.1016/j.ejmp.2020.10.030
- [2] Willemink MJ, Persson M, Pourmorteza A et al. Photon-counting CT: Technical Principles and Clinical Prospects. *Radiology* 2018; 289: 293–312. doi:10.1148/radiol.2018172656
- [3] Leng S, Bruesewitz M, Tao S et al. Photon-counting Detector CT: System Design and Clinical Applications of an Emerging Technology. *Radiographics* 2019; 39 (3): 729–743
- [4] Sartoretti T, Wildberger JE, Flohr T et al. Photon-counting detector CT: early clinical experience review. *Br J Radiol* 2023; 96: 20220544. doi:10.1259/bjr.20220544
- [5] Flohr T, Schmidt B. Technical Basics and Clinical Benefits of Photon-Counting CT. *Invest Radiol* 2023; 58: 441–450. doi:10.1097/RLI.0000000000000980
- [6] Nehra AK, Rajendran K, Baffour FI et al. Seeing More with Less: Clinical Benefits of Photon-counting Detector CT. *Radiographics* 2023; 43: e220158
- [7] van der Bie J, van Straten M, Booiij R et al. Photon-counting CT: Review of initial clinical results. *Eur J Radiol* 2023; 163: 110829. doi:10.1016/j.ejrad.2023.110829
- [8] McCollough CH, Rajendran K, Leng S et al. The technical development of photon-counting detector CT. *Eur Radiol* 2023; 33 (8): 5321–5330. doi:10.1007/s00330-023-09545-9
- [9] Baffour FI, Glazebrook KN, Ferrero A et al. Photon-Counting Detector CT for Musculoskeletal Imaging: A Clinical Perspective. *AJR Am J Roentgenol* 2023; 220: 551–560. doi:10.2214/AJR.22.28418

- [10] Leng S, Rajendran K, Gong H et al. 150- μm Spatial Resolution Using Photon-Counting Detector Computed Tomography Technology: Technical Performance and First Patient Images. *Invest Radiol* 2018; 53: 655–662. doi:10.1097/RLI.0000000000000488
- [11] Zhou W, Lane JI, Carlson ML et al. Comparison of a Photon-Counting-Detector CT with an Energy-Integrating-Detector CT for Temporal Bone Imaging: A Cadaveric Study. *AJNR Am J Neuroradiol* 2018; 39: 1733–1738
- [12] Grunz JP, Huflage H, Heidenreich JF et al. Image Quality Assessment for Clinical Cadmium Telluride-Based Photon-Counting Computed Tomography Detector in Cadaveric Wrist Imaging. *Invest Radiol* 2021; 56: 785–790. doi:10.1097/RLI.0000000000000789
- [13] Grunz JP, Heidenreich JF, Lennartz S et al. Spectral Shaping Via Tin Prefiltration in Ultra-High-Resolution Photon-Counting and Energy-Integrating Detector CT of the Temporal Bone. *Invest Radiol* 2022; 57: 819–825. doi:10.1097/RLI.0000000000000901
- [14] Gutjahr R, Halaweish AF, Yu Z et al. Human Imaging With Photon Counting-Based Computed Tomography at Clinical Dose Levels: Contrast-to-Noise Ratio and Cadaver Studies. *Invest Radiol* 2016; 51: 421–429
- [15] Bette S, Braun FM, Haerting M et al. Visualization of bone details in a novel photon-counting dual-source CT scanner-comparison with energy-integrating CT. *Eur Radiol* 2022; 32: 2930–2936
- [16] Patzer TS, Kunz AS, Huflage H et al. Quantitative and qualitative image quality assessment in shoulder examinations with a first-generation photon-counting detector CT. *Sci Rep* 2023; 13: 8226
- [17] Kämmerling N, Sandstedt M, Farnebo S et al. Assessment of image quality in photon-counting detector computed tomography of the wrist – An ex vivo study. *Eur J Radiol* 2022; 154: 110442. doi:10.1016/j.ejrad.2022.110442
- [18] Patzer TS, Kunz AS, Huflage H et al. Ultrahigh-Resolution Photon-Counting CT in Cadaveric Fracture Models: Spatial Frequency Is Not Everything. *Diagnostics (Basel)* 2023; 13 (10): 1677. doi:10.3390/diagnostics13101677
- [19] Conrads N, Grunz J-P, Huflage H et al. Ultrahigh-resolution computed tomography of the cervical spine without dose penalty employing a cadmium-telluride photon-counting detector. *Eur J Radiol* 2023; 160: 110718
- [20] Peña JA, Klein L, Maier J et al. Dose-efficient assessment of trabecular microstructure using ultra-high-resolution photon-counting CT. *Z Med Phys* 2022; 32: 403–416. doi:10.1016/j.zemedi.2022.04.001
- [21] Thomsen FSL, Horstmeier S, Niehoff JH et al. Effective Spatial Resolution of Photon Counting CT for Imaging of Trabecular Structures is Superior to Conventional Clinical CT and Similar to High Resolution Peripheral CT. *Invest Radiol* 2022; 57: 620–626. doi:10.1097/RLI.0000000000000873
- [22] Grunz JP, Petritsch B, Luetkens KS et al. Ultra-Low-Dose Photon-Counting CT Imaging of the Paranasal Sinus With Tin Prefiltration: How Low Can We Go? *Invest Radiol* 2022; 57: 728–733
- [23] Sonnow L, Salimova N, Behrendt L et al. Photon-counting CT of elbow joint fractures: image quality in a simulated post-trauma setting with off-center positioning. *Eur Radiol Exp* 2023; 7: 15
- [24] Gaillandre Y, Duhamel A, Flohr T et al. Ultra-high resolution CT imaging of interstitial lung disease: impact of photon-counting CT in 112 patients. *Eur Radiol* 2023; 33 (8): 5528–5539. doi:10.1007/s00330-023-09616-x
- [25] Marton N, Gyebnar J, Fritsch K et al. Photon-counting computed tomography in the assessment of rheumatoid arthritis-associated interstitial lung disease: an initial experience. *Diagn Interv Radiol* 2023; 29: 291–299. doi:10.4274/dir.2023.221959
- [26] Dunning CAS, Marsh JF, Winfree T et al. Accuracy of Nodule Volume and Airway Wall Thickness Measurement Using Low-Dose Chest CT on a Photon-Counting Detector CT Scanner. *Invest Radiol* 2023; 58: 283–292. doi:10.1097/RLI.0000000000000933
- [27] Prayer F, Kienast P, Strassl A et al. Detection of Post-COVID-19 Lung Abnormalities: Photon-counting CT versus Same-Day Energy-integrating Detector CT. *Radiology* 2023; 307: e222087. doi:10.1148/radiol.222087
- [28] Huber NR, Ferrero A, Rajendran K et al. Dedicated convolutional neural network for noise reduction in ultra-high-resolution photon-counting detector computed tomography. *Phys Med Biol* 2022; 67 (17). doi:10.1088/1361-6560/ac8866
- [29] Sartoretti T, Racine D, Mergen V et al. Quantum Iterative Reconstruction for Low-Dose Ultra-High-Resolution Photon-Counting Detector CT of the Lung. *Diagnostics (Basel)* 2022; 12 (2): 522. doi:10.3390/diagnostics12020522
- [30] Van Ballaer V, Dubbeldam A, Muscogiuri E et al. Impact of ultra-high-resolution imaging of the lungs on perceived diagnostic image quality using photon-counting CT. *Eur Radiol* 2023. doi:10.1007/s00330-023-10174-5
- [31] Greffier J, Si-Mohamed SA, Lacombe H et al. Virtual monochromatic images for coronary artery imaging with a spectral photon-counting CT in comparison to dual-layer CT systems: a phantom and a preliminary human study. *Eur Radiol* 2023; 33 (8): 5476–5488
- [32] Remy-Jardin M, Hutt A, Flohr T et al. Ultra-High-Resolution Photon-Counting CT Imaging of the Chest: A New Era for Morphology and Function. *Invest Radiol* 2023; 58: 482–487. doi:10.1097/RLI.0000000000000968
- [33] Mergen V, Eberhard M, Manka R et al. First in-human quantitative plaque characterization with ultra-high resolution coronary photon-counting CT angiography. *Front Cardiovasc Med* 2022; 9: 981012
- [34] Holmes TW, Yin Z, Stevens GM et al. Ultra-high-resolution spectral silicon-based photon-counting detector CT for coronary CT angiography: Initial results in a dynamic phantom. *J Cardiovasc Comput Tomogr* 2023; 17 (5): 341–344. doi:10.1016/j.jcct.2023.08.003
- [35] Rajendran K, Baffour F, Powell G et al. Improved visualization of the wrist at lower radiation dose with photon-counting-detector CT. *Skeletal Radiol* 2023; 52: 23–29
- [36] Baffour FI, Rajendran K, Glazebrook KN et al. Ultra-high-resolution imaging of the shoulder and pelvis using photon-counting-detector CT: a feasibility study in patients. *Eur Radiol* 2022; 32: 7079–7086. doi:10.1007/s00330-022-08925-x
- [37] McCabe C, Sauer TJ, Zarei M et al. A systematic assessment of photon-counting CT for bone mineral density and microarchitecture quantifications. *Proc SPIE Int Soc Opt Eng* 2023; 12463: 1246303
- [38] Huflage H, Grunz JP, Kunz AS et al. Potential of employing a quantum iterative reconstruction algorithm for ultra-high-resolution photon-counting detector CT of the hip. *Radiography (Lond)* 2023; 29: 44–49. doi:10.1016/j.radi.2022.09.010
- [39] Ruetters M, Sen S, Gehrig H et al. Dental imaging using an ultra-high resolution photon-counting CT system. *Sci Rep* 2022; 12: 7125. doi:10.1038/s41598-022-11281-x
- [40] Rajendran K, Petersilka M, Henning A et al. Full field-of-view, high-resolution, photon-counting detector CT: technical assessment and initial patient experience. *Phys Med Biol* 2021; 66. doi:10.1088/1361-6560/ac155e
- [41] Rajendran K, Voss BA, Zhou W et al. Dose Reduction for Sinus and Temporal Bone Imaging Using Photon-Counting Detector CT With an Additional Tin Filter. *Invest Radiol* 2020; 55: 91–100
- [42] Benson JC, Rajendran K, Lane JI et al. A New Frontier in Temporal Bone Imaging: Photon-Counting Detector CT Demonstrates Superior Visualization of Critical Anatomic Structures at Reduced Radiation Dose. *AJNR Am J Neuroradiol* 2022; 43: 579–584. doi:10.3174/ajnr.A7452
- [43] Rajagopal JR, Schwartz FR, Solomon JB et al. High Spatial-Resolution Skull Base Imaging With Photon-Counting Computed Tomography and Energy-Integrating Computed Tomography: A Comparative Phantom Study. *J Comput Assist Tomogr* 2023; 47 (4): 613–620

- [44] Rau A, Straehle J, Stein T et al. Photon-Counting Computed Tomography (PC-CT) of the spine: impact on diagnostic confidence and radiation dose. *Eur Radiol* 2023; 33 (8): 5578–5586. doi:10.1007/s00330-023-09511-5
- [45] Marth AA, Marcus RP, Feuerriegel GC et al. Photon-Counting Detector CT Versus Energy-Integrating Detector CT of the Lumbar Spine: Comparison of Radiation Dose and Image Quality. *AJR Am J Roentgenol* 2024; 222 (1): e2329950. doi:10.2214/AJR.23.29950
- [46] Sartoretti T, Landsmann A, Nakhostin D et al. Quantum Iterative Reconstruction for Abdominal Photon-counting Detector CT Improves Image Quality. *Radiology* 2022; 303: 339–348. doi:10.1148/radiol.211931
- [47] Cook J, Rajendran K, Ferrero A et al. Photon counting detector CT: a new frontier of myeloma bone disease evaluation. *Acta Haematol* 2023; 146 (5): 419–423. doi:10.1159/000531461
- [48] Schwartz FR, Vinson EN, Spritzer CE et al. Prospective Multireader Evaluation of Photon-counting CT for Multiple Myeloma Screening. *Radiol Imaging Cancer* 2022; 4: e220073. doi:10.1148/rycan.220073
- [49] Baffour FI, Huber NR, Ferrero A et al. Photon-counting Detector CT with Deep Learning Noise Reduction to Detect Multiple Myeloma. *Radiology* 2023; 306: 229–236
- [50] Winkelmann MT, Hagen F, Le-Yannou L et al. Myeloma bone disease imaging on a 1st-generation clinical photon-counting detector CT vs. 2nd-generation dual-source dual-energy CT. *Eur Radiol* 2023; 33: 2415–2425. doi:10.1007/s00330-022-09225-0
- [51] Wehrse E, Sawall S, Klein L et al. Potential of ultra-high-resolution photon-counting CT of bone metastases: initial experiences in breast cancer patients. *NPJ Breast Cancer* 2021; 7: 3. doi:10.1038/s41523-020-00207-3
- [52] Hermans R, Boomgaert L, Cockmartin L et al. Photon-counting CT allows better visualization of temporal bone structures in comparison with current generation multi-detector CT. *Insights Imaging* 2023; 14: 112
- [53] Booij R, Kämmerling NF, Oei EHG et al. Assessment of visibility of bone structures in the wrist using normal and half of the radiation dose with photon-counting detector CT. *Eur J Radiol* 2023; 159: 110662
- [54] Bette S, Decker JA, Braun FM et al. Optimal Conspicuity of Liver Metastases in Virtual Monochromatic Imaging Reconstructions on a Novel Photon-Counting Detector CT-Effect of keV Settings and BMI. *Diagnostics (Basel)* 2022; 12 (5): 1231. doi:10.3390/diagnostics12051231
- [55] Liu LP, Shapira N, Chen AA et al. First-generation clinical dual-source photon-counting CT: ultra-low-dose quantitative spectral imaging. *Eur Radiol* 2022; 32: 8579–8587. doi:10.1007/s00330-022-08933-x
- [56] Gruschwitz P, Hartung V, Kleefeldt F et al. Photon-Counting Versus Energy-Integrating Detector CT Angiography of the Lower Extremity in a Human Cadaveric Model With Continuous Extracorporeal Perfusion. *Invest Radiol* 2023; 58 (10): 740–745
- [57] Stamp LK, Anderson NG, Becce F et al. Clinical Utility of Multi-Energy Spectral Photon-Counting Computed Tomography in Crystal Arthritis. *Arthritis Rheumatol* 2019; 71: 1158–1162. doi:10.1002/art.40848
- [58] Chou H, Chin TY, Peh WCG. Dual-energy CT in gout – A review of current concepts and applications. *J Med Radiat Sci* 2017; 64: 41–51. doi:10.1002/jmrs.223
- [59] Baer K, Kieser S, Schon B et al. Spectral CT imaging of human osteoarthritic cartilage via quantitative assessment of glycosaminoglycan content using multiple contrast agents. *APL Bioeng* 2021; 5: 026101. doi:10.1063/5.0035312
- [60] Rajendran K, Murthy NS, Frick MA et al. Quantitative Knee Arthrography in a Large Animal Model of Osteoarthritis Using Photon-Counting Detector CT. *Invest Radiol* 2020; 55: 349–356. doi:10.1097/RLI.0000000000000648
- [61] Garcelon C, Abascal J, Olivier C et al. Quantification of cartilage and subchondral bone cysts on knee specimens based on a spectral photon-counting computed tomography. *Sci Rep* 2023; 13: 11080. doi:10.1038/s41598-023-38238-y
- [62] Starr AM, Wessely MA, Albastaki U et al. Bone marrow edema: pathophysiology, differential diagnosis, and imaging. *Acta Radiol* 2008; 49: 771–786. doi:10.1080/02841850802161023
- [63] Kellock TT, Nicolaou S, Kim SSY et al. Detection of Bone Marrow Edema in Nondisplaced Hip Fractures: Utility of a Virtual Noncalcium Dual-Energy CT Application. *Radiology* 2017; 284: 798–805. doi:10.1148/radiol.2017161063
- [64] Karaca L, Yuceler Z, Kantarci M et al. The feasibility of dual-energy CT in differentiation of vertebral compression fractures. *Br J Radiol* 2016; 89: 20150300. doi:10.1259/bjr.20150300
- [65] Reddy T, McLaughlin PD, Mallinson PI et al. Detection of occult, undisplaced hip fractures with a dual-energy CT algorithm targeted to detection of bone marrow edema. *Emerg Radiol* 2015; 22: 25–29
- [66] Wang C-K, Tsai JM, Chuang M-T et al. Bone marrow edema in vertebral compression fractures: detection with dual-energy CT. *Radiology* 2013; 269: 525–33
- [67] Koch V, Müller FC, Gosvig K et al. Incremental diagnostic value of color-coded virtual non-calcium dual-energy CT for the assessment of traumatic bone marrow edema of the scaphoid. *Eur Radiol* 2021; 31: 4428–4437. doi:10.1007/s00330-020-07541-x
- [68] Booz C, Nöske J, Lenga L et al. Color-coded virtual non-calcium dual-energy CT for the depiction of bone marrow edema in patients with acute knee trauma: a multireader diagnostic accuracy study. *Eur Radiol* 2020; 30: 141–150
- [69] Gosangi B, Mandell JC, Weaver MJ et al. Bone Marrow Edema at Dual-Energy CT: A Game Changer in the Emergency Department. *RadioGraphics* 2020; 40: 859–874. doi:10.1148/rg.2020190173
- [70] Pache G, Krauss B, Strohm P et al. Dual-energy CT virtual noncalcium technique: detecting posttraumatic bone marrow lesions—feasibility study. *Radiology* 2010; 256: 617–624. doi:10.1148/radiol.10091230
- [71] Long Z, Tiegs-Heiden CA, Anderson TL et al. Clinical evaluation of a new adaptive iterative metal artifact reduction method in whole-body low-dose CT skeletal survey examinations. *Skeletal Radiol* 2021; 50: 149–157. doi:10.1007/s00256-020-03547-0
- [72] Katsura M, Sato J, Akahane M et al. Current and Novel Techniques for Metal Artifact Reduction at CT: Practical Guide for Radiologists. *RadioGraphics* 2018; 38: 450–461. doi:10.1148/rg.2018170102
- [73] Laukamp KR, Zopfs D, Lennartz S et al. Metal artifacts in patients with large dental implants and bridges: combination of metal artifact reduction algorithms and virtual monoenergetic images provides an approach to handle even strongest artifacts. *Eur Radiol* 2019; 29: 4228–4238
- [74] Laukamp KR, Lennartz S, Neuhaus VF et al. CT metal artifacts in patients with total hip replacements: for artifact reduction monoenergetic reconstructions and post-processing algorithms are both efficient but not similar. *Eur Radiol* 2018; 28: 4524–4533
- [75] Schmidt AMA, Grunz JP, Petritsch B et al. Combination of Iterative Metal Artifact Reduction and Virtual Monoenergetic Reconstruction Using Split-Filter Dual-Energy CT in Patients With Dental Artifact on Head and Neck CT. *AJR Am J Roentgenol* 2022; 218: 716–727
- [76] Khodarahmi I, Haroun RR, Lee M et al. Metal Artifact Reduction Computed Tomography of Arthroplasty Implants: Effects of Combined Modeled Iterative Reconstruction and Dual-Energy Virtual Monoenergetic Extrapolation at Higher Photon Energies. *Invest Radiol* 2018; 53: 728–735. doi:10.1097/RLI.0000000000000497
- [77] Neuhaus V, Grosse Hokamp N, Zopfs D et al. Reducing artifacts from total hip replacements in dual layer detector CT: Combination of virtual monoenergetic images and orthopedic metal artifact reduction. *Eur J Radiol* 2019; 111: 14–20
- [78] Schmitt N, Wucherpfennig L, Rotkopf LT et al. Metal artifacts and artifact reduction of neurovascular coils in photon-counting detector CT versus energy-integrating detector CT – in vitro comparison of a standard brain imaging protocol. *Eur Radiol* 2023; 33: 803–811. doi:10.1007/s00330-022-09073-y

- [79] Zhou W, Bartlett DJ, Diehn FE et al. Reduction of Metal Artifacts and Improvement in Dose Efficiency Using Photon-Counting Detector Computed Tomography and Tin Filtration. *Invest Radiol* 2019; 54: 204–211. doi:10.1097/RLI.0000000000000535
- [80] Do TD, Sawall S, Heinze S et al. A semi-automated quantitative comparison of metal artifact reduction in photon-counting computed tomography by energy-selective thresholding. *Sci Rep* 2020; 10: 21099. doi:10.1038/s41598-020-77904-3
- [81] Chang CH, Wu HN, Hsu CH et al. Virtual monochromatic imaging with projection-based material decomposition algorithm for metal artifacts reduction in photon-counting detector computed tomography. *PLoS One* 2023; 18: e0282900
- [82] Byl A, Klein L, Sawall S et al. Photon-counting normalized metal artifact reduction (NMAR) in diagnostic CT. *Med Phys* 2021; 48: 3572–3582. doi:10.1002/mp.14931
- [83] Richtsmeier D, O'Connell J, Rodesch PA et al. Metal artifact correction in photon-counting detector computed tomography: metal trace replacement using high-energy data. *Med Phys* 2023; 50: 380–396. doi:10.1002/mp.16049
- [84] Anhaus JA, Schmidt S, Killermann P et al. Iterative metal artifact reduction on a clinical photon counting system-technical possibilities and reconstruction selection for optimal results dependent on the metal scenario. *Phys Med Biol* 2022; 67 (11). doi:10.1088/1361-6560/ac71f0
- [85] Lee CL, Park J, Nam S et al. Metal artifact reduction and tumor detection using photon-counting multi-energy computed tomography. *PLoS One* 2021; 16: e0247355. doi:10.1371/journal.pone.0247355
- [86] Popp D, Sinzinger AX, Decker JA et al. Spectral metal artifact reduction after posterior spinal fixation in photon-counting detector CT datasets. *Eur J Radiol* 2023; 165: 110946. doi:10.1016/j.ejrad.2023.110946
- [87] Schreck J, Laukamp KR, Niehoff JH et al. Metal artifact reduction in patients with total hip replacements: evaluation of clinical photon counting CT using virtual monoenergetic images. *Eur Radiol* 2023; 33 (12): 9286–9295
- [88] Risch F, Decker JA, Popp D et al. Artifact Reduction From Dental Material in Photon-Counting Detector Computed Tomography Data Sets Based on High-keV Monoenergetic Imaging and Iterative Metal Artifact Reduction Reconstructions-Can We Combine the Best of Two Worlds? *Invest Radiol* 2023; 58 (9): 691–696
- [89] Layer YC, Mesropyan N, Kupczyk PA et al. Combining iterative metal artifact reduction and virtual monoenergetic images severely reduces hip prosthesis-associated artifacts in photon-counting detector CT. *Sci Rep* 2023; 13: 8955. doi:10.1038/s41598-023-35989-6
- [90] Patzer TS, Kunz AS, Huflage H et al. Combining virtual monoenergetic imaging and iterative metal artifact reduction in first-generation photon-counting computed tomography of patients with dental implants. *Eur Radiol* 2023; 33 (11): 7818–7829