


Comprehensive analysis of adverse events associated with transmural use of LAMS in patients with liver cirrhosis: International multicenter study



Authors

Faisal Nimri¹ , Yervant Ichkhanian², Brianna Shinn³, Thomas E. Kowalski³, David E. Loren³, Anand Kumar³, Alexander Schlachterman³, Alina Tantau⁴, Martha Arevalo⁵, Ashraf Taha¹, Omar Shamaa², Maria Chavarria Viales⁶, Mouen A. Khashab⁷, Stephen Simmer¹, Sumit Singla¹, Cyrus Piraka¹, Tobias E. Zuchelli¹

Institutions

- 1 Division of Gastroenterology and Hepatology, Henry Ford Hospital, Detroit, United States
- 2 Department of Internal Medicine, Henry Ford Hospital, Detroit, United States
- 3 Division of Gastroenterology and Hepatology, Thomas Jefferson Hospital, Wayne, United States
- 4 Division of Gastroenterology and Hepatology Medical Center, Iuliu Hatieganu University of Medicine and Pharmacy, Cluj-Napoca, Romania
- 5 Instituto Ecuatoriano de Enfermedades Digestivas (IECED), Guayaquil, Ecuador
- 6 Gastroenterology, Universidad Internacional de las Americas, San Jose, Costa Rica
- 7 Division of Gastroenterology and Hepatology, Johns Hopkins Hospital, Baltimore, United States

Keywords

Endoscopic ultrasonography, Intervention EUS, Endoscopy Upper GI Tract, Portal hypertension and variceal bleeding, Dilation, injection, stenting, Quality and logistical aspects, Performance and complications, Biliary tract

received 13.11.2023

accepted after revision 16.4.2024

Bibliography

Endosc Int Open 2024; 12: E740–E749

DOI 10.1055/a-2312-1528

ISSN 2364-3722

© 2024. The Author(s).

This is an open access article published by Thieme under the terms of the Creative Commons Attribution-NonDerivative-NonCommercial License, permitting copying and reproduction so long as the original work is given appropriate credit. Contents may not be used for commercial purposes, or adapted, remixed, transformed or built upon. (<https://creativecommons.org/licenses/by-nc-nd/4.0/>)

Georg Thieme Verlag KG, Rüdigerstraße 14,
70469 Stuttgart, Germany

Corresponding author

Dr. Faisal Nimri, MD, Henry Ford Hospital, Division of Gastroenterology and Hepatology, Detroit, United States
faisalnimri@gmail.com

ABSTRACT

Background and study aims Endoscopic ultrasound (EUS)-guided transmural (TM) deployment of lumen-apposing metal stents (LAMS) is considered relatively safe in non-cirrhotic patients and is cautiously offered to cirrhotic patients.

Patients and methods This was a retrospective, multicenter, international matched case-control study to study the safety of EUS-guided TM deployment of LAMS in cirrhotic patients.

Results Forty-three cirrhotic patients with model for end-stage liver disease score 12.5 ± 5 , with 23 having ascites and 16 with varices underwent EUS-guided TM LAMS deployment, including 19 for pancreatic fluid collection (PFC) drainage, 13 gallbladder drainage, six for endoscopic ultrasound-directed transgastric endoscopic retrograde cholangiopancreatography (ERCP), three for EDGI, one for endoscopic ultrasound-directed transenteric ERCP, and one postsurgical collection drainage. Technical failure occurred in one LAMS for PFC drainage. Clinical failure was encountered in another PFC. Nine adverse events (AEs) occurred. The most common AE was LAMS migration (3), followed by non-bleeding mucosal erosion (2), delayed bleeding (2), sepsis (1), and anesthesia-related complication (pulseless electrical activity) (1). Most AEs were graded as mild (6), followed by severe (2), and moderate (1); the majority were managed conservatively. On univariable comparison, risk of AE was higher when using a 20×10 mm LAMS and the absence of through-the-LAMS plastic stent(s). Conditional logistic regression of matched case-control patients did not show any association between potential predicting factors and occurrence of AEs.

‡ These authors contributed equally.

Conclusions Our study demonstrated that mainly in patients with Child-Pugh scores A and B cirrhosis and despite the presence of mild-to-moderate ascites in over half of

cases, the majority of AEs were mild and could be managed conservatively. Further studies are warranted to verify the safety of LAMS in cirrhotic patients.

Introduction

The transmural deployment of lumen-apposing metal stents (LAMS) under endoscopic ultrasound (EUS) guidance has expanded the array of gastrointestinal pathologies that can be endoscopically managed [1, 2]. Although LAMS were originally developed for the device-labeled uses of pancreatic fluid collection (PFC) and walled-off necrosis (WAN) drainage, the electrocautery-assisted bi-flanged design of LAMS paved the way for its use in many other indications that rely on the creation of de novo fistulas, such as endoscopic gallbladder drainage, management of gastric outlet obstruction, and access to the distal parts of the gastrointestinal tract for pancreaticobiliary interventions in patients with surgically altered anatomy [3, 4, 5, 6, 7, 8, 9, 10]. The high success rates with low adverse event (AE) rates seen in procedures that involve transmural LAMS has led to a shift away from invasive surgical or transcutaneous interventions toward novel, minimally invasive endoscopic procedures [3, 4, 5, 6, 7, 8, 9, 10].

The most common AEs encountered with transmural LAMS placement range from post-procedure abdominal pain, bleeding, and obstruction, to stent migration, and rarely, perforation, which all can be managed endoscopically with a short hospital stay [11, 12, 13, 14, 15]. Rates of AEs have been reported to be approximately 16% to 21% by Choi et al. However, for high-risk patients such as individuals with liver cirrhosis, invasive endoscopic procedures are often only cautiously offered. This is because patients with liver cirrhosis are prone to higher rates and increased severity of AE, because the loss of synthetic function in the liver and portal hypertension increase risks of bleeding and infection and can lead to poor healing capacity [16, 17]. In addition, endoscopy in this subpopulation of patients carries a theoretical risk of aggravating already existing disruptions in intestinal wall permeability, which could precipitate bacterial peritonitis [18, 19].

Only a handful of studies have evaluated the risks associated with EUS-guided transmural LAMS placement in patients with liver cirrhosis. Laique et al [20] assessed the risks associated with use of self-expandable metal stents for managing pancreatic fluid collections in patients with and without cirrhosis and found that this procedure can, indeed, carry significant risks in patients with cirrhosis [20]. Another study by James et al [21] looked at the efficacy and risks of EUS-guided gallbladder drainage (EUS-GBD) in patients with cirrhosis who were not eligible for surgical cholecystectomy. They showed that patients who were Child-Pugh class A or B were not at increased risk of AEs after EUS-GBD. [21]. Thus, given the paucity of data on EUS-guided transmural deployment of LAMS in patients with cirrhosis, and given the critical need for minimally invasive procedures to treat different conditions that increase the risk of

morbidity and mortality in this patient population, we aimed to explore outcomes in patients with cirrhosis who received EUS-guided transmural LAMS to shed light on the safety and utility of this approach.

Patients and methods

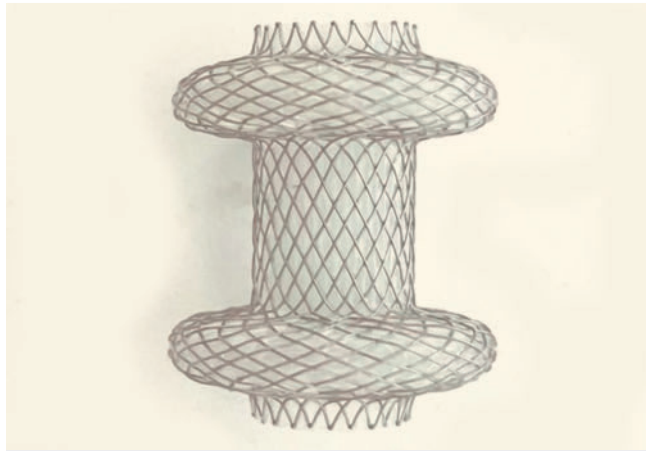
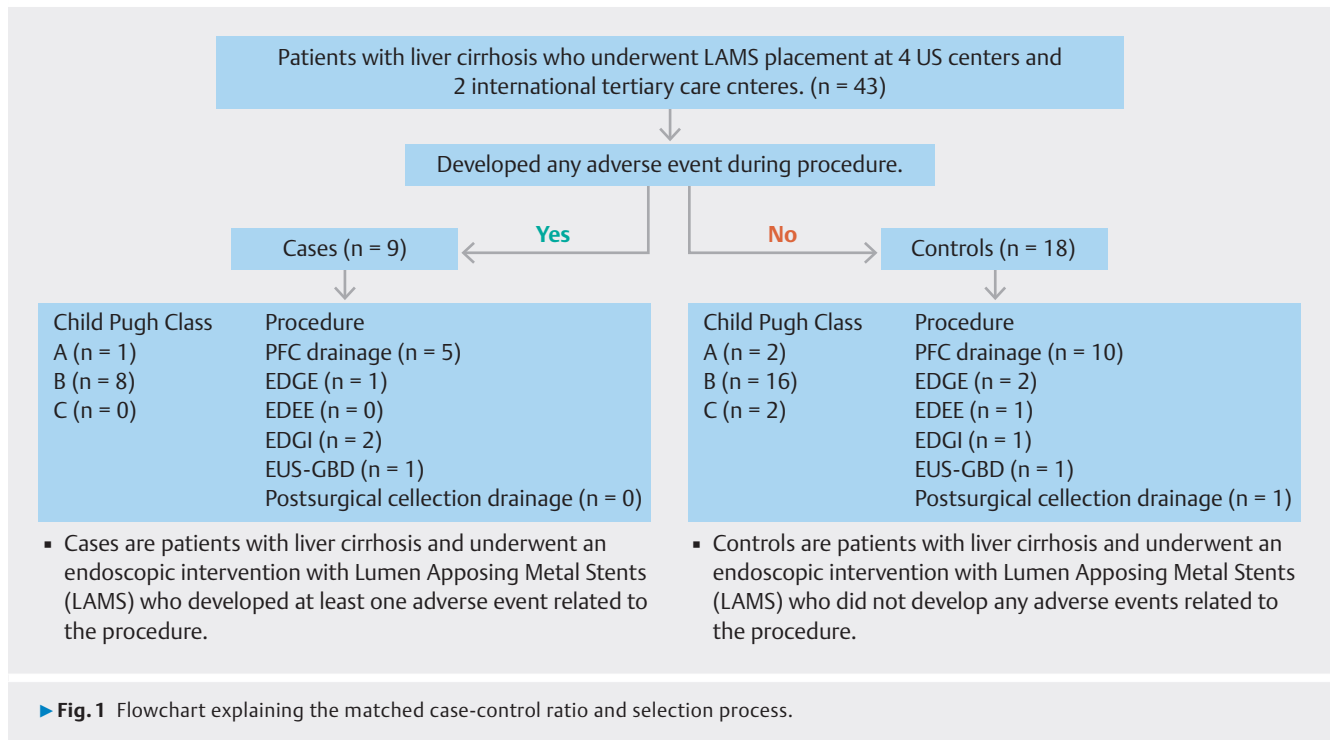
This was a retrospective, matched case-control study that included patients with a diagnosis of liver cirrhosis who underwent EUS-guided transmural LAMS placement at four US and two international tertiary care centers between March 2015 and September 2021. Patients who had intra-procedure or post-procedure AEs were identified as cases and those without reported AEs were identified as controls. Cases were matched with two controls based on type of procedure and Child-Pugh class based on the Child-Pugh scoring system using 1:2 case to control ratio (► **Fig. 1**).

Procedure techniques

All procedures were performed by 10 interventional endoscopists in the endoscopy unit with clinical experience in therapeutic endoscopy ranging from 5 to 20+ years. All patients underwent EUS-guided LAMS placement under general anesthesia during procedures. All LAMS stents used in this cohort were AXIOS stents (► **Fig. 2**). Both hot and cold LAMS placement techniques were used in our cohort. Hot technique included using of an electrocautery-enhanced catheter to create a tract between desired lumens for placement of LAMS and was used in 36 cases (84%), whereas the cold technique used the fine needle with a guidewire to create a tract between desired lumens for placement of LAMS without using electrocautery and was used in seven cases (16%). The five EUS-guided transmural LAMS deployment procedures included the following.

EUS-guided PFC drainage was used for management and drainage of PFC or WAN. This procedure was performed by advancing a therapeutic linear array echoendoscope to the stomach or duodenum. After the hypoechoic fluid collection within the pseudo-membrane was located, an electrocautery-enhanced LAMS was deployed under EUS guidance through a trans-gastric or trans-duodenal approach creating a cystogastrostomy/duodenostomy, allowing drainage and endoscopic necrosectomy of the necrotic matter [22].

EUS-directed trans-gastric endoscopic retrograde cholangiopancreatography (EDGE) was used to perform endoscopic retrograde cholangiopancreatography (ERCP) in patients with Roux-en-Y gastric bypass (RYGB). EDGE was performed by advancing a therapeutic linear array echoendoscope to the gastric pouch or the proximal jejunum. The excluded stomach was identified under EUS guidance and punctured with a 19-gauge fine-needle aspiration (FNA) needle followed by the trans-gas-



► **Fig. 2** Lumen-apposing metal stent used in our cohort, also known as AXIOS stent.

tric deployment of electrocautery-enhanced LAMS. This procedure creates a de novo gastro-gastric fistula, or gastro-jejunal fistula [23].

EUS-directed trans-enteric ERCP (EDEE) was used to perform ERCP in patients who did not have RYGB surgically altered anatomy. EDEE was performed by advancing a therapeutic linear array echoendoscope to the efferent bowel loop. The distended afferent limb was localized under EUS guidance and punctured with a 19-gauge FNA needle followed by trans-enteric deployment of electrocautery-enhanced LAMS, which creates a de novo entero-enteric fistula [24].

EUS-directed trans-gastric intervention (EDGI) is similar to EDGE; however, EDGI is used for interventions other than

ERCP, such as EUS-guided FNA or fine-needle biopsy and EUS-guided cystogastrostomy [25].

EUS-guided gallbladder drainage (EUS-GBD) was used to drain the gallbladder in patients with cholecystitis who were not candidates for surgical cholecystectomy. EUS-GBD was performed by advancing a therapeutic linear array echoendoscope into the prepyloric antrum or duodenal bulb, and under EUS guidance, a 19-gauge FNA needle was used to puncture the gallbladder. This was then followed by trans-gastric deployment of electrocautery-enhanced LAMS, which creates a de novo cholecystoduodenostomy or cholecystogastrostomy [26].

Postsurgical fluid collection drainage was performed by advancing a therapeutic linear array echoendoscope to identify the fluid collection and/or abscess and drain the collection by deploying a transluminal LAMS. The approach depends on the location of the fluid collection having been previously identified with cross-sectional imaging [27].

Definitions and data collection

Henry Ford Hospital was the lead center for this multicenter study. The study was approved by the Institutional Review Board for Human Research or its equivalent in all participating institutions. All de-identified data were compiled and shared with the lead center.

An AE was defined as a symptomatic event that was directly related to the transmural LAMS deployment procedure or anesthesia necessitating temporary/permanent cessation of the procedure and/or necessitating additional pharmacologic and/or surgical intervention. Post-procedure events that required prolonged hospital stay or additional diagnostic study or intervention other than the standard of care or medical consultation were considered AEs. The following procedure-related data

were collected: procedure duration, relevant technical details, and events. All pertinent data on AEs in terms of severity according to the ASGE (American Society for Gastrointestinal Endoscopy) severity grading system and AGREE (adverse events in gastrointestinal endoscopy) classification, timing, and management approach were collected [28,29]. “Early” AEs were those that occurred within 48 hours of the procedure and all others were considered “late.” Other patient data collected included the following: sex, age, model for end-stage liver disease (MELD) score, Child-Pugh class, Charlson comorbidity index (CCI), international normalized ratio (INR), American Society of Anesthesiologists (ASA) physical status score, and laboratory test results (platelet count, creatinine, alanine aminotransferase, aspartate transferase, and bilirubin).

Statistical analysis

A case-control analysis was performed with the aim of identifying factors associated with the occurrence of AEs after EUS-guided transmural LAMS placement. “Cases” were those patients at each participating center who underwent transmural LAMS placement and experienced an AE. “Controls” were those patients who underwent transmural LAMS placement without any AEs. For each case, two control patients were randomly selected by each center and matched by type of procedure and Child-Pugh Score.

Patient, physician, and procedure characteristics were reported as mean and standard deviation (SD) and case and control groups were compared. $P < 0.05$ was considered significant. A stepwise logistical regression analysis was performed to determine risk factors for AEs. For the matched case-control analysis for risk factors, conditional logistic regression was used. Risk factors were grouped based on their relation to patient, physician, and procedure. The variables were selected in a stepwise manner to be included in the model for multivariable analysis of each group. $P \leq 0.2$ was set as a cut-off to include the variable in the model. Statistical analysis was performed using SPSS software (SPSS 16.0, Chicago, Illinois, United States).

Results

A total of 43 patients with liver cirrhosis (mean \pm SD age 58.4 ± 12.3 years; 21 [49%] female) underwent EUS-guided transmural LAMS placement. There were 19 (44%) who underwent EUS for PFC drainage, six (14%) who received EDGE, one (2%) who underwent EDEE, three (9%) who underwent EDGI, 13 (30%) who had EUS-GBD, and one (2.3%) who had postsurgical collection drainage. A total of 23 patients (53%) had ascites (69% mild; 30% moderate), and 16 (37%) had varices (87% esophageal; 13% gastric). The mean MELD score was 12.5 ± 5 . There were 14 patients (33%) who were in Child-Pugh class A, 26 (60%) in class B, and 3 (7%) in class C (► **Table 1**).

Technical failure occurred in one control patient (2%) who received PFC drainage, during which the LAMS was deployed in close proximity to the splenic artery, which required its removal and a repeat procedure during the same session. Clinical failure occurred in one other control patient (2%), in which the walled-

off pancreatic necrosis did not resolve, and thus required percutaneous drainage (► **Table 1**).

Adverse event severity, timing, and management

A total of nine adverse events (21%) occurred. The most common AE was LAMS migration in three patients (33%), followed by non-bleeding mucosal erosion in two patients (22%), delayed bleeding in two patients (22%), sepsis in one patient (11%), and anesthesia-related complication (pulseless electrical activity) in one patient (11%). No intra-procedure AEs were reported. There were two early AEs (22%), both of which occurred within 24 hours of the procedure, while seven AEs (78%) were late (> 48 hours after procedure). Most AEs were graded as mild ($n=6$ [67%]), followed by two (22%) that were severe and one (11%) that was moderate, with most ($n=5$ [56%]) having been managed conservatively (► **Table 2**).

Early post-procedure adverse events

The two early post-procedure AEs were classified as severe. In one EUS-GBD procedure, the patient developed septic shock 4 hours after the procedure and required escalation of the level of care to the Intensive Care Unit (ICU). The patient received intravenous broad-spectrum antibiotics and temporary vasopressor support and recovered. The second patient who had an early AE had received PFC drainage and had pulseless electrical activity immediately after the procedure. The patient required advanced cardiovascular life support and supportive care in the ICU.

Late post-procedure adverse events

Of the seven patients who had late AEs, six (86%) were mild, and most ($n=5$ [71%]) were treated conservatively. Asymptomatic LAMS migration was encountered in three patients (2 PFC drainage; 1 EDGI). The stents from these procedures were repositioned or replaced during scheduled routine procedures. Non-bleeding mucosal erosion occurred in two patients (1 EDGI; 1 EDGE) who were treated conservatively, and mucosal erosion healing was documented in one patient.

There were two patients who experienced delayed bleeding. The first had undergone EDGE. The bleeding was characterized as moderate because it required an unscheduled upper endoscopy 4 days after the initial procedure, during which time old blood clots were noted inside the LAMS. The patient received conservative treatment. The other patient underwent PFC drainage, and the bleeding was characterized as mild because blood clots inside the LAMS were noted at the time of the scheduled removal (► **Table 2**).

Characteristics associated with adverse events: Matched case-control analysis

No significant differences in occurrence of AEs were observed among the different categories of transmural LAMS deployment ($P=0.231$) (► **Table 1**). Although a higher proportion of cases than controls were in Child-Pugh class B, the difference between groups was not significant (89% case vs 53% control; $P=0.21$).

► **Table 1** Baseline patient, disease, and procedure characteristics.

	Total (N = 43)	Cases with adverse events (n = 9)	Controls no adverse events (n = 34)	P value
Sex, F n (%) female sex, no. (%)	21 (49%)	4 (44%)	17 (50%)	–
Age, years, mean ± SD	58.44 ± 12.3	58.13 ± 6.2	57.71 ± 11.2	0.213
ASA, mean ± SD	3.4 ± 0.6	3.6 ± 1.3	3.3 ± 0.7	0.116
Charlson Comorbidity Index (CCI), mean ± SD	5.2 ± 2.9	5.1 ± 1.2	5.3 ± 2.7	0.214
INR, mean ± SD	1.3 ± 0.3	1.6 ± 1.2	1.4 ± 0.7	0.235
Platelets, mean ± SD	263.9 ± 156	251.2 ± 136	253.9 ± 253	0.123
Total bilirubin, mg/dL, mean ± SD	1.6 ± 1.7	1.4 ± 2.1	1.7 ± 1.8	0.223
AST, U/L, mean ± SD	55.4 ± 62.4	54.3 ± 61.3	53.1 ± 65.1	0.124
ALT, U/L, mean ± SD	44.4 ± 68	44.1 ± 58	44.8 ± 62	0.214
Creatinine, mg/dL, mean ± SD	0.9 ± 0.6	0.9 ± 0.4	1 ± 0.7	0.221
MELD score, mean ± SD				0.241
▪ Basic MELD	12.5 ± 5	13.1 ± 4	12.4 ± 2.6	
▪ MELD-Na, mean ± SD	13.9 ± 5.8	12.8 ± 4.2	13.1 ± 5.6	
Child-Pugh score, n (%)				0.127
▪ A	14 (33)	1 (11)	13 (38)	
▪ B	26 (60)	8 (89)	18 (53)	
▪ C	3 (7)	0	3 (8.8)	
Ascites, n (%)				0.112
▪ No	16 (37)	2 (22)	14 (41)	
▪ Mild	20 (37)	6 (67)	14 (41)	
Presence of varices, n (%)				0.231
▪ Esophageal grade 1	11 (26)	3 (33)	8 (24)	
▪ Esophageal grade 2	3 (7)	0 (8.8)	3 (8.8)	
▪ Gastric	2 (4.7)	1 (2.9)	1 (2.9)	
Procedure, n (%)				0.231
▪ PFC drainage	19 (44)	5 (56)	14 (42)	
▪ EDGE	6 (14)	1 (11)	5 (15)	
▪ EDEE	1 (2.3)	0	1 (2.9)	
▪ EDGI	3 (7)	2 (22)	1 (3)	
▪ EUS-GBD	13 (30)	1 (11)	12 (36)	
▪ Postsurgical (abscess/seroma) collection drainage	1 (2.3)	0	1 (2.9)	
LAMS size, n (%)				0.039
▪ 10 × 10 mm	12 (28)	1 (11)	11 (32)	
▪ 15 × 10 mm	29 (67)	6 (67)	23 (68)	
▪ 20 × 10 mm	2 (5)	2 (22)	0	
LAMS deployment technique, n (%)				0.172
▪ Hot/electrocautery-enhanced	36 (84)	8 (89)	28 (82)	
▪ Cold/over a guide wire	7 (16)	1 (11)	6 (18)	

► **Table 1** (Continuation)

	Total (N = 43)	Cases with adverse events (n = 9)	Controls no adverse events (n = 34)	P value
LAMS placement of plastic stent, n (%)	25 (58)	2 (22)	23 (68)	0.045
▪ 1 stent	15 (35)	0	15 (44)	
▪ 2 stents	9 (21)	2 (22)	7 (21)	
▪ 3 stents	1 (2)	0	1 (3)	
Technical success, n (%)	42 (98)	9 (100)	33 (97)	0.211
Clinical success, n (%)	42 (98)	9 (100)	33 (97)	0.131

ALT, alanine aminotransferase; ASA, American Society of Anesthesiologists physical status score; AST, aspartate transferase; EDEE, EUS-directed trans-enteric ERCP; EDGE, EUS-directed trans-gastric ERCP; EDGI, EUS-directed trans-gastric interventions; ERCP, endoscopic retrograde cholangiopancreatography; EUS, endoscopic ultrasound; EUS-GBD, EUS-guided gallbladder drainage; FNA, fine-needle aspiration; INR, international normalized ratio; LAMS, lumen-apposing metal stent; MELD, model for end-stage liver disease score; MELD-Na, model for end-stage liver disease with sodium; PFC, pancreatic fluid collection; SD, standard deviation.

Univariate analysis showed that LAMS size and LAMS placement of a plastic stent were significantly different between groups. While approximately the same proportion of patients in each group received a 15×10mm LAMS (67% case vs 71% control), a smaller proportion of patients who received a 10×10mm LAMS had an AE (11% case vs. 32% control) and a much higher proportion of those who received a 20×10mm LAMS had an AE (22% case vs 0% control; $P = 0.039$). Notably, a much smaller proportion of patients in the case group than in the control group received LAMS placement of at least one plastic stent (22% vs 68%; $P = 0.045$) which may be related to the anchoring effect lowering the risk for stent migration or bleeding from mucosal irritation of the metal flanges of the LAMS (► **Table 1**). However, conditional logistic regression of matched case and control patients did not show any association between any potential predicting factors and occurrence of AEs.

Discussion

In this study of AEs seen in patients with cirrhosis who underwent endoscopic transmural LAMS placement, we observed that 21% of patients experienced AE. While we did not assess AE development relative to patients who did not have cirrhosis, we looked at various different endoscopic LAMS placement procedures and did not see a significant difference in number of AEs based on procedure type. However, our results suggest that plastic stent placement and smaller LAMS size may be associated with lower rates of AE development in this patient population, and that placement of larger LAMS may lead to more AEs.

Endoscopic LAMS placement is an important emerging alternative to many complex and invasive procedures. LAMS deployment represents an easier, relatively low risk and less invasive procedure that results in mortality and quality-of-life outcomes to more invasive options [3]. Overall AE rates for endoscopic LAMS placement were found to be about 16% to 21% depending on indication, intervention and patient population and these include abdominal pain, bleeding, infections, stent mal-

function, stent migration and rarely perforation [29]. However, several underlying medical conditions can affect the safety profile of any procedural intervention, including surgeries and endoscopies, and patients with multiple comorbid conditions can be at a higher risk for complications and AEs from the intervention itself or from periprocedure aspects, such as anesthesia [30].

Liver cirrhosis is a medical condition that carries a higher risk of periprocedure complications. Postsurgical mortality is about 2- to 10-fold higher in patients with cirrhosis than in the general population [31, 32], and endoscopic procedures are generally considered higher risk for patients with cirrhosis. Simon et al. found that the major AEs that complicate general endoscopic procedures in patients with cirrhosis are hemorrhage, perforation, and generalized infections, among others [33]. In our study, 43 patients with cirrhosis had undergone different procedures of transmural LAMS deployment in six international centers. Despite the fact that most of the cohort (79%) had Child-Pugh class B liver cirrhosis, only nine patients experienced an AE, a rate of 21%. A study of patients with cirrhosis who had ERCP found that of 158 patients with cirrhosis 27 (17.1%) experienced an AE, which is a slightly lower rate than what we observed [34]. James TW et al also reported two AEs in a cohort of 15 patients (13.3%) with cirrhosis who underwent EUS-GBD, which included stent misdeployment requiring surgery and acute pancreatitis. They also reported a patient with hepatic decompensation after the procedure [35]. But both of these studies looked at only one type of procedure, whereas our study looked at a range of LAMS deployment approaches; thus, our study gives insight into the types of AEs that may follow from specific uses of LAMS.

Almost half of our cohort (19/43) underwent EUS-guided LAMS deployment for PFC drainage, and five of these patients developed an AE, four of which were mild, including asymptomatic LAMS migration (2 patients) found at routine repeat esophagogastroduodenoscopy, non-bleeding mucosal erosion (1 patient 38 days after procedure), and delayed bleeding (1 patient with blood clots within LAMS at routine repeat EGD with

► **Table 2** Severity, timing, and treatment of adverse events.

Adverse event	Type of procedure	Liver status	ASGE Lexicon Severity Score	AGREE classification system for adverse events	Timing	AE details	Management	Follow-up findings
LAMS migration #1	PFC drainage	INR: 1.3 Platelets: 276 Ascites: moderate Varices: none MELD: 10 Child-Pugh Score: B	Mild	Grade I	Late post-procedure (30 days)	A 10 × 10 mm hot LAMS was deployed + 2 plastic stents through LAMS. No necrosectomy was performed. On repeat routine EGD, LAMS was found to be displacement distally into the cyst.	Redeployment of a new LAMS and removal of the old one	PFC was resolved and LAMS was removed 45-days post initial procedure
LAMS migration #2	EDGI	INR: 1.8 Platelets: 252 Ascites: mild Varices: none MELD: 10 Child-Pugh Score: B	Mild	Grade I	Late post-procedure (2 days)	A 15 × 10 mm hot LAMS was deployed to access the excluded stomach to investigate a bleeding source which was managed successfully. On repeat routine EGD, LAMS was found to be displaced distally into the excluded stomach.	The previously deployed LAMS was fixed with endoscopic suturing	Stent removed 2 weeks post-deployment
LAMS migration #3	PFC drainage	NR: 1.6 Platelets: 240 Ascites: mild Varices: none MELD: 10 Child-Pugh Score: A	Mild	Grade I	Late post-procedure (45 days)	A 15 × 10 mm hot LAMS was deployed. Necrosectomy was performed. At the time of LAMS (repeat routine EGD) removal, displacement of stent into the stomach was noted.	None – Conservative management.	LAMS was removed at 45 days post-deployment
Non-bleeding mucosal erosion #1	PFC drainage	INR: 1.6 Platelets: 216 Ascites: mild Varices: Grade 1 MELD: 15 Child-Pugh Score: B	Mild	Grade I	Late post-procedure (38 days)	A 20 × 10 mm hot LAMS was deployed with 2 plastic stents through LAMS. No necrosectomy was performed. On repeat routine EGD, mild non-bleeding gastric mucosal erosion was noted adjacent to LAMS	None - Conservative management	LAMS was removed 38 days post-deployment. No further interventions were required post-LAMS removal
Non-bleeding mucosal erosion #2	EDGI	INR: 1.6 Platelets: 310 Ascites: moderate Varices: Grade 1 MELD: 14 Child-Pugh Score: B	Mild	Grade I	Late post-procedure (23 days)	A 15 × 10 mm hot LAMS was utilized to access the excluded stomach and limb to perform diagnostic EUS-FNA of pancreatic mass. On repeat routine EGD, non-bleeding gastric mucosal erosion was noted adjacent to LAMS	None – Conservative management	Stent removed 3 weeks post-deployment. No further interventions were required post-LAMS removal

► **Table 2** (Continuation)

Adverse event	Type of procedure	Liver status	ASGE Lexicon Severity Score	AGREE classification system for adverse events	Timing	AE details	Management	Follow-up findings
Delayed bleeding	EDGE	INR: 1.9 Platelets: 200 Ascites: mild Varices: Grade 1 MELD: 14 Child-Pugh Score: B	Moderate	Grade IIIa	Late post-procedure (2 days)	A 20 × 10 mm cold LAMS was deployed to access the excluded stomach and limb. On repeat (unscheduled) EGD, blood clots were found inside the LAMS with no signs of active bleeding.	None – Conservative management	LAMS was removed 1 month later, with no further signs of active bleeding
Delayed bleeding	PFC drainage	INR: 1.9 Platelets: 215 Ascites: mild Varices: none MELD: 10 Child-Pugh Score: B	Mild	Grade I	Late post-procedure (27 days)	A 15 × 10 mm hot LAMS was deployed. Necrosectomy was performed. At the time of LAMS removal (routine repeat EGD), blood clots were found inside the LAMS with no signs of active bleeding.	None – Conservative management	LAMS was removed with no further signs of active bleeding
Sepsis	EUS-guided gallbladder drainage	INR: 1.4 Platelets: 189 Ascites: moderate Varices: None MELD: 10 Child-Pugh Score: B	Severe	Grade IVa	Early post-procedure (same day)	A 15 × 10 mm hot LAMS was deployed into the gallbladder for the management of acute cholecystitis (trans-gastric approach). Shortly after the procedure patient became septic.	Sepsis management + ICU admission	Cholecystectomy was not performed during the duration of the study.
Pulses Electric Activity	PFC drainage	INR: 1.35 Platelets: 671 Ascites: mild Varices: None MELD: 17 Child-Pugh Score: B	Severe	Grade IVa	Early post-procedure (same day)	A 15 × 10 mm hot LAMS was deployed. Necrosectomy was performed. Shortly after the procedure patient suffered a PEA with ROSC achieved. The patient was later found to have a pulmonary embolism	ACLS + ICU admission	LAMS was removed 2 weeks post-procedure

AE, adverse event; AGREE, adverse events in gastrointestinal endoscopy; ASGE, American Society for Gastrointestinal Endoscopy; PFC, pancreatic fluid collection; EDEE, EUS-directed trans-enteric ERCP; EDGE, EUS-directed trans-gastric ERCP; EDGI, EUS-directed trans-gastric interventions; ERCP, endoscopic retrograde cholangiopancreatography; EUS, endoscopic ultrasound; INR, international normalized ratio; LAMS, lumen-apposing metal stent; MELD, model for end-stage liver disease score.

no signs of active bleeding or overt gastrointestinal bleeding 27 days after procedure). The next most performed procedure was EUS-GBD in 13 patients (30%). While all the patients who had EUS-GBD had successful gallbladder drainage with no procedure-related complications, one patient developed sepsis shortly after the procedure, requiring intensive care admission with intravenous antibiotics. This patient received EUS-GBD with a 15 × 10 mm hot LAMS for treatment of acute cholecysti-

tis, and the patient improved with care. In descending order of number of procedures performed, EDGE, EDGI, EDEE, and post-surgical abscess collection drainage were the final procedures assessed. Of the six patients who underwent the EDGE procedure, only one patient had a moderate AE, which was delayed bleeding 3 days after LAMS deployment. Blood clots were noticed inside of the LAMS on repeat EGD, but no bleeding source or active bleeding was found. This patient was in Child-Pugh

class B with a MELD of 14 and an INR of 1.9, and they experienced other sequelae of decompensated portal hypertension (ascites and varices). The patient was treated conservatively and recovered successfully.

For EDGI procedures, two of the three patients who received this procedure had mild AEs. This included a LAMS migration 2 days after placement in a patient who underwent EDGI for investigation of a possible upper gastrointestinal bleeding source, and this event was managed by suturing in place. The second patient, who had an RYGB, experienced non-bleeding mucosal erosion diagnosed incidentally on routine EGD 3 weeks after LAMS deployment for EUS-guided FNA, which was required to access the excluded stomach to investigate a concerning pancreatic mass. The two cases of mucosal erosions reported were thought to be related to the LAMS stent flanges rubbing into the mucosa, but it was only discovered on routine EGD follow-up after LAMS placement and there were no significant clinic symptoms associated with these mucosal erosions, including bleeding or pain. The LAMS stent was removed in both cases at the time of diagnosis of mucosal erosions, but also because the indication for the intervention had already been achieved.

We believe that the rate of AEs from transmural LAMS deployment in this high-risk population was not unusual because the complications observed were all mild. Stent migration was the most common AE seen in three patients, and can be related to performing subsequent intervention during the same session after LAMS placement. This is a well-known risk factor for stent migration even in patients without liver cirrhosis and multiple interventions are used to prevent such complication, including LAMS stent fixation with suturing or clipping. We observed only two severe AEs, which occurred on the same day that the procedures were performed and in the most commonly performed procedures. Also, whether these AEs were directly related to the procedures or the underlying disease process for which these procedures were performed remains unclear. However, our data suggest that plastic stents may lead to fewer AEs in patients with cirrhosis, and larger-sized LAMS may best be avoided in patients with cirrhosis.

This study had several limitations, including limited sample size, its retrospective nature, and limited follow-up time. However, this was the first attempt to comprehensively analyze a range of variables that could be associated with AEs after different modes of transmural LAMS deployment in patients with cirrhosis. Thus, our study should be cautiously interpreted. Transmural LAMS placement is still considered a high-risk procedure overall, and patients with liver cirrhosis are considered a high-risk population. Therefore, further prospective controlled studies are required to reveal the true risks associated with endoscopic LAMS procedures in patients with cirrhosis.

Conclusions

In conclusion, the safety profile of endoscopic transmural LAMS placement among patients with liver cirrhosis, especially with CPS A and CPS B patients, may be comparable to that reported in patients without liver cirrhosis. Most of the AEs reported in

our cohort were mild in severity and often managed conservatively.

Conflict of Interest

T. Zuchelli: Consultant for Boston Scientific, C. Piraka is recipient of study funding from Aries and US Endoscopy. A. Kumar: Consultant for Boston Scientific. T. Kowalski: Consultant for Olympus and Boston Scientific, D. Loren: Consultant for Olympus, A. Schlachterman: consultant for Fujifilm Healthcare and Olympus, M. A. Khashab: Consultant for Boston Scientific, Medtronic, Olympus, Pentax, Apollo, and Laborie; research support from Boston Scientific and royalties from Elsevier and UpToDate. All other authors have no relevant conflicts of interest.

References

- [1] Sharma P, McCarty TR, Chhoda A et al. Alternative uses of lumen apposing metal stents. *World J Gastroenterol* 2020; 26: 2715–2728 doi:10.3748/wjg.v26.i21.2715
- [2] Stier MW, Waxman I. Lumen-apposing metal stents: Which one and why? *Gastrointest Endosc Clin N Am* 2018; 28: 207–217 doi:10.1016/j.giec.2017.11.008
- [3] Bhenswala P, Lakhana M, Gress FG et al. Novel uses of lumen-apposing metal stents: a review of the literature. *J Clin Gastroenterol* 2021; 55: 641–651 doi:10.1097/MCG.0000000000001566
- [4] Bang JY, Hasan M, Navaneethan U et al. Lumen-apposing metal stents (LAMS) for pancreatic fluid collection (PFC) drainage: may not be business as usual. *Gut* 2017; 66: 2054–2056 doi:10.1136/gutjnl-2016-312812
- [5] Mohan BP, Jayaraj M, Asokkumar R et al. Lumen apposing metal stents in drainage of pancreatic walled-off necrosis, are they any better than plastic stents? A systematic review and meta-analysis of studies published since the revised Atlanta classification of pancreatic fluid collections *Endosc Ultrasound* 2019; 8: 82–90
- [6] Jain D, Bhandari BS, Agrawal N et al. Endoscopic ultrasound-guided gallbladder drainage using a lumen-apposing metal stent for acute cholecystitis: A systematic review. *Clin Endosc* 2018; 51: 450–462 doi:10.5946/ce.2018.024
- [7] Tyberg A, Kedia P, Tawadros A et al. EUS-directed transgastric endoscopic retrograde cholangiopancreatography (EDGE): The first learning curve. *J Clin Gastroenterol* 2020; 54: 569–572 doi:10.1097/MCG.0000000000001326
- [8] Krafft MR, Hsueh W, James TW et al. The EDGI new take on EDGE: EUS-directed transgastric intervention (EDGI), other than ERCP, for Roux-en-Y gastric bypass anatomy: a multicenter study. *Endosc Int Open* 2019; 7: E1231–E1240
- [9] Khashab MA. Endoscopic ultrasound-directed transenteric ERCP (EDEE) in patients with postsurgical anatomy – novel but challenging. *Endoscopy* 2019; 51: 1119–1120 doi:10.1055/a-0958-2323
- [10] Itoi T, Baron TH, Khashab MA et al. Technical review of endoscopic ultrasonography-guided gastroenterostomy in 2017. *Dig Endosc* 2017; 29: 495–502 doi:10.1111/den.12794
- [11] Mangiavillano B, Moon JH, Crino SF et al. Safety and efficacy of a novel electrocautery-enhanced lumen-apposing metal stent in interventional EUS procedures (with video). *Gastrointest Endosc* 2022; 95: 115–122
- [12] Shah RJ, Shah JN, Waxman I et al. Safety and efficacy of endoscopic ultrasound-guided drainage of pancreatic fluid collections with lumen-apposing covered self-expanding metal stents. *Clin Gastroenterol Hepatol* 2015; 13: 747–752

- [13] Bazaga Pérez de Rozas S, Carbajo AY, Garcia-Alonso FJ et al. A retrospective, multicenter analysis of incidents associated with Axios lumen-apposing stents. *Rev Esp Enferm Dig* 2019; 111: 419–424
- [14] Ghandour B, Bejjani M, Irani SS et al. Classification, outcomes, and management of misdeployed stents during EUS-guided gastroenterostomy. *Gastrointest Endosc* 2022; 95: 80–89
- [15] Ichkhanian Y, Runge T, Jovani M et al. Management of adverse events of EUS-directed transgastric ERCP procedure. *VideoGIE* 2020; 5: 260–263 doi:10.1016/j.vgie.2020.02.005
- [16] Garcia-Pagan JC, Gracia-Sancho J, Bosch J. Functional aspects on the pathophysiology of portal hypertension in cirrhosis. *J Hepatol* 2012; 57: 458–461 doi:10.1016/j.jhep.2012.03.007
- [17] Engelmann C, Claria J, Szabo G et al. Pathophysiology of decompensated cirrhosis: Portal hypertension, circulatory dysfunction, inflammation, metabolism and mitochondrial dysfunction. *J Hepatol* 2021; 75: S49–S66 doi:10.1016/j.jhep.2021.01.002
- [18] Wiest R, Lawson M, Geuking M. Pathological bacterial translocation in liver cirrhosis. *J Hepatol* 2014; 60: 197–209 doi:10.1016/j.jhep.2013.07.044
- [19] Runyon BA, Squier S, Borzio M. Translocation of gut bacteria in rats with cirrhosis to mesenteric lymph nodes partially explains the pathogenesis of spontaneous bacterial peritonitis. *J Hepatol* 1994; 21: 792–796 doi:10.1016/s0168-8278(94)80241-6
- [20] Laique S, Franco MC, Stevens T et al. Clinical outcomes of endoscopic management of pancreatic fluid collections in cirrhotics vs non-cirrhotics: A comparative study. *World J Gastrointest Endosc* 2019; 11: 403–412 doi:10.4253/wjge.v11.i6.403
- [21] James TW, Krafft M, Croglia M et al. EUS-guided gallbladder drainage in patients with cirrhosis: results of a multicenter retrospective study. *Endosc Int Open* 2019; 7: E1099–E1104
- [22] Parsa N, Nieto JM, Powers P et al. Endoscopic ultrasound-guided drainage of pancreatic walled-off necrosis using 20-mm versus 15-mm lumen-apposing metal stents: an international, multicenter, case-matched study. *Endoscopy* 2020; 52: 211–219 doi:10.1055/a-1096-3299
- [23] Runge TM, Chiang AL, Kowalski TE et al. Endoscopic ultrasound-directed transgastric ERCP (EDGE): a retrospective multicenter study. *Endoscopy* 2021; 53: 611–618 doi:10.1055/a-1254-3942
- [24] Ichkhanian Y, Yang J, James TW et al. EUS-directed transenteric ERCP in non-Roux-en-Y gastric bypass surgical anatomy patients (with video). *Gastrointest Endosc* 2020; 91: 1188–1194e2
- [25] Ghandour B, Shinn B, Dawod QM et al. EUS-directed transgastric interventions in Roux-En-Y gastric bypass anatomy: a multicenter experience. *Gastrointest Endosc* 2022; 96: 630–638 doi:10.1016/j.gie.2022.05.008
- [26] Walter D, Teoh AY, Itoi T et al. EUS-guided gall bladder drainage with a lumen-apposing metal stent: a prospective long-term evaluation. *Gut* 2016; 65: 6–8
- [27] Priyanka P, Hsueh W, Nasr J. Use of lumen-apposing stents for the treatment of postsurgical fluid collections: A case series and a review of literature. *Case Rep Gastrointest Med* 2019; 2019: 7656950 doi:10.1155/2019/7656950
- [28] Cotton PB, Eisen GM, Aabakken L et al. A lexicon for endoscopic adverse events: report of an ASGE workshop. *Gastrointest Endosc* 2010; 71: 446–454 doi:10.1016/j.gie.2009.10.027
- [29] Choi JH, Kozarek RA, Larsen MC et al. Effectiveness and safety of lumen-apposing metal stents in endoscopic interventions for off-label indications. *Dig Dis Sci* 2022; 67: 2327–2336 doi:10.1007/s10620-021-07270-1
- [30] Nass KJ, Zwager LW, van der Vlugt M et al. Novel classification for adverse events in GI endoscopy: the AGREE classification. *Gastrointest Endosc* 2022; 95: 1078–1085e8
- [31] Newman KL, Johnson KM, Cornia PB et al. Perioperative evaluation and management of patients with cirrhosis: risk assessment, surgical outcomes, and future directions. *Clin Gastroenterol Hepatol* 2020; 18: 2398–2414e3
- [32] Johnson KM, Newman KL, Green PK et al. Incidence and risk factors of postoperative mortality and morbidity after elective versus emergent abdominal surgery in a national sample of 8193 patients with cirrhosis. *Ann Surg* 2021; 274: e345–e354
- [33] Simon K, Orłowska I, Pazgan-Simon M. The risk of complications of endoscopic procedures in patients with liver cirrhosis. *Clin Exp Hepatol* 2017; 3: 135–140 doi:10.5114/ceh.2017.70284
- [34] Leal C, Prado V, Colan J et al. Adverse events and acute chronic liver failure in patients with cirrhosis undergoing endoscopic retrograde cholangiopancreatography: a multicenter matched-cohort study. *Am J Gastroenterol* 2019; 114: 89–97
- [35] James TW, Krafft M, Croglia M et al. EUS-guided gallbladder drainage in patients with cirrhosis: results of a multicenter retrospective study. *Endosc Int Open* 2019; 7: E1099–E1104