

Clinical and Surgical Evaluation of Sentinel Node Biopsy in Patients with Early-Stage Endometrial Cancer and Atypical Hyperplasia

Klinische und chirurgische Evaluation der Sentinel-Lymphknoten-Biopsie in Patientinnen mit Endometriumkarzinom im Frühstadium und atypischer Hyperplasie



Authors

Patrik Pöschke^{1,2}, Paul Gass^{1,2}, Annika Krückel¹, Katharina Keller¹, Ramona Erber^{2,3}, Arndt Hartmann^{2,3}, Matthias W. Beckmann^{1,2}, Julius Emons^{1,2}

Affiliations

- 1 Department of Gynecology and Obstetrics, Erlangen University Hospital, Comprehensive Cancer Center Erlangen-EMN (CCC ER-EMN), Friedrich Alexander University of Erlangen–Nuremberg, Erlangen, Germany
- 2 Bavarian Center for Cancer Research (BZKF), Erlangen, Germany
- 3 Institute of Pathology, Erlangen University Hospital, Comprehensive Cancer Center Erlangen-EMN (CCC ER-EMN), Friedrich Alexander University of Erlangen–Nuremberg (FAU), Erlangen, Germany

Keywords

atypical endometrial hyperplasia, endometrial cancer, sentinel node biopsy, indocyanine green, surgery

Schlüsselwörter

atypische Endometriumhyperplasie, Endometriumkarzinom, Sentinel-Lymphknoten-Biopsie, Indocyaningrün, chirurgischer Eingriff

received 29.1.2024

accepted after revision 20.3.2024

Bibliography

Geburtsh Frauenheilk 2024; 84: 470–476

DOI 10.1055/a-2293-5700

ISSN 0016-5751

© 2024. The Author(s).

This is an open access article published by Thieme under the terms of the Creative Commons Attribution-NonDerivative-NonCommercial-License, permitting copying and reproduction so long as the original work is given appropriate credit. Contents may not be used for commercial purposes, or adapted, remixed, transformed or built upon. (<https://creativecommons.org/licenses/by-nc-nd/4.0/>).

Georg Thieme Verlag KG, Rüdigerstraße 14,
70469 Stuttgart, Germany

Correspondence

Julius Emons, M.D.
Department of Gynecology and Obstetrics,
Erlangen University Hospital
Comprehensive Cancer Center Erlangen-EMN
(CCC ER-EMN), Friedrich Alexander University of
Erlangen–Nuremberg
Universitätsstraße 21–23
91054 Erlangen, Germany
julius.emons@uk-erlangen.de

ABSTRACT

Introduction

The medical and surgical treatment of endometrial cancer (EC) is evolving toward a more patient-centered and personalized approach. The role of laparoscopic sentinel node biopsy (SNB) for early-stage EC is unclear, and very few data are available for atypical endometrial hyperplasia (AEH). The present study investigated the effectiveness of SNB combined with laparoscopic hysterectomy in patients with early-stage EC and AEH.

Patients and Methods

This was a retrospective, single-center cohort study for the period from January 2018 to December 2023. A total of 102 patients with atypical hyperplasia (n = 20) and early-stage EC (n = 82) findings on diagnostic curettage underwent pelvic sentinel node biopsy during the final operation.

Results

Eleven patients (55%) who had initially been diagnosed with AEH were found to have EC in the final pathology report. No lymph node metastases were detected in patients who had initially been diagnosed with AEH; a 3.6% rate of positive SNBs was found in patients with EC. Changes in tumor grade occurred in 31.3% of the patients and changes in FIGO stage in 33%. Bilateral sentinel node (SN) mapping was successful in 94.1% of the patients. The postoperative out-

comes were comparable to those of routine clinical practice without SNB.

Conclusions

SNB can be safely offered to patients who have precursor lesions and early-stage EC without notably extending surgical times or increasing postoperative morbidity. This approach can be considered and is safe for patients diagnosed with AEH, but it appears to have a rather small impact on these patients.

ZUSAMMENFASSUNG

Einleitung

Die medizinisch-chirurgische Behandlung des Endometriumkarzinoms (EK) verändert sich hin zu einer mehr patientenorientierten und personalisierten Vorgehensweise. Die Rolle der laparoskopisch durchgeführten Sentinel-Lymphknoten-Biopsie (SNB) bei EK im Frühstadium ist noch unklar, und es gibt nur wenige Daten zur atypischen Endometriumhyperplasie (AEH). Die vorliegende Studie untersuchte die Effektivität von SNB in Kombination mit einer laparoskopischen Hysterektomie bei Patientinnen mit EK im Frühstadium und AEH.

Patientinnen und Methoden

Es handelt sich um eine retrospektive monozentrische Kohortenstudie, die zwischen Januar 2018 bis Dezember 2023

durchgeführt wurde. Insgesamt erhielten 102 Patientinnen mit dem Befund der atypischen Hyperplasie (n = 20) und EK im Frühstadium (n = 82) nach diagnostischer Abrasio während der endgültigen Operation eine Sentinel-Lymphknoten-Biopsie.

Ergebnisse

Bei 11 Patientinnen (55%), die ursprünglich mit AEH diagnostiziert wurden, wurde gemäß dem abschließenden Pathologiebericht ein EK identifiziert. Es wurden keine Lymphknotenmetastasen bei Patientinnen gefunden, deren ursprüngliche Diagnose AEH lautete; die Rate der positiven SNB bei Patientinnen mit EK betrug 3,6%. Bei 31,3% der Patientinnen kam es zu einer Veränderung des Tumorgrads und bei 33% zu einer Änderung des FIGO-Stadiums. Das bilaterale Sentinel-Lymphknoten-Mapping war bei 94,1% der Patientinnen erfolgreich. Die postoperativen Ergebnisse aller Patientinnen waren mit denen eines routinemäßigen chirurgischen Eingriffs ohne Durchführung einer SNB vergleichbar.

Schlussfolgerungen

Die SNB kann problemlos bei Patientinnen mit Vorläuferläsionen und EK im Frühstadium durchgeführt werden, ohne dass sich die Operationszeit wesentlich verlängert oder sich die postoperative Morbidität erhöht. Während diese Vorgehensweise für Patientinnen mit einer Diagnose von AEH als sicher betrachtet werden kann und ist, scheint sie nur geringe Auswirkungen auf diese Patientinnen zu haben.

Introduction

The publication of the Cancer Genome Atlas in 2013 marked a significant milestone in the understanding of cancer biology, particularly in the context of endometrial carcinoma [1]. This landmark study led to the establishment of novel molecular classifications, representing a paradigm shift from the traditional dualistic view of the disease [2]. Concurrently, there has been a notable trend toward reducing lymphadenectomy procedures, as evidenced in the German S3 Level guideline for endometrial cancer (EC) [3, 4].

The introduction of sentinel lymph node biopsy (SNB) for intermediate-risk EC has emerged as a pivotal technique for providing a comprehensive means of lymph node staging while mitigating the morbidities associated with systematic lymphadenectomy. This innovative approach represents a substantial stride toward personalized, patient-centered care. The FIRES trial reported a negative predictive value of 99.6% (97.9–100%) for patients diagnosed with EC who underwent pelvic SNB followed by pelvic lymphadenectomy, with or without paraaortic lymphadenectomy [5].

In the realm of advanced endometrial carcinoma, the advent of molecular classification systems has catalyzed the development of personalized immunotherapeutic modalities. These treatments, such as dostarlimab and pembrolizumab, offer promising prospects for patients with advanced-stage EC [6, 7, 8].

However, the role for SNB in the context of early-stage endometrial carcinoma (International Federation of Gynecology and Obstetrics [FIGO] Grade Ia [G] 1–2) in the absence of p53 mutations and for atypical endometrial hyperplasia is still not finally determined [9]. The German S3 Level guideline for EC, which was recently updated, recommends that a sentinel node biopsy can be performed, and this is also in line with international recommendations in which SNB can be considered in patients with low-risk or intermediate-risk disease [10, 11]. This is against the background of a 15% likelihood of lymph node metastases across all cancer disease stages – underscoring the clinical necessity for a more refined approach to lymph node evaluation [12]. Moreover, the final histology in patients initially found to have AEH reveals EC in up to 60% of cases [13]. Furthermore, 22% of patients initially classified as having FIGO I were found to have higher tumor stages postoperatively [14]. This highlights discrepancies between preoperative and postoperative staging.

Indocyanine green (ICG) has gained recognition as a reliable SNB mapping modality, and it is now included in clinical practice guidelines [3, 4]. Several studies have examined lymph node detection rates in patients with EC treated with ICG, reporting negative predictive values ranging from 99% to 99.5% [15, 16]. The results of the SENTI-ENDO trial led to the analysis of early-stage EC

patients in the trial, since EC patients with FIGO stages I and II were included. The authors found that SNB up-staged the final cancer stage in 10% of patients at low risk and in 15% of those at intermediate risk [17].

The present study aimed to address three major topics. Firstly, the diagnostic FIGO stage, determined using vaginal sonography and gynecologic examination, was correlated with the final pathologic stage. The frequency of final tumor stage upgrades and how often the tumor grade changes influence final therapy decisions. Secondly, the feasibility and efficacy of laparoscopic SNB for AEH was to be examined; and thirdly, the feasibility and efficacy of laparoscopic SNB for early-stage endometrial carcinoma was to be assessed. In addition, clinical outcome parameters were evaluated.

Materials and Methods

Patient cohort

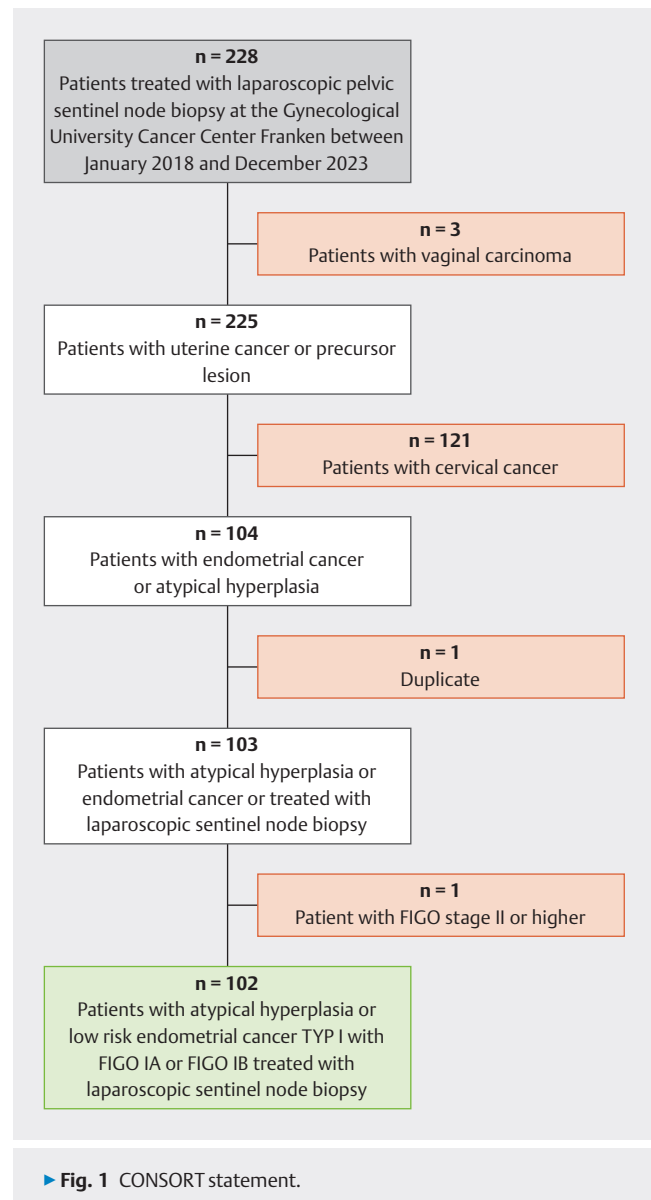
This retrospective, single-center cohort study included the period from January 2018 to December 2023. A total of 102 patients with AEH ($n = 20$) and early-stage EC ($n = 82$) according to diagnostic curettage were treated with laparoscopic pelvic sentinel node biopsy during the final operation. Patients with other malignant tumors, such as vaginal carcinoma or cervical cancer, and one duplicate dataset were excluded. In addition, only patients with early-stage FIGO Ia and Ib EC or AEH were included (► Fig. 1).

Vaginal ultrasonography and gynecological examination were used to define the FIGO stage for EC, and also for patients with AEH at the initial histology. Possible myometrial invasion is assessed using ultrasound. Hysteroscopy and curettage were performed in all patients to obtain pretherapeutic biopsies. All patients were treated in accordance with the German S3 Level guideline for EC, with hysterectomy and bilateral adnexectomy or salpingectomy if indicated in addition to SNB and, if indicated, with radical pelvic and paraaortic lymphadenectomy [3, 4]. The SNB procedures were performed with ICG, following the algorithm set out in the German guideline, with intracervical injection of ICG at two to four points [3, 4]. Systematic lymphadenectomy was not performed for patients with AEH if sentinel node mapping was not possible. This approach was reserved only for patients with EC who were found to have higher disease stages during surgery. The study was approved by the local ethics committee (ethical approval number: 252_20 B, first approval on June 29, 2020).

Collection of clinical and histopathological data

Clinical, histopathological, and follow-up data were prospectively documented as part of routine care at the University Gynecological Oncology Center in Erlangen. Data on tumor type, tumor grade, and molecular analysis, such as p53 mutation status, mismatch repair (MMR) protein status, and DNA sequencing for the POLE exonuclease domain, were obtained from the pathology files. The latest WHO classification for endometrial hyperplasia, published in 2014, was used [18]. The new (revised 2020) FIGO/TNM classification of EC was used to define tumor stage [19].

All surgical procedures were exclusively performed at the University Gynecological Oncology Center in Erlangen. SLB was con-



ducted following the protocols described in the German S3 Level guideline for endometrial cancer [3, 4].

Statistical analysis

Data management was facilitated using the Microsoft Access database. Descriptive analysis was conducted using IBM SPSS Statistics for Windows, Version 28.0 (IBM Corp., released 2021, Armonk, New York).

Results

The analysis included 102 patients with a mean age of 63 years who had been diagnosed with atypical endometrial hyperplasia or EC. Their mean body mass index (BMI) was 33. In the final pathologic staging, over 75% of the lesions were stage pT1a or pT1b, with 92.2% pN0. The predominant histological type was endometrioid adenocarcinoma, at 88.2%. The final grades resulting

from the hysterectomy were grade 1 in 37.2%, grade 2 in 46.1%, and only 7.8% in grade 3 (► **Table 1**).

Sentinel node biopsy for patients with atypical endometrial hyperplasia

As ► **Table 2** shows, no lymph node metastases were detected in the groups that were initially diagnosed with AEH. Bilateral SNL detection was also possible in all but one of the patients (95%).

Sentinel node biopsy for patients with endometrial cancer

Among the 82 patients diagnosed with EC at the initial curettage, three (3.6%) were found to have lymph node metastases. Bilateral lymph node mapping was possible in 77 patients (95.1%); only unilateral SNL detection was possible in one patient (1.2%); and SNL detection was not successful in four patients (► **Table 2**). Notably, these patients did not warrant systematic lymphadenectomy due to their presurgical FIGO stage. Among the three patients with lymph node metastases, the first and second underwent pelvic lymphadenectomy; the ascites cytology was positive, and adjuvant chemotherapy was therefore administered. In the third patient with a positive sentinel lymph node, a systematic pelvic and paraaortic lymphadenectomy was performed.

FIGO stage and tumor grade changes

A significant finding was that 11 of the 20 patients (55%) who had initially been diagnosed with AEH were found to have EC at the final pathology (► **Table 3**).

A change in the FIGO stage occurred in 31 patients (33.7%), aggregated over all stages. The diagnostic FIGO stage and final pathologic tumor stage differed for patients with FIGO stage Ia (n = 53): six patients (11.3%) were upgraded to pT1b, and four patients (7.5%) were upgraded to pT2 or higher. In patients with FIGO stage Ib disease (n = 39), the postsurgical tumor stage was

► **Table 1** Demographic and clinical characteristics.

Characteristic	All patients (n = 102)
Age (Mean)	63.38
BMI (Mean)	33.0
Final Pathological Stage (%)	
pT1a	54 (52.9)
pT1b	24 (23.5)
pT2	13 (12.7)
pT3a	2 (2.0)
Nodal status (%)	
pN0	94 (92.2)
pN1	3 (2.9)
pNx	4 (3.9)
Histology	
Atypical endometrial Hyperplasia	9 (8.8)
Endometrioid Adenocarcinoma	90 (88.2)
Uterine serous carcinoma	2 (2.0)
Adenosquamous endometrial cancer	1 (1.0)
Final Grading	
Grade 1	38 (37.3)
Grade 2	47 (46.1)
Grade 3	8 (7.8)

Abbreviations: BMI = Body Mass Index; FIGO = The International Federation of Gynecology and Obstetrics; n = number

► **Table 2** Sentinel node detection rates and metastases.

	Endometrial cancer (n = 82)	Atypical endometrial hyperplasia (n = 9)	Endometrial cancer (Atypical endometrial hyperplasia presurgery) (n = 11)
SNL detection	n (%)	n (%)	n (%)
Unilateral SNL detection	1 (1.2)	0	1 (9.1)
Bilateral SNL detection	77 (94.9)	9 (100)	10 (90.9)
Total detection rate	78 (95.1)	9 (100)	11 (100)
No SNL detection	4 (4.9)	0	0
Surgical Lymph node assessment			
SNL mapping only	76 (92.7)	9 (100%)	11 (100)
SNL mapping and PLD	6 (7.3)	0	0
Lymph node metastases	3	0	0

Abbreviations: n = number; PLD = Pelvic Lymphadenectomy; SNL = Sentinel lymph node

► **Table 3** Change of presurgical FIGO classification and postsurgical pathological classification for patients with endometrial cancer in final pathology.

	Number of patients (n = 93)
No FIGO stage available	1
FIGO IA	53
FIGO IA to pT1a	43
Change FIGO IA to pT1b	6
Change FIGO IA to pT2 or higher	4
FIGO IB	39
FIGO IB to pT1b	18
Change FIGO IB to pT1a	10
Change FIGO IB to pT2 or higher	11
Change of histological type (%)	
Atypical endometrial hyperplasia	20
No change	9 (45)
Change to endometrial cancer	11 (55)
Change of histological grade (%)	(n = 82)
No grading available in curettage	2
No change for G1	22 (58.9)
G1 to G2	14 (36.8)
G1 to G3	2 (5.2)
No change for G2	31 (77.5)
G2 to G1	6 (15)
G2 to G3	3 (7.5)
No change for G3	2
Abbreviations: FIGO = The International Federation of Gynecology and Obstetrics; G = grade; n = number	

downgraded to pT1a in 10 patients (25.6%) and upgraded to pT2 or higher in 11 patients (28.2%) (► **Table 3**).

Another important factor for therapy decisions is tumor grade. The grading was determined for the curettage and final pathology findings, and the results differed in 33.3% of the patients. In the group with grade 1 tumors, 12 of 38 patients (31.6%) had the tumor grade increased to grade 2, and two tumors (5.3%) were found to be grade 3 at the final histology. Most grade 2 tumors were confirmed as grade 2, in 31 patients (77.5%); they were downgraded to grade 1 in six patients (15%), and upgraded to grade 3 in three patients (7.5%) (► **Table 3**). Those of clinical significance were mostly changes from low-grade to high-grade, which occurred in five patients (6.2%).

Surgical outcomes

The duration of the operations ranged from 38 to 268 minutes, with a mean of 97.5 minutes. The mean duration of laparoscopic

► **Table 4** Postsurgical outcome.

	All patients (n = 102)
Time of surgery (minutes; min to max)	97.58 (38 to 268*)
Hospitalization (days, min to max)	4.38 (2 to 35)
Documented Lymphedema (n)	0
Mean total amount of drain fluid (ml)	312.63
Postsurgical antibiotic therapy (n)	7
Conversion to laparotomy (n)	8
Mean Pain Score (NRS 1 to 10)	2.52
Abbreviations: max = maximum; min = minimum; n = number; NRS = numeric rating scale * Surgery with conversion to open laparotomies for systematic lymphadenectomy is included	

operations alone was shorter, at 92.3 minutes. The patients' mean hospital stay was shorter with laparoscopic procedures (3.6 days) than for the overall procedure (4.4 days). Postoperative outcomes were documented, including the absence of lymphedema and typical ranges for drain fluid volume, pain scores, and antibiotic use (► **Table 4**). Eight patients underwent conversion from laparoscopic surgery to laparotomy. Conversion to laparotomy took place because the FIGO stage was higher than expected, the uterus was larger, vaginal constriction occurred, or the patient was overweight and had a positive SNB.

Discussion

The findings of this study contribute to understanding the management of early-stage endometrial carcinoma and atypical endometrial hyperplasia (AEH) in the context of pelvic sentinel node biopsy (SNB). The data show the efficacy and feasibility of this approach, particularly in relation to clinical outcome parameters such as surgical duration, drainage fluid, and hospitalization period. The conversion rate from AEH to EC in 55% of the patients is in line with findings in the literature of between 42.6% and 60% — emphasizing the clinical importance of close monitoring and aggressive management in AEH patients [13, 20].

One critical aspect of the study's findings is the discrepancy observed between the preoperative FIGO stage and the final pathological stage. The upgrades from FIGO stage Ia to pT1b and higher in a notable percentage of patients reflect the complexities of EC staging, as noted by Creasman et al. [14].

The 94.1% success rate in bilateral sentinel node mapping in the present study and the low complication rate are consistent with recent literature reports advocating the accuracy and safety of SNB in treating EC [15, 21]. These results further endorse the effectiveness of SNB in accurately staging early-stage EC, reducing the need for more invasive procedures and associated morbidities.

The integration of molecular profiling into EC management offers a promising avenue for enhancing the precision of staging

and personalizing treatment strategies [1]. This approach is especially relevant in a setting in which conventional staging may underestimate the severity of disease.

The emerging therapeutic options for treating EC — pembrolizumab with or without the combination of lenvatinib, or dostarlimab as monotherapy, or both immunotherapies in combination with standard chemotherapy — present promising treatment options, especially in patients with advanced-stage EC [6, 7, 22, 23]. These advances in targeted therapies and immunotherapies are indicative of a shift toward personalized medicine in oncology; precise lymph node staging is therefore crucial.

Nevertheless, none of the patients initially diagnosed with AEH had any lymph node metastases, a finding that is in line with recent literature reports. In the 2021 study by Sullivan and coworkers, for example, 141 patients with preinvasive endometrial lesions were diagnosed. Fifty-one patients (36%) had a final diagnosis of cancer, a rate that is slightly lower than the cancer rate of 56% in the present study; the majority of the patients (96%) had stage IA grade 1 endometrioid carcinomas. Among these patients, seven (5%) met the Mayo criteria of 2000 used for SNB and did not have any lymph node metastases [24, 25]. In the present cohort, none of the 20 patients with AEH met the criteria for SNB in accordance with recent guidelines, as all of the carcinomas were classified as pT1a grade 1, with one exception being pT1a grade 2 [3, 4]. Another study described multiple models estimating the risk for lymph node metastasis in patients with AEH and reported that the estimated risk of lymph node spread was 1.6–2.1% for all women with a preoperative diagnosis of AEH and 4.4–6.8% for the 55 women with EC included [26]. A recent meta-analysis of 1044 patients with AEH showed comparable unilateral and bilateral detection rates (89% and 79%) and a lymph node involvement rate of less than 2% — again underlining the view that SNB needs to be carefully indicated in patients with AEH [27].

In contrast, for low-risk EC, Convery and coworkers found lymph node metastases in 1.6% of patients with grade 1 or 2 endometrial carcinoma [28]. A post hoc analysis of the GOG LAP2 study also reported a 1% rate of lymph node metastases in 389 EC patients [29]. In both studies, low risk was assessed using the Mayo criteria: <50% myometrial invasion, tumor size <2 cm, and grade 1 or 2 [25, 29]. In the cohort described, 41 patients with pT1a grade 1 or 2 EC in the final pathology report did not have any lymph node metastases, but the indication for at least SNB depended on the molecular pathology in one patient who had a grade 3 tumor according to the final pathology findings.

Limitations

The retrospective nature and single-center design of the present study limit the extent to which its findings can be generalized. The absence of systematic lymphadenectomy in patients with unsuccessful SLN mapping might affect staging accuracy. In addition, only iliac sentinel nodes were detected and resected, and no sacral or paraaortic nodes, which represents a selection bias in comparison with literature. Potential selection bias might be present due to omission of AEHs that were not included in the study because a sentinel node biopsy was not performed. Furthermore, the number of patients with AEH in this trial was only 20, so that only

limited conclusions can be drawn. Future studies, particularly prospective and multicenter trials, are essential for further validation of the role of SNB in early EC.

Conclusion

Sentinel node biopsy (SNB) can be safely performed in patients with precursor lesions and early-stage EC without notably extending surgical times or increasing postoperative morbidity. It can be discussed as a safe method with patients diagnosed with AEH, but it appears to have a fairly small impact on these patients, and it seems to be safe for them not to undergo SNB. In addition, variations in presurgical grading and FIGO staging, in both directions, suggest the potential need for tailored treatment strategies.

Funding: This research received no external funding.

Informed Consent Statement: Informed consent was obtained from all the patients involved in the study.

Institutional Review Board Statement: The ethics committee of Erlangen University Hospital provided approval for the study (ref. number 252_20_B).

Data availability statement: The datasets are available from the corresponding author upon reasonable request.

Contributors' Statement

P.P. and J.E. made substantial contributions to the conception and design of the study, to the acquisition, analysis, and interpretation of data, and to the writing and critical revision of the manuscript. M.W.B., P.G., A.H., and R.E. were involved in suggestions for manuscript revision. P.P., P.G., J.E., K.K. and A.K. were involved in data acquisition (patient and tumor characteristics, histopathological assessment, and carrying out surgical procedures or systemic treatment). All of the authors have given final approval for the version to be published, have revised the manuscript critically, and have participated sufficiently in the research to take public responsibility for appropriate portions of the content. All of the authors have agreed to be accountable for all aspects of the work in ensuring that questions related to the accuracy or integrity of any part of the work are appropriately investigated and resolved. All authors have read and agreed to the published version of the manuscript.

Acknowledgement

We would also like to extend our gratitude to the patients who participated in the study. English editing was performed by Michael Robertson.

Conflict of Interest

J.E. reports personal fees from Eisai, Novartis, and Pfizer. P.G. has received honoraria from Novartis, MSD, and AstraZeneca. A.H. had an advisory role and received honoraria from BMS, MSD, Roche, Cepheid, Qiagen, Agilent, Diaceutics, Lilly, AstraZeneca, Boehringer Ingelheim, Abbvie, Jansen-Cilag, Pfizer, and Ipsen. R.E. has received honoraria from Roche, Eisai, Pfizer, BioNTech, VeracYTE (PROCURE), Diaceutics, and Novartis. The institution to which A.H. and R.E. are affiliated conducts research for AstraZeneca, Roche, Janssen-Cilag, NanoString Technologies, Biocartis, ZytoVision, Novartis, Cepheid, Mindpeak, and BioNTech. The authors declare no conflicts of interest.

References

- [1] Cancer Genome Atlas Research Network, Weinstein JN, Collisson EA, Mills GB et al. The Cancer Genome Atlas Pan-Cancer analysis project. *Nat Genet* 2013; 45: 1113–1120
- [2] Bokhman JV. Two pathogenetic types of endometrial carcinoma. *Gynecol Oncol* 1983; 15: 10–17. doi:10.1016/0090-8258(83)90111-7
- [3] Emons G, Steiner E, Vordermark D et al. Endometrial Cancer. Guideline of the DGGG, DKG and DKH (S3-Level, AWMF Registry Number 032/034-OL, September 2022) – Part 2 with Recommendations on the Therapy of Precancerous Lesions and Early-stage Endometrial Cancer, Surgical Therapy, Radiotherapy and Drug-based Therapy, Follow-up Care, Recurrence and Metastases, Psycho-oncological Care, Palliative Care, Patient Education, and Rehabilitative and Physiotherapeutic Care. *Geburtshilfe Frauenheilkd* 2023; 83: 963–995. doi:10.1055/a-2066-2068
- [4] Emons G, Steiner E, Vordermark D et al. Endometrial Cancer. Guideline of the DGGG, DKG and DKH (S3-Level, AWMF Registry Number 032/034-OL, September 2022). Part 1 with Recommendations on the Epidemiology, Screening, Diagnosis and Hereditary Factors of Endometrial Cancer, Geriatric Assessment and Supply Structures. *Geburtshilfe Frauenheilkd* 2023; 83: 919–962. doi:10.1055/a-2066-2051
- [5] Rossi EC, Kowalski LD, Scalici J et al. A comparison of sentinel lymph node biopsy to lymphadenectomy for endometrial cancer staging (FIRES trial): a multicentre, prospective, cohort study. *Lancet Oncol* 2017; 18: 384–392. doi:10.1016/S1470-2045(17)30068-2
- [6] Mirza MR, Chase DM, Slomovitz BM et al. Dostarlimab for Primary Advanced or Recurrent Endometrial Cancer. *N Engl J Med* 2023; 388: 2145–2158. doi:10.1056/NEJMoa2216334
- [7] Eskander RN, Sill MW, Beffa L et al. Pembrolizumab plus Chemotherapy in Advanced Endometrial Cancer. *N Engl J Med* 2023; 388: 2159–2170. doi:10.1056/NEJMoa2302312
- [8] Tempfer C, Brucker S, Juhasz-Boess I et al. Statement of the Uterus Commission of the Gynecological Oncology Working Group (AGO) on the Use of Primary Chemoimmunotherapy to Treat Patients with Locally Advanced or Recurrent Endometrial Cancer. *Geburtshilfe Frauenheilkd* 2023; 83: 1095–1101. doi:10.1055/a-2145-1545
- [9] Taran FA, Jung L, Waldschmidt J et al. Status of Sentinel Lymph Node Biopsy in Endometrial Cancer. *Geburtshilfe Frauenheilkd* 2021; 81: 562–573. doi:10.1055/a-1228-6189
- [10] Concin N, Matias-Guiu X, Vergote I et al. ESGO/ESTRO/ESP guidelines for the management of patients with endometrial carcinoma. *Int J Gynecol Cancer* 2021; 31: 12–39. doi:10.1136/ijgc-2020-002230
- [11] German Guideline Program in Oncology (German Cancer Society GCA, AWMF). Endometrial Cancer, Long version 2.0, 2022, AWMF Registration Number: 032/034-OL. . Accessed October 17, 2023 at: <https://www.leitlinienprogramm-onkologie.de/leitlinien/endometriumkarzinom/>
- [12] Sueoka K, Umayahara K, Abe A et al. Prognosis for endometrial cancer patients treated with systematic pelvic and para-aortic lymphadenectomy followed by platinum-based chemotherapy. *Int J Gynecol Cancer* 2015; 25: 81–86. doi:10.1097/IGC.0000000000000268
- [13] Antonsen SL, Ulrich L, Hogdall C. Patients with atypical hyperplasia of the endometrium should be treated in oncological centers. *Gynecol Oncol* 2012; 125: 124–128. doi:10.1016/j.ygyno.2011.12.436
- [14] Creasman WT, Morrow CP, Bundy BN et al. Surgical pathologic spread patterns of endometrial cancer. A Gynecologic Oncology Group Study. *Cancer* 1987; 60: 2035–2041. doi:10.1002/1097-0142(19901015)60:8+2035::aid-cnrcr28206015153.0.co:2-8
- [15] Cusimano MC, Vicus D, Pulman K et al. Assessment of Sentinel Lymph Node Biopsy vs Lymphadenectomy for Intermediate- and High-Grade Endometrial Cancer Staging. *JAMA Surg* 2021; 156: 157–164. doi:10.1001/jamasurg.2020.5060
- [16] Persson J, Salehi S, Bollino M et al. Pelvic Sentinel lymph node detection in High-Risk Endometrial Cancer (SHREC-trial)-the final step towards a paradigm shift in surgical staging. *Eur J Cancer* 2019; 116: 77–85. doi:10.1016/j.ejca.2019.04.025
- [17] Ballester M, Dubernard G, Lecuru F et al. Detection rate and diagnostic accuracy of sentinel-node biopsy in early stage endometrial cancer: a prospective multicentre study (SENTI-ENDO). *Lancet Oncol* 2011; 12: 469–476. doi:10.1016/S1470-2045(11)70070-5
- [18] Emons G, Beckmann MW, Schmidt D et al. New WHO Classification of Endometrial Hyperplasias. *Geburtshilfe Frauenheilkd* 2015; 75: 135–136. doi:10.1055/s-0034-1396256
- [19] Berek JS, Matias-Guiu X, Creutzberg C et al. FIGO staging of endometrial cancer: 2023. *Int J Gynaecol Obstet* 2023; 162: 383–394. doi:10.1002/ijgo.14923
- [20] Trimble CL, Kauderer J, Zaino R et al. Concurrent endometrial carcinoma in women with a biopsy diagnosis of atypical endometrial hyperplasia: a Gynecologic Oncology Group study. *Cancer* 2006; 106: 812–819. doi:10.1002/cncr.21650
- [21] Persson J, Salehi S, Bollino M et al. Pelvic Sentinel lymph node detection in High-Risk Endometrial Cancer (SHREC-trial)-the final step towards a paradigm shift in surgical staging. *Eur J Cancer* 2019; 116: 77–85. doi:10.1016/j.ejca.2019.04.025
- [22] Colombo N, Dubot C, Lorusso D et al. Pembrolizumab for Persistent, Recurrent, or Metastatic Cervical Cancer. *N Engl J Med* 2021; 385: 1856–1867. doi:10.1056/NEJMoa2112435
- [23] Mirza MR, Chase DM, Slomovitz BM et al. Dostarlimab for Primary Advanced or Recurrent Endometrial Cancer. *N Engl J Med* 2023; 388: 2145–2158. doi:10.1056/NEJMoa2216334
- [24] Sullivan MW, Philp L, Kanbergs AN et al. Lymph node assessment at the time of hysterectomy has limited clinical utility for patients with pre-cancerous endometrial lesions. *Gynecol Oncol* 2021; 162: 613–618. doi:10.1016/j.ygyno.2021.07.004
- [25] Mariani A, Webb MJ, Keeney GL et al. Low-risk corpus cancer: is lymphadenectomy or radiotherapy necessary? *Am J Obstet Gynecol* 2000; 182: 1506–1519. doi:10.1067/mob.2000.107335
- [26] Costales AB, Schmeler KM, Broaddus R et al. Clinically significant endometrial cancer risk following a diagnosis of complex atypical hyperplasia. *Gynecol Oncol* 2014; 135: 451–454. doi:10.1016/j.ygyno.2014.10.008
- [27] Vieira-Serna S, Peralta J, Viveros-Carreño D et al. Sentinel lymph node assessment in patients with atypical endometrial hyperplasia: a systematic review and meta-analysis. *Int J Gynecol Cancer* 2023. doi:10.1136/ijgc-2023-004936
- [28] Convery PA, Cantrell LA, Di Santo N et al. Retrospective review of an intraoperative algorithm to predict lymph node metastasis in low-grade endometrial adenocarcinoma. *Gynecol Oncol* 2011; 123: 65–70. doi:10.1016/j.ygyno.2011.06.025
- [29] Milam M, Java J, Walker J et al. Incidence of nodal metastasis in endometrioid endometrial cancer risk groups: A Gynecologic Oncology Group multicenter review. *Gynecol Oncol* 2011; 121: S4