

# Quantification of interstitial cells of Cajal and fibrosis during gastric per-oral endoscopic myotomy and its association with clinical outcomes

OPEN  
ACCESS

## Authors

Dennis Yang<sup>1</sup>, Muhammad Khalid Hasan<sup>1</sup>, BahaAldeen Bani Fawwaz<sup>2</sup>, Aimen Farooq<sup>3,1</sup>, Yiyang Zhang<sup>4</sup>, Hafiz M Khan<sup>5</sup>, Tony S Brar<sup>1</sup>, Sanmeet Singh<sup>2</sup>, Artur Viana<sup>2</sup>, Gurdeep Singh<sup>6</sup>, Kambiz Kadkhodayan<sup>1</sup>, Mustafa A Arain<sup>1</sup>, Natalie Cosgrove<sup>1</sup>, Deepanshu Jain<sup>1</sup>, Irteza Inayat<sup>2</sup>, Charanjeet Singh<sup>7</sup>

## Institutions

- 1 Center for Interventional Endoscopy, AdventHealth Orlando, Orlando, United States
- 2 Gastroenterology, AdventHealth Central Florida, Orlando, United States
- 3 Internal Medicine, AdventHealth Central Florida, Orlando, United States
- 4 Statistics, AdventHealth Central Florida, Orlando, United States
- 5 Gastroenterology and Hepatology, Staten Island University Hospital, Staten Island, United States
- 6 Medicine, AdventHealth Central Florida, Orlando, United States
- 7 Pathology, AdventHealth Central Florida, Orlando, United States

## Keywords

POEM, Endoscopy Upper GI Tract, Motility / achalasia, GI Pathology

received 3.1.2024

accepted after revision 4.3.2024

accepted manuscript online 18.3.2024

## Bibliography

Endosc Int Open 2024; 12: E585–E592

DOI 10.1055/a-2290-0502

ISSN 2364-3722

© 2024. The Author(s).

This is an open access article published by Thieme under the terms of the Creative Commons Attribution-NonDerivative-NonCommercial License, permitting copying and reproduction so long as the original work is given appropriate credit. Contents may not be used for commercial purposes, or adapted, remixed, transformed or built upon. (<https://creativecommons.org/licenses/by-nc-nd/4.0/>)

Georg Thieme Verlag KG, Rüdigerstraße 14,  
70469 Stuttgart, Germany

## Corresponding author

Dennis Yang, MD, AdventHealth Orlando – Center for Interventional Endoscopy, 601 E Rollins Street, Orlando, FL

32803-1489, United States

[dennis.yang.md@adventhealth.com](mailto:dennis.yang.md@adventhealth.com)

## ABSTRACT

**Background and study aims** Alterations to interstitial cells of Cajal (ICC) and collagen fibrosis have been implicated in the pathogenesis of gastroparesis. We aimed to evaluate the feasibility and safety of pyloric muscle sampling during gastric peroral endoscopic myotomy (G-POEM) and the association between pyloric ICC density and degree of fibrosis with clinical outcomes.

**Patients and methods** This was a single-center prospective study of gastroparetic patients who underwent G-POEM and intraprocedural pyloric muscle biopsies between January 2022 and April 2023. ICC count was estimated using CD117 stain and trichome for collagen fibrosis. Clinical response to G-POEM was defined as an improvement of  $\geq 1$  point on the Gastroparesis Cardinal Symptom Index.

**Results** Fifty-six patients (median age 60 years, 71.4% women) underwent G-POEM (100% technical success; 71.4% clinical response). ICC depletion ( $< 10$ /high-power field) and fibrosis were encountered in 70.4% and 75% of the cases, respectively. There was no difference in mean ICC count between G-POEM responders vs. non-responders ( $7 \pm 3.6$  vs.  $7.7 \pm 3.3$ ;  $P = 0.9$ ). There was no association between ICC density or degree of fibrosis with the etiology of gastroparesis, duration of symptoms, gastric emptying rate, or pyloric impedance planimetry. Patients who did not respond to G-POEM had a significantly higher degree of moderate/severe fibrosis when compared with those who responded (81.3% vs. 25%;  $P = 0.0002$ ).

**Conclusions** Pyloric muscle biopsies during G-POEM was feasible and safe. ICC depletion and pyloric muscle fibrosis are common in gastroparetic patients. The degree of fibrosis may be related to pyloric dysfunction and clinical response to G-POEM. Additional studies are needed to confirm these results.

## Introduction

Gastroparesis is a condition characterized by delayed gastric emptying in the absence of mechanical obstruction in the context of symptoms. Patients often report chronic disabling symptoms, including nausea, vomiting, early satiety, bloating, abdominal pain, and weight loss, which often translate into recurrent hospital visits and result in a significant burden to the health care system [1,2,3]. Importantly, many patients have medically refractory gastroparesis, defined as persistent symptoms despite dietary modifications and prokinetics as first-line therapeutic agents [4].

Gastric per-oral endoscopic pyloromyotomy (G-POEM) has recently emerged as a potential therapy for patients with medically refractory gastroparesis [1]. Yet, clinical response to G-POEM remains quite variable and no clear predictors of treatment success have been identified [5,6,7]. One of the main limitations in development of highly effective treatment strategies lies in the lack of a clear understanding of the underlying pathophysiology of this disease. Nonetheless, new advances, including introduction of functional luminal impedance planimetry (FLIP), have shown promise in our evaluation of pylorospasm and clinical response to G-POEM [8].

Interstitial cells of Cajal (ICC) act as a physiological pacemaker by generating a slow-wave electrical rhythm that mediates motor contractions leading to normal gastric emptying [3,4,9,10]. It has been hypothesized that slow-wave electric activity in gastroparesis is impaired due to altered or damaged ICC [10,11,12,13,14]. A previous study by Morajevi et al demonstrated alteration in ICC density and degree of fibrosis in the pylorus in surgical biopsy specimens of gastroparetic patients [15]. As opposed to surgery, G-POEM offers a less invasive approach for direct tissue acquisition at the time of the procedure. A prior single-center retrospective study of 21 patients indicated that gastric muscle biopsy during G-POEM for histological assessment was safe [16].

The aim of this single-center prospective study was to: 1) confirm the feasibility and safety of pyloric muscle sampling during G-POEM; 2) quantify ICC density and the degree of fibrosis in the pylorus; and 3) correlate histological findings with clinical outcomes.

## Patients and methods

### Study design and population

This was a single-center prospective trial (NCT05905016) of consecutive patients  $\geq 18$  years of age who underwent G-POEM and intraprocedural pyloric muscle biopsies between January 2022 and March 2023. Prior to G-POEM, clinical assessment, baseline gastroparesis cardinal symptom index (GCSI) score [17], and gastric emptying scan (GES), were performed. Patients who met the following inclusion criteria were prospectively enrolled in the study: 1) gastroparesis refractory to standard therapy (including diet, lifestyle modification and prokinetics); and 2) gastroparesis diagnosis established by a 4-hour solid-phase GES. Abnormal GES was defined as  $> 10\%$  meal retention at 4 hours [18]. Patients were excluded if they met any of

the following criteria: 1) on chronic opiate medications; 2) upper gastrointestinal surgeries involving the pylorus, including prior surgical or laparoscopic pyloromyotomy; 3) current or history of gastroesophageal malignancy; 4) pregnancy; 5) any contraindication to endoscopy; and/or 6) unable to provide informed consent. The study was approved by the Institutional Review Board for Human Research at AdventHealth, Orlando, Florida, United States. Signed procedure and research informed consent was obtained from all patients. All authors had access to the study data and reviewed and approved the final manuscript.

### Data collection

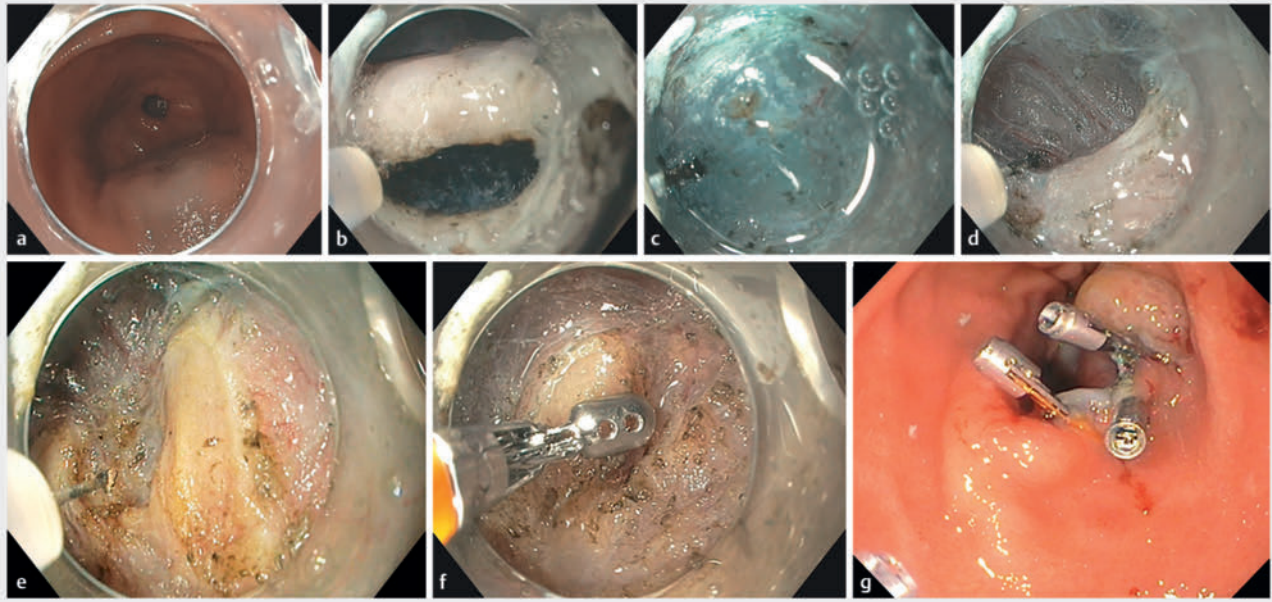
The data were prospectively recorded and entered into a central electronic database specifically created for the purpose of the study. Data on patient demographics, gastroparesis (etiology, duration of symptoms, GCSI, prior interventions), and GES were collected. Procedure data included pyloric endoscopic FLIP, length of pyloromyotomy, procedure time, technical success of G-POEM, pyloric muscle biopsies, and adverse events (AEs). Post-procedure data (i.e. histology, GCSI, pyloric FLIP) were also recorded at the time of follow-up.

### G-POEM procedure

All patients underwent endoscopy under propofol sedation and carbon dioxide insufflation. Pyloric FLIP (models EF-100 and EndoFLIP 2.0, balloon catheter EF-325N, Medtronic, Minneapolis, Minnesota, United States) was performed immediately before and after the procedure (during the same endoscopy session with G-POEM) as previously described in the literature [8,19]. The following FLIP measurements were obtained at a volumetric distension of 40 mL: intraballoon pressure, pylorus diameter, cross-sectional area (CSA), and distensibility index (DI) [8,19].

All G-POEM procedures were performed by two providers (DY and MKH) with experience in submucosal endoscopy. The procedures were performed as previously described in the literature [20,21,22,23]. In brief, all cases were under general anesthesia with the patient in left lateral decubitus position. Patients received 3.75 g piperacillin/tazobactam or 500 mg ciprofloxacin shortly before the procedure. A standard gastroscope (GIF-H190; Olympus, Tokyo, Japan) with a clear distal attachment cap (MH 588; Olympus America, Center Valley, Pennsylvania, United States) was used for all procedures.

A submucosal injection of 6% hetastarch admixed with methylene blue was performed approximately 5 cm proximal from the pylorus on the greater curvature. Following the submucosal lift, a 1.5- to 2.5-cm transverse mucosal incision was made (Endocut Q, effect 3, cut duration 2, cut interval 1) (ERBE, Marietta, Georgia, United States) with a high-pressure needle-free electrosurgical knife (Hybrid I-type knife, ERBE, Marietta, Georgia, USA). Submucosal dissection was then performed with the electrosurgical knife (Endocut Q and forced coagulation, effect 2, maximum 50 W) and repeated submucosal injections until the pyloric ring was exposed. Pyloromyotomy using an insulated tip knife (IT-2 knife, Olympus America, Center Valley, Pennsylvania, United States) was then performed by starting at the pylorus ring from the most distal aspect of the pylorus to prox-



► **Fig. 1** Gastric per-oral endoscopic pyloromyotomy (G-POEM) with pyloric muscle biopsies. **a** Transverse mucosal incision was made proximal to the pylorus **b** followed by submucosal tunneling **c** until the pyloric ring was visualized. **d** After completion of pyloromyotomy, **e** pyloric muscle biopsies were obtained with cold biopsy forceps **f** followed by mucosal incision closure with endoscopic clips.

imal and extended approximately 2 cm toward the antrum. Finally, the mucosal incision was closed using either the through-the-scope (TTS) suturing system (X-tack Endoscopic Helix Tacking System; Boston Scientific, Marlborough, Massachusetts, United States), or the dual action tissue clip (Micro-Tech Endoscopy, USA, Ann Arbor, Michigan, United States) in conjunction with conventional TTS clips [21, 22].

### Intraprocedural pyloric muscle biopsy and histologic evaluation

After completion of the myotomy and prior to mucosal closure of the submucosal tunnel, biopsies of the pylorus were obtained with a large-capacity forceps (M00513313; Boston Scientific, Marlborough, Massachusetts, United States) (► **Fig. 1**, ► **Video 1**). A total of two to three biopsies were performed with tissue acquisition visually confirmed by the presence of gross specimens in the formalin container. The pyloric muscle biopsies were fixed in 10% formaldehyde, embedded in paraffin and processed for routine hematoxylin and eosin (H&E) stains, Masson's trichrome stain, and CD117 immunoperoxidase stain [15]. Any biopsy with at least one fragment of muscularis propria was deemed adequate for microscopic evaluation. Intracytoplasmic inclusions were evaluated on H&E-stained slides. The ICC density was estimated using CD117 stain - for evaluation 200 x (with 20 x objective) was deemed a single high-power field, and the highest density was reported (► **Fig. 2**). Trichrome stain was utilized to evaluate the extent of fibrosis (► **Fig. 2**).

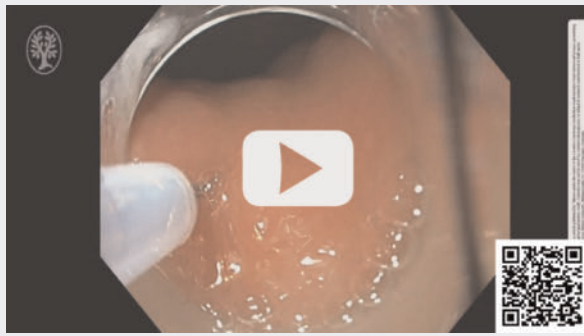### Study endpoints and definitions

Technical success was defined as successful completion of the G-POEM procedure. In concordance with G-POEM literature, clinical response was defined as an improvement of  $\geq 1$  point on GCSI after G-POEM [24]. Adequacy of pyloric muscle biopsies was defined by the proportion of cases in which the biopsies yielded at least one fragment of muscularis propria sufficient for microscopic evaluation. Tissues without any smooth muscle and only fibrovascular or adipose tissue were deemed non-diagnostic. For quantification of ICC, only cells with both an identifiable nuclei and wavy cytoplasmic process were counted using CD117 stain. Depletion of ICC was defined as  $< 10/\text{HPF}$ . This cut-off was based on prior studies comparing ICC density between control and gastroparetic patients and its association with gastric emptying rate [12, 15]. Fibrosis was deemed as mild or minimal (grade 1) if there was no expansion of the space between two bundles of smooth muscle, and if there was no fibrosis within a bundle. Cases with either expanded interstitial space between the bundles and/or fibrosis within a bundle but without destruction of smooth muscle were deemed as moderate (grade 2). Any fibrosis associated with loss of tissue architecture and destruction of smooth muscle bundles was deemed as marked or severe (grade 3). AEs were graded according to a standardized AE classification system for gastrointestinal endoscopy [25].

### Statistical analysis

Descriptive statistics for each baseline variable were obtained and expressed as mean, standard deviation (SD), median and interquartile ranges (IQR). Chi-square or Fisher exact test for

## VIDEO



► **Video 1** Gastric per-oral endoscopic pyloromyotomy (G-POEM) with intraprocedural pyloric muscle biopsies.

categorical variables and the *t* test for continuous variables were performed when indicated. Nominal *P* values are reported; *P* < 0.05 was considered significant. All statistical analysis was performed with the open-source statistical software package R (version 3.5.0).

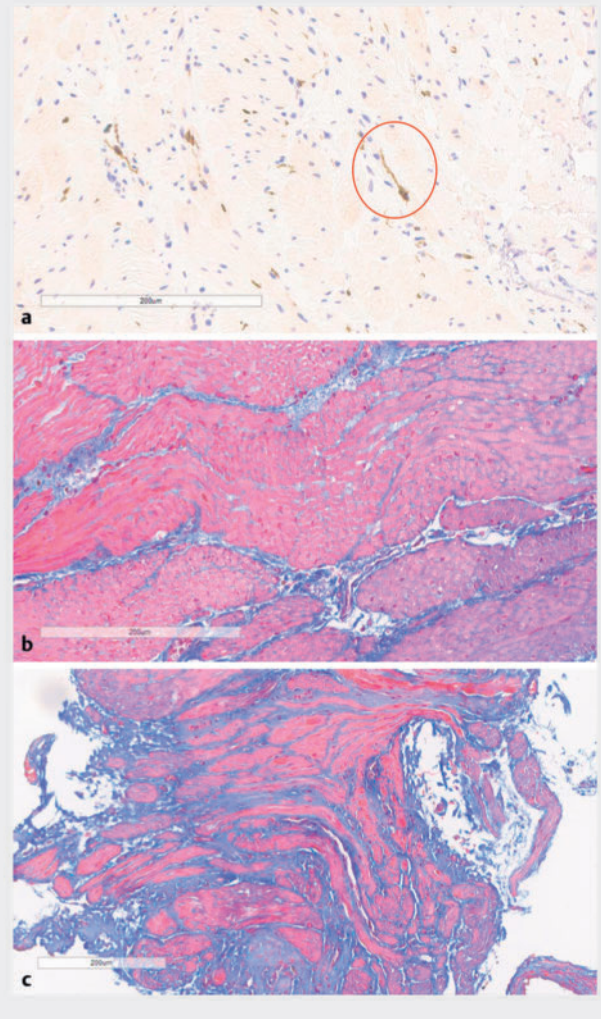
## Results

Fifty-six patients (median age 60 years; 71.4% women) underwent G-POEM between January 2022 and March 2023 for diabetic (*n* = 18), idiopathic (*n* = 17), and postsurgical (*n* = 21) medically refractory gastroparesis (► **Table 1**). Nearly half the patients had prior treatment with botulinum toxin injections to the pylorus (*n* = 25; 44.6%). Mean 4-hour retention percentages on GES and baseline GCSI were  $46.6 \pm 24.2\%$  and  $3.3 \pm 1.2$ , respectively.

The G-POEM technical success rate was 100%. Mean pyloromyotomy length was  $2.3 \pm 0.9$  cm and total procedure time was  $43.1 \pm 17.3$  minutes (► **Table 1**). There was one AE (1.8%). In that patient, a mucosotomy was identified after completion of the pyloromyotomy. This was adequately closed on the mucosal side with placement of two hemostatic clips. Upper gastrointestinal series did not reveal contrast extravasation on postoperative day (POD) #1 and the patient was discharged with full recovery on POD #3.

## Pyloric muscle tissue acquisition and histology findings

Direct biopsies of the pyloric muscle during G-POEM were performed with visual confirmation of a retrieved specimen in all cases. Of these, 54 (96.4%) were deemed adequate for histological ICC quantification and 52 (92.9%) for grading of fibrosis. In two cases, the smooth muscle specimens were fragmented and cauterized, which impeded assessment for CD117 positivity. In the other cases, the specimens were insufficient for histologic evaluation. The mean ICC count was  $7.3 \pm 3.5$ /HPF. The ICC count was found to be depleted (< 10/HPF) in 70.4% of patients (*n* = 38) who underwent G-POEM. There was no fibrosis identified in 13 specimens (25%), whereas the remaining were



► **Fig. 2** a Pyloric interstitial cells of Cajal (ICC) (circled) on CD117 immunostain ( $\times 200$ ). b Mild (grade 1) fibrosis c and severe (grade 3) detected by Trichrome (blue color) staining ( $\times 40$ ).

categorized as mild (*n* = 17; 32.7%), moderate (*n* = 18; 34.6%), and severe (*n* = 4; 7.7%).

► **Table 2** compares baseline characteristics between patients with low ICC count (< 10/HPF) vs. high ICC count ( $\geq 10$ /HPF) and those with minimal degree of fibrosis (none/mild) vs high degree of fibrosis (moderate/severe). In all, there were no significant differences in patient demographics (age, sex, etiology of gastroparesis), severity of disease (duration of symptoms, GCSI and GES), proportion of patients who underwent botulinum toxin injection prior to G-POEM, or pylorus FLIP parameters among the different groups.

## Clinical response and correlation with histopathology

Short-term clinical success (up to 12-month follow-up), defined by an average reduction of 1 point in GCSI, was observed in 71.4% of patients (*n* = 40), with mean GCSI decreasing from a baseline of  $3.3 \pm 1.1$  to  $1.5 \pm 1.2$  (*P* < 0.001). Baseline character-

► **Table 1** Baseline and procedure characteristics.

Baseline characteristics	All (n = 56)
Median age (IQR); years	60 (48–68.5)
Female; n (%)	40 (71.4)
Median duration of symptoms (IQR); months	24 (12–36)
Etiology of gastroparesis; n (%)	
▪ Diabetes mellitus	18 (32.1)
▪ Post-surgical	21 (37.5)
▪ Idiopathic	17 (30.4)
Psychiatric comorbidities; n (%)	
▪ Depression	25 (44.6)
▪ Anxiety	22 (39.3)
History of pyloric botulinum toxin injections; n (%)	25 (44.6)
Mean 4-hour retention percentage on GES emptying scan, (SD)	46 (24.2)
Mean baseline GCSI, (SD)	3.3 (1.2)
Baseline FLIP measurements at 40 mL distension, mean (SD)	
▪ Diameter, mm	14.0 (2.1)
▪ Pylorus CSA (mm <sup>2</sup> )	24.5 (19.5)
▪ Bag pressure (mm Hg)	175 (80)
▪ Distensibility index (mm <sup>2</sup> /Hg)	7.8 (3.8)
<b>Procedure characteristics</b>	
Length, mean (SD), cm	
▪ Mucosal Incision	2.1 (0.4)
▪ Submucosal tunnel	4.5 (0.7)
▪ Pyloromyotomy	2.3 (0.9)
Total procedure time, mean (SD)	43.1 (17.3)
Adverse events, n (%)	
▪ Post-procedure bleeding	0
▪ Mucosotomy	1 (1.8)
▪ Other	0
IQR, interquartile range; GES, gastric emptying scan; GCSI, gastroparesis cardinal symptom index; SD, standard deviation; FLIP, functional luminal impedance planimetry; CSA, cross-sectional area.	

istics between G-POEM responders vs non-responders are shown in the supplementary material (Supplement 1). Overall, there were no significant differences in patient demographics (age, sex, etiology of gastroparesis), disease severity (duration of symptoms, GCSI, GES), procedure characteristics (length of pyloromyotomy, procedure time), or post-procedure FLIP between the two groups.

Mean ICC count was similar between G-POEM responders ( $7 \pm 3.6$ ) and non-responders ( $7.7 \pm 3.3$ ) ( $P = 0.90$ ). ICC depletion

trended higher among patients who did not respond to G-POEM as opposed to the responder group (80% vs. 63.9%) but this was not statistically significant ( $P = 0.33$ ) (► **Fig. 3**). There was a significantly higher proportion of patients with no fibrosis on pyloric muscle biopsy among G-POEM responders vs non-responders (33.3% vs 6.3%;  $P = 0.04$ ). Conversely, there were no patients with severe fibrosis in the G-POEM responders group as opposed to four patients (25%) in the non-responder group ( $P = 0.007$ ). In all, there was a significantly higher rate of moderate/severe fibrosis among patients who did not respond to G-POEM as opposed to those who did respond (81.3% vs 25%;  $P = 0.0002$ ).

## Discussion

The pathophysiology of gastroparesis, a condition characterized by symptomatic delayed gastric emptying, remains poorly understood. ICC are involved in the neural signaling that mediates motor contractions during gastric emptying [14]. In this prospective study, pyloric muscle biopsies for histological analysis were obtained from all consecutive patients with medically refractory gastroparesis referred for G-POEM. We demonstrated that pyloric smooth muscle biopsy during G-POEM was feasible and safe. ICC depletion was frequently identified among all patients with gastroparesis, whereas moderate to severe pyloric muscle fibrosis was more commonly identified among patients who did respond to G-POEM.

ICC play an important role in the pathogenesis of gastroparesis [12, 14]. Previous studies have shown that ICC are depleted in the gastric body and antrum of gastroparetic patients [12, 15, 16]. Loss of ICC has also been implicated in abnormal regulation of pyloric relaxation and potentially affects gastric emptying [14]. In our study, pyloric ICC were depleted in 70.4% of gastroparetic patients who underwent G-POEM. Notably, this finding is identical to the ICC depletion (70.5%) reported from a prior study on surgical full-thickness pyloric smooth muscle specimens of patients with gastroparesis [15]. Hence, our results suggest that pyloric smooth muscle biopsy during G-POEM is a minimally invasive alternative with high correlation to surgical tissue acquisition and supports the notion that pyloric ICC are depleted in these patients [15, 16]. Animal studies have suggested that the rate of gastric emptying may depend on the levels of ICC [26, 27]. However, similar to a prior report [15], we did not identify an association between pyloric ICC counts and gastric emptying rate.

Furthermore, patient characteristics, etiology of gastroparesis, duration of symptoms, pyloric compliance based on FLIP, and clinical response to G-POEM did not correlate with levels of pyloric ICC on histology. Our findings are in contrast with a study by Shah et al, which reported lower average ICC (per 4 mm<sup>2</sup>) in G-POEM non-responders as compared with responders [16]. However, besides the retrospective nature and small number of patients (21 patients; only four in the G-POEM non-responder group), the authors included ICC counts from both antral and pyloric specimens, which limits the interpretability of the results as ICC density varies significantly based on location [9, 10, 15]. Hence, further investigation of the exact role of py-

**Table 2** Comparison of patients with pyloric ICC < 10/HPF vs  $\geq$  10/HPF and no/mild fibrosis vs. moderate/severe fibrosis.

Variable	ICC < 10/HPF (n = 38)	ICC $\geq$ 10/HPF (n = 16)	P value	Mild fibrosis (n = 30)	Moderate/severe fibrosis (n = 22)	P value
Age, median (IQR); years	64 (44.5–69)	57 (48.5–65.3)	0.92	58.5 (49–68.3)	65 (45–69)	0.91
Female; n (%)	25 (62.5)	14 (87.5)	0.18	23	14	0.36
Etiology of gastroparesis; n (%)						
▪ Diabetes	11	6	13	5	5	0.15
▪ Postsurgical	18	3	12	10	10	0.78
▪ Idiopathic	9	7	15	7	7	0.26
Duration of symptoms, median (IQR); months	24 (12–54)	23 (16.3–24)	0.16	24 (10.5–60)	20 (12–33)	0.18
Botulinum toxin injections; n (%)	16	8	0.77	13	10	1.00
4-hour retention percentage on GES, mean (SD), %	48.2 (21.8)	44 (28.1)	0.56	44.1 (24.1)	47.6 (24.4)	0.60
Baseline GCSI, mean (SD)	3.3 (1.2)	3.3 (1.2)	1.00	3.4 (1.3)	3.1 (1.2)	0.40
Baseline pylorus FLIP, mean (SD)						
▪ Pylorus CSA (mm <sup>2</sup> )	178.6 (68.5)	168 (98)	0.65	164.7 (57.9)	193.5 (104.6)	0.71
▪ Distensibility index (mm <sup>2</sup> /Hg)	8.3 (3.5)	6.9 (4.3)	0.22	8.0 (3.5)	7.9 (4.3)	0.44

ICC, interstitial cells of Cajal; IQR, interquartile range; GES, gastric emptying scan; GCSI, gastroparesis cardinal symptom index; FLIP, functional luminal impedance planimetry; CSA, cross-sectional area.

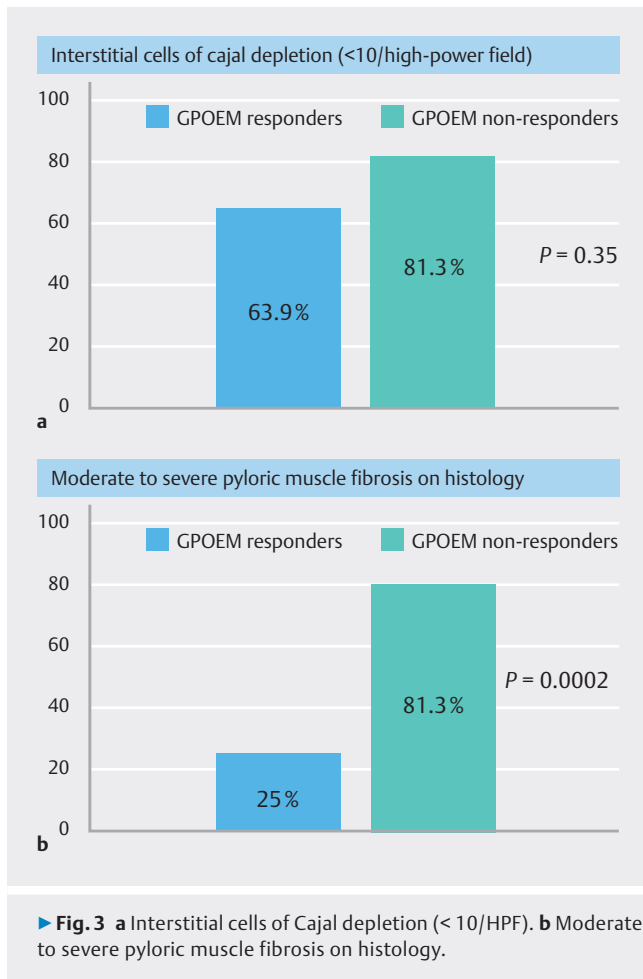
pyloric ICC in the pathogenesis and clinical manifestations of patients with gastroparesis is still needed.

Our study demonstrated that most patients with gastroparesis had diffuse collagen fibrosis (75%) in the pylorus. This finding is consistent with the degree of fibrosis (82%) identified on a prior study evaluating full-thickness pyloric muscle surgical specimens in gastroparesis [15]. The more prominent fibrosis in the pylorus as compared with in the antrum or body of the stomach in patients with gastroparesis has been implicated as a potential contributor to pyloric dysfunction [14, 15]. Interestingly, we identified significant variability in the degree of fibrosis between patients who had a clinical response to G-POEM versus those who did not. For one, approximately one-third of patients who responded to G-POEM (33.3%) had no pyloric fibrosis as compared with only one patient (6.3%) in the non-responder group ( $P = 0.04$ ). Even among patients with fibrosis, the degree of moderate to severe fibrosis was significantly more prevalent among G-POEM non-responders vs responders (81.3% vs 25%;  $P = 0.0002$ ). Interestingly, pyloric compliance, based on CSA and DI on FLIP, was not different between patients with no to mild fibrosis vs. those with moderate to severe fibrosis. Additional studies are needed to further elucidate the mechanism by which fibrosis may contribute to pyloric dysfunction and impact treatment response to pylorus-directed therapies such as G-POEM.

There are several strengths to our study. For one, this is the largest prospective study evaluating histological changes at the pylorus in patients with gastroparesis. We demonstrated that

pyloric smooth muscle biopsy during G-POEM was highly feasible and safe, with adequate tissue acquisition for histological analysis obtained in > 93% of the cases and no AEs reported. Second, our histological findings correlated closely with previous reports using full-thickness surgical specimens, further supporting the efficacy of submucosal endoscopy as a viable path for direct biopsy and augmenting the external validity of our observations. Last, we were able to correlate histological findings with clinical response to G-POEM, thereby providing additional data regarding pyloric dysfunction in patients with gastroparesis.

Our study is not without limitations. First, the criterion for clinical success used in this study was an improvement  $\geq$  1 point on the GCSI, which was based on some prior studies. However, there is currently no consensus definition for clinical success and a more stringent criterion may have affected our results. Second, we also acknowledge that most of our patients have only been followed between 3 and 12 months; therefore, long-term data are lacking. There are currently no data on the association between ICC density and fibrosis at the pylorus on histology and clinical response to G-POEM. As such, no formal sample size calculation was derived for this study, which should be taken into consideration when interpreting our results. Third, we also recognize that while this represents the largest study assessing histological changes on pyloric muscle biopsies in patients undergoing G-POEM, the relatively small sample size precludes any significant subgroup analyses. We also acknowledge that more than half of the patients in this study had prior



► **Fig. 3** a Interstitial cells of Cajal depletion (< 10/HPF). b Moderate to severe pyloric muscle fibrosis on histology.

botulinum toxin injections to the pylorus and it remains unclear if this could have affected the histological findings. Nonetheless, on subgroup analysis (supplementary material), we did not find a difference in ICC count or degree of fibrosis between gastroparetic patients who received botulinum toxin injections vs. those who did not. Third, our sample size included only patients with medically refractory gastroparesis referred for G-POEM; therefore, it may not be representative of all patients with gastroparesis. Furthermore, given the nature of how the biopsies were obtained, a control group (patients without gastroparesis) was not available. Irrespective of those limitations, our study provides compelling data indicating an association between ICC depletion and fibrosis in patients with pyloric dysfunction and clinical response to G-POEM.

## Conclusions

In conclusion, our study supports the feasibility and safety of direct biopsy of the pylorus during G-POEM. We demonstrated that both pyloric ICC depletion and fibrosis are common among patients with gastroparesis. Initial data suggest patients with a higher degree of fibrosis at the pylorus may have a worse response to G-POEM therapy. Further longitudinal studies are needed to corroborate these results and the implications in

management of patients with medically refractory gastroparesis.

## Conflict of Interest

Dr. Yang is a consultant for Olympus, Fujifilm, Boston Scientific, Medtronic, 3D-Matrix, Microtech, and Neptune Medical. Dr. Yang receives research grants from Microtech and 3D-Matrix. MK Hasan is a consultant for Boston Scientific, Olympus, and Microtech. Dr. Cosgrove is a consultant for Boston Scientific and Olympus. Dr. Arain is a consultant for Boston Scientific, Olympus and Cook Medical. All other authors have no disclosures.

## Clinical trial

ClinicalTrials.gov (<http://www.clinicaltrials.gov/>)  
 Registration number (trial ID): NCT05905016  
 Type of Study: Prospective

## References

- [1] Khashab MA, Wang AY, Cai Q. AGA Clinical Practice Update on Gastric Peroral Endoscopic Myotomy for Gastroparesis: Commentary. *Gastroenterology* 2023; 164: 1329–1335 doi:10.1053/j.gastro.2023.02.027
- [2] Wadhwa V, Mehta D, Jobanputra Y et al. Healthcare utilization and costs associated with gastroparesis. *World J Gastroenterol* 2017; 23: 4428–4436
- [3] Grover M, Farrugia G, Stanghellini V. Gastroparesis: a turning point in understanding and treatment. *Gut* 2019; 68: 2238–2250 doi:10.1136/gutjnl-2019-318712
- [4] Lacy BE, Tack J, Gyawali CP. AGA Clinical Practice Update on management of medically refractory gastroparesis: expert review. *Clin Gastroenterol Hepatol* 2022; 20: 491–500 doi:10.1016/j.cgh.2021.10.038
- [5] Martinek J, Hustak R, Mares J et al. Endoscopic pyloromyotomy for the treatment of severe and refractory gastroparesis: a pilot, randomized, sham-controlled trial. *Gut* 2022; 71: 2170–2178
- [6] Kamal F, Khan MA, Lee-Smith W et al. Systematic review with meta-analysis: one-year outcomes of gastric peroral endoscopic myotomy for refractory gastroparesis. *Aliment Pharmacol Ther* 2022; 55: 168–177
- [7] Labonde A, Lades G, Debourdeau A et al. Gastric peroral endoscopic myotomy in refractory gastroparesis: long-term outcomes and predictive score to improve patient selection. *Gastrointest Endosc* 2022; 96: 500–508 doi:10.1016/j.gie.2022.04.002
- [8] Vosoughi K, Ichkhanian Y, Jacques J et al. Role of endoscopic functional luminal imaging probe in predicting the outcome of gastric peroral endoscopic pyloromyotomy (with video). *Gastrointest Endosc* 2020; 91: 1289–1299
- [9] Takaki M. Gut pacemaker cell: the interstitial cells of Cajal (ICC). *J Smooth Muscle Res* 2003; 39: 137–161 doi:10.1540/jsmr.39.137
- [10] Bashashati M, McCallum RW. Is interstitial cells of Cajal (ICC)-opathy present in gastroparesis? *Journal of neurogastroenterology and motility* 2015; 12: 486–493 doi:10.5056/jnm15075
- [11] Langer JC, Berezin I, Daniel EE. Hypertrophic pyloric stenosis: ultrastructural abnormalities of enteric nerves and the interstitial cells of Cajal. *J Pediatr Surg* 1995; 30: 1535–1543 doi:10.1016/0022-3468(95)90151-5

- [12] Lin Z, Sarosiek I, Forster J et al. Association of the status of interstitial cells of Cajal and electrogastrogram parameters, gastric emptying and symptoms in patients with gastroparesis. *Neurogastroenterol Motil* 2010; 22: 56–61
- [13] Forster J, Damjanov I, Lin Z et al. Absence of the interstitial cells of Cajal in patients with gastroparesis and correlation with clinical findings. *J Gastrointest Surg* 2005; 9: 102–108
- [14] Camilleri M, Sanders KM. Gastroparesis. *Gastroenterology* 2022; 162: 68–87 doi:10.1053/j.gastro.2021.10.028
- [15] Moraveji S, Bashashati M, Elhanafi S et al. Depleted interstitial cells of Cajal and fibrosis in the pylorus: Novel features of gastroparesis. *Neurogastroenterol Motil* 2016; 28: 1048–1054 doi:10.1111/nmo.12806
- [16] Shah R, Calderon LF, Sanders BE et al. Quantification of interstitial cells of Cajal in the gastric muscle of patients with gastroparesis at per-oral endoscopic pyloromyotomy: a novel approach for future research in pathogenesis of gastroparesis. *Dig Dis Sci* 2022; 67: 4492–4499
- [17] Revicki DA, Rentz AM, Dubois D et al. Gastroparesis Cardinal Symptom Index (GCSI): development and validation of a patient reported assessment of severity of gastroparesis symptoms. *Qual Life Res* 2004; 13: 833–844 doi:10.1023/B:QURE.0000021689.86296.e4
- [18] Abell TL, Camilleri M, Donohoe K et al. Consensus recommendations for gastric emptying scintigraphy: a joint report of the American Neurogastroenterology and Motility Society and the Society of Nuclear Medicine. *Am J Gastroenterol* 2008; 103: 753–763 doi:10.1111/j.1572-0241.2007.01636.x
- [19] Gregor L, Wo J, DeWitt J et al. Gastric peroral endoscopic myotomy for the treatment of refractory gastroparesis: a prospective single-center experience with mid-term follow-up (with video). *Gastrointest Endosc* 2021; 94: 35–44
- [20] Hayat M, Yang D, Draganov PV. Third-space endoscopy: the final frontier. *Gastroenterol Rep* 2023; 11: goac077 doi:10.1093/gastro/goac077
- [21] Khan HM, Brar TS, Hasan MK et al. Prospective study on the efficacy of endoscopic through-the-scope tack and suture system for gastric peroral endoscopic myotomy mucosal incision site closure. *Endosc Int Open* 2023; 11: E187–E192 doi:10.1055/a-1978-6842
- [22] Yang D, Kadkhodayan K, Arain MA et al. Novel dual-action tissue through-the-scope clip for endoscopic closure. *VideoGIE* 2022; 7: 345–347 doi:10.1016/j.vgie.2022.07.004
- [23] Uemura KL, Chaves D, Bernardo WM et al. peroral endoscopic pyloromyotomy for gastroparesis: a systematic review and meta-analysis. *Endosc Int Open* 2020; 8: E911–E923 doi:10.1055/a-1119-6616
- [24] Dacha S, Mekaroonkamol P, Li L et al. Outcomes and quality-of-life assessment after gastric per-oral endoscopic pyloromyotomy (with video). *Gastrointest Endosc* 2017; 86: 282–289
- [25] Nass KJ, Zwager LW, van der Vlugt M et al. Novel classification for adverse events in GI endoscopy: the AGREE classification. *Gastrointest Endosc* 2022; 95: 1078–1085 doi:10.1016/j.gie.2021.11.038
- [26] Huizinga JD, Chen JH. Interstitial cells of Cajal: update on basic and clinical science. *Curr Gastroenterol Rep* 2014; 16: 363 doi:10.1007/s11894-013-0363-z
- [27] Choi KM, Gibbons SJ, Roeder JL et al. Regulation of interstitial cells of Cajal in the mouse gastric body by neuronal nitric oxide. *Neurogastroenterol Motil* 2007; 19: 585–595 doi:10.1111/j.1365-2982.2007.00936.x