

A novel “NOTES” technique for treating incarcerated stones in the gallbladder neck

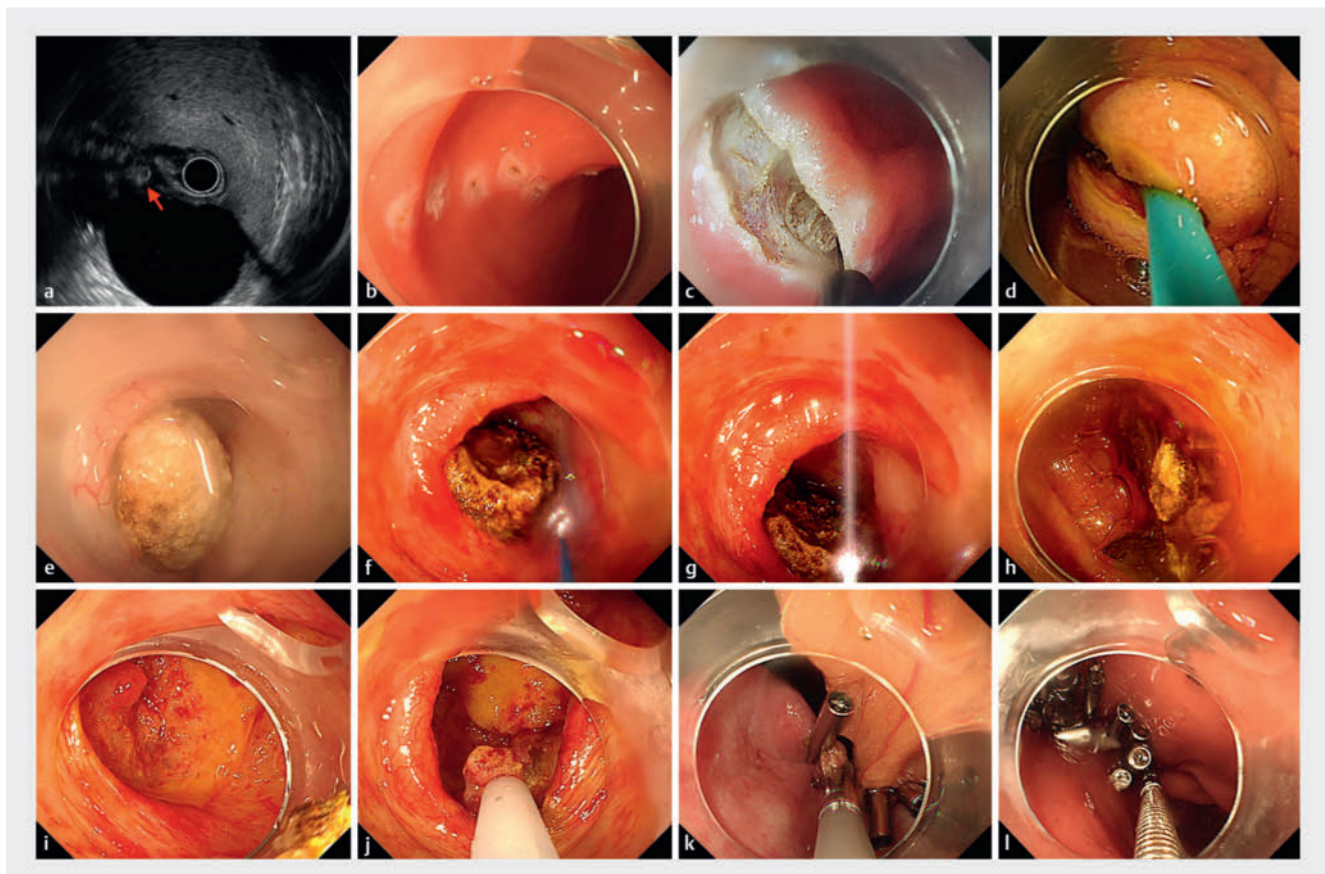
OPEN
ACCESS

Incarceration of stones in the gallbladder neck often causes acute inflammation and, in severe cases, even pyogenic gangrene. Medical treatment is often ineffective, and guidelines recommend laparoscopic cholecystectomy (LC) as the preferred treatment within 24 to 72 hours of onset [1,2]. However, this procedure carries a relatively high risk of adverse events, including bile duct injury, postoperative bile leakage, common bile duct stones, and other serious problems [3]. In nonsurgical patients, endoscopic options such as endoscopic ultrasound

(EUS)-guided drainage with metal stents have improved the treatments that could be offered [4,5]. In this report, we first present a novel endoscopic solution, derived from NOTES, to address stone obstruction of the gallbladder neck.

A 59-year-old woman presented with right epigastric pain for 1 month, which had worsened over the past 2 days. Abdominal ultrasonography, hepatobiliary scintigraphy and EUS revealed an incarcerated stone of approximately 13 × 12 mm in the gallbladder neck as the underlying cause. The patient declined LC

and requested preservation of her gallbladder. To address the issue, we performed endoscopic laser lithotripsy and lithotomy through a transgastric mini-incision of the cholecystic fundus (**Fig. 1**, **Video 1**). During the procedure, the anterior wall of the gastric antrum was perforated with a sterile colonoscope (PCF-Q260Jl, 3.2-mm channel diameter; Olympus, Tokyo, Japan). Subsequently, the gallbladder fundus was located and a 3- to 4-mm incision was made using a flush knife (Fuji, Tokyo, Japan). Incision occlusion was achieved with a lithotomy



▶ Fig. 1 Endoscopic laser lithotripsy and lithotomy through transgastric mini-incision of the cholecystic fundus for treatment of an incarcerated stone in the gallbladder neck of a 59-year-old woman. **a** EUS showed an incarcerated stone in the gallbladder neck. **b, c** Active perforation of the anterior wall of the gastric antrum. **d** Making a 3- to 4-mm incision of the cholecystic fundus and exchanging the suppurative bile with normal saline after incision occlusion with a lithotomy balloon. **e** An incarcerated stone was found embedded in the entrance to the gallbladder neck. **f, g, h** Laser lithotripsy and lithotomy. **i, j** Gallbladder lavage and biopsies of superficial protuberant red lesion. **k** Closure of the gallbladder incision with clips. **l** Closure of the gastric wall.

VIDEO

Endoscopy International Open

VidEIO

 Thieme

▶ **Video 1** Endoscopic laser lithotripsy and lithotomy through a transgastric mini-incision of the cholecystic fundus for treatment of an incarcerated stone in the gallbladder neck of a 59-year-old woman.

balloon (Micro-Tech, Nanjing, China) to prevent bile leakage, followed by thorough exchanges of suppurative bile with normal saline. After adequate gallbladder lavage, the incision was widened to 12 to 14 mm. Upon entering the gallbladder cavity, congestion and edema of the gallbladder wall were observed, along with an incarcerated stone embedded in the entrance to the gallbladder neck. Laser lithotripsy (U100plus lithotripter-Laser, W.O.M. WORLD OF MEDICINE AG, Berlin, Germany) was performed using a laser fiber (560 μm \times 3.5 m, SiliconFlex 300Rplus, Berlin, Germany) to fragment the stones, which were subsequently extracted using an extraction bag (Alton, Shanghai, China). The gallbladder cavity was flushed and biopsies of a 5-mm superficial, protuberant, red lesion were taken. Finally, the gallbladder incision was closed, the abdominal cavity was flushed, and the gastric wall was closed. The patient had an uneventful postoperative course and was discharged 3 days after the endoscopic surgery. Pathology of the gall-

bladder wall indicated inflammation of the cells. During the 15-month follow-up, the patient's symptoms completely resolved, and no obvious stones were detected in her gallbladder by ultrasonography at her 1-month and 6-month follow-up visits. Thus, endoscopic laser lithotripsy and lithotomy through a transgastric mini-incision of the cholecystic fundus might offer a feasible approach for management of incarcerated stones in the gallbladder neck, especially solitary stones.

Conflict of Interest

The authors declare that they have no conflict of interest.

The authors

Congying Chen¹, Xiao Han¹, Jingnan Chen¹, Zhenni Yin¹, Rong Wan¹

¹ Department of Gastroenterology, Shanghai General Hospital, Shanghai, China

Corresponding author

Dr. Rong Wan

Shanghai General Hospital – Department of Gastroenterology, Haining Rd 100, 200080 Shanghai, China
wanrong1970@163.com

References

- [1] Warttig S, Ward S, Rogers G et al. Diagnosis and management of gallstone disease: summary of NICE guidance. *BMJ* 2014; 349: g1 doi:10.1136/bmj.g624125360037
- [2] Pisano M, Allievi N, Gurusamy K et al. 2020 World Society of Emergency Surgery updated guidelines for the diagnosis and treatment of acute calculus cholecystitis. *World J Emerg Surg* 2020; 15: 61 doi:10.1186/s13017-020-00336-x33153472
- [3] Kim SS, Donahue TR. Laparoscopic cholecystectomy. *JAMA* 2018; 319: 1834 doi:10.1001/jama.2018.343829715356
- [4] Mandai K, Uno K. A case of acute cholecystitis successfully treated with endoscopic ultrasound-guided gallbladder drainage in a patient with osteogenesis imperfecta. *Cureus* 2023; 15: e48424
- [5] Ahmed O, Ogura T, Eldahrouty A et al. Endoscopic ultrasound-guided gallbladder drainage: Results of long-term follow-up. *Saudi J Gastroenterol* 2018; 24: 183–2 doi:10.4103/sjg.SJG_506_1729652030

Bibliography

Endosc Int Open 2024; 12: E568–E569

DOI 10.1055/a-2285-2286

ISSN 2364-3722

© 2024. The Author(s).

This is an open access article published by Thieme under the terms of the Creative Commons Attribution-NonDerivative-NonCommercial License, permitting copying and reproduction so long as the original work is given appropriate credit. Contents may not be used for commercial purposes, or adapted, remixed, transformed or built upon. (<https://creativecommons.org/licenses/by-nc-nd/4.0/>)

Georg Thieme Verlag KG, Rüdigerstraße 14, 70469 Stuttgart, Germany

