

Current Diagnostic and Therapeutic Approaches in May–Thurner Syndrome in Children, Adolescents, and Young Adults: A Survey among Thrombosis Experts of the German Society of Thrombosis and Haemostasis

Franziska Cuntz¹ Bernhard Gebauer² Andreas Greiner³ Nikola Hagedorn¹ Madlen Reschke¹
Wolfgang Eberl⁴ Barbara Zieger⁵ Edelgard Lindhoff-Last⁶ Susanne Holzhauser¹

¹ Department of Paediatric Oncology and Haematology, Charité-Universitätsmedizin Berlin, Campus Virchow-Klinikum, Berlin, Germany

² Department of Radiology, Charité-Universitätsmedizin Berlin, Campus Virchow-Klinikum, Berlin, Germany

³ Clinic of Vascular Surgery, Charité-Universitätsmedizin Berlin, Campus Benjamin Franklin, Berlin, Germany

⁴ Department of Paediatrics, Städtisches Klinikum Braunschweig, Braunschweig, Germany

⁵ Division of Paediatric Haematology and Oncology, Department of Paediatrics and Adolescent Medicine, Medical Centre, Faculty of Medicine, University of Freiburg, Freiburg, Germany

⁶ Cardiology Angiology Centre Bethanien, CCB Vascular Centre, CCB Coagulation Centre, Frankfurt, Germany

Address for correspondence Franziska Cuntz, MD, Department of Paediatric Oncology and Haematology, Charité-Universitätsmedizin Berlin, Campus Virchow-Klinikum, Augustenburger Platz 1, 13353 Berlin, Germany (e-mail: Franziska.cuntz@charite.de).

Hamostaseologie

Abstract

May–Thurner syndrome (MTS) is a pelvic venous disorder involving compression of the left common iliac vein by the right common iliac artery, which results in predisposition for deep vein thrombosis. Although MTS is increasingly recognized in young patients, specific guidelines on diagnosis and management for children, adolescents, and young adults do not exist so far. The aim of this study was to assess current diagnostic and therapeutic practice in Germany, Austria, and Switzerland in children and young adults with thrombosis and MTS.

We designed an online survey with 11 questions, which we sent via a mailing list to all members of the German, Austrian, and Swiss Society of Thrombosis and Haemostasis Research. Between July and October 2022, 33 specialists answered the questionnaire. Most participating specialists worked at pediatric hospitals (61%). Numbers of annually treated thromboses ranged from <5 (26%) to >30 (13%). Most specialists used venous ultrasound to diagnose deep vein thrombosis, 53% magnetic resonance imaging. Only 25% of specialists systematically screened for MTS in deep vein thrombosis. MTS was managed with anticoagulation (65%), iliac vein stent placement (32%), or balloon angioplasty (13%). In total, 31% of specialists reported to use more than one therapeutic method. Diagnostic and therapeutic approaches for MTS differed between specialists. Lack of standardization resulted in individualized and highly diverse management. Prospective observational clinical studies investigating the outcome of different management strategies including

Keywords

- ▶ venous thrombosis
- ▶ May–Thurner syndrome
- ▶ iliac vein compression syndrome
- ▶ children
- ▶ adolescents
- ▶ young adults

received
September 24, 2023
accepted after revision
March 6, 2024

© 2024, Thieme. All rights reserved.
Georg Thieme Verlag KG,
Rüdigerstraße 14,
70469 Stuttgart, Germany

DOI <https://doi.org/10.1055/a-2282-4565>.
ISSN 0720-9355.

long-term follow-up on outcome and incidence of postthrombotic syndrome will help in defining patient groups who benefit most from revascularizing interventional strategies and developing standardized guidelines.

Zusammenfassung

Als May–Thurner Syndrom (MTS) wird eine Erkrankung der Beckenvenen bezeichnet, bei der die linke V. iliaca communis durch die rechte A. iliaca communis komprimiert wird, was zu einer Prädisposition für tiefe Bein-/ Beckenvenenthrombosen führt. Unter pädiatrischen Patienten sind vor allem Jugendliche und junge Erwachsene (AYA) betroffen. Spezifische Leitlinien zur optimalen Behandlungsstrategie für Kinder und AYA fehlen.

Ziel dieser Studie war, den derzeitigen diagnostischen und therapeutischen Standard für MTS bei diesen Patientinnen und Patienten in Deutschland, Österreich und der Schweiz zu erfassen.

Wir entwarfen eine Online-Umfrage mit 11 Fragen, die wir per Mailingliste an alle Mitglieder der Deutschen Gesellschaft für Thrombose- und Hämostaseforschung verschickten. Zwischen Juli und Oktober 2022 wurde der Fragebogen von 33 ExpertInnen beantwortet. Die meisten teilnehmenden Zentren waren Kinderkliniken (61%). Die Zahl der jährlich behandelten Thrombosen lag bei <5 (26%) bis >30 (13%). Die meisten ExpertInnen verwendeten den venösen Ultraschall zur Diagnose tiefer Venenthrombosen, 53% der ExpertInnen setzten auch die Magnetresonanztomographie ein. Nur 25% der ExpertInnen führten bei tiefen Venenthrombosen ein systematisches Screening auf MTS durch. Das MTS wurde mit Antikoagulation (65%), Stentimplantation in die V. iliaca (32%) oder Ballonangioplastie (13%) behandelt. 31% der ExpertInnen gaben an, mehr als eine Behandlungsmethode zu nutzen. Diagnostische und therapeutische Ansätze für das MTS unterschieden sich zwischen den ExpertInnen. Die fehlende Standardisierung führte zu einer individualisierten und unterschiedlichen Behandlung.

Prospektive Beobachtungsstudien, die die Ergebnisse verschiedener Behandlungsstrategien einschließlich der Inzidenz des postthrombotischen Syndroms in der Langzeitnachverfolgung untersuchen, werden dazu beitragen, Patientengruppen zu definieren, die von revaskularisierenden interventionellen Strategien profitieren, und standardisierte Leitlinien zu entwickeln.

Schlüsselwörter

- ▶ Thrombose
- ▶ May–Thurner Syndrom
- ▶ Vena-iliaca-Kompressionssyndrom
- ▶ Kinder
- ▶ Jugendliche
- ▶ junge Erwachsene

Introduction

Pelvic venous disorders comprise a variety of clinical signs and symptoms arising from dysfunctions of pelvic veins and their primary drainage pathways.¹ Among these is an anatomical variant known as May–Thurner syndrome (MTS), named after its first describers.² According to the VEIN-TERM transatlantic interdisciplinary consensus document, MTS is defined as venous symptoms and signs caused by obstruction of the left common iliac vein due to external compression at its crossing posterior to the right common iliac artery.³

The incidence of MTS in children and adolescents as well as its impact on the development of venous thrombosis is unknown. Although venous spurs, intraluminal fibrous bands due to left-sided iliac vein compression, have been found in 22% of cadavers of an unselected population² and in up to 75% of patients with left-sided iliofemoral deep vein thrombosis (DVT),⁴ MTS is reported as a cause for venous thrombosis only in a minority of cases. Specifically, children

and adolescent and young adult (AYA) patients with iliac vein compression may be asymptomatic.

Several factors contribute to under-reporting of MTS, including limited awareness of the disease, competing risk factors overshadowing further diagnosis, difficulties in accurately diagnosing MTS, and the lack of clear treatment recommendations when MTS is detected. Adding to the complexity, the clinical significance of different degrees of iliac vein compression as a risk factor for thrombosis remains a topic of debate and the criteria defining pathological stenosis specific to each diagnostic method still need to be established. The accuracy of magnetic resonance imaging (MRI) and computed tomography (CT) in diagnosing MTS in the pediatric population is not well established and at least some patients may not have pathological MRI. In adults, intravascular ultrasound has been shown to be more sensitive than MRI in identifying iliac vein compression.⁵

Against the diagnostic pitfalls, it has been demonstrated that delayed diagnosis of MTS can promote recurrent

thrombosis or reduced efficacy of anticoagulation,⁶ underscoring the importance of early detection.

Treatment options for MTS include long-term anticoagulation, local thrombolysis, thrombectomy, and placement of an intravascular stent or a combination of these methods. There is currently no evidence supporting prophylactic iliac vein stent placement to prevent DVT. Criteria to decide on stent placement during acute DVT intervention additional to insufficient inflow or outflow still need to be defined. Consequently, stent placement is not routinely administered in endovascular treatment of DVT. Techniques as well as expertise differ significantly between centers further contributing to inequality of treatment. However, restoring normal blood flow and preventing development of postthrombotic syndrome (PTS) are important aspects of thrombosis treatment and bear the potential of reducing long-term morbidity. If PTS has already developed, treatment options are limited, and management typically focuses on alleviating symptoms and implementing compression therapy to reduce swelling and enhance blood flow.

AYAs are the predominantly affected group with MTS among the pediatric population. In light of the long life-expectancy, long-term morbidity and the impact on quality of life caused by PTS and recurrent thrombosis must be carefully weighed against the risks associated with stent placement, radiological or surgical interventions, and radiation exposure.

As evidence of long-term outcomes of the various management approaches is sparse, guidelines do not specify diagnostics and treatment for MTS for these patients. Moreover, sufficient data to develop decision models for endovascular treatment strategies for selected patient groups at specialized treatment centers are lacking.

To improve the management of MTS-associated DVT in this patient group, it is imperative to gain a better understanding of the current diagnostic and treatment landscape given the aforementioned uncertainties. Therefore, the objective of this survey was to assess the current practices in German, Austrian, and Swiss centers to standardize diagnostic and therapeutic procedures.

Methods

First, we assembled an interdisciplinary expert team of pediatric hematologists and hemostaseologists (F.C., S.H.), interventional radiologists (B.G.), and vascular surgeons (A.G.). We then designed an online survey consisting of 11 questions, which we distributed via the mailing list to the members of the pediatric working group of the Gesellschaft für Thrombose- und Hämostaseforschung (GTH), namely the Ständige Kommission Pädiatrie (of the GTH), and to all members of the GTH. We included specialists in Germany, Austria, and Switzerland treating pediatric and AYA patients with vein thrombosis. The initial email was sent in July 2022, followed by three reminder emails. The survey was closed in October 2022.

We used the program SoSci Survey of the Charité (<https://survey.charite.de/admin/index.php>; version 3.3.13, university hospital license) for design of the questionnaire and data collection. Questions included center characterization (hospital vs. outpatient practice, specialization), number and age of

treated patients with thrombosis, diagnostic methods available, and used therapeutic options. We wanted to know in which cases physicians chose invasive treatment after diagnosis of MTS. We also asked about awareness and screening of MTS and if patients were referred to specialized treatment centers. In most questions, multiple preselected answers (from a drop-down menu) were provided with an optional free text for individual remarks. Missing answers were excluded. For the complete questionnaire, please see the [►Supplementary Appendix](#). Participants were able to either answer the questionnaire anonymously or to provide name and contact information. Personal data and comments were saved separately from the answers to our questions. The ethics committee of the Charité University Hospital Berlin approved the project (project number EA2/008/22, date of approval 05/05/2022).

Results

Basic Data/Center Characterization

Between July and October 2022, 33 specialists participated in the survey. In total, 91% of participating specialists worked in hospitals (61% pediatrics/pediatric hemostaseology, 15% internal medicine, 3% vascular surgery, 12% others: pediatric cardiology, transfusion medicine/ hemostaseology, internal medicine/ rheumatology) and 9% in outpatient practices (3% general pediatrics, 3% pediatric hemostaseology, 3% internal medicine/hemostaseology) ([►Supplementary Fig. S1](#)). In addition, 52% exclusively treated patients <18 years, 21% only adults >18 years, and 27% patients of all age groups. Numbers of treated thromboses in patients <25 years ranged from 1–5 (26%) to >30 (13%) per year with higher patient numbers in centers treating adult patients only. As the survey was taken anonymously, we do not have full information on the overall response rate.

Diagnostic Approach for Deep Vein Thrombosis

Main diagnostic methods used for DVT were clinical and laboratory workup along with Doppler sonography (Doppler sonography used by 81% of specialists). Furthermore, 53% reported also using MRI ([►Fig. 1](#), 33% of specialists treating only adult patients, 59% only treating pediatric patients) and about two-thirds report using MRI angiograms. CT was chosen less frequently to diagnose DVT, especially by the pediatric specialists (6% vs. 33% treating only adult patients). All specialists opting for MRI or CT angiograms also applied Doppler sonography. Other diagnostic methods were conventional angiogram (used by 9% of all specialists vs. 17% of adult medicine specialists) or phlebography (used by 6% of all specialists vs. 17% of adult medicine specialists). None of the participating specialists performed intravascular sonography for diagnosis of DVT.

Treatment Approach for Deep Vein Thrombosis and MTS

Available treatment options at the participating centers included therapeutic anticoagulation (81%), systemic fibrinolysis (55%), local lysis/catheter-directed lysis (68%), interventional thrombectomy (71%), and surgical thrombectomy (68%).

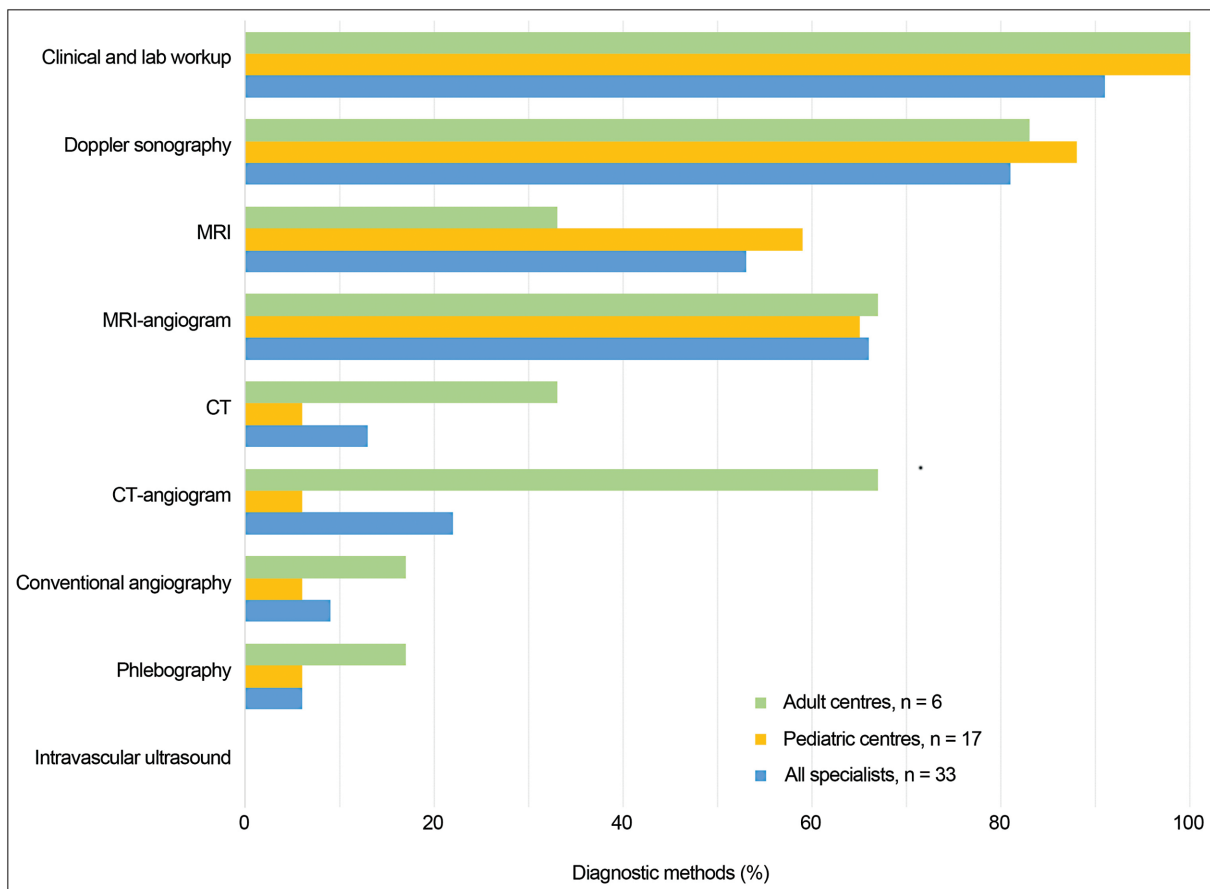


Fig. 1 Diagnostic methods for DVT (in %). Diagnostic methods for DVT chosen by all specialists (blue bars), specialists working at pediatric centers (yellow), and specialists treating adult patients (green), shown in %. Main diagnostic methods are clinical/laboratory workup and Doppler sonography. Only 53 to 59% chose MRI and 66% MRI-angiogram. CT and CT-angiogram are used less frequently, and very rarely by pediatric specialists. Conventional angiography and phlebography are chosen by 6% pediatric specialists and 17% nonpediatric specialists. None of the specialists opt for intravascular sonography. CT, computed tomography; DVT, deep vein thrombosis; MRI, magnetic resonance imaging.

DVT was treated by therapeutic anticoagulation (84% of specialists), interventional thrombectomy (39%), catheter lysis/ultrasound-directed methods (32%), systemic fibrinolysis (13%), surgical thrombectomy (10%), or several of these methods (→ **Supplementary Fig. S2**). In addition, 16% of specialists did not choose any of these treatment methods. Furthermore, 47% of specialists used more than one treatment method although we do not have information on prioritization and combination of therapeutic methods.

Screening for MTS was only performed by 25% of specialists (always 7%, in case of typical clinical signs 4%, in case of left-sided DVT 4%, in iliac vein compression 8%) (→ **Fig. 2**). Patients with MTS received anticoagulation by 65% of specialists, stent implantation was performed by 32%, and balloon angioplasty by 13%—or more than one method was applied (→ **Supplementary Fig. S3**). Some specialists stated that they considered continuous anticoagulation, secondary angioplasty and stent placement, lysis, thrombectomy, or that the condition was too rare at their center to answer the question. Choice of treatment was highly individualized. Invasive (endovascular, nonconservative) treatment was performed depending on thrombus localization (85%), thrombus size (81%), estimated age of thrombosis (77%), for lack of contraindications (42%), or to avoid PTS (42%)

(→ **Fig. 3**). Some specialists reported that they use invasive treatment depending on clinical symptoms, specifically stasis, claudicatio venosa, if venous compression was diagnosed or in young patients with proximal thrombosis of pelvic veins. One specialist, on the other hand, stated that they rarely choose invasive methods in patients <18 years.

Diagnostic or therapeutic approaches did not significantly differ between larger and smaller centers nor between hospitals and outpatient practices.

Half of participating specialists defined their center as specialized treatment center and in 36%, patients were referred to specialized centers. Most specialists who referred patients to specialized centers stated that they choose conservative treatment for MTS.

Discussion

The results of this survey highlight the lack of a standardized approach to diagnose or treat MTS in pediatric and adolescent patients in German, Austrian, and Swiss centers. The participating specialists, who worked primarily at hospitals (91%), and a few outpatient practices (9%) showed variability both in their awareness of MTS and the management strategies employed. The fact that no specific guideline for this

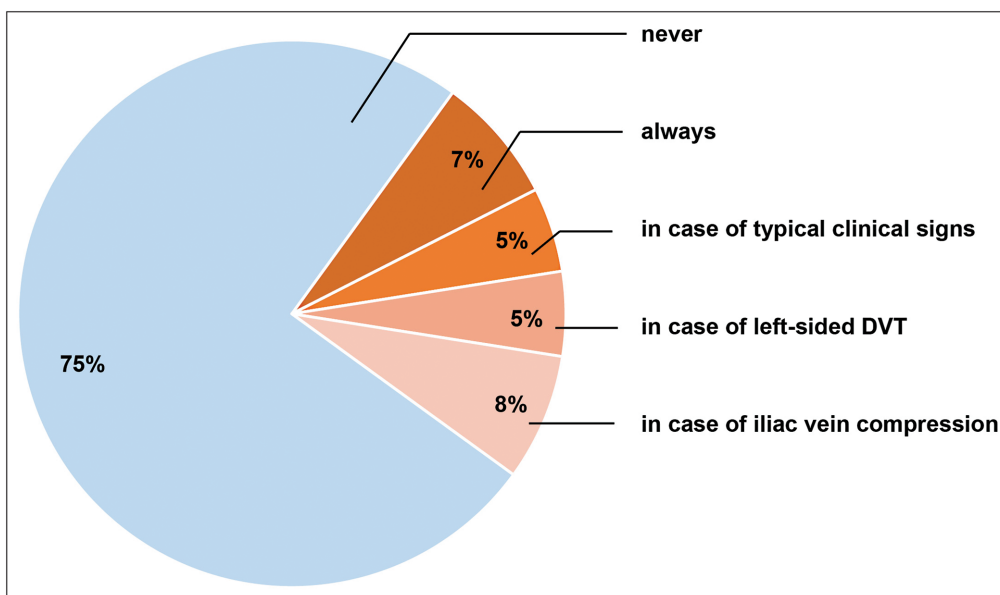


Fig. 2 Screening for MTS. Screening for MTS is performed by 25% of specialists (always 7%, in case of typical clinical signs 5%, in case of left-sided DVT 5%, in iliac vein compression 8%). MTS, May–Thurner syndrome.

condition exists contributes to individualized and center-specific treatment approaches.

More than 80% of specialists in our survey use color Doppler ultrasound for diagnosis of DVT. Although color Doppler ultrasound is the current imaging standard method to diagnose DVT, several studies have reported low sensitivity of ultrasound to diagnose MTS.^{7–9} Besides differences in expertise and training of the investigator, the diagnostic accuracy of Doppler sonography highly depends on individual anatomical features and visibility of the iliac veins⁷ and venous collaterals are poorly identified by ultrasound.¹⁰ Consequently, the diagnosis of iliac vein compression will be missed in part of the patients if no systematic screening for MTS with MRI or CT is performed.⁶ As only about half of the specialists in our survey reported applying

MRI and two-thirds chose MRI angiogram to screen for MTS in DVT of leg and pelvis, underlying MTS is likely to be underestimated in patients who present with left-sided proximal DVT in these centers.

If cross-sectional imaging is performed, pediatric specialists participating in our survey strongly preferred MRI to CT (59% vs. 6%, respectively). As the pelvic region contains vulnerable organs and to preserve fertility and prevent radiation exposure and cancer development, MRI, if available, is recommended specifically in young patients to avoid radiation exposure.^{11,12} While CT and MRI venography can detect iliac vein compression and rule out a pelvic mass with high sensitivity, there are some limitations to cross-sectional imaging as these methods need to be performed and

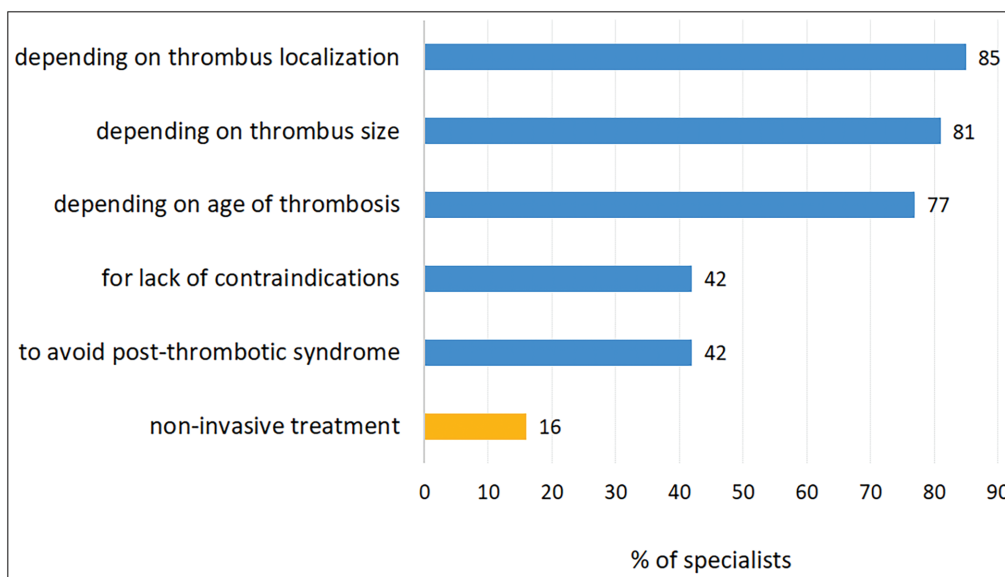


Fig. 3 Invasive treatment for MTS (%). Invasive treatment is chosen by >80% of specialists, depending on localization, size, age of thrombus, for lack of contraindications or to avoid PTS. MTS, May–Thurner syndrome; PTS, postthrombotic syndrome.

interpreted in a standardized manner and sufficient hydration must be ensured to avoid overdiagnosis of iliac vein compression.¹³ Conventional angiography and phlebography were rarely chosen by the specialists in our survey. The specialists did not report on reasons, but increased radiation and contrast dye exposure as well as bleeding risk of the patient may influence that choice. Intravascular ultrasound has been shown to be more sensitive in identifying iliofemoral stenotic lesions than venography in adult patients⁵ and has been recommended as most accurate method to evaluate MTS¹⁰; the participating specialists did not report the use of this method, however. As intravascular ultrasound is an invasive method, it still needs to be determined whether the outcome of MTS in AYA can be improved by treatment decisions based on intravascular ultrasound.

The variable level of awareness of MTS is underlined by the fact that only 25% of specialists participating in the survey systematically screen for MTS. Consequently, diagnosis of MTS may be overlooked or delayed in unscreened patients leading to an increased recurrence and PTS risk. Although the impact on recurrent thrombosis and long-term morbidity still needs to be determined, data suggest that early detection of pelvic venous disorders through screening can improve patient outcomes.⁶

The inconsistent screening for MTS in participating centers stands in contrast to the result that, once the diagnosis of MTS is established, most specialists (84%) opt for invasive endovascular treatment, frequently using a combination of different treatment methods, including iliac vein stenting and balloon angioplasty. This aligns with findings from previous studies on pediatric MTS, summarized in a systematic review on 109 cases. The overall rate of invasive treatment in these studies was as high as 76% in children with iliac vein compression with favorable safety profiles and improved vessel patency. In the study, interventions were reported to be safe with major bleeding in 4% of patients after image-guided therapy without any deaths.⁹

Data on long-term outcome after image-guided invasive treatment versus anticoagulation alone are controversial. In addition, it is unclear which patients benefit from endovascular treatment and what is the best time point for this kind of intervention. The safety and efficacy of secondary endovascular intervention in pediatric patients with iliac and/or femoral thrombosis after up to 12 months after diagnosis have been recently demonstrated in a study that involved 12 pediatric patients.¹⁴

Another important question is how effectiveness and safety of any therapeutic approach are best evaluated. Many studies use PTS as outcome parameter after thrombosis. Due to various PTS scoring systems and inconsistent PTS definitions, comparison of PTS incidence across studies is of limited value. Outcome data on PTS rates after different kinds of treatment in adult patients with iliac vein compression syndrome are conflicting: a retrospective study and prospective registry on 35 patients with MTS showed overall low rates of PTS (assessed by the Villalta score) with no significant difference between conservative and image-guided invasively treated groups.¹⁵ Also, in two large, randomized studies in adults with iliofemoral or proximal DVT, there was

no significant difference in PTS incidence in patients with or without endovascular intervention at short-term follow-up.^{16,17} However, in those studies with long-term follow-up observation, a higher impact on prevention of PTS and improvement of venous-related quality of life was reported.^{18,19} In the CaVenT-trial, the incidence of PTS in patients with iliofemoral thrombosis was significantly lower in the group of patients treated with catheter-directed thrombolysis compared to the standard treatment group; however, there were no cases of severe PTS and no difference in quality of life.²⁰ Based on these results, the authors of the CaVenT-trial recommend catheter-based thrombolysis in patients with a high proximal DVT and low bleeding risk.

There are limited data on the incidence, characteristics, prevention, and treatment of PTS in children and it is unclear whether the results in adults can be transferred to pediatric patients.²¹ In a recent study in children, increasing age at the time of DVT and non-central venous catheter-related thrombosis were associated with higher PTS severity scores.²² So far, severe PTS has been rarely reported in children and young adults²³; however, reliable data on incidence of PTS in children and AYAs with MTS and venous thrombosis are not available and long-term effects of pediatric PTS are yet to be determined. In a systematic review on 109 pediatric patients, 61% showed signs of PTS (using a broad definition of PTS; PTS considered to be present when patients were reported to have any signs or symptoms secondary to DVT and its sequelae).⁹ In the aforementioned study, PTS was not predicted by treatment modality; however, lack of complete vessel patency predicted relapse of thrombosis and recurrent thrombosis predicted PTS. The authors state that an image-guided approach could be considered to improve patency.⁹ In a study on adolescent patients, 36% of patients showed signs of PTS with all but one patient receiving endovascular treatment.⁶ A recent study on 12 pediatric patients with thrombosis reported low rates of PTS both after endovascular treatment and anticoagulation alone with secondary endovascular intervention being safe and efficient in case of persistent signs of veno-occlusion despite therapeutic anticoagulation.¹⁴

The potential advantages of image-guided endovascular treatment methods must be weighed against the risks. Stent implantation seems to improve vessel patency; however, it bears the risk of stent migration, stent thrombosis, and excessive/periprocedural bleeding, although in the few published studies in children and adolescents, bleeding rates were low.^{6,9} A recent retrospective single-center study reported technical feasibility and high patency rates after iliac vein stent placement in 63 AYAs with MTS.²⁴ Children might be at low risk of bleeding due to less concomitant medication than adults; however, smaller size of vessels may bear risks as well. Regular check-ups after stent placement in children and adolescents are necessary given the developmental changes of the vascular system and the very long duration of stent implantation in these patients. Radiation exposure is another side effect, which is particularly relevant in female young patients since the ovaries are located in the radiation field of the pelvic veins.

Of note, 13% of specialists participating in our survey reported using systemic fibrinolysis for treatment of

thrombosis. In our survey, we did not ask for specific reasons for systemic lysis; however, the current national guideline advises against systemic fibrinolysis because of the risk of excessive bleeding²⁵ and alternatives available; additionally, in the current American Society of Hematology guideline, catheter-directed thrombolysis is recommended over systemic thrombolysis for patients with extensive DVT.²⁶

Limitations

As we do not have information on all medical centers treating pediatric patients, either because they did not participate in the survey or because they are not members of the GTH and therefore did not receive the questionnaire, we acknowledge selection bias. Gynecologists, vascular surgeons, or other specialists underrepresented in our survey may primarily see AYA patients with MTS. Consequently, the results may not reflect management reality in young adults, as pediatric centers, which were the majority of participating centers, do not primarily treat these patients. Although our survey questions did not discriminate between treatment reports of pediatric and adult patients, our survey was explicitly tailored to children and AYA.

Moreover, we cannot state an overall response rate due to missing information on the exact number of included centers, which is due to the database structure of the GTH and the option to answer the questions anonymously. In addition, 48% of participants (16/33) provided us with their affiliations and they all were from different centers. We estimate a response rate of at least 37% for pediatric hemostaseologists as 11 participants who provided their affiliations work at pediatric centers (of which there are 30 in the GTH). The results therefore do not reflect the diagnostic and treatment landscape for all German-speaking centers and our survey focused on pediatric patients and AYAs.

However, the aim of the survey was to explore potential variability in the treatment landscape, which we found among the specialists participating in the survey. Our survey allows, for the first time, a systematic evaluation in a group of highly specialized primarily pediatric hematologists.

More than one-third of participating specialists refer patients to specialized treatment centers. In these primary care centers, there was a preference for conservative treatment of MTS. Consequently, the rate of subsequent endovascular treatment in these patients may be underestimated, as we do not have information on the follow-up treatment.

Conclusion and Perspective

For the first time, current diagnostic and therapeutic procedures in pediatric and AYA patients with MTS in German, Austrian, and Swiss centers were systematically assessed. The survey highlights the heterogeneity in diagnostic and treatment approaches with only 25% of participating specialists systematically screening for iliac vein compression. These differences point at a knowledge gap for this patient group. To optimize care, it is crucial to systematically observe these patients, compare different strategies currently used, and follow up on short- and long-term outcomes.

Questions remain not only about diagnostics, treatment, and outcomes of patients with MTS, but also about the influence of localization and extension of thrombosis on PTS. Age-group specific issues such as clinical course after invasive treatment in different age groups need to be considered.

The next step is to set up a prospective observational study investigating efficacy and safety of different management strategies in this patient group. Long-term follow-up on outcome, specifically (1) on the incidence of PTS or (2) on the long-term effects of stent placing, can identify patient groups that benefit most from revascularizing interventional strategies. Information from observational data helps defining research questions for multicenter randomized trials.

What Is Known about This Topic?

- May–Thurner syndrome (MTS) is a pelvic venous disorder involving compression of the left common iliac vein by the right common iliac artery, which results in predisposition for deep vein thrombosis.
- Although MTS is increasingly recognized in young patients, specific guidelines on diagnosis and management for children, adolescents, and young adults do not exist so far.
- The incidence of MTS as well as its impact on the development of venous thrombosis is not well established.
- Delayed diagnosis of MTS can promote recurrent thrombosis or reduced efficacy of anticoagulation.
- Treatment options include anticoagulation, iliac vein stent placement, thrombectomy, and/or catheter-directed fibrinolysis.
- Evidence of long-term outcomes of the various management approaches is sparse.

What Does This Paper Add?

- Current diagnostic and therapeutic procedures in German, Austrian, and Swiss centers treating pediatric, adolescent, and adult patients with MTS were systematically assessed.
- The survey highlights the heterogeneity in diagnostic and treatment approaches with only 25% of participating specialists systematically screening for MTS. These differences between centers point at a knowledge gap in this patient group. To optimize care, it is crucial to compare different strategies currently used and follow up on outcomes.
- Next steps are to set up a prospective observational study investigating efficacy and safety of different management strategies in this patient group. Long-term follow-up on outcome, specifically (1) incidence of postthrombotic syndrome or (2) long-term effects of stent placing, is urgently needed to define patient groups that benefit from revascularizing interventional strategies and to develop standardized guidelines. Information from observational data can guide to define research questions to be addressed in multicenter randomized trials.

Author Contributions

F.C., S.H., B.G., and A.G. designed the questionnaire. F.C. and S.H. collected data from the participating centers and wrote the manuscript. F.C. presented the results of the survey at the annual meeting of the German Society for Thrombosis and Haemostasis (GTH) 2023. E.L.-L. treats adult patients with MTS, has read the manuscript, and suggested modifications. All authors revised the manuscript.

Conflict of Interest

FC: Support for attending meetings and/or travel: GTH meeting Frankfurt 2023, train ticket and hotel paid by NovoNordisk

BG: Payment or honoraria for lectures, presentations, speakers bureaus, manuscript writing or educational events: Parexel/CALYX, SIRTEx Medical, BAYER, COOK, Siemens/VARIAN, Pharmaceut, Ewimed, Guerbet, Terumo, Beacon Bioscience/ICON, Elsay, INARI, IPSEN; Support for attending meetings and/or travel: Parexel/CALYX, SIRTEx Medical, BAYER, COOK, Siemens/VARIAN, Pharmaceut, Ewimed, Guerbet, Terumo, Beacon Bioscience/ICON, Elsay, INARI, IPSEN

BZ: Grants or contracts from any entity: Grant funding from CSL Behring, Grant funding from Takeda; Leadership or fiduciary role in other board, society, committee or advocacy group, paid or unpaid: Leader of the Pediatric commission of the German GTH

EL-L: Consulting fees: Boehringer Ingelheim, BMS/Pfizer, Bayer, Leo Pharma; Payment or honoraria for lectures, presentations, speakers bureaus, manuscript writing or educational events: Daiichi Sankyo, Boehringer Ingelheim, BMS/Pfizer, Bayer, Leo Pharma, CSL Behring, Astra Zeneca, Norgine, Alexion; Participation on a Data Safety Monitoring Board or Advisory Board: BMS/Pfizer, Boehringer Ingelheim, Bayer

SH: Consulting fees: Bayer, Boehringer Ingelheim; Payment or honoraria for lectures, presentations, speakers bureaus, manuscript writing or educational events: Biomarin, Chugai; Support for attending meetings and/or travel: Biomarin; Participation on a Data Safety Monitoring Board or Advisory Board: Bayer, Boehringer Ingelheim, Sobi, Pfizer; Leadership or fiduciary role in other board, society, committee or advocacy group, paid or unpaid: ISTH

MR: Grants or contracts from any entity: Pfizer, Octapharma, LFB, CSL, SOBI, Takeda, Chugai; Consulting fees: Pfizer, LFB, CSL, SOBI, Takeda, Chugai; Payment or honoraria for lectures, presentations, speakers bureaus, manuscript writing or educational events: Pfizer, LFB, CSL, SOBI, Takeda, Chugai; Support for attending meetings and/or travel: Pfizer, Octapharma, LFB, CSL, SOBI, Takeda, Chugai; Participation on a Data Safety Monitoring Board or Advisory Board: Octapharma, CSL, SOBI, Takeda, Chugai AG, WE, NH have no conflict of interest

Acknowledgements

We thank all specialists for participating in this survey.

The project was approved by the ethics committee of the Charité University Hospital, Berlin.

References

- 1 Meissner MH, Khilnani NM, Labropoulos N, et al. The Symptoms-Varices-Pathophysiology classification of pelvic venous disorders: a report of the American Vein & Lymphatic Society International Working Group on Pelvic Venous Disorders. *J Vasc Surg Venous Lymphat Disord* 2021;9(03):568–584
- 2 May R, Thurner J. The cause of the predominantly sinistral occurrence of thrombosis of the pelvic veins. *Angiology* 1957;8(05):419–427
- 3 Eklof B, Perrin M, Delis KT, Rutherford RB, Gloviczki P American Venous Forum European Venous Forum International Union of Phlebology American College of Phlebology International Union of Angiology. Updated terminology of chronic venous disorders: the VEIN-TERM transatlantic interdisciplinary consensus document. *J Vasc Surg* 2009;49(02):498–501
- 4 Cockett FB, Thomas ML. The iliac compression syndrome. *Br J Surg* 1965;52(10):816–821
- 5 Gagne PJ, Tahara RW, Fastabend CP, et al. Venography versus intravascular ultrasound for diagnosing and treating iliofemoral vein obstruction. *J Vasc Surg Venous Lymphat Disord* 2017;5(05):678–687
- 6 Cohen CT, Kirk S, Desai SB, Kukreja KU, Srivaths L. Diagnosis, clinical characteristics, and treatment modalities of adolescent May-Thurner syndrome-associated deep venous thrombosis. *J Pediatr Hematol Oncol* 2021;43(03):e346–e350
- 7 Zucker EJ, Ganguli S, Ghoshhajra BB, Gupta R, Prabhakar AM. Imaging of venous compression syndromes. *Cardiovasc Diagn Ther* 2016;6(06):519–532
- 8 White JM, Comerota AJ. Venous compression syndromes. *Vasc Endovascular Surg* 2017;51(03):155–168
- 9 Avila L, Cullinan N, White M, et al. Pediatric May-Thurner Syndrome-Systematic review and individual patient data meta-analysis. *J Thromb Haemost* 2021;19(05):1283–1293
- 10 Poyyamoli S, Mehta P, Cherian M, et al. May-Thurner syndrome. *Cardiovasc Diagn Ther* 2021;11(05):1104–1111
- 11 Miglioretti DL, Johnson E, Williams A, et al. The use of computed tomography in pediatrics and the associated radiation exposure and estimated cancer risk. *JAMA Pediatr* 2013;167(08):700–707
- 12 Pearce MS, Salotti JA, Little MP, et al. Radiation exposure from CT scans in childhood and subsequent risk of leukaemia and brain tumours: a retrospective cohort study. *Lancet* 2012;380(9840):499–505
- 13 Ibrahim W, Al Safran Z, Hasan H, Zeid WA. Endovascular management of may-thurner syndrome. *Ann Vasc Dis* 2012;5(02):217–221
- 14 Glonnegger H, Zieger B, Grohmann J, et al. Successful secondary endovascular intervention in pediatric patients with venous thromboembolic events. *Hamostaseologie* 2023;43(02):102–109
- 15 Nawasrah J, Zydek B, Lucks J, et al. Incidence and severity of postthrombotic syndrome after iliofemoral thrombosis - results of the Iliaca-PTS - Registry. *Vasa* 2021;50(01):30–37
- 16 Notten P, Ten Cate-Hoek AJ, Arnoldussen CWKP, et al. Ultrasound-accelerated catheter-directed thrombolysis versus anticoagulation for the prevention of post-thrombotic syndrome (CAVA): a single-blind, multicentre, randomised trial. *Lancet Haematol* 2020;7(01):e40–e49
- 17 Vedantham S, Goldhaber SZ, Julian JA, et al; ATTRACT Trial Investigators. Pharmacomechanical catheter-directed thrombolysis for deep-vein thrombosis. *N Engl J Med* 2017;377(23):2240–2252
- 18 Comerota AJ, Kearon C, Gu CS, et al; ATTRACT Trial Investigators. Endovascular thrombus removal for acute iliofemoral deep vein thrombosis. *Circulation* 2019;139(09):1162–1173
- 19 Notten P, de Smet AAEA, Tick LW, et al. CAVA (Ultrasound-Accelerated Catheter-Directed Thrombolysis on Preventing

- Post-Thrombotic Syndrome) trial: long-term follow-up results. *J Am Heart Assoc* 2021;10(11):e018973
- 20 Enden T, Haig Y, Kløw NE, et al; CaVenT Study Group. Long-term outcome after additional catheter-directed thrombolysis versus standard treatment for acute iliofemoral deep vein thrombosis (the CaVenT study): a randomised controlled trial. *Lancet* 2012; 379(9810):31–38
 - 21 Betensky M, Goldenberg NA. Post-thrombotic syndrome in children. *Thromb Res* 2018;164:129–135
 - 22 Avila L, Amiri N, De R, et al. Characteristics of upper- and lower-extremity deep vein thrombosis and predictors of postthrombotic syndrome in children. *Blood Adv* 2021;5(19):3737–3747
 - 23 Goldenberg NA, Branchford B, Wang M, Ray C Jr, Durham JD, Manco-Johnson MJ. Percutaneous mechanical and pharmacomechanical thrombolysis for occlusive deep vein thrombosis of the proximal limb in adolescent subjects: findings from an institution-based prospective inception cohort study of pediatric venous thromboembolism. *J Vasc Interv Radiol* 2011;22(02): 121–132
 - 24 Bertino FJ, Hawkins CM, Woods GM, et al. Technical feasibility and clinical efficacy of iliac vein stent placement in adolescents and young adults with May-Thurner syndrome. *Cardiovasc Intervent Radiol* 2024;47(01):45–59
 - 25 Gefäßmedizin DGfAGf. Diagnostik und Therapie der Venenthrombose und Lungenembolie 2023. [Version 5.0: National AWMF guideline]. Accessed March 27, 2024 at: https://register.awmf.org/assets/guidelines/065-0021_S2k_Venenthrombose-Lungenembolie_2023-03.pdf
 - 26 Ortel TL, Neumann I, Ageno W, et al. American Society of Hematology 2020 guidelines for management of venous thromboembolism: treatment of deep vein thrombosis and pulmonary embolism. *Blood Adv* 2020;4(19):4693–4738