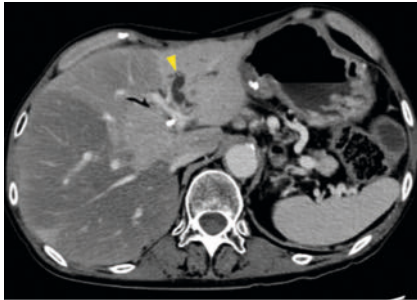


Efficacy of a novel drill dilator in overcoming severe biliary strictures with balloon enteroscopy

OPEN
ACCESS

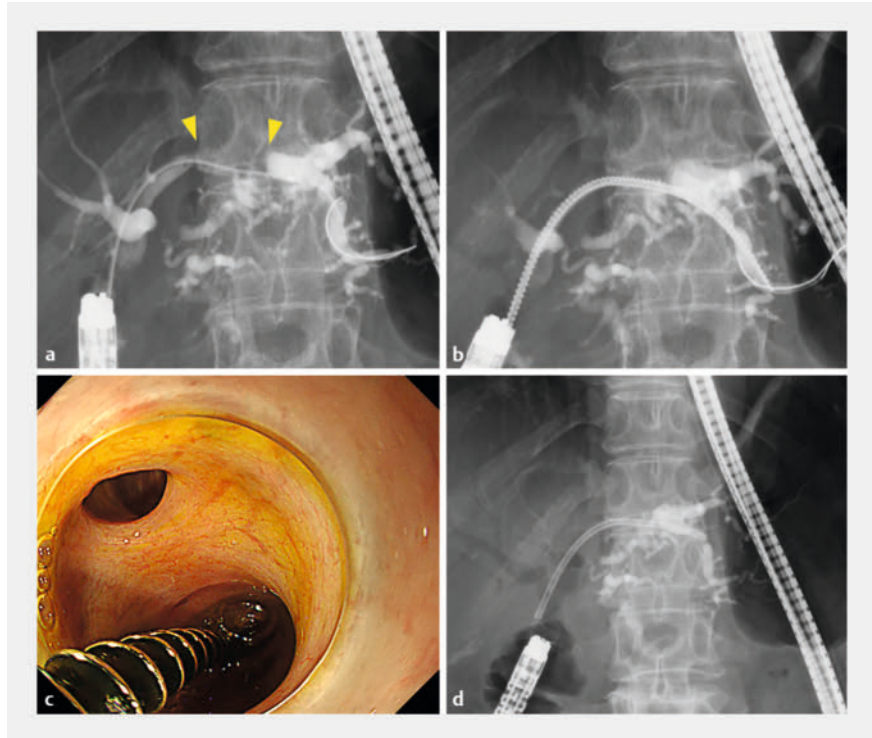


► **Fig. 1** Contrast-enhanced computed tomography image of the dilated left hepatic bile duct (yellow arrowhead), which was obstructed by metastasis of pancreatic cancer on the biliary hilum.

In patients with altered anatomy, biliary strictures are widely overcome using balloon enteroscopy-assisted endoscopic retrograde cholangiopancreatography (BE-ERCP). As the balloon endoscope has a small-diameter channel and scope maneuverability is poor, severe biliary strictures are often difficult to overcome. In such cases, dilation has previously been achieved using screw-type stent retrievers [1, 2]. Recently, however, a novel drill dilator (Tornus ES; Asahi Intecc Co., Ltd., Aichi, Japan) has been developed specifically for penetrating and dilating strictures [3, 4, 5].

Case 1: A woman aged in her 60s, with liver metastasis after subtotal stomach-preserving pancreaticoduodenectomy (SSPPD) for pancreatic head cancer presented with cholangitis due to a severe malignant stricture in the left hepatic bile duct (► **Fig. 1**). Attempts to place a plastic stent using a balloon endoscope (SIF-H290S, Olympus Co., Tokyo, Japan) were challenging because of the extreme hardness of the stricture. Despite trying another dilator, only a catheter was able to pass through. The novel drill dilator easily traversed and dilated the stricture, allowing for successful stent placement (► **Fig. 2**, ► **Video 1**).

Case 2: A man aged in his 70s experienced cholangitis with intrahepatic bili-



► **Fig. 2** Balloon enteroscopy-assisted endoscopic retrograde cholangiopancreatography was performed to place a plastic stent in the occluded bile duct. **a** The left hepatic duct was rigidly obstructed for a long distance (yellow arrowheads), and only a catheter was able to pass through. **b** The novel drill dilator could easily break through and dilate the stricture by simply rotating, without strong pushing. **c** Endoscopic image of the drill dilator. **d** After dilation, a 7 Fr plastic stent was successfully deployed in the left hepatic duct.

ary obstruction due to recurrence of distal bile duct cancer after SSPPD. It was determined that the obstruction in the posterior branch, where stenting had not been successful, was the main cause of cholangitis. The stricture was very tight and significantly angulated, making it impossible to traverse with any devices under BE-ERCP (► **Fig. 3**). The rotational force and adequate flexibility of the novel drill dilator enabled the stricture to be successfully traversed and dilated, followed by successful stent placement (► **Fig. 4**, ► **Video 1**).

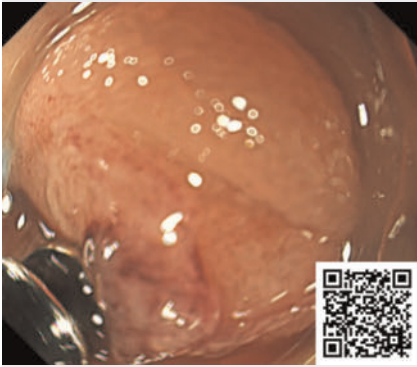
In BE-ERCP, where the range of usable devices and maneuverability are limited, the novel drill dilator proved to be useful

in dilating severe biliary strictures, even in patients with altered anatomy.

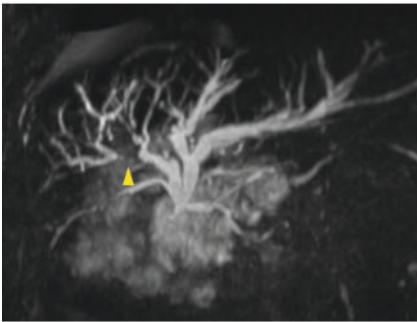
Endoscopy_UCTN_Code_TTT_1AR_2AG

Conflict of Interest

A. Katanuma has received honoraria as a lecture fee from Olympus Co., Tokyo, Japan. H. Toyonaga, T. Hayashi, M. Motoya, T. Kin, and K. Takahashi declare that they have no conflict of interest.



▶ Video 1 A novel drill dilator showed efficacy in overcoming severe biliary strictures during balloon enteroscopy-assisted endoscopic retrograde cholangiopancreatography in patients with altered anatomy, even when scope maneuverability and device options were limited.



▶ Fig. 3 Magnetic resonance cholangiopancreatography image. The right posterior branch was occluded by the recurrence of biliary cancer (yellow arrowhead).

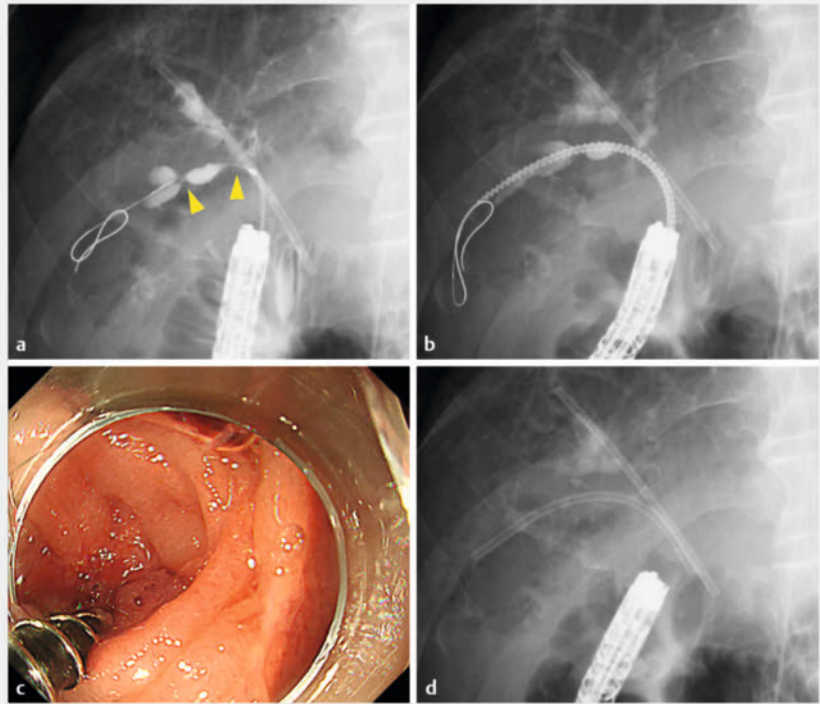
The authors

Haruka Toyonaga¹, Tsuyoshi Hayashi¹, Masayo Motoya¹, Toshifumi Kin¹, Kuniyuki Takahashi¹, Akio Katanuma¹

¹ Center for Gastroenterology, Teine Keijinkai Hospital, Sapporo, Japan

Corresponding author

Haruka Toyonaga, MD
Center for Gastroenterology, Teine Keijinkai Hospital, 1-40-1-12 Maeda, Teine-ku, Sapporo 006-8555, Japan
toyonaga.pc@gmail.com



▶ Fig. 4 Use of the novel drill dilator for severe biliary structure. **a** The posterior branch of the right bile duct was rigidly stenosed in several places (yellow arrowheads) and at an acute angle to the enteroscope, making it impassable by any device. **b** The novel drill dilator could easily break through the stenosis without any resistance, despite the poor conditions. **c** Endoscopic image of the malignant stenosis being dilated by the drill dilator. **d** Fluoroscopic image after successful stent deployment.

References

- [1] Inoue T, Ibusuki M, Kitano R et al. Severe biliary stricture dilation using the Soehendra stent retriever with a short-type balloon enteroscope in patients with surgically altered anatomies. *J Gastrointest Surg* 2019; 23: 1–2
- [2] Toyonaga H, Hayashi T, Katanuma A. Usefulness of a screw tip stent retriever as a dilator during side-by-side placement of multiple stents for malignant hilar biliary obstruction. *Endoscopy* 2022; 54: E698–E699doi:10.1055/a-1757-920835226943
- [3] Hara K, Okuno N, Haba S et al. Utility of a novel drill dilator for easier EUS-guided pancreatic duct drainage. *J Hepatobiliary Pancreat Sci* 2022; 29: e91–e92doi:10.1002/jhbp.113035243809
- [4] Mizumachi M, Mukai S, Itoi T. Transmural pancreatoscopy-assisted lithotripsy through endoscopic ultrasound-guided pancreatic duct drainage tract created by a novel drill dilator. *Dig Endosc* 2023; 35: e93–e94doi:10.1111/den.1456937193654
- [5] Okamoto T, Takeda T, Sasahira N. Endoscopic ultrasound-guided choledochoduodenostomy using a drill dilator. *Endoscopy* 2023; 55: E635–E636doi:10.1055/a-2055-972437068741

Bibliography

Endoscopy 2024; 56: E240–E241
DOI 10.1055/a-2271-4215
ISSN 0013-726X
© 2024. The Author(s).

This is an open access article published by Thieme under the terms of the Creative Commons Attribution License, permitting unrestricted use, distribution, and reproduction so long as the original work is properly cited.

(<https://creativecommons.org/licenses/by/4.0/>)

Georg Thieme Verlag KG, Rüdigerstraße 14, 70469 Stuttgart, Germany

