

Neuroradiological diagnosis and therapy of cerebral vasospasm after subarachnoid hemorrhage

Neuroradiologische Diagnostik und Therapie von zerebralen Vasospasmen nach Subarachnoidalblutung

Authors

Alexander Neumann , Hannes Schacht, Peter Schramm

Affiliations

Department of Neuroradiology, University Hospital Schleswig-Holstein, Campus Lübeck, Germany

Keywords

subarachnoid hemorrhage, delayed cerebral ischemia, cerebral vasospasm, endovascular rescue treatment, nimodipine, balloon angioplasty

received 29.11.2023

accepted after revision 30.1.2024

published online 2024

Bibliography

Fortschr Röntgenstr

DOI 10.1055/a-2266-3117

ISSN 1438-9029

© 2024, Thieme. All rights reserved.

Georg Thieme Verlag KG, Rüdigerstraße 14, 70469 Stuttgart, Germany

Correspondence

Priv.-Doz. Dr. Alexander Neumann

Department of Neuroradiology, University Hospital Schleswig-Holstein, Campus Lübeck, Ratzeburger Allee 160, 23564 Lübeck, Germany

Tel.: +49/4 51/50 01 72 12

Alexander.Neumann@uksh.de

ABSTRACT

Background Cerebral damage after aneurysmal subarachnoid hemorrhage (SAH) results from various, sometimes unrelated causes. After the initial hemorrhage trauma with an increase in intracranial pressure, induced vasoconstriction, but also microcirculatory disturbances, inflammation and pathological electrophysiological processes (cortical spreading depolarization) can occur in the course of the disease, resulting in delayed cerebral ischemia (DCI). In the neuroradiological context, cerebral vasospasm (CVS) remains the focus of diagnostic imaging and endovascular therapy as a frequent component of the genesis of DCI.

Methods The amount of blood leaked during aneurysm rupture (which can be detected by CT, for example) correlates with the occurrence and severity of CVS. CT perfusion is then an important component in determining the indication for

endovascular spasm therapies (EST). These include intra-arterial drug administration (also as long-term microcatheter treatment) and mechanical procedures (balloon angioplasty, vasodilatation using other instruments such as stent retrievers, stenting).

Conclusion This review summarizes the current findings on the diagnosis and treatment of CVS after aneurysmal SAH from a neuroradiological perspective, taking into account the complex and up-to-date international literature.

Key Points

- Vasospasm is a frequent component of the multifactorial genesis of delayed cerebral ischemia after SAH and remains the focus of diagnosis and treatment in the neuroradiological context.
- The initial extent of SAH on CT is associated with the occurrence and severity of vasospasm.
- CT perfusion is an important component in determining the indication for endovascular spasm therapy.
- Endovascular spasm therapies include local administration of medication (also as long-term therapies with microcatheters) and mechanical procedures (balloon angioplasty, dilatation using other devices such as stent retrievers, stenting).

Citation Format

- Neumann A, Schacht H, Schramm P. Neuroradiological diagnosis and therapy of cerebral vasospasm after subarachnoid hemorrhage. *Fortschr Röntgenstr* 2024; DOI 10.1055/a-2266-3117

ZUSAMMENFASSUNG

Hintergrund Die zerebrale Schädigung nach einer aneurysmatischen Subarachnoidalblutung (SAB) entsteht aus verschiedenen, teils unverbundenen Ursachen. Nach dem initialen Blutungstrauma mit Anstieg des intrakraniellen Drucks kann es im Verlauf zu einer induzierten Vasokonstriktion, aber auch zu Störungen der Mikrozirkulation, Inflammationen und pathologischen elektrophysiologischen Vorgängen (kortikale Streudepolarisation) mit der Folge einer verzögerten zerebralen Ischämie (= Delayed cerebral ischemia [DCI]) kommen. Im neuroradiologischen Kontext bleiben zerebrale Vasospasmen (ZVS) als häufiger Bestandteil der Genese von DCI im Fokus der bildgebenden Diagnostik und endovaskulären Therapie.

Methode Die Menge des bei der Aneurysmaruptur ausgetretenen Blutes (die z. B. durch das CT erfasst werden kann) korreliert mit Auftreten und Ausprägung von ZVS. Die CT-Perfusion ist dann ein wichtiger Baustein für die Indikationsstellung zu endovaskulären Spasmustherapien (EST). Diese beinhalten intraarterielle Medikamentengaben (auch als Mikrokatheterdauerbehandlung) und mechanische Verfahren

(Ballonangioplastie, Gefäßerweiterungen durch andere Instrumente wie z. B. Stentretreiver, Stenting).

Schlussfolgerung Die vorliegende Übersichtsarbeit stellt aus neuroradiologischer Sicht die gegenwärtigen Erkenntnisse zur Diagnostik und Therapie von ZVS nach aneurysmatischer SAB unter Berücksichtigung einer insgesamt komplexen und dabei auch der aktuellsten internationalen Literatur zusammen.

Introduction

After an aneurysmal subarachnoid hemorrhage (SAH), brain damage can occur for various, partly unrelated reasons. The initial bleeding trauma (early brain injury [EBI]) can result primarily in an increase in intracranial pressure with possibly fatal effects on cerebral perfusion pressure [1–3]. A secondary damage phase begins approximately on the third day after an SAH. Based on the multifactorial origin, delayed cerebral ischemia (DCI) has become established as the clinically defined term here. DCI occurs in approximately 40% of cases of SAH and includes complex processes resulting from EBI, arterial constrictions, microcirculatory dysfunction with loss of autoregulation, inflammatory changes, microthromboses, and pathological electrophysiological processes (cortical spreading depolarization) [4–6]. DCI often results in additional deaths or potentially severe disabilities.

In spite of the multifactorial origin of DCI, cerebral vasospasm (CVS) is still considered to be a frequent contributing factor. The spasms result from the effects of blood degradation products in the subarachnoid space with sustained contraction of the muscle cells of the vascular walls. They occur in approx. 50–90% of cases after SAH up to 10 days after the initial bleeding event [7, 8]. As an independent factor, CVS is significantly associated with infarction and a less favorable clinical outcome [9, 10]. However, only approximately 20–30% of patients with CVS develop clinical symptoms [11]. It is important to note that DCI can also occur independently of CVS [12]. In connection with DCI, CVS remains the main starting point both in diagnostic imaging and in endovascular treatment.

The guidelines of the American Heart Association (AHA)/American Stroke Association (ASA), which were last updated in 2023, recommend systemic administration of the calcium channel antagonist nimodipine for the prevention and treatment of CVS/DCI. Blood pressure and blood volume management is also mentioned in the guidelines as a possible method for treating CVS, with an increase in cardiac ejection fraction and maintenance of euvolemia being capable of limiting the progression and severity of DCI. However, prophylactic hemodynamic augmentation and hypervolemia should not be performed in order to minimize iatrogenic risks for patients [13]. Comparisons of the effectiveness of enteral and intravenous DCI prophylaxis with nimodipine cannot yet be definitively evaluated [14]. Moreover, intrathecal therapies are described in connection with CVS and have been endorsed with the focus being placed on nimodipine in the form of slow-release microparticles in addition to the use of, e. g., magnesium [13, 15, 16].

However, a clear recommendation is lacking here as for endovascular spasm therapy (EST). This is also due to the fact that to date there is no evidence of a positive effect on clinical outcome even though there are indications of an additional benefit of EST based on numerous at times complicated studies including meta-analyses [17–21]. Thus, there is also currently a lack of consensus-based guidelines regarding EST even though they are broadly implemented and include the intraarterial administration of medication (also in the form of continuous therapy with microcatheters) and mechanical vascular dilation (balloon angioplasty [BA], dilation by means of other instruments, e. g. stent retrievers, stenting).

Computed tomographic grading of aneurysmal SAH and effect of vasospasm/delayed cerebral ischemia

The Fisher grading system from the year 1980 is based in general on the assumption of a connection between the distribution of SAH on the initial CT scan and the development of CVS [22]. In the late 1980s and 1990s, analyses of the specific connection between the amount of blood and CVS/DCI and later also analyses of the exact influence of the site of the SAH were performed [23–25]. Consequently, a modified classification of the corresponding CT findings was created. The modified system additionally included the cisternal and intraventricular accumulation of blood and was promoted by the authors as being better for the prediction of CVS requiring treatment [26]. In light of the different classification systems, a systematic review with meta-analysis of these radiological classifications was recently published with the modified Fisher grading system proving to be most suitable for predicting symptomatic CVS [27]. The Vasograde, which was introduced in 2015, combines the modified Fisher grading system with the initial clinical classification of the World Federation of Neurosurgical Societies (WFNS), and provides 3 color-coded grades for evaluating DCI risk, is not taken into consideration [28].

► **Table 1** shows the comparison of the classic and modified computed tomographic grading of subarachnoid hemorrhage for the purpose of predicting symptomatic CVS.

► **Table 1** Comparison of classic and modified computed tomographic grading of a subarachnoid hemorrhage for the purpose of predicting symptomatic cerebral vasospasm. Its probability increases with higher degrees [22, 26].

SAH in CT	IVH	Fisher Grade	Modified Fisher-Grade
Diffuse thick	+	3	4
	-	3	3
Localized thick	+	3	4
	-	3	3
Diffuse thin	+	4	2
	-	2	2
Localized thin	+	4	2
	-	1	1
None	+	4	2
	-	1	0

SAH = subarachnoid hemorrhage, IVH = intraventricular hematoma.

Indication for endovascular spasm therapy

In general, every decision in favor of an EST must be precisely weighted because the risk of periprocedural complications as well as the organizational effort for intensive care units and possible risks due to the transport of unstable patients must be taken into consideration [29, 30]. Therefore, the selection criteria must be carefully reviewed.

Alert patients can typically undergo a neurological examination. In the case of sudden clinical worsening with a decreased level of consciousness and/or new deficits or increased flow rates or a temporary significant increase in flow rates on transcranial Doppler ultrasound (TCD) of the cerebral arteries, these patients can be diagnosed with DCI [31]. In the case of intubation or sedation, multimodal, invasive neuromonitoring including continuous measurement of intracranial and cerebral perfusion pressure and regional brain tissue oxygenation (oxygen partial pressure [PBrO₂]) is often performed. A refractory decrease in PBrO₂ and/or abnormalities on TCD indicate DCI. If these clinical signs persist in spite of intensified hemodynamic therapy in addition to systemic nimodipine administration, CT perfusion or digital subtraction angiography (DSA) should be performed. Constrictions of the cerebral arteries on angiography confirm symptomatic CVS and are thus a finding requiring endovascular treatment [8].

► **Fig. 1** shows a possible procedure for determining the indication for EST. The indication must be reviewed before every treatment session in the case of suspicion of symptomatic cerebral vasospasm. This also means that, after the individual indication for EST during the vulnerable spasm phase, additional intraarterial treatments do not necessarily need to be performed if symptomatic CVS is not suspected again.

Role of CT perfusion

CT perfusion plays an important role as a selection criterion for EST and can be considered a more objective imaging method than TCD with advantages regarding the accuracy of the diagnosis of CVS/DCI [32–34]. CT perfusion is typically performed in combination with CT angiography so that changes in microcirculation and macroscopically visible vasospasms can be visualized [35, 36]. In relation to CT perfusion, comparative studies have focused repeatedly on the value of individual parameter maps with the time to drain (TTD) and especially the mean transit time (MTT) proving to be particularly sensitive for pathological deviations [37–40]. In general, a prolonged MTT and reduced cerebral blood flow (CBF) indicate CVS [41] (► **Fig. 2**).

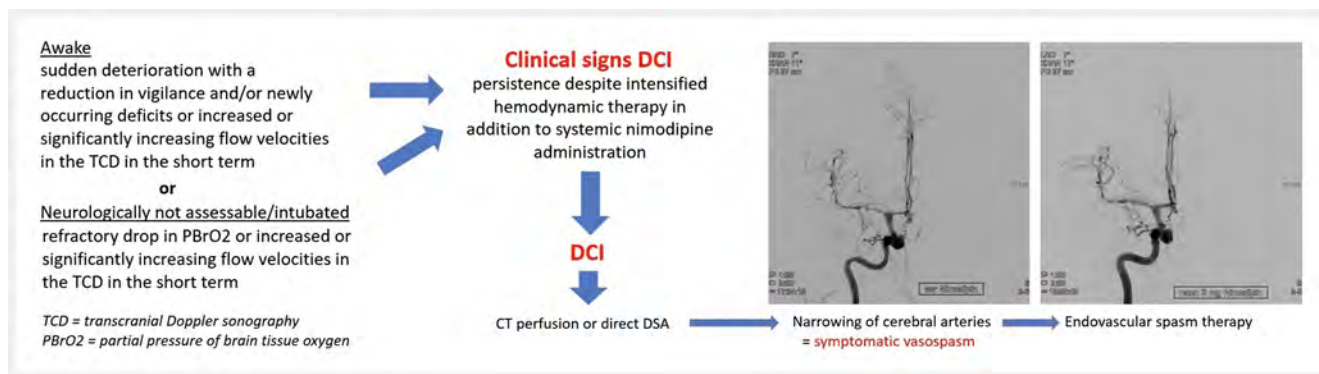
The need for initial CT perfusion as a baseline finding seems to have been disproved [39]. The value of CT perfusion acquired early, i. e., on day 1, 2, or 3 after SAH, to predict DCI was recently shown in a comprehensive meta-analysis. However, standardization of data acquisition was recommended [42]. This is discussed in the studies by Sanelli et al. and Westermaier et al., which specify specific parameter variations in CT perfusion as the selection criterion for EST but also explicitly state that scanner dependence must be taken into consideration [31, 43]. That being said, routine CT perfusion in intubated patients particularly in the high-risk phase, i. e., between day 6 and day 10 after SAH, undoubtedly has significant diagnostic value since hypoperfusion with an endovascular treatment option can be detected to a large extent [44]. Newer studies examined subtle changes in parameter maps between individual follow-up CT perfusion examinations [45, 46]. It is clear that better selection of EST based on CT perfusion will be the goal in the future. In addition to the need for standardization, the question of whether subtle dynamics of individual parameters in CT perfusion could perhaps lead to more customized treatment should be further investigated.

In light of the already mentioned overlaps between DCI and CVS, it must be noted that CT perfusion is sufficient for showing CVS and associated perfusion deficits but other factors resulting in DCI could have no correlate in this imaging method [5].

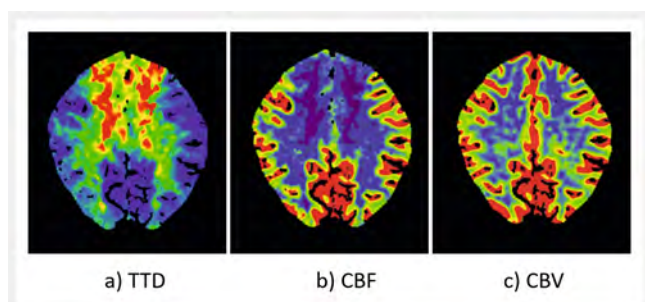
Endovascular spasm therapies

Medication

In the case of CVS, the dihydropyridine blocker nimodipine, which can block the flux of extracellular calcium through L-type, voltage-gated calcium channels particularly in smooth muscle cells, is a standout among the group of intraarterially administered medications [47, 48]. This drug is more effective when administered intraarterially than intravenously and a temporary improvement in cerebral perfusion has been described when using nimodipine for EST [49, 50]. In a comparison of CVS patients in initially poor clinical condition treated systemically and additionally intraarterially with nimodipine, published study results did not show any major differences so that the positive effect of such intraarterial therapy can be assumed [51]. We regularly use nimodipine for EST. We typically administer the medication via a catheter placed



► **Fig. 1** Proposal for the indication of endovascular spasm therapies.



► **Fig. 2** Example of symptomatic vasospasm of the anterior cerebral artery on both sides in CT perfusion with **a** prolonged time to drain (TTD), **b** delayed cerebral blood flow (CBF), and **c** normal cerebral blood volume (CBV).

in an extracranial artery upstream from the spasms (internal carotid artery and/or vertebral artery) with a dose of 1–5 mg diluted over a period of 30–60 minutes after systemic, weight-adapted heparinization (3000–5000 IU) [52].

Papaverine with its effect as a phosphodiesterase inhibitor is used less often, at least in Germany, for intraarterial vasospasm therapy even though study results have shown advantages compared to nimodipine [53, 54]. Medications that are effective on an intraarterial basis include the substances amrinone, milrinone, verapamil, nicardipine, fasudil hydrochloride, and a forskolin derivative [55–57]. In particular, the intraarterial use of milrinone and verapamil has already been sufficiently examined and has a positive effect on the course of CVS [58, 59]. Moreover, intraarterial infusion of prostaglandin E1 (Prostavasin) with its suspected effect primarily on peripheral CVS has already been systematically evaluated [60].

In individual institutions continuous treatment involving the intraarterial administration of medication via microcatheters is used to treat vasospasms. This is recommended particularly in severe otherwise treatment-refractory cases even under consideration of potentially serious side effects like thromboembolic events [61–63]. Therefore, such continuous intraarterial treatments involving the application of vasodilators for several days are more effective than short infusions even though systematic examinations including the specific comparison of these two endovascular methods are still lacking. In the case of continuous endovascular

infusions, most thromboembolic complications can be reliably prevented by ensuring technically correct implementation of the intraarterial infusion. However, this is not the case for the sometimes significant drop in blood pressure caused by the intraarterial administration of the above-mentioned medications.

Mechanical vascular dilation

Balloon angioplasty

Due to its direct effects on the biomechanics and structure of the arterial wall, BA promises longer-term effects and may thus result in a lower rate of vasospastic infarctions [64, 65]. We support the use of BA only in the case of severe spasms (> 50% constriction of the affected vessel compared to the baseline finding on catheter angiography) in the large cerebral arteries (including the proximal part of the second segment of the anterior cerebral artery and the middle cerebral artery). It should be used either on a primary basis in recurrent CVS after prior nimodipine instillation or on a secondary basis as a supplement to intraarterial nimodipine administration when the angiographic response is not sufficient (< 50% vascular dilation compared to the baseline angiogram provided that CVS was not yet present there). In the case of BA, both non-compliant and compliant balloon catheters are used for endovascular treatment of CVS. Systematic comparisons are not yet available. [52, 66]. In principle, BA carries the risk of severe periprocedural complications like thromboembolic infarctions and – especially in contrast to the purely intraarterial administration of medication – vascular rupture. However, there are significant differences in the literature regarding frequency (0–15%) [52, 66–69]. According to the results of our own studies, a non-negligible rate of recurrence of CVS can be seen after BA [52].

A comparison of the two types of EST most commonly used in Germany (intraarterial nimodipine and BA) is provided in ► **Table 2**.

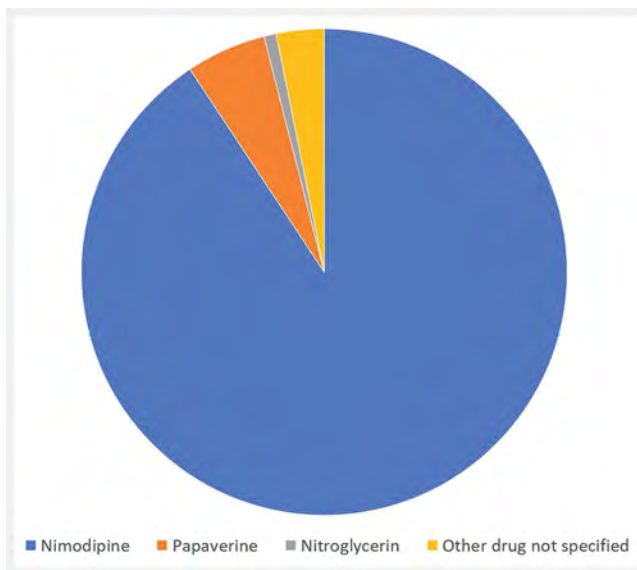
Other instruments

Stent retrievers to correct vascular constrictions can also be used for the intraarterial treatment of CVS [70]. In contrast to BA, no direct intimal damage is to be expected. Instead, a mechanical radial force is gradually exerted on the spastic vascular wall by means of self-expansion after release of the stent retriever

► **Table 2** Comparison of local nimodipine administration and balloon angioplasty for the treatment of cerebral vasospasm, taking into account our own study results. Balloon angioplasty is usually performed on a supplementary basis.

Type of endovascular spasm therapy (EST)	Local administration of nimodipine	Balloon angioplasty
Starting point on the vessel wall	Pharmacological dilatation of the smooth muscles	Mechanical intima disruption
Target vessels	Proximal and distal	Especially proximal
Good angiographic response	77 % (89 patients, 356 treated vessel segments) [69]	87 % (35 patients, 99 vessel segments [ACI n = 16, ACA n = 33, ACM n = 39, VAS n = 11]) [52]
Duration of therapeutic effect	Short-term	Longer-term, but recurrences possible in the spasm phase (16 %) [52]
Possible peri-interventional complications	M3 occlusion (total complication rate 2 %; 15 patients, 65 EST) [30]	M1 dissection (total complication rate 2 %; 35 patients, 41 EST) [52]

ICA = internal carotid artery, ACA = anterior cerebral artery, ACM = middle cerebral artery, VAS = vertebrobasilar arterial system.



► **Fig. 3** Illustration of the frequencies of intra-arterial medication administration in endovascular spasm therapies based on the nationwide registry data of the DeGIR and DGNR from 2018–2021 with evaluation of a total of 7628 interventions [54].

without the need for temporary occlusion. In addition, different novel non-occlusive stents are currently used for treating spasms [71–73]. In our institution we have had positive experiences with the Comaneci instrument with an adjustable and easy-to-control radial force for the endovascular treatment of CVS. Moreover, there are also descriptions of the use of stent angioplasty as an ultima ratio option for treating CVS. However, this strategy is limited to individual centers [74].

► **Fig. 3, 4** show the frequencies of intraarterial medication administration and the types of EST based on an evaluation of national registry data of the German Society for Interventional Radiology and Minimally Invasive Therapy (DeGIR) and the Ger-

man Society for Neuroradiology (DGNR) from the years 2018–2021 [54].

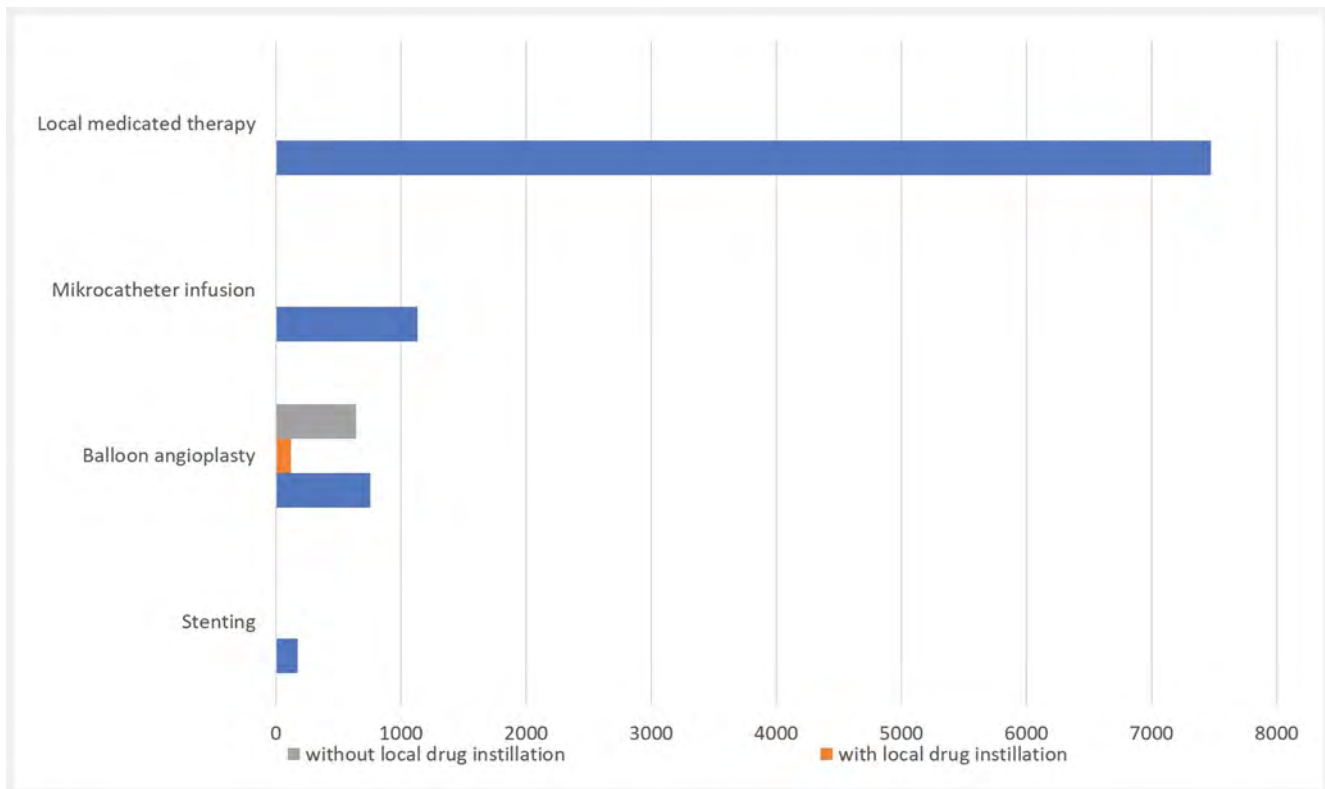
Summary

Given the not yet fully understood and complex origin especially of DCI, CVS is still to be considered a central component of brain damage after SAH. For neuroradiologists, CVS after aneurysm rupture therefore remains the main starting point both in diagnostic imaging and in endovascular treatment.

In the initial CT examination, there are different classifications of SAH with the goal of assessing prognosis. The modified Fisher grading system has proven to be most suitable for predicting symptomatic CVS [27].

Further standardization should be targeted in the future for selecting patients with an indication for EST. CT perfusion is useful primarily in the middle and late vasospasm phases at the latest as of day 6 after the bleeding event, particularly in intubated patients [44]. The dynamics of quantitative parameters will become increasingly important as a selection criterion in CT perfusion. Therefore, the possibility of more individualized treatment steps will presumably also be investigated [45, 46]. TCD is still a helpful additional diagnostic parameter but does not seem to be reliable on its own for detecting CVS: Thus, a meta-analysis including 18 studies showed evidence supporting this method only in the case of spasms in the middle cerebral artery [75]. In the angio suite, greater weighting of standardized classifications of CVS is an interesting starting point for the future also for the optimization of endovascular treatments for individual vessels [76, 77].

Specifically in relation to EST, treatment with intraarterially administered medications continues to dominate. A systematic evaluation of the joint registry data of the DeGIR and DGNR on the treatment of intraarterial spasm in Germany showed a possible advantage of papaverine compared to nimodipine [54]. However, the low level of evidence of these results should be noted. They merely represent an overview of the current care situation



► **Fig. 4** Illustration of the frequencies of the general types of endovascular spasm therapies based on the nationwide registry data of the DeGIR and DGNR from 2018–2021 with evaluation of a total of 7628 interventions [54].

with intraarterial spasm treatments and thus provide a general picture. The action profiles of individual intraarterially administered substances in EST as well as investigation of the time effects of new instruments for the mechanical expansion of CVS should be the topic of future scientific studies.

With respect to the treatment of posthemorrhagic vasospasm, there is currently still significant heterogeneity regarding the implementation of EST [47]. Insight from meta-analyses, Cochrane reviews, and multinational registry databases should still be taken into consideration for standardization and large randomized studies should be performed [13, 78]. However, the path to definitive evidence supporting EST is still long which can be attributed to the repeatedly sobering results of individual studies on this topic [79, 80]. However, interdisciplinary guidelines on the standardization of diagnostic and treatment procedures would already be helpful now and, in our opinion, would be able to be implemented rather quickly. At present, such requirements could unfortunately only reflect the limited treatment options for CVS/DCI. We currently do not know how to reliably prevent disability or death due to the secondary complications of SAH. While microsurgical and endovascular aneurysm treatment has undoubtedly significantly improved the chance of survival after an intracranial aneurysmal hemorrhage in the last 30 years, these primarily adequately treated patients are still at significant risk in the spasm phase.

Conflict of Interest

The authors declare that they have no conflict of interest.

References

- [1] Lauzier DC, Jayaraman K, Yuan JY et al. Early Brain Injury After Subarachnoid Hemorrhage: Incidence and Mechanisms. *Stroke* 2023; 54 (5): 1426–1440
- [2] Alsbrook DL, Di Napoli M, Bhatia K et al. Pathophysiology of Early Brain Injury and Its Association with Delayed Cerebral Ischemia in Aneurysmal Subarachnoid Hemorrhage: A Review of Current Literature. *J Clin Med* 2023; 12 (3): 1015
- [3] Dodd WS, Laurent D, Dumont AS et al. Pathophysiology of Delayed Cerebral Ischemia After Subarachnoid Hemorrhage: A Review. *J Am Heart Assoc* 2021; 10 (15): e021845
- [4] Østergaard L, Aamand R, Karabegovic S et al. The Role of the Microcirculation in Delayed Cerebral Ischemia and Chronic Degenerative Changes after Subarachnoid Hemorrhage. *Cereb Blood Flow Metab* 2013; 33 (12): 1825–1837
- [5] Budohoski KP, Guilfoyle M, Helmy A et al. The pathophysiology and treatment of delayed cerebral ischaemia following subarachnoid haemorrhage. *J Neurol Neurosurg Psychiatry* 2014; 85 (12): 1343–1353
- [6] Dreier JP, Winkler MKL, Major S et al. Spreading depolarizations in ischaemia after subarachnoid haemorrhage, a diagnostic phase III study. *Brain* 2022; 145 (4): 1264–1284

- [7] Li K, Barras CD, Chandra RV et al. A Review of the Management of Cerebral Vasospasm After Aneurysmal Subarachnoid Hemorrhage. *World Neurosurg* 2019; 126: 513–527
- [8] Vergouwen MD, Vermeulen M, van Gijn J et al. Definition of delayed cerebral ischemia after aneurysmal subarachnoid hemorrhage as an outcome event in clinical trials and observational studies: proposal of a multidisciplinary research group. *Stroke* 2010; 41 (10): 2391–2395
- [9] Ferguson S, Macdonald RL. Predictors of cerebral infarction in patients with aneurysmal subarachnoid hemorrhage. *Neurosurgery* 2007; 60 (4): 658–667
- [10] Vergouwen MD, Ildigwe D, Macdonald RL. Cerebral infarction after subarachnoid hemorrhage contributes to poor outcome by vasospasm-dependent and -independent effects. *Stroke* 2011; 42 (4): 924–929
- [11] Dehdashti AR, Mermillod B, Rufenacht DA et al. Does treatment modality of intracranial ruptured aneurysms influence the incidence of cerebral vasospasm and clinical outcome? *Cerebrovasc Dis* 17 (1): 53–60
- [12] Rabinstein AA, Friedman JA, Weigand SD et al. Predictors of cerebral infarction in aneurysmal subarachnoid hemorrhage. *Stroke* 2004; 35 (8): 1862–1866
- [13] Hoh BL, Ko NU, Amin-Hanjani S et al. 2023 Guideline for the Management of Patients With Aneurysmal Subarachnoid Hemorrhage: A Guideline From the American Heart Association/American Stroke Association. *Stroke* 2023; 54 (7): e314–e370
- [14] Geraldini F, De Cassai A, Diana P et al. A Comparison Between Enteral and Intravenous Nimodipine in Subarachnoid Hemorrhage: A Systematic Review and Network Meta-Analysis. *Neurocrit Care* 2022; 36 (3): 1071–1079
- [15] Grossen AA, Ernst GL, Bauer AM. Update on intrathecal management of cerebral vasospasm: a systematic review and meta-analysis. *Neurosurg Focus* 2022; 52 (3): E10
- [16] Etminan N, Macdonald RL, Davis C et al. Intrathecal application of the nimodipine slow-release microparticle system eg-1962 for prevention of delayed cerebral ischemia and improvement of outcome after aneurysmal subarachnoid hemorrhage. *Acta Neurochir Suppl* 2015; 120: 281–286
- [17] Boulouis G, Labeyrie MA, Raymond J et al. Treatment of cerebral vasospasm following aneurysmal subarachnoid haemorrhage: a systematic review and meta-analysis. *Eur Radiol* 2017; 27 (8): 3333–3342
- [18] Venkatraman A, Khawaja AM, Gupta S et al. Intra-arterial vasodilators for vasospasm following aneurysmal subarachnoid hemorrhage: a meta-analysis. *J Neurointerv Surg* 2018; 10 (4): 380–387
- [19] Weiss M, Conzen C, Mueller M et al. Endovascular Rescue Treatment for Delayed Cerebral Ischemia After Subarachnoid Hemorrhage Is Safe and Effective. *Front Neurol* 2019; 10: 136
- [20] Jabbarli R, Pierscianek D, Rözl R et al. Endovascular treatment of cerebral vasospasm after subarachnoid hemorrhage: More is more. *Neurology* 2019; 93 (5): e458–e466
- [21] Mielke D, Döring K, Behme D et al. The Impact of Endovascular Rescue Therapy on the Clinical and Radiological Outcome After Aneurysmal Subarachnoid Hemorrhage: A Safe and Effective Treatment Option for Hemodynamically Relevant Vasospasm? *Front Neurol* 2022; 13: 838456
- [22] Fisher CM, Kistler JP, Davis JM. Relation of cerebral vasospasm to subarachnoid hemorrhage visualized by computerized tomographic scanning. *Neurosurgery* 1980; 6 (1): 1–9
- [23] Hijdra A, van Gijn J, Nagelkerke NJ et al. Prediction of delayed cerebral ischemia, rebleeding, and outcome after aneurysmal subarachnoid hemorrhage. *Stroke* 1988; 19 (10): 1250–1256
- [24] Brouwers PJ, Dippel DW, Vermeulen M et al. Amount of blood on computed tomography as an independent predictor after aneurysm rupture. *Stroke* 1993; 24 (6): 809–814
- [25] Nomura Y, Kawaguchi M, Yoshitani K et al. Retrospective analysis of predictors of cerebral vasospasm after ruptured cerebral aneurysm surgery: influence of the location of subarachnoid blood. *J Anesth* 2010; 24 (1): 1–6
- [26] Frontera JA, Claassen J, Schmidt JM et al. Prediction of symptomatic vasospasm after subarachnoid hemorrhage: the modified fisher scale. *Neurosurgery* 2006; 59 (1): 21–27
- [27] van der Steen WE, Leemans EL, van den Berg R et al. Radiological scales predicting delayed cerebral ischemia in subarachnoid hemorrhage: systematic review and meta-analysis. *Neuroradiology* 2019; 61 (3): 247–256
- [28] de Oliveira Manoel AL, Jaja BN, Germans MR et al. SAHIT collaborators. The VASOGRADE: A Simple Grading Scale for Prediction of Delayed Cerebral Ischemia After Subarachnoid Hemorrhage. *Stroke* 2015; 46 (7): 1826–1831
- [29] Neumann A, Ditz C, Schacht H et al. Symptomatic Cerebral Vasospasm after Spontaneous Subarachnoid Hemorrhage: Comparison of Single and Multiple Intra-arterial Treatment with Respect to the Functional Outcome. *J Neurol Surg A Cent Eur Neurosurg* 2020; 81 (3): 220–226
- [30] Ditz C, Neumann A, Wojak J et al. Repeated Endovascular Treatments in Patients with Recurrent Cerebral Vasospasms After Subarachnoid Hemorrhage: A Worthwhile Strategy? *World Neurosurg* 2018; 112: e791–e798
- [31] Westermaier T, Pham M, Stetter C et al. Value of transcranial Doppler, perfusion-CT and neurological evaluation to forecast secondary ischemia after aneurysmal SAH. *Neurocrit Care* 2014; 20 (3): 406–412
- [32] Binaghi S, Colleoni ML, Maeder P et al. CT angiography and perfusion CT in cerebral vasospasm after subarachnoid hemorrhage. *AJNR Am J Neuroradiol* 2007; 28 (4): 750–758
- [33] Romenskaya T, Longhitano Y, Piccolella F et al. Cerebral Vasospasm: Practical Review of Diagnosis and Management. *Rev Recent Clin Trials* 2023; 18 (1): 12–18
- [34] Darsaut TE, Keough MB, Chan AM et al. Transcranial Doppler Velocities and Angiographic Vasospasm after SAH: A Diagnostic Accuracy Study. *AJNR Am J Neuroradiol* 2022; 43 (1): 80–86
- [35] Zhang H, Zhang B, Li S et al. Whole brain CT perfusion combined with CT angiography in patients with subarachnoid hemorrhage and cerebral vasospasm. *Clin Neurol Neurosurg* 2013; 115 (12): 2496–2501
- [36] Letourneau-Guillon L, Farzin B, Darsaut TE et al. Reliability of CT Angiography in Cerebral Vasospasm: A Systematic Review of the Literature and an Inter- and Intraobserver Study. *AJNR Am J Neuroradiol* 2020; 41 (4): 612–618
- [37] Turowski B, Haenggi D, Wittsack J et al. Die zerebrale Perfusions-Computertomografie beim Vasospasmus nach Subarachnoidalblutung: Diagnostischer Wert der MTT [Cerebral perfusion computerized tomography in vasospasm after subarachnoid hemorrhage: diagnostic value of MTT]. *Fortschr Röntgenstr* 2007; 179 (8): 847–854
- [38] Othman AE, Afat S, Nikoubashman O et al. Volume perfusion CT imaging of cerebral vasospasm: diagnostic performance of different perfusion maps. *Neuroradiology* 2016; 58 (8): 787–792
- [39] Vulcu S, Wagner F, Santos AF et al. Repetitive Computed Tomography Perfusion for Detection of Cerebral Vasospasm-Related Hypoperfusion in Aneurysmal Subarachnoid Hemorrhage. *World Neurosurg* 2019; 121: e739–e746
- [40] Murphy A, Lee TY, Marotta TR et al. Prospective Multicenter Study of Changes in MTT after Aneurysmal SAH and Relationship to Delayed Cerebral Ischemia in Patients with Good- and Poor-Grade Admission Status. *AJNR Am J Neuroradiol* 2018; 39 (11): 2027–2033
- [41] Greenberg ED, Gold R, Reichman M et al. Diagnostic accuracy of CT angiography and CT perfusion for cerebral vasospasm: a meta-analysis. *AJNR Am J Neuroradiol* 2010; 31 (10): 1853–1860

- [42] Han H, Chen Y, Li R et al. The value of early CT perfusion parameters for predicting delayed cerebral ischemia after aneurysmal subarachnoid hemorrhage: a systematic review and meta-analysis. *Neurosurg Rev* 2022; 45 (4): 2517–2531
- [43] Sanelli PC, Ugorec I, Johnson CE et al. Using quantitative CT perfusion for evaluation of delayed cerebral ischemia following aneurysmal subarachnoid hemorrhage. *AJNR Am J Neuroradiol* 2011; 32 (11): 2047–2053
- [44] Ditz C, Hartlieb M, Neumann A et al. Routine use of perfusion computed tomography for the detection of delayed cerebral ischemia in unconscious patients after aneurysmal subarachnoid hemorrhage. *Acta Neurochir (Wien)* 2021; 163 (1): 151–160
- [45] Hofmann BB, Fischer I, Engel A et al. MTT Heterogeneity in Perfusion CT Imaging as a Predictor of Outcome after Aneurysmal SAH. *AJNR Am J Neuroradiol* 2021; 42 (8): 1387–1395
- [46] You F, Tang WJ, Zhang C et al. Whole-brain CT Perfusion at Admission and During Delayed Time-window Detects the Delayed Cerebral Ischemia in Patients with Aneurysmal Subarachnoid Hemorrhage. *Curr Med Sci* 2023; 43 (2): 409–416
- [47] Guenego A, Fahed R, Rouchaud A et al. Research Committee of the European Society of Minimally Invasive Neurological Therapy (ESMINT). Diagnosis and endovascular management of vasospasm after aneurysmal subarachnoid hemorrhage – survey of real-life practices. *J Neurointerv Surg* 2023. doi:10.1136/jnirs-2023-020544
- [48] Carlson AP, Hänggi D, Macdonald RL et al. Nimodipine Reappraised: An Old Drug With a Future. *Curr Neuropharmacol* 2020; 18 (1): 65–82
- [49] Hänggi D, Turowski B, Beseoglu K et al. Intra-arterial nimodipine for severe cerebral vasospasm after aneurysmal subarachnoid hemorrhage: influence on clinical course and cerebral perfusion. *AJNR Am J Neuroradiol* 2008; 29 (6): 1053–1060
- [50] Hasegawa S, Hasegawa Y, Miura M. Current Therapeutic Drugs Against Cerebral Vasospasm after Subarachnoid Hemorrhage: A Comprehensive Review of Basic and Clinical Studies. *Curr Drug Deliv* 2017; 14 (6): 843–852
- [51] Walter J, Grutza M, Möhlenbruch M et al. The Local Intraarterial Administration of Nimodipine Might Positively Affect Clinical Outcome in Patients with Aneurysmal Subarachnoid Hemorrhage and Delayed Cerebral Ischemia. *J Clin Med* 2022; 11 (7): 2036
- [52] Schacht H, Küchler J, Boppel T et al. Transluminal balloon angioplasty for cerebral vasospasm after spontaneous subarachnoid hemorrhage: A single-center experience. *Clin Neurol Neurosurg* 2020; 188: 105590
- [53] Kerz T, Boor S, Beyer C et al. Effect of intraarterial papaverine or nimodipine on vessel diameter in patients with cerebral vasospasm after subarachnoid hemorrhage. *Br J Neurosurg* 2012; 26 (4): 517–524
- [54] Neumann A, Weber W, Küchler J et al. Evaluation of DeGIR registry data on endovascular treatment of cerebral vasospasm in Germany 2018–2021: an overview of the current care situation. *Fortschr Röntgenstr* 2023; 195 (11): 1018–1026
- [55] Fraticelli AT, Cholley BP, Losser MR et al. Milrinone for the treatment of cerebral vasospasm after aneurysmal subarachnoid hemorrhage. *Stroke* 2008; 39 (3): 893–898
- [56] Keuskamp J, Murali R, Chao KH. High-dose intraarterial verapamil in the treatment of cerebral vasospasm after aneurysmal subarachnoid hemorrhage. *J Neurosurg* 2008; 108 (3): 458–463
- [57] Dabus G, Nogueira RG. Current options for the management of aneurysmal subarachnoid hemorrhage-induced cerebral vasospasm: a comprehensive review of the literature. *Interv Neurol* 2013; 2 (1): 30–51
- [58] Lakhali K, Hivert A, Alexandre PL et al. Intravenous Milrinone for Cerebral Vasospasm in Subarachnoid Hemorrhage: The MILRISPASM Controlled Before-After Study. *Neurocrit Care* 2021; 35 (3): 669–679
- [59] Sehy JV, Holloway WE, Lin SP et al. Improvement in angiographic cerebral vasospasm after intra-arterial verapamil administration. *AJNR Am J Neuroradiol* 2010; 31 (10): 1923–1928
- [60] Rasmussen R, Wetterslev J, Stavngaard T et al. Effects of prostacyclin on cerebral blood flow and vasospasm after subarachnoid hemorrhage: randomized, pilot trial. *Stroke* 2015; 46 (1): 37–41
- [61] Kapapa T, König R, Mayer B et al. Adverse Events and Complications in Continuous Intra-arterial Nimodipine Infusion Therapy After Aneurysmal Subarachnoid Hemorrhage. *Front Neurol* 2022; 12: 812898
- [62] Anthofer J, Bele S, Wendl C et al. Continuous intra-arterial nimodipine infusion as rescue treatment of severe refractory cerebral vasospasm after aneurysmal subarachnoid hemorrhage. *J Clin Neurosci* 2022; 96: 163–171
- [63] Kramer A, Selbach M, Kerz T et al. Continuous Intraarterial Nimodipine Infusion for the Treatment of Delayed Cerebral Ischemia After Aneurysmal Subarachnoid Hemorrhage: A Retrospective, Single-Center Cohort Trial. *Front Neurol* 2022; 13: 829938
- [64] Keris V, Ozolanta I, Enina G et al. Biomechanical and structural assessment of transluminal angioplasty. *Med Eng Phys* 1998; 20 (5): 339–346
- [65] Jestaedt L, Pham M, Bartsch AJ et al. The impact of balloon angioplasty on the evolution of vasospasm-related infarction after aneurysmal subarachnoid hemorrhage. *Neurosurgery* 2008; 62 (3): 610–617
- [66] Neumann A, Küchler J, Ditz C et al. Non-compliant and compliant balloons for endovascular rescue therapy of cerebral vasospasm after spontaneous subarachnoid haemorrhage: experiences of a single-centre institution with radiological follow-up of the treated vessel segments. *Stroke Vasc Neurol* 2021; 6 (1): 16–24
- [67] Adami D, Berkefeld J, Platz J et al. Complication rate of intraarterial treatment of severe cerebral vasospasm after subarachnoid hemorrhage with nimodipine and percutaneous transluminal balloon angioplasty: Worth the risk? *J Neuroradiol* 2019; 46 (1): 15–24
- [68] Chalouhi N, Tjoumakaris S, Thakkar V et al. Endovascular management of cerebral vasospasm following aneurysm rupture: outcomes and predictors in 116 patients. *Clin Neurol Neurosurg* 2014; 118: 26–31
- [69] Schacht H, Küchler J, Neumann A et al. Analysis of Angiographic Treatment Response to Intra-Arterial Nimodipine Bolus Injection in Patients with Medically Refractory Cerebral Vasospasm After Spontaneous Subarachnoid Hemorrhage. *World Neurosurg* 2022; 162: e457–e467
- [70] Hensler J, Wodarg F, Madjidyar J et al. Efficacy and safety in the use of stent-retrievers for treatment of cerebral vasospasms after subarachnoid hemorrhage. *Interv Neuroradiol* 2023; 29 (3): 277–284
- [71] Salem MM, Khalife J, Desai S et al. COManeci MechANical dilation for vasospasm (COMMAND): multicenter experience. *J Neurointerv Surg* 2022; 15 (9): 864–870
- [72] Gupta R, Woodward K, Fiorella D et al. VITAL Study Investigators. Primary results of the Vesalio NeVa VS for the Treatment of Symptomatic Cerebral Vasospasm following Aneurysm Subarachnoid Hemorrhage (VITAL) Study. *J Neurointerv Surg* 2022; 14 (8): 815–819
- [73] Bhogal P, Simpanen T, Wong K et al. Use of the Cascade expandable net to treat cerebral vasospasm – initial clinical experience from a single centre with in vitro benchside tests. *CVIR Endovasc* 2021; 4 (1): 82
- [74] Khanafer A, Cimpoca A, Bhogal P et al. Intracranial stenting as a bail-out option for posthemorrhagic cerebral vasospasm: a single-center experience with long-term follow-up. *BMC Neurol* 2022; 22 (1): 351
- [75] Mastantuono JM, Combescure C, Elia N et al. Transcranial Doppler in the Diagnosis of Cerebral Vasospasm: An Updated Meta-Analysis. *Crit Care Med* 2018; 46 (10): 1665–1672
- [76] Merkel H, Lindner D, Gaber K et al. Standardized Classification of Cerebral Vasospasm after Subarachnoid Hemorrhage by Digital Subtraction Angiography. *J Clin Med* 2022; 11 (7): 2011
- [77] Halama D, Merkel H, Werdehausen R et al. Reference Values of Cerebral Artery Diameters of the Anterior Circulation by Digital Subtraction Angiography: A Retrospective Study. *Diagnostics (Basel)* 2022; 12 (10): 2471

- [78] Salazar-Díaz LC, Lozano-Castillo A, Neira-Escobar F et al. Endovascular treatment versus standard management for cerebral vasospasm after aneurysmal subarachnoid haemorrhage (Protocol). *Cochrane Database of Systematic Reviews* 2020; (8). doi:10.1002/14651858.CD013713
- [79] Vatter H, Güresir E, König R et al. Invasive Diagnostic and Therapeutic Management of Cerebral VasoSpasm after Aneurysmal Subarachnoid Hemorrhage (IMCVS)-A Phase 2 Randomized Controlled Trial. *J Clin Med* 2022; 11 (20): 6197
- [80] Burth S, Meis J, Kronsteiner D et al. Outcome analysis for patients with subarachnoid hemorrhage and vasospasm including endovascular treatment. *Neurol Res Pract* 2023; 5 (1): 57