

# Value of contrast-enhanced sonography in the diagnosis of vesicoureteral reflux

## Stellenwert der Kontrastmittelgestützten Sonografie in der Diagnostik des vesikoureteralen Refluxes

### Authors

Patrick Conen<sup>1,2</sup>, Janine Thiemann<sup>1,2</sup>, Regina Stredle<sup>3</sup>, Dirk Andre Clevert<sup>1,2</sup>

### Affiliations

- 1 Department of Radiology, Ludwig Maximilians University Munich, München, Germany
- 2 Interdisciplinary Ultrasound-Center, Ludwig Maximilians University Munich, München, Germany
- 3 Department of Urology, Ludwig Maximilians University Munich, München, Germany

### Keywords

contrast agents, bladder, ureter, ultrasound

received 7.7.2023

accepted 19.12.2023

published online 2024

### Bibliography

Fortschr Röntgenstr

DOI 10.1055/a-2254-5490

ISSN 1438-9029

© 2024, Thieme. All rights reserved.

Georg Thieme Verlag KG, Rüdigerstraße 14, 70469 Stuttgart, Germany

### Correspondence

Herr Dr. Patrick Conen

Radiology, University Hospital of Munich Grosshadern Campus, Marchioninistraße 15, 81377 Munich, Germany  
Tel.: +49/1 51 72 04 39 63  
conenpatrick@outlook.de

### ABSTRACT

**Background** Contrast-enhanced ultrasound of the urinary tract and bladder (ceVUS) is an alternative examination method to micturition cysturethrography (MCU/VCUG) for suspected vesicoureteral reflux (VUR) that is increasing in practice. The purpose of this review is to present the current value of ceVUS in the diagnosis.

**Method** A systematic literature search was performed using the keywords “vesicoureteral reflux”, “ceVUS”, “VCUG” of the databases MEDLINE and Cochrane Library as well as a review of current German, European, and American guidelines on this topic. In addition, recommendations for action in clinical practice were developed.

**Conclusion** ceVUS is a quick-to-learn examination method that is equivalent to VCUG for the diagnosis of vesicoureteral reflux and should be used as the diagnostic method of first choice when available given the absence of radiation exposure.

### Key Points

- Like VCUG, ceVUS is the diagnostic method of first choice in suspected vesicoureteral reflux and should be used preferentially given the absence of radiation exposure.
- Especially in comparison to the alternative VCUG, ceVUS is a quick-to-learn examination method.
- ceVUS can also be used to diagnose other pathologies of the lower urinary tract.

### Citation Format

- Conen P, Thiemann J, Stredle R et al. Value of contrast-enhanced sonography in the diagnosis of vesicoureteral reflux. Fortschr Röntgenstr 2024; DOI 10.1055/a-2254-5490

### ZUSAMMENFASSUNG

**Hintergrund** Kontrastmittelgestützter Ultraschall der ableitenden Harnwege und der Harnblase (ceVUS) ist eine in der Praxis zunehmende alternative Untersuchungsmethode zur Miktionscysturethrografie (MCU/VCUG) bei dem Verdacht auf einen vesikoureteralen Reflux (VUR). In dieser Übersichtsarbeit soll der aktuelle Stellenwert der ceVUS in der Diagnosestellung dargestellt werden.

**Methode** Es erfolgte eine systematische Literaturrecherche mit den Stichwörtern „vesicoureteral reflux“, „ceVUS“, „VCUG“ der Datenbanken MEDLINE und Cochrane Library sowie eine Aufarbeitung der aktuellen deutschen, europäischen und amerikanischen Leitlinien zu diesem Thema. Darüber hinaus wurden Handlungsempfehlungen für den klinischen Alltag erarbeitet.

**Schlussfolgerung** Die ceVUS ist eine schnell zu erlernende Untersuchung, die der VCUG in der Diagnostik des vesikoureteralen Refluxes gleichzusetzen ist und bei fehlender Strahlenbelastung bei Verfügbarkeit als Diagnostik der ersten Wahl eingesetzt werden sollte.

## Introduction

Vesicoureteral reflux (VUR) is the non-physiological backward flow of urine from the bladder into the ureters due to an absence of preventive mechanisms [1]. This lack of preventive mechanisms can be either congenital (primary) or acquired (secondary) [2].

With an incidence of 0.4–1.8%, a primary genesis of vesicoureteral reflux is most common. Incomplete closure of the vesicoureteral junction with a shortened intravesical portion of the ureter occurs during embryogenesis [3].

The diagnosis of vesicoureteral reflux is typically made as part of expanded diagnostic testing in the case of prenatal suspicion or recurrent febrile urinary tract infections and more rarely in the case of voiding dysfunction or known hereditary predisposition [4]. The probability of vesicoureteral reflux after a urinary tract infection is age-dependent [4]. Further risk factors for vesicoureteral reflux include ethnicity, gender, and a genetic/hereditary predisposition [5].

Secondary causes can be normal anatomical variants (subvesical obstruction), functional disorders (bladder-bowel dysfunction), or a neurogenic voiding dysfunction [6].

## Symptoms and initial diagnostic steps

Since patients with vesicoureteral reflux at a very young age often have recurrent urinary tract infections, the first diagnostic measure is typically ultrasound of the kidneys and the urinary tract. According to the S2K guidelines of the German Society for Pediatric Nephrology, an ultrasound examination should be performed within 24 hours after the onset of a febrile urinary tract infection for orientation purposes [4]. Scarring, inflammation, and urinary tract dilation can be diagnosed here.

Indirect signs of vesicoureteral reflux on B-mode ultrasound include parenchymal defects (as part of reflux nephropathy), usually seen as wedge-shaped defects with retraction of the renal parenchyma and enlarged renal calyces, a pronounced volume difference of the kidneys, nephromegaly as part of a urinary tract infection, prevesical dilation of the ureter, dilation of the renal pelvis with varying widths depending on the bladder filling, as well as a positive urothelial sign [4]. A comparison of the two kidneys is helpful here. However, the sensitivity and specificity of B-mode ultrasound for diagnosing vesicoureteral reflux is not particularly high so that a normal ultrasound examination does not rule out vesicoureteral reflux and a positive urothelial sign is not necessarily indicative of vesicoureteral reflux [7].

## Indication for reflux testing

The indications for reflux testing varied between the American and European pediatric and urological societies, but these have been adapted somewhat in recent years.

The current recommendation of the various professional societies is to perform reflux testing in children under the age of two years in the case of two occurrences of pyelonephritis and normal B-mode ultrasound examinations in order to avoid excessive diag-

nostic measures after a single occurrence of pyelonephritis. Further indications are an abnormal B-mode ultrasound examination with indirect signs of vesicoureteral reflux (B-mode ultrasound should be performed after the first febrile urinary tract infection as mentioned above) and an abnormal microbiological finding of non-E. coli infections [4, 8, 9]. A further indication is the diagnosis of vesicoureteral reflux in first degree relatives.

## Possibilities for reflux testing

Diagnostic possibilities for direct detection of vesicoureteral reflux include voiding cystourethrography (VCUG), contrast-enhanced voiding urosonography (ceVUS), and radionuclide cystography (RNC) [10]. There are also additional nuclear medicine methods that can diagnose the complications of vesicoureteral reflux, like [99Tc]DMSA-scintigraphy of the kidneys to evaluate possible parenchymal damage [11].

## Classification of vesicoureteral reflux

There are five grades of vesicoureteral reflux. This classification was published in 1985 by Lebowitz et al. and is recognized by various guidelines [12]. The classification system is described in ► **Table 1**. Higher-grade vesicoureteral reflux is associated with intrarenal reflux (IRR), which causes a pathological backward flow of urine into the renal parenchyma.

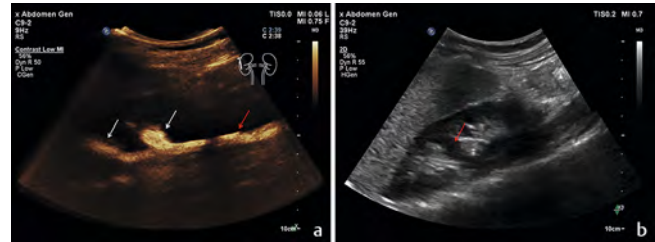
Vesicoureteral reflux is difficult to evaluate in the case of an additional obstruction in the region of the urinary tract. Tortuous ureters can also occur in the case of an obstruction and suggest higher grade vesicoureteral reflux [13]. It is not always easy to differentiate between the different grades of vesicoureteral reflux since the transitions between the grades are fluid. ► **Fig. 1** shows a contrast-enhanced image of grade II vesicoureteral reflux in the proximal ureter and renal pelvis with no dilation of the renal pelvis and with minor dilation of the proximal ureter. Dilation of the renal pelvis must be present for the reflux to be classified as grade III. The classification in ► **Fig. 2** as vesicoureteral reflux grade II is clearer but with a bifid ureter in duplex kidney. ► **Fig. 3** also shows grade II vesicoureteral reflux but in this case with a mixed mode image with overlay of the contrast-enhanced image and the B-mode image.

► **Fig. 4** shows a seven-year-old female patient with suspicion of vesicoureteral reflux after recurrent pyelonephritis. The transition between the different grades is also fluid here. Based on the indication of dilation of a renal calyx but the lack of pronounced dilation of the renal pelvis and the ureter, grade III classification was assigned.

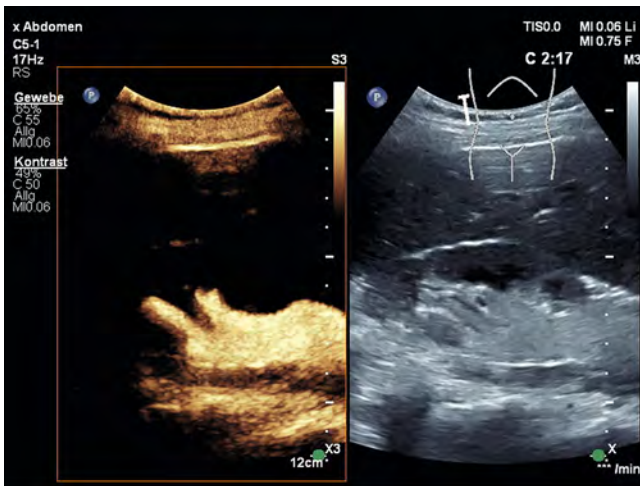
The higher the grade of disease, the clearer the diagnosis. ► **Fig. 5** shows vesicoureteral reflux grade IV in a 6-year-old female patient with recurrent pyelonephritis with mild impression but preserved papillary form and significantly enlarged renal calyces. ► **Fig. 6** shows marked impressions with a loss of the papillae, which is consistent with grade V vesicoureteral reflux. The origin of the proximal ureter must be additionally documented when deciding to surgically treat higher grade vesicoureteral reflux.

► **Table 1** Classification of vesicoureteral reflux according to Lebowitz.

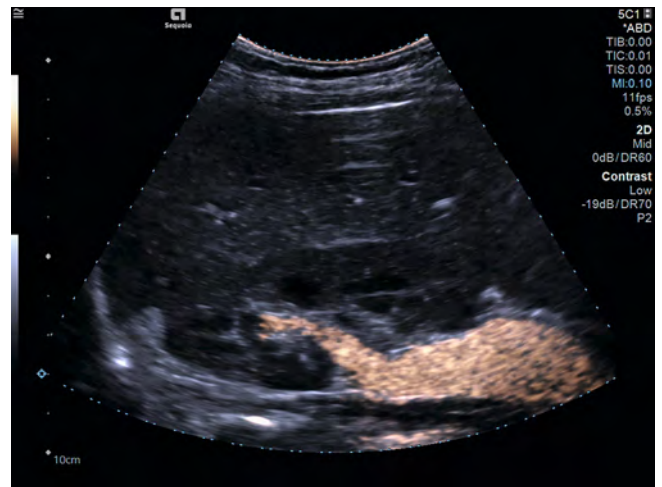- Grade 1:** Reflux only into the non-dilated ureter.
- Grade 2:** Reflux into the ureter and the renal pelvis without dilatation.
- Grade 3:** Reflux into the ureter (with or without kinking) and renal pelvis with mild to moderate dilatation. Normal or slightly deformed renal calyces.
- Grade 4:** Reflux into moderately dilated ureter (with or without kinking) and (slightly) dilated renal calyces. The papillary impression is preserved.
- Grade 5:** Reflux with tortuous and significantly dilated ureter, dilation of the renal pelvis and calyces with impressions with a loss of the renal papillae.



► **Fig. 2** **A** Contrast-enhanced ultrasound with grade II VUR of the right kidney. Imaging > 2 minutes after intravesical administration of the contrast agent. White arrows: Image of the contrast agent in the renal calyces. Red arrow: Contrast-enhanced image of the ureter in bifid ureter. **B** B-mode examination of the right kidney. Urinary retention or dilation of the ureter cannot be delimited. A parenchymal bridge (red arrow) can be detected as a secondary finding.



► **Fig. 1** Grade II VUR of the right kidney on comparison mode B-mode image (right) and contrast-enhanced image (left). Imaging > 2 minutes after intravesical administration of contrast agent.



► **Fig. 3** Mixed mode image with overlay of contrast-enhanced image and B-mode image of grade II VUR of the right kidney.

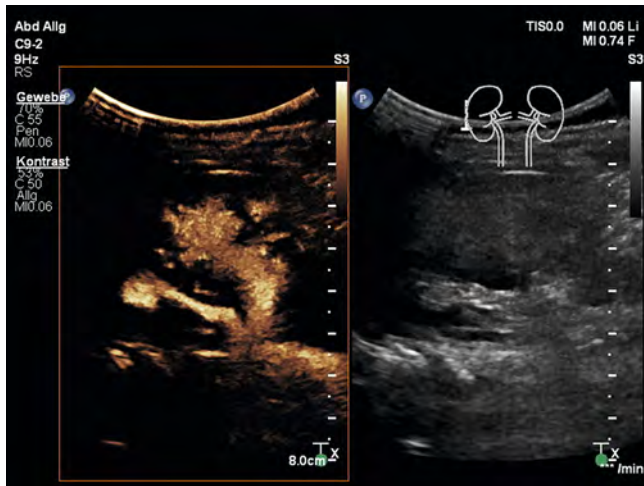
## Voiding cystourethrography and radionuclide cystography

To date, vesicoureteral reflux has been primarily diagnosed via voiding cystourethrography (VCUG). In this examination method, intravesical contrast administration and X-ray fluoroscopy are used to diagnose vesicoureteral reflux [14]. This method has been used for over 60 years and is considered the gold standard [15]. The disadvantage of the examination is the use of radiation in the primarily young patient population. In Germany, there are age- and weight-dependent diagnostic reference values. These range from a dose area product of 5 [cGy·cm<sup>2</sup> = μGy·m<sup>2</sup>] for newborns (3 to <5 kilograms or under 3 months of age) up to 30 [cGy·cm<sup>2</sup> = μGy·m<sup>2</sup>] in children between 5 and 10 years of age or between 19 and 32 kilograms [16]. In spite of the fact that this examination method has been in use for a long time and numerous publications are available, a study by Schneider et al. was able to show that both documentation and the examination procedure are not standardized in Europe and the result of the examination, like in ceVUS, is highly dependent on the experience of the examiner [17].

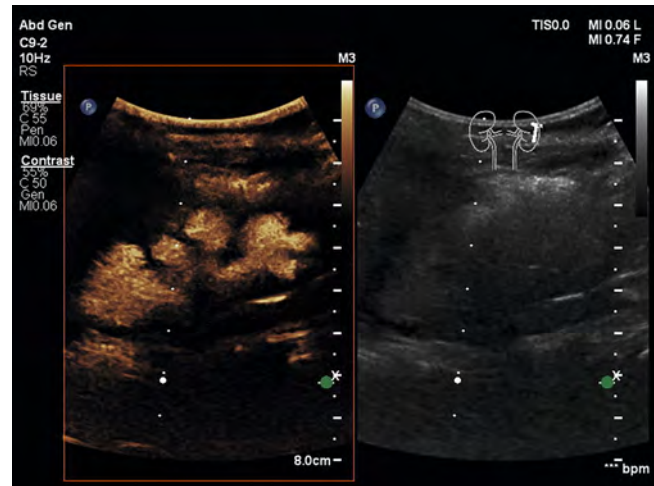
There are also nuclear medicine methods for diagnosing vesicoureteral reflux. Radionuclide cystourethrography is performed as a direct method analogous to VCUG. This method has a similar sensitivity to VCUG with slightly lower radiation exposure [18]. <sup>99</sup>Tc-MAG3 renal scintigraphy can be used as an indirect method for detecting vesicoureteral reflux. The advantage of this method is that the radiotracer is applied intravenously so that the bladder does not need to be catheterized for the examination. However, the sensitivity and specificity are significantly lower than that of VCUG and RNC. Moreover, since urinary continence is necessary for examination planning and the patient population is typically young, this method is not generally used for primary diagnosis in the case of suspicion of vesicoureteral reflux [18].

## Alternative method: ceVUS

Contrast-enhanced ultrasound examination (ceVUS) can be used as an alternative method to reduce radiation exposure. Studies on the successful use of ultrasound to diagnose vesicoureteral



► **Fig. 4** After administration of contrast agent, mild to moderate dilation of the ureter and renal pelvis and mild enlargement of the renal calyces can be detected. The finding is consistent with grade III reflux.

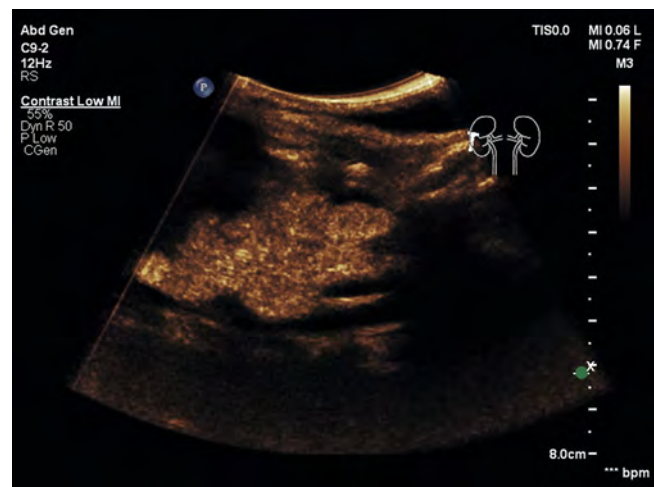


► **Fig. 5** 6-year old female patient with recurrent pyelonephritis. After contrast administration, moderate dilation of the renal pelvis and enlarged renal calyces can be detected. The finding is consistent with grade IV reflux. Comparison mode with B-mode ultrasound image on the right and contrast-enhanced image on the left.

reflux have been available for years. In 1984, Schneider et al. described the good sensitivity and specificity of B-mode ultrasound for higher grade vesicoureteral reflux [19]. The currently available ceVUS examination method can be considered a further development of the method described by Alzen et al. in 1994 in which vesicoureteral reflux was diagnosed based on intravesically administered air bubbles. Using this method, higher grade vesicoureteral reflux (starting at grade III) could be detected with a sensitivity of 100% and a specificity of 95.6% [20]. Various studies by Darge played a major role in the further development of ceVUS and the approval of the first-generation ultrasound contrast agent Levovist and were able to show at least comparable diagnostic accuracy to that of VCUG [21–26]. This was then able to be confirmed in the following years in a number of studies [27–30]. A meta-analysis by Darge from the year 2008 showed that more cases of vesicoureteral reflux were detected with ceVUS than with VCUG and that the grade was higher in the ceVUS examination than in VCUG in 19.6% of the cases [22].

A meta-analysis from the year 2022 compared the sensitivity and specificity of ceVUS examinations and calculated a sensitivity of 92%, a specificity of 94%, and an AUC of 97% on average for ultrasound contrast agents of the first generation. These values were 93%, 91%, and 97%, respectively, for ultrasound contrast agents of the second generation [31]. The rate of false-negative ceVUS results was 3% so that according to both the study and the current S2k guidelines VCUG should be additionally performed in the case of a negative ceVUS examination but persistent suspicion of vesicoureteral reflux [4]. However, the clinical-therapeutic relevance of performing another invasive examination should always be questioned here.

VCUG and ceVUS differ primarily with regard to the diagnosis of low-grade vesicoureteral reflux since the distal ureters sometimes cannot be reliably evaluated on ceVUS due to a lack of visibility of the distal ureters (e. g. in the case of intestinal gas overlying the branches) or due to the high concentration of contrast



► **Fig. 6** 7-year old female patient with recurrent pyelonephritis. After contrast administration, pronounced dilation of the renal pelvis and calyces can be detected. There are marked impressions with a loss of the papillae. The finding is consistent with grade V reflux.

medium in the neighboring bladder [13]. In contrast, another study showed that 9% more cases of vesicoureteral reflux were able to be detected on ceVUS than VCUG [22]. An important reason why VCUG is preferred over ceVUS in many cases is the expertise of the examiner. However, a single-center study showed a good learning curve for ceVUS and that there is a lack of standardization in the examination procedure and documentation for VCUG [17, 31].

In addition to the advantage of reduced radiation exposure for the primarily young patient population, legal guardians are more accepting of ceVUS than VCUG. In one study, 92.9% of surveyed parents preferred ceVUS over VCUG [32].

## Which examination should be performed and when?

The pediatric and nephrology guidelines in Germany view the currently available diagnostic methods as equivalent. The following recommendation is included in the S2k guidelines on urinary tract infections in children from the year 2021: “If sufficient for the particular diagnostic issue, sonographic reflux testing (ceVUS) should be given preference over methods involving radiation provided that the examiner has the necessary experience” [4]. This applies to an accordingly selected patient population.

If other diseases or anomalies of the urinary tract, e.g., a duplex kidney or ureterocele, are suspected in addition to the suspicion of vesicoureteral reflux, VCUG should be given preference over ceVUS [33]. In the case of suspected subvesical obstruction, both VCUG and ceVUS can provide information about the cause [34]. On the other hand, ceVUS is particularly advantageous when intrarenal reflux (IRR) is present in addition to vesicoureteral reflux [35]. Since IRR often occurs in addition to vesicoureteral reflux (averaged over all VUR grades, IRR is seen in 3–10% of cases), ceVUS should be used for the primary diagnosis of vesicoureteral reflux provided that the corresponding requirements are met by the hospital and examiner [36].

However, the selection of the examination method depends on the availability of resources on-site, the specific clinical question, and the goal of ensuring the lowest possible radiation exposure while obtaining maximum information.

The examination can first be performed after successful treatment of the urinary tract infection/pyelonephritis. It must be taken into consideration that the examination should not be performed too soon after an infection in order to avoid any false-negative findings resulting from temporary infection-related swelling [37]. To ensure this and to avoid the transfer of bacteria from the bladder to the renal pelvis as a result of the examination, the urine must be examined prior to ceVUS. The examination should not be performed if intravesical bacteria is detected. A sterile procedure is also important for bladder catheter placement and intravesical injection of the contrast medium. There is currently only insufficient literature regarding the periprocedural application of an antibiotic for ceVUS. Some individual studies were performed without the administration of antibiotics [38] or with a single administration on the day of the examination [39]. In comparison, administration of an antibiotic the day before, the day of, and the day after VCUG is recommended [40]. Since both examination procedures have the same risk factors for the development of a urinary tract infection, we recommend using the same procedure for ceVUS.

Continuous antibiotic prophylaxis is recommended by current guidelines in the case of diagnosed vesicoureteral reflux. However, this is being reexamined in new studies from the year 2023 [4, 41]. In the case of additional obstructive diseases of the urinary tract, antibiotic prophylaxis should be implemented [38].

## Types of contrast agent for diagnosing vesicoureteral reflux

The ultrasound contrast agents typically used for diagnosing vesicoureteral reflux are second-generation SonoVue (primarily in Europe) and Optison (primarily in the US). First-generation Levovist was also used in initial studies [42]. The use of Levovist and SonoVue for detecting vesicoureteral reflux is included in the product information. However, the production of Levovist has been discontinued. General approval for use of Optison in minors is described [43]. Multiple studies on the safety of the intravesical administration of ultrasound contrast agent have been conducted. No serious adverse events were reported. In one study, the rate of non-serious adverse events was 0.31%, with most issues being associated with the placement of the urinary catheter [32, 44–46].

## ceVUS examination procedure

The ceVUS examination procedure has already been described many times. Refer to the ESPR reviews and the review by Ntoulia et al. from the year 2021 [44]. There are various techniques for filling the bladder with contrast agent. The contrast agent can either be administered extracorporeally in a 0.9% saline solution and continuously applied during the course of the examination or the contrast agent can be administered directly into the bladder after prior partial filling of the bladder with 0.9% saline solution. The mechanical index for the examination depends on the ultrasound transducer but should ideally be under 0.1. The product information for SonoVue recommends a value of less than 0.4 [47].

The examination should be performed during filling and emptying of the bladder. If it is not possible to evaluate both kidneys and both ureters during emptying of the bladder, the bladder can be filled again. By filling the bladder several times, the sensitivity of the examination could be further increased.

Low-grade, particularly grade I, vesicoureteral reflux can often be effectively detected in the filling phase of the examination, while the full bladder and the voiding phase are the most suitable times for evaluating the severity of vesicoureteral reflux. If the bladder is to be filled again, the extracorporeal mixing of ultrasound agent and carrier solution is the most suitable method for achieving uniform contrast enhancement during the examination.

Continuous scanning of the bladder during filling is not recommended since this will destroy the contrast bubbles. Therefore, pauses at regular intervals are recommended.

## Daily practice/recommended actions

Contrast-enhanced ultrasound examination of the bladder and the urinary tract is becoming increasingly important in the diagnosis of vesicoureteral reflux and should be used as the primary diagnostic method if the corresponding resources are available in suitable cases. Suspicion of either primary or secondary vesicoureteral reflux is considered an indication for examination. Indica-

tions include congenital hydronephrosis, a first degree relative with vesicoureteral reflux, a urinary tract infection with non-E. coli bacteria, an abnormal B-mode ultrasound examination after a febrile urinary tract infection, or at least two occurrences of pyelonephritis in children under the age of two. ceVUS can be quickly learned, is equivalent to the gold standard examination (VCUG) and should be used as the primary diagnostic method in the often very young patient population due to the lack of radiation exposure. The examination should not be performed during a urinary tract infection/pyelonephritis but rather in the inflammation-free period after treatment. It is important to wait long enough after treatment of the infection to avoid false-negative findings due to temporary swelling of the ostium and the distal section of the ureter.

Given method-based weaknesses regarding the diagnosis of low-grade vesicoureteral reflux (grade I), VCUG or RNC can be additionally performed depending on the clinical relevance in the case of persistent suspicion and a normal ceVUS examination. To coordinate all examinations and ensure prompt introduction of any necessary treatment, patients should be connected to a pediatric urological, surgical, or nephrological center. The question currently under discussion regarding continuous antibiotic prophylaxis can thus be clarified here, ideally in an interdisciplinary board, particularly in the case of a conservative approach.

### Conflict of Interest

The authors declare that within the past 3 years they have worked as speakers for Bracco, Philips, Mindray, Esaote, Siemens and Samsung.

### References

- [1] Fanos V, Cataldi L. Antibiotics or surgery for vesicoureteric reflux in children. *Lancet* 2004; 364: 1720–1722. doi:10.1016/S0140-6736(04)17359-5
- [2] Greenbaum LA, Mesrobian HG. Vesicoureteral reflux. *Pediatr Clin North Am* 2006; 53: 413–427, vi. doi:10.1016/j.pcl.2006.02.010
- [3] Ramage IJ, Schuckett B, McLorie GA et al. Primary vesicoureteric reflux diagnosed in the 1<sup>st</sup> month of life. *Pediatr Nephrol* 1999; 13: 716–717
- [4] Gesellschaft für Pädiatrische Nephrologie e. V. S2k-Leitlinie Harnwegsinfektionen im Kindesalter – Diagnostik, Therapie und Prophylaxe, Version 1.0, 2021, verfügbar unter. <https://register.awmf.org/de/leitlinien/detail/166-004> Zugriff am 08.09.2023
- [5] Chand DH, Rhoades T, Poe SA et al. Incidence and severity of vesicoureteral reflux in children related to age, gender, race and diagnosis. *J Urol* 2003; 170: 1548–1550. doi:10.1097/01.ju.0000084299.55552.6c
- [6] Willemsen J, Nijman RJ. Vesicoureteral reflux and videourodynamic studies: results of a prospective study. *Urology* 2000; 55: 939–943. doi:10.1016/s0090-4295(00)00549-5
- [7] Hoberman A, Charron M, Hickey RW et al. Imaging studies after a first febrile urinary tract infection in young children. *N Engl J Med* 2003; 348: 195–202. doi:10.1056/NEJMoa021698
- [8] American Urological Association. Management and Screening of Primary Vesicoureteral Reflux in Children, 2017, verfügbar unter. <https://www.auanet.org/guidelines-and-quality/guidelines/vesicoureteral-reflux-guide-line> Zugriff am 08.09.2023
- [9] Tekgül S, Riedmiller H, Hoebeke P et al. EAU Guidelines on Vesicoureteral Reflux in Children. *Eur. Urol* 2012; 62 (3): P534–P542. doi:10.1016/j.euro.2012.05.059
- [10] Rothwell DL, Constable AR, Albrecht M. Radionuclide cystography in the investigation of vesicoureteric reflux in children. *Lancet* 1977; 1: 1072–1075. doi:10.1016/s0140-6736(77)92333-9
- [11] Arapovic A, Punda A, Brdar D et al. Types of Parenchymal Changes Diagnosed on DMSA Scans of Kidneys Affected by Different Grades of Vesicoureteral Reflux. *Med Sci Monit* 2021; 27: e929617. doi:10.12659/MSM.929617
- [12] Lebowitz RL, Olbing H, Parkkulainen KV et al. International system of radiographic grading of vesicoureteric reflux. *International Reflux Study in Children. Pediatr Radiol* 1985; 15: 105–109. doi:10.1007/BF02388714
- [13] Benya EC, Prendergast FM, Liu DB et al. Assessment of distal ureteral and ureterovesical junction visualization on contrast-enhanced voiding urosonography. *Pediatr Radiol* 2021; 51: 1406–1411. doi:10.1007/s00247-021-04979-z
- [14] Thomsen HS, Rygaard H, Strandberg C. Micturating cystourethrography and vesicoureteral reflux. *Eur J Radiol* 1985; 5: 318–320
- [15] Gudbjerg CE, Hansen LK, Hasner E. Micturition cysto-urethrography; automatic serial technique. *Acta radiol* 1958; 50: 310–315. doi:10.3109/00016925809172309
- [16] Bundesamt für Strahlenschutz. Bekanntmachung der aktualisierten diagnostischen Referenzwerte für diagnostische und interventionelle Röntgenanwendungen.
- [17] Schneider K, Krüger-Stollfuss I, Ernst G et al. Paediatric fluoroscopy—a survey of children’s hospitals in Europe. I. Staffing, frequency of fluoroscopic procedures and investigation technique. *Pediatr Radiol* 2001; 31 (4): 238–246. doi:10.1007/s002470100429
- [18] Likartsis C, Printza N, Notopoulos A. Radionuclide techniques for the detection of vesicoureteral reflux and their clinical significance. *Hell J Nucl Med* 2020; 23 (2): 180–187. doi:10.1967/s002449912107
- [19] Schneider K, Jablonski C, Wiessner M et al. Screening for vesicoureteral reflux in children using real-time sonography. *Pediatr Radiol* 1984; 14 (6): 400–403. doi:10.1007/BF02343428
- [20] Alzen G, Wildberger JE, Ferris EJ et al. Sonographic detection of vesicoureteral reflux with air: a new method. *Eur Radiol* 1994; 4: 142–145. doi:10.1007/BF00231200
- [21] Darge K. Voiding urosonography with ultrasound contrast agents for the diagnosis of vesicoureteric reflux in children. I. Procedure. *Pediatr Radiol* 2008; 38 (1): 40–53. doi:10.1007/s00247-007-0529-7
- [22] Darge K. Voiding urosonography with US contrast agents for the diagnosis of vesicoureteric reflux in children. II. Comparison with radiological examinations. *Pediatr Radiol* 2008; 38 (1): 54–63. doi:10.1007/s00247-007-0528-8
- [23] Robrecht J, Darge K. [In-vitro comparison of a 1<sup>st</sup> and a 2<sup>nd</sup> generation US contrast agent for reflux diagnosis]. *Rofo Fortschr* 2007; 179 (8): 818–825. doi:10.1055/s-2007-963312
- [24] Darge K, Moeller RT, Trusen A et al. Diagnosis of vesicoureteric reflux with low-dose contrast-enhanced harmonic ultrasound imaging. *Pediatr Radiol* 2005; 35 (1): 73–78. doi:10.1007/s00247-004-1317-2
- [25] Darge K, Troeger J, Duetting T et al. Reflux in young patients: comparison of voiding US of the bladder and retrovesical space with echo enhancement versus voiding cystourethrography for diagnosis. *Radiology* 1999; 210 (1): 201–207. doi:10.1148/radiology.210.1.r99ja40201
- [26] Darge K, Troeger J. Vesicoureteral reflux grading in contrast-enhanced voiding urosonography. *Eur J Radiol* 2002; 43 (2): 122–128. doi:10.1016/s0720-048x(02)00114-6
- [27] Mentzel HJ, Vogt S, John U et al. Voiding urosonography with ultrasonography contrast medium in children. *Pediatr Nephrol* 2002; 17 (4): 272–276. doi:10.1007/s00467-002-0843-0
- [28] Marschner CA, Schwarze V, Stredele R et al. Evaluation of the Diagnostic Value of Contrast-Enhanced Voiding Urosonography with Regard to the Further Therapy Regime and Patient Outcome—A Single-Center Experi-

- ence in an Interdisciplinary Uroradiological Setting. *Medicina (Kaunas)* 2021; 57. doi:10.3390/medicina57010056
- [29] Ključevšek D, Battelino N, Tomažič M et al. A comparison of echo-enhanced voiding urosonography with X-ray voiding cystourethrography in the first year of life. *Acta Paediatr* 2012; 101: e235–e239. doi:10.1111/j.1651-2227.2011.02588.x
- [30] Roic AC, Milošević D, Turudić D et al. An innovative diagnostic procedure in children: videourodynamics with contrast-enhanced voiding urosonography. *J Ultrasound* 2022. doi:10.1007/s40477-022-00721-z
- [31] Velasquez M, Emerson MG, Diaz E et al. The learning curve of contrast-enhanced “microbubble” voiding urosonography-validation study. *J Pediatr Urol* 2019; 15: 385.e381–385.e386. doi:10.1016/j.jpuro.2019.04.015
- [32] Seelbach J, Krüger PC, Waginger M et al. Safety and parents’ acceptance of ultrasound contrast agents in children and adolescents – contrast enhanced voiding urosonography and contrast enhanced ultrasound. *Med Ultrason* 2022; 24: 27–32. doi:10.11152/mu-3196
- [33] Benya EC, Prendergast FM, Liu DB et al. Assessment of distal ureteral and ureterovesical junction visualization on contrast-enhanced voiding urosonography. *Pediatr Radiol* 2021; 51 (8): 1406–1411. doi:10.1007/s00247-021-04979-z
- [34] Barnewolt CE, Acharya PT, Aguirre Pascual E et al. Contrast-enhanced voiding urosonography part 2: urethral imaging. *Pediatr Radiol* 2021; 51 (12): 2368–2386. doi:10.1007/s00247-021-05116-6
- [35] Kim D, Hun Choi Y, Choi G et al. Contrast-enhanced voiding urosonography for the diagnosis of vesicoureteral reflux and intrarenal reflux: a comparison of diagnostic performance with fluoroscopic voiding cystourethrography. *Ultrasonography* 2021; 40 (4): 530–537. doi:10.14366/usg.20157
- [36] Klein EL, Wyers MR, Prendergast FM et al. Prevalence of intrarenal reflux in pediatric patients on contrast-enhanced voiding urosonography. *Pediatr Radiol* 2023; 53 (3): 387–393. doi:10.1007/s00247-022-05548-8
- [37] Pfitzinger PL, Stredle R, Eismann L et al. [Special diagnostics in pediatric urology-Ultrasound, VCUG, CT and MRI: Part 1: tips for the practice]. *Urologie* 2022; 61: 782–791. doi:10.1007/s00120-022-01869-6
- [38] Oh S, Ha JY, Cho YJ. Contrast-enhanced voiding ultrasonography to detect intrarenal reflux in children: comparison with 99mTc-DMSA renal scans. *Ultrasonography* 2022; 41 (3): 502–510. doi:10.14366/usg.21143
- [39] Ključevšek D, Pecanac O, Tomazic M et al. Potential causes of insufficient bladder contrast opacification and premature microbubble destruction during contrast-enhanced voiding urosonography in children. *J Clin Ultrasound* 2019; 47 (1): 36–41. doi:10.1002/jcu.22656
- [40] Sinha R, Saha S, Maji B et al. Antibiotics for performing voiding cystourethrogram: a randomised control trial. *Arch Dis Child* 2018; 103 (3): 230–234. doi:10.1136/archdischild-2017-313266
- [41] Autore G, Bernardi L, Ghidini F et al. Antibiotic Prophylaxis for the Prevention of Urinary Tract Infections in Children: Guideline and Recommendations from the Emilia-Romagna Pediatric Urinary Tract Infections (UTI-Ped-ER) Study Group. *Antibiotics (Basel)* 2023; 12 (6): 1040. doi:10.3390/antibiotics12061040
- [42] Chung YE, Kim KW. Contrast-enhanced ultrasonography: advance and current status in abdominal imaging. *Ultrasonography* 2015; 34: 3–18. doi:10.14366/usg.14034
- [43] American College of Radiology Committee on Drugs and Contrast Media. *ACR Manual on Contrast Media, Version 2023*, verfügbar unter: [https://www.acr.org/-/media/acr/files/clinical-resources/contrast\\_media.pdf](https://www.acr.org/-/media/acr/files/clinical-resources/contrast_media.pdf) Zugriff am 08.09.2023
- [44] Ntoulia A, Anupindi SA, Back SJ et al. Contrast-enhanced ultrasound: a comprehensive review of safety in children. *Pediatr Radiol* 2021; 51 (12): 2161–2180. doi:10.1007/s00247-021-05223-4
- [45] Darge K, Papadopoulou F, Ntoulia A et al. Safety of contrast-enhanced ultrasound in children for non-cardiac applications: a review by the Society for Pediatric Radiology (SPR) and the International Contrast Ultrasound Society (ICUS). *Pediatr Radiol* 2013; 43 (9): 1063–1073. doi:10.1007/s00247-013-2746-6
- [46] Riccabona M, Avni FE, Blickman JG. Imaging recommendations in paediatric uroradiology: minutes of the ESPR workgroup session on urinary tract infection, fetal hydronephrosis, urinary tract ultrasonography and voiding cystourethrography, Barcelona, Spain, June 2007. *Pediatr Radiol* 2008; 38 (2): 138–145. doi:10.1007/s00247-007-0695-7
- [47] Fachinformation (Zusammenfassung der Merkmale des Arzneimittels) SonoVue. Verfügbar unter: <https://www.bracco.com/sites/default/files/2023-05/fachinfo-sonovue.pdf> Zugriff am: 08.09.2023