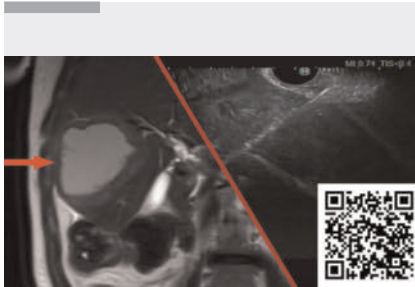
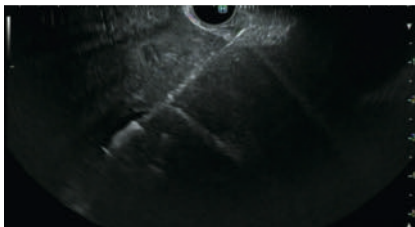


Endoscopic treatment of a hepatic abscess arising from a biliary stricture due to intraductal papillary neoplasm of the bile duct

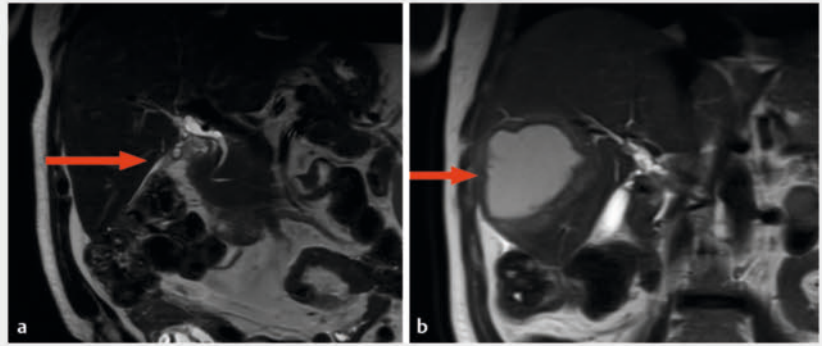
OPEN
ACCESS



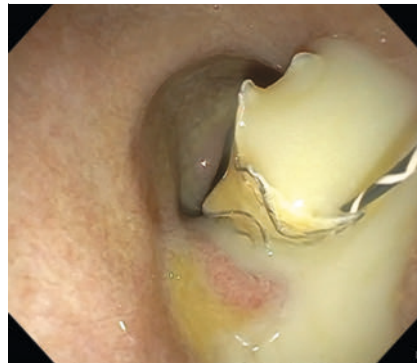▶ **Video 1** Endoscopic management of a large hepatic abscess secondary to a severe chronic biliary stricture due to intraductal papillary neoplasm of the bile duct.



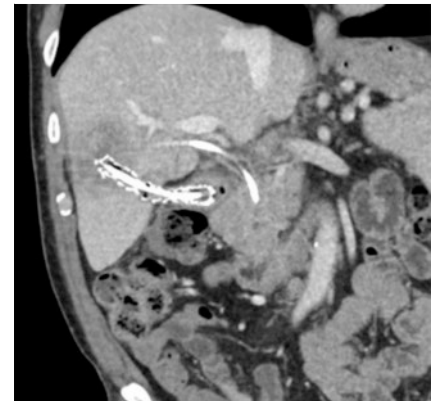
▶ **Fig. 2** Endoscopic ultrasound (EUS) image during EUS-guided cystoduodenostomy.



▶ **Fig. 1** Magnetic resonance cholangiopancreatography images showing: **a** mild-to-moderate intrahepatic biliary dilatation in liver segment 5; **b** an 8.8-cm thick-walled cystic lesion in the right hepatic lobe near the previously dilated biliary segment 4 months after ERCP and sphincterotomy.



▶ **Fig. 3** Endoscopic image showing copious pus draining from cystoduodenostomy tract after placement of a fully covered metal stent.



▶ **Fig. 4** Follow-up computed tomography scan 1 month after the procedure showing abscess resolution and reduction in the biliary dilatation.

Endoscopic ultrasound (EUS)-guided drainage, primarily used for intra-abdominal abscesses/fluid collections, is increasingly used for hepatic abscesses that have been traditionally managed by external drainage or surgery. EUS interventions offer reduced morbidity and potentially lower complication rates. We present a case showcasing the efficacy and safety of EUS-guided drainage in treating a complex hepatic abscess (▶ **Video 1**).

A 63-year-old man with abdominal pain and elevated alkaline phosphatase was found to have a dilated right-sided bile duct and mild-to-moderate intrahepatic biliary dilatation with stones (▶ **Fig. 1 a**). After an endoscopic retrograde cholangiopancreatography (ERCP) with biliary sphincterotomy and stent placement

had been performed, a follow-up ERCP revealed a benign-appearing biliary stenosis, with brush cytology showing benign epithelial cells. Four months later, the patient experienced worsening symptoms. A further scan revealed a hepatic abscess in segment 6 (▶ **Fig. 1 b**). Another ERCP confirmed a biliary stricture with prestenotic dilatation and debris in the dilated hepatic duct. Attempts to access the cavity via the transpapillary route failed, leading us to a planned EUS-guided drainage.

EUS-guided fine-needle aspiration (FNA) confirmed the presence of pus in the abscess, and EUS-guided cystoduodenostomy was performed (▶ **Fig. 2**). A 10-mm×10-cm metal stent and a 7-Fr×15-cm double-pigtail plastic stent were placed, enabling significant pus drainage (▶ **Fig. 3**). Both the biliary and cystoduodenostomy stents were correctly placed, and this was confirmed by fluoroscopy. The patient was monitored post-procedure on a liquid to low-resi-

due diet progression, with antibiotics prescribed.

A follow-up computed tomography (CT) scan 1 month later showed resolution of the abscess and decreased biliary dilatation (► **Fig. 4**). The cystoduodenostomy stents were removed, while the biliary stent was left in place. After review by the multidisciplinary team, the patient underwent robot-assisted right hepatectomy, which revealed an intraductal papillary neoplasm of the bile duct with high grade dysplasia. The patient showed significant symptom improvement post-surgery.




In conclusion, chronic biliary strictures can lead to cholangitis and hepatic abscesses. EUS-guided drainage is a safe and effective approach, which may be useful alone or with ERCP, for managing liver abscesses and as a bridge to surgery in complex biliary conditions.

Endoscopy_UCTN_Code_TTT_1AR_2AG

Conflict of Interest

S. Mahadev is a consultant for CONMED and Boston Scientific. R. Z. Sharaiha is a consultant for Cook Medical, Boston Scientific, Olympus, and Surgical Intuitive. K. Sampath is a consultant for CONMED. K. M. Hassan, D. Dawod, M. Hassan, and S. M. Salgado declare that they have no conflict of interest.

The authors

Kamal M. Hassan¹ , **Enad Dawod**¹, **Mohammed Hassan**², **Sanjay M. Salgado**¹ , **SriHari Mahadev**¹, **Reem Z. Sharaiha**¹ , **Kartik Sampath**¹

- 1 Gastroenterology and Hepatology, Weill Cornell Medical College, New York, United States
- 2 Alivation, Lincoln, United States

Corresponding author

Kamal M. Hassan, MD

Weill Cornell Medicine, Division of Gastroenterology and Hepatology, Department of Medicine, 1305 York Avenue, 4th Floor, 10021 New York, USA
kamal.mahassan@gmail.com

Bibliography

Endoscopy 2024; 56: E225–E226

DOI 10.1055/a-2253-0948

ISSN 0013-726X

© 2024. The Author(s).

This is an open access article published by Thieme under the terms of the Creative Commons Attribution License, permitting unrestricted use, distribution, and reproduction so long as the original work is properly cited.

(<https://creativecommons.org/licenses/by/4.0/>)

Georg Thieme Verlag KG, Rüdigerstraße 14, 70469 Stuttgart, Germany



ENDOSCOPY E-VIDEOS

<https://eref.thieme.de/e-videos>



E-Videos is an open access online section of the journal *Endoscopy*, reporting on interesting cases

and new techniques in gastroenterological endoscopy. All papers include a high-quality video and are published with a Creative Commons CC-BY license. Endoscopy E-Videos qualify for HINARI discounts and waivers and eligibility is automatically checked during the submission process. We grant 100% waivers to articles whose corresponding authors are based in Group A countries and 50% waivers to those who are based in Group B countries as classified by Research4Life (see: <https://www.research4life.org/access/eligibility/>).

This section has its own submission website at

<https://mc.manuscriptcentral.com/e-videos>