

# Systematic, noninvasive endometriosis diagnosis in transvaginal sonography by the Swiss Society of Ultrasound in Medicine

## Systematische, nicht invasive Endometriose-Diagnostik in der transvaginalen Sonografie: Empfehlungen der Schweizerischen Gesellschaft für Ultraschall in der Medizin

### Authors

Julian Matthias Metzler<sup>1,2</sup>, Leana Finger<sup>2</sup>, Tilo Burkhardt<sup>3,2</sup>, Markus Eugen Hodel<sup>4</sup>, Gwendolin Manegold-Brauer<sup>5</sup>, Sara Imboden<sup>6,7</sup>, Janna Pape<sup>8,7</sup>, Patrick Imesch<sup>1,2</sup>, Isabell Witzel<sup>1,2</sup>, Michael Bajka<sup>1,2</sup>

### Affiliations

- 1 Gynecology, University Hospital Zurich, Switzerland
- 2 Faculty of Medicine, University of Zurich, Switzerland
- 3 Obstetrics, University Hospital Zurich, Switzerland
- 4 Obstetrics and Gynecology, Cantonal Hospital Lucerne, Switzerland
- 5 Prenatal medicine and gynecologic ultrasound, University Hospital, Basel, Switzerland
- 6 Gynecology, Inselspital University Hospital, Bern, Switzerland
- 7 Faculty of Medicine, University of Bern, Switzerland
- 8 Gynecological Endocrinology and Reproductive Medicine, Inselspital University Hospital, Bern, Switzerland

### Keywords

endometriosis, ultrasound, transvaginal, sonography, classification

received 1.2.2024

accepted 16.2.2024

published online 24.5.2024

### Bibliography

Ultraschall in Med 2024; 45: 367–388

DOI 10.1055/a-2241-5233

ISSN 0172-4614

© 2024, Thieme. All rights reserved.

Georg Thieme Verlag KG, Rüdigerstraße 14,  
70469 Stuttgart, Germany

### Correspondence

Dr. Julian Matthias Metzler

Gynecology, University Hospital Zurich, Frauenklinikstraße 10,  
8091 Zürich, Switzerland

Tel.: +41/44/2 55 50 36

julian.metzler@usz.ch

### ABSTRACT

We present a new systematic, comprehensive, checklist-based sonographic assessment of endometriosis in the female true pelvis. Emphasis is placed on practical skills teaching. The newly introduced White Sliding Line (WSL) is the core structure. The WSL separates five compartments (anterior, central, posterior, and lateral right and left) containing dedicated endometriosis signs of mobility and morphology to be checked. This approach relies on the 2016 IDEA Consensus and further developments. It directly connects to the 2021 #ENZIAN Classification Standard. In practice, evaluation follows the proposed checklist in all compartments, judging first sliding mobility between organs and structures in a highly dynamic investigation. A rigorous search for deep endometriosis (DE) is then performed. We treat adhesions due to their great clinical importance and possible, reliable diagnosis by TVS as the fifth endometriosis unit, next to endometrioma, DE, adenomyosis, and superficial endometriosis. Including superficial (peritoneal) endometriosis is a future goal.

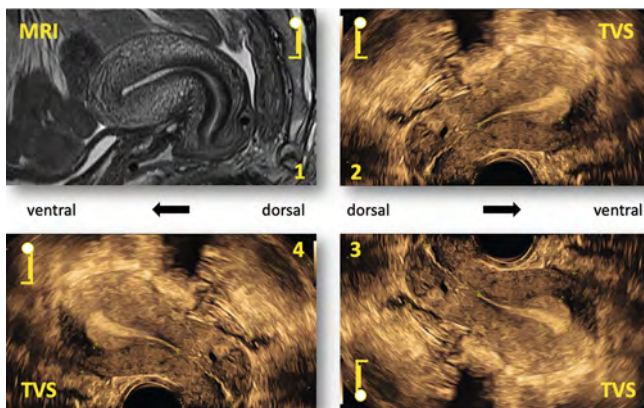
### ZUSAMMENFASSUNG

Wir präsentieren eine systematische, umfassende, auf einer Checkliste basierende sonografische Abklärung der Endometriose im weiblichen kleinen Becken. Das Übermitteln praktischer Fähigkeiten stellt einen Schwerpunkt dar. Der neu eingeführten White Sliding Line (WSL) kommt dabei eine Schlüsselrolle zu. Die WSL ermöglicht die Einteilung in 5 Kompartimente (anterior, zentral, posterior und lateral rechts und links). Diese enthalten dedizierte Endometriose-Zeichen zur Mobilität und Morphologie. Die vorgeschlagene Systematik beruht auf dem IDEA-Konsensus von 2016 und dessen Erweiterungen. Sie leitet direkt in die #Enzian-Klassifikation von 2021 über. In der Praxis wird gemäß der Checkliste in einer betont dynamischen Untersuchung nach reduziertem oder aufgehobenem Sliding zwischen Organen und Strukturen gefahndet, gefolgt von einer rigorosen Suche nach tiefen Endometriose-Läsionen. Die große klinische Bedeutung der Adhäsionen und ihre zuverlässige sonografische Beurteilbarkeit lässt uns diese als 5. Entität der Endometriose behandeln, nebst Endometriomen, tiefer Endometriose, Adenomyose und oberflächlicher Endometriose. In Zukunft soll möglichst auch die oberflächliche (peritoneale) Endometriose in die Systematik aufgenommen werden.

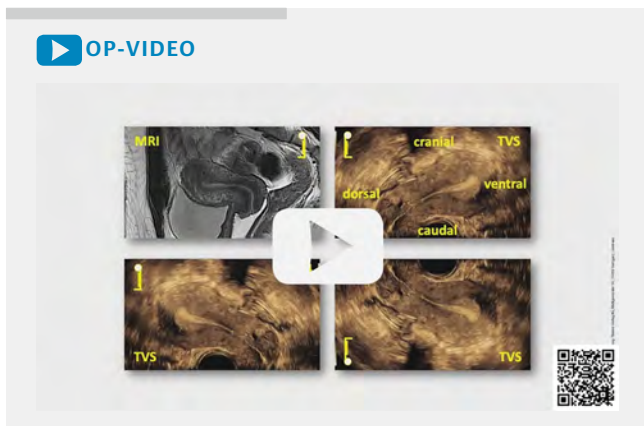
## 1 Objective

Transvaginal sonography (TVS) is the standard examination method of the female pelvis and is now the recommended first-line imaging modality to diagnose endometriosis [1–3]. In the hands of experienced examiners, TVS offers high sensitivity and specificity [4] for diagnosing ovarian endometriosis (endometrioma) [5], adenomyosis [6, 7], deep endometriosis (DE) [8, 9], and adhesions [4]. In symptomatic patients, not only adenomyosis and DE are prevalent findings, but also a negative Sliding Sign in 25% of cases, and the loss of ovarian mobility in 20% [10]. On the other hand, the sonographic detection of peritoneal endometriosis is still challenging [11].

The sonographic appearance of recognizable endometriotic lesions on TVS may be briefly summarized as direct and indirect signs. Direct signs (endometriomas, space-occupying lesions of low echogenicity) are indicators of DE. Indirect signs (reduced or absent sliding mobility between organs, evidence of tissue tension, painful areas) are indicators of adhesions. An encompassing checklist protocol for endometriosis assessment, including both direct and indirect signs, is still needed [10].



► **Fig. 1** Different TVS image orientations in use. MRI: magnetic resonance imaging; TVS: transvaginal sonography.



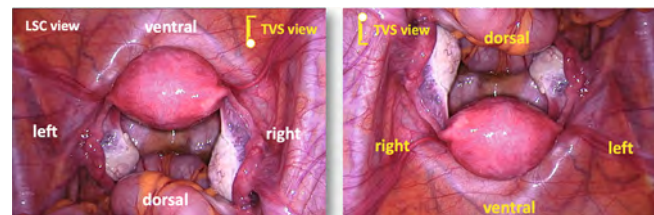
► **Video 1** Applied TVS image orientation. MRI: magnetic resonance imaging; TVS: transvaginal sonography

This article presents a new, comprehensive, and systematic approach by the Swiss Society of Ultrasound in Medicine (SGUM) (SWISS Gynecologic Ultrasound Guideline, 3<sup>rd</sup> edition, in press) to explore the entire female true (lesser) pelvis in five compartments for endometriotic lesions using TVS. It is based on the 2016 IDEA Consensus (IDEA 2016) [8], including subsequent extensions [11, 12], refinements [6, 13], and validations [4, 14]. It highlights the five sites most commonly affected by DE (sacrouterine ligaments (SUL) 53%, bowel 23%, vagina 16%, bladder 6%, and ureters 2%) [15]. It also explains how the well-known sliding mobility can be expanded and applied using the unique strength of TVS: a highly dynamic investigation. Finally, the description of endometriosis findings proposed by the #ENZIAN Endometriosis Classification (#ENZIAN) from 2021 is used as an essential summary that allows comparability across cases, imaging modalities, and disciplines [16].

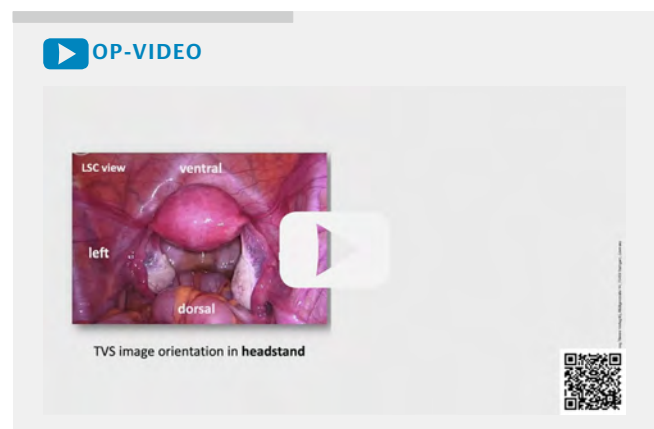
We focus on teaching practical skills. In addition to the text, QR code-backed instructional figures (fig.), videos (vid.), and tables (tab.) help the reader to master the highly dynamic examination.

## 2 Transvaginal sonographic image orientation

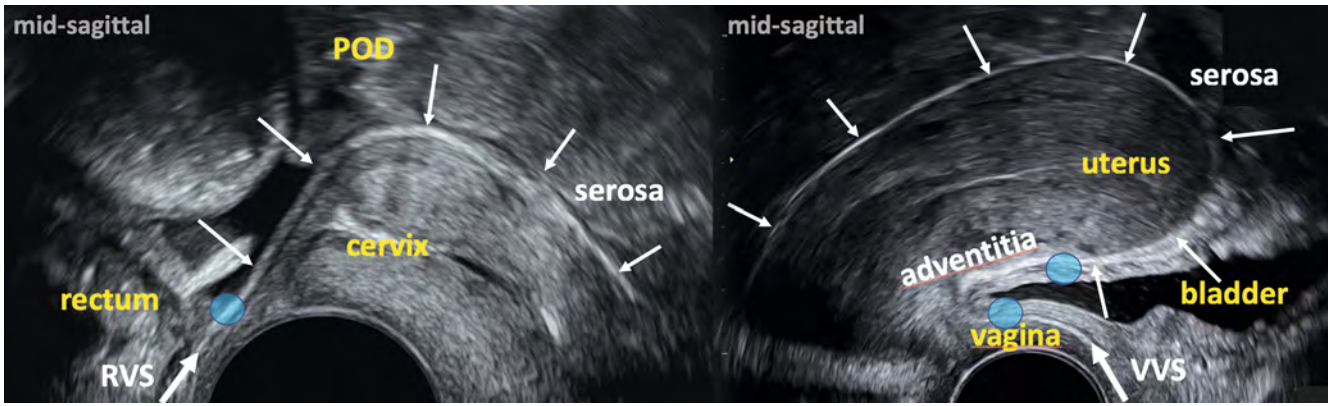
For TVS image orientation in **sagittal** planes, a headstand or footstand is used with patients looking either to the right or left (► **Fig. 1**). Following the central European standard [17, 18], we have chosen the TVS image orientation with the woman standing upright looking to the right, also presenting her bladder on the right side (► **Video 1**). The second main plane used is the **trans-**



► **Fig. 2** Recommended TVS view. LSC: laparoscopy; TVS: transvaginal sonography.



► **Video 2** How to reach footstand TVS view



► **Fig. 3** White Sliding Line (WSL). RVS: rectovaginal septum; VVS: vesicovaginal septum.

► **OP-VIDEO**

► **Video 3** White Sliding Line (WSL). VVS: vesicovaginal septum; RVS: rectovaginal septum

► **OP-VIDEO**

► **Video 4** Compartmentation. Image on the right: adapted from Schünke M, Schulte E, Schumacher U, Voll M, Wesker K. 6.23 Schnittbildanatomie des weiblichen Beckens. In: Schünke M, Schulte E, Schumacher U, Voll M, Wesker K, Hrsg. Prometheus LernAtlas – Innere Organe. 5. Auflage. Stuttgart: Thieme; 2018. doi:10.1055/b-006-149 645

verse plane. It runs from right to left and is ideal for lateral comparisons. The investigators should consciously choose and switch between sagittal and transverse planes and use them to start a dynamic examination with individually adapted planes.

Matching the TVS view with the laparoscopic (LSC) view is crucial for preoperative diagnosis communication. Unlike TVS, the LSC view shows the sliding peritoneal surface at a glance. We, therefore, recommend the important sliding mobility exploration in TVS by working with a mental image of the typical LSC view (looking down from the umbilicus to the pelvis) (► **Fig. 2**). TVS examiners who choose the image orientation with the woman on the handstand (top-down) may work directly with the LSC view. To match the footstand image orientation in TVS (bottom-up) with the LSC view (► **Fig. 2**), examiners should turn the mental LSC image 180 degrees (► **Video 2**).

### 3 Extending the sliding sign for comprehensive endometriosis diagnosis

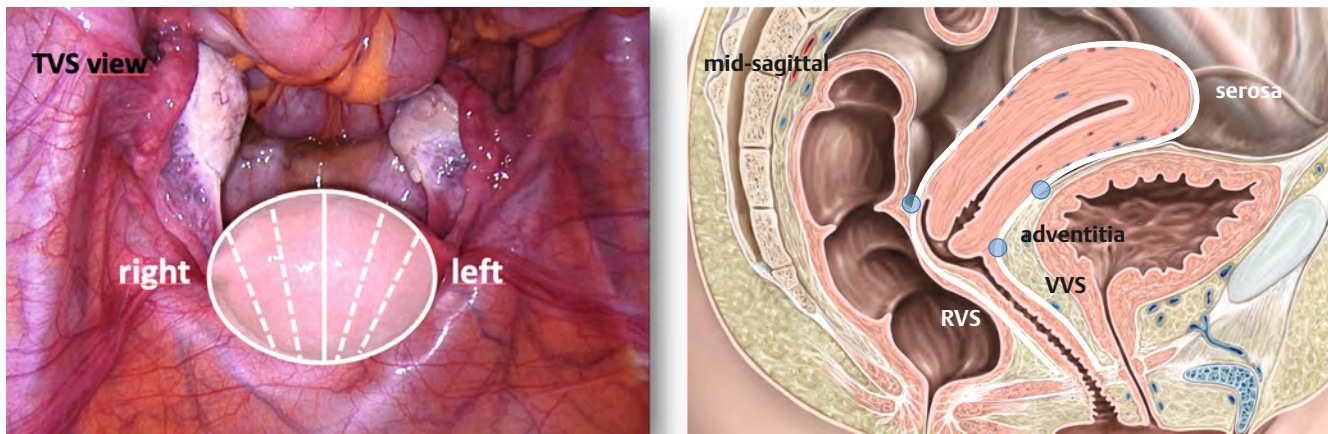
We use *mobility* for any shifting, position change, or dislocation of organs and structures, spontaneously occurring or manually provoked. *Sliding mobility*, or simply *sliding*, refers to the physiological

shifting of organs and structures against each other along two surfaces.

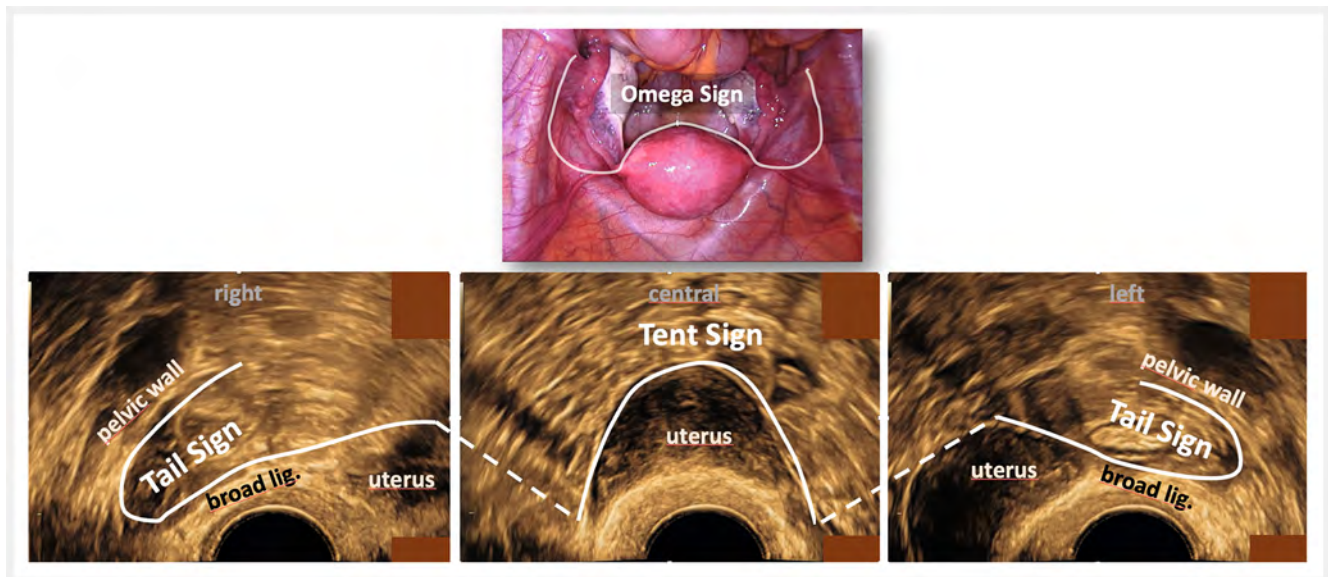
We propose extending the *sliding sign*, formerly described as sliding limited to the back side of the uterus [19, 20], in any direction to analyze all *sliding mobility* visible in the true pelvis. In a highly dynamic investigation, looking for impairment or even loss of sliding should be the first step in TVS assessment, as when searching for adhesions and detecting endometriotic lesions or tumors [19, 20].

#### 3.1 The White Sliding Line (WSL)

The critical element for judging the sliding mobility in the pelvis is establishing the *White Sliding Line (WSL)*, (► **Fig. 3**) in the **mid-sagittal plane** through the uterus. With the gently continuous application of pressure against the anteфлекted uterus and the vaginal wall by the ultrasound probe from the anterior fornix (from the posterior fornix in the case of a retroflexed uterus), the complete uterine surface gets progressively exposed as a curved thin white line, representing the central part of the WSL (► **Fig. 3** right, ► **Video 3**).



► **Fig. 4** White Sliding Line (WSL) right-left extension. RVS: rectovaginal septum; VVS: vesicovaginal septum. Image on the right: adapted from Schünke M, Schulte E, Schumacher U, Voll M, Wesker K. 6.23 Schnittbildanatomie des weiblichen Beckens. In: Schünke M, Schulte E, Schumacher U, Voll M, Wesker K, Hrsg. Prometheus LernAtlas – Innere Organe. 5. Auflage. Stuttgart: Thieme; 2018. doi:10.1055/b-006-149 645.



► **Fig. 5** Tent sign, tail sign, and omega sign.

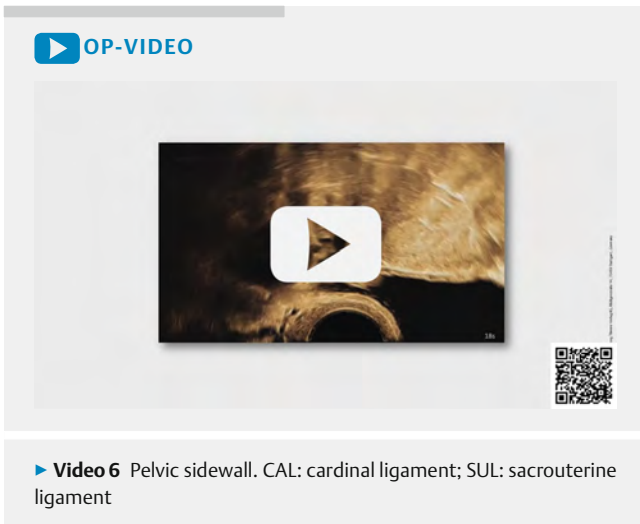
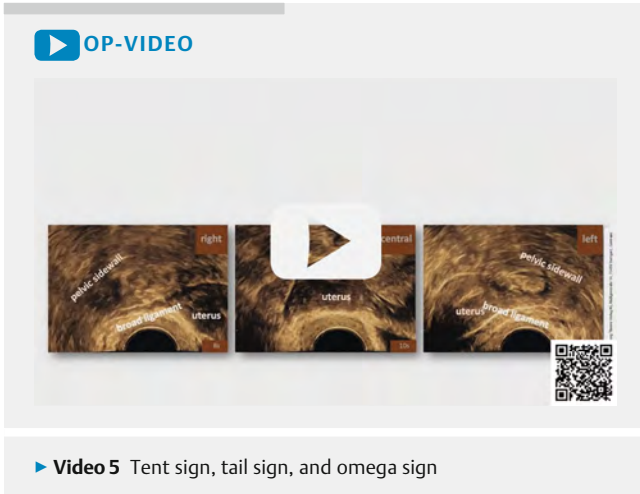
Physiologically, the WSL shows free sliding between the uterus and its surroundings. Posteriorly, at the posterior fornix, this white line merges directly into the equally echogenic *rectovaginal septum* (RVS) (► **Fig. 3** left). It runs at the backside of the vagina down to the anal verge. Anteriorly, at the anterior fornix, this white line merges directly into the equally white-appearing *vesicovaginal septum* (VVS) (► **Fig. 3** right). It runs to the introitus first between the vagina and the bladder, then between the vagina and urethra. Optimum dynamic exposure shows this line as a **continuous white line** from the ventral introitus along the anterior vaginal wall around the uterus and the backside of the vagina dorsally to the anal verge (► **Video 3**).

The mid-sagittal WSL can be accompanied by the other sagittal planes through the uterus and vagina from right to left. The accumulation of all resulting white lines around the uterus and vagina represents an almost closed white 3 D envelope (► **Fig. 4**), which

corresponds to the well-known uterovaginal fascia [21]. Furthermore, the *WSL* plays an essential role by defining clear and reliable borders between the five compartments.

### 3.2 The tent sign, tail sign, and omega sign

If the ultrasound probe is rotated in the transverse plane while maintaining constant, gentle pressure, an echogenic, sharp white line runs horizontally from right to left along the back of the uterus, visible from the fundus to the cervix. Like the WSL, it corresponds to the serosa of the uterus. We call it the *tent sign* (► **Fig. 5**, ► **Video 5**). Tracking the prolongation of the *tent sign* laterally beyond the uterus at the dorsal sheet of the broad ligament and further to the lateral pelvic sidewall results in a tail-like curved white line, which we call the right and left *tail sign* (► **Video 5**). We refer to the resulting closed white line, representing the *tent sign* in the center and the left and right *tail signs*



on the laterals as the *omega sign* (▶ Fig. 5, ▶ Video 5, 6). Sliding along the omega sign should be fully detectable on the entire posterior surface of the uterus and broad ligaments.

## 4 Practical approach for endometriosis diagnosis by TVS

Pelvic endometriosis evaluation by TVS starts with the basic sonographic examination as usual (“basic TVS”) [17, 18]. All non-endometriotic findings should be described and proceed following the given standards. The comprehensive evaluation for endometriosis is directly connected to the basic examination. The examiners should strictly follow a well-developed examination protocol (▶ Table 2). The presented concept shows the suggested sequence for working through the compartments and structures (▶ Table 1, 2, ▶ Video 4). We propose the application of five compartments in the pelvis (▶ Table 1, ▶ Video 4), defined by the WSL, containing a total of 35 relevant sliding qualities, structures, and organs (▶ Table 2), as described in IDEA 2016 [8] and its extensions. Our proposal provides direct preparation for classifying the endometriotic findings with #ENZIAN [16] (▶ Fig. 6).

▶ **Table 1** Compartment Definition.

Compartments	Definitions	Content
<i>Leading structure</i>	“White Sliding Line” (WSL)	WSL, VVS, RVS
Anterior	Ventral to WSL	Sliding, bladder, ureters
Central	Enclosed by WSL	Tent sign, uterus, vagina, POD
Posterior	Posterior to WSL	RVS, rectum
Lateral right/left	Lateral to WSL (lateral to uterus/vagina)	Sliding, omega sign, ovaries, tubes, uterus, bowel, ligaments

WSL: White Sliding Line; VVS: vesicovaginal septum; RVS: rectovaginal septum; POD: pouch of Douglas

The term nodule is suitable for describing the palpable findings of a hard nodular resistance in the pelvis. In contrast, on TVS, endometriotic lesions typically appear as discrete, blurred, hypoechoic changes in the tissue of varying size and shape in favored locations. They often do not resemble a nodule and are hard to detect. Therefore, the term *lesion* should be preferred for TVS.

IDEA 2016 and #ENZIAN [8, 16] define only lesions at a sub-peritoneal depth of 5 mm or more as **DE**. All thinner lesions are counted as superficial. For hollow organs such as bowels, bladder, and ureters, **DE partial thickness defects** reach the muscular layer, and **DE full thickness defects** involve the complete muscular layer. They may reach or even penetrate the submucosal layer. The infiltrated layers should be documented (adventitia/peritoneal border, muscularis, submucosa, mucosa/urothelium).

Conscious navigation through the pelvis, exposing the region of interest as best possible, is mandatory to avoid missing relevant pathologies while taking the patient’s comfort into account at the same time. The examiner’s free hand rests on the suprapubic region and gently applies pressure toward the true pelvis, supporting the exposure of dedicated structures and sliding between them. We use the following self-explaining terminology to describe the **movements of the ultrasound probe: up, down, right, left, push, pull, and rotate**. It is important to note that the pen-like **ultrasound probe** used for TVS **pivots** around an intravaginal **center point** close to the introitus, and the **terminology describes the movements of the probe tip**. In contrast, the probe guiding hand must move automatically in the opposite direction for the pivoting motions, which are up, down, right, and left.

The proper machine settings, mainly the optimal magnification scale, allow the inspection of the investigated structure/organ (region of interest) in detail at a glance.

► **Table 2** Checklist.

Checklist Endometriosis evaluation						
Procedure	Examination sequence	Definition, mobility, and organs/structures	#ENZIAN classification		Findings	DOC*
<b>Preparation</b>	1	Routine transvaginal sonography (TVS) including biometry and description of any other pathology than endometriosis or adenomyosis (polyps, myomas, congenital anomalies, adnexal tumors, etc.)				
	2	Expose the complete sagittal <i>White Sliding Line (WSL)</i>				
<b>Compartment evaluation</b>						
<b>Anterior</b>		<b>Definition: ventral to WSL</b>				
Sliding (impaired? block sign?)	3	Vesicouterine region (VUR)	Fb			
	4	Bladder dome	Fb			
Lesion (DE?)	5	Bladder wall** (trigonum, base, dome, extra-peritoneal)	Fb			
	6	Vesicovaginal septum (VVS)	Fb			
	7	Ureter right	Fu			
	8	Ureter left	Fu			
<b>Central</b>		<b>Definition: enclosed by WSL</b>				
Sliding (impaired? block sign?)	9	Uterine serosa (WSL)	T2,3			
	10	<i>Tent sign</i> (entire dorsal uterine serosa), transverse	T2,3			
	11	Pouch of Douglas (POD)	T2/3			
Lesion (DE? superficial?)	12	Adenomyosis	Fa			
	13	Vaginal wall anterior	A			
	14	Vaginal fornix anterior	A			
	15	Vaginal fornix posterior	A			
	16	Vaginal wall posterior	A			
<b>Posterior</b>		<b>Definition: posterior to WSL</b>				
Lesion (DE? superficial?)	17	Rectovaginal septum (RVS)	A			
	18	Rectal wall anterior (< 16 cm to anal verge)**	C			
	19	Intestinal wall anterior (> 16 cm to anal verge)**	Fi			
<b>Lateral</b>		<b>Definition: lateral to WSL</b>				
	<b>Right</b>		Right			
Sliding (impaired? block sign?)	20	<i>Right tail sign</i>	T1,2,3			
	21	Between ovaries, tubes, uterus, bowel, ligaments	T1,2,3			
Lesion (DE? superficial?)	22	Broad ligament (dorsal sheath)	B			
	23	Pelvic sidewall	B			
	24	Cardinal ligament (CAL)	B			
	25	Sacruterine ligament (SUL)	B			
	26	Endometrioma(s)	O			
	27	Tube***	T			

► **Table 2** (Continuation)

Checklist Endometriosis evaluation						
Procedure	Examination sequence	Definition, mobility, and organs/structures	#ENZIAN classification		Findings	DOC*
			Left	Left/right		
Sliding (impaired? Block Sign?)	28	Left tail sign	T1,2,3	T /		
	29	Between ovaries, tubes, uterus, bowel, ligaments	T1,2,3	T /		
Lesion (DE? superficial?)	30	Broad ligament	B	B /		
	31	Pelvic sidewall	B	B /		
	32	Cardinal ligament (CAL)	B	B /		
	33	Sacrouterine ligament (SUL)	B	B /		
	34	Endometrioma(s)	O	O /		
	35	Tube***	T	T /		

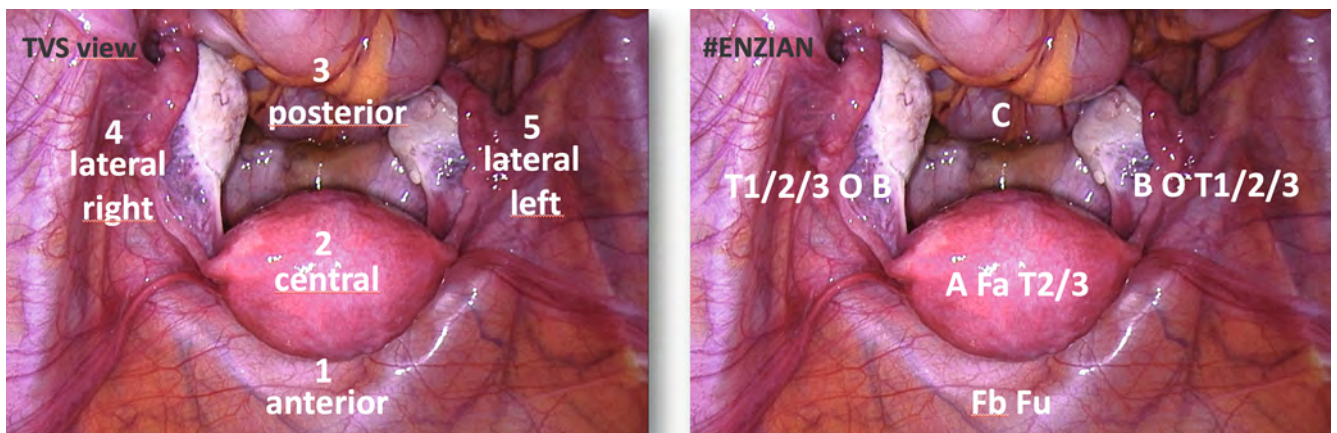
Forms of impaired sliding: free, reduced, fixed; DE lesion: definition by #ENZIAN  $\geq 5$  mm from the surface, measured in three dimensions; in bowel nodule: measure distance from anal verge to lowest end of lesions, indicate with or without internal obstruction.

\* documentation (photos, movies, drawings).

\*\* Definition of partial or full thickness defect by IDEA affecting bowel and bladder: in full thickness defect the nodule affects the complete muscular layer, in partial thickness defect only parts of it are affected.

\*\*\* if visible.

Download available on [www.sgumgg.ch](http://www.sgumgg.ch)



► **Fig. 6** Compartmentation and #ENZIAN classification. TVS: transvaginal sonography.

## 4.1 Anterior compartment

### 4.1.1 Definition

The anterior compartment is defined by organs and structures ventral to the WSL, principally represented by the bladder and the ureters (“urologic compartment”) (► Fig. 8, ► Video 7, ► Table 2).

Sliding should be observable along the WSL on the ventral uterine serosa, at the bladder dome, and in the subperitoneal vesicouterine region, corresponding to the adventitia (► Fig. 3), but not at the VVS. Impaired sliding mainly occurs at the surface of the bladder dome (► Fig. 9) due to adhesions to the bowel or at the bladder base. DE in this compartment appears preferably in the median part of the bladder at the bladder base (► Video 8) or dome and at the ureters at the undercrossing of the uterine vessel complex (UVC, containing the uterine artery) [22, 23]. Lesions may affect all layers of the bladder and ureters, single or multiple.

Endometriotic lesions affecting the bladder area are reported as #ENZIAN Fb, and lesions affecting the ureters as #ENZIAN FU (► Fig. 7a) [16].


### 4.1.2 Assessment

A lightly or moderately filled bladder is advantageous. It may be necessary to postpone the examination of this compartment to the end of the workup if the bladder is empty.

The probe is placed in the center of the anterior vaginal fornix **sagittally**, also in retroflexed uteri. The proper settings, mainly the optimal magnification scale, allow the inspection of the entire bladder circumference in one plane at a glance.

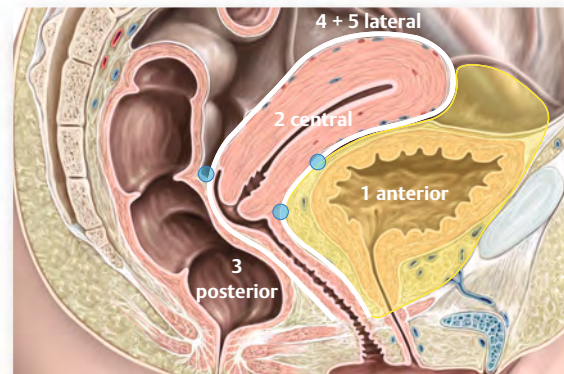
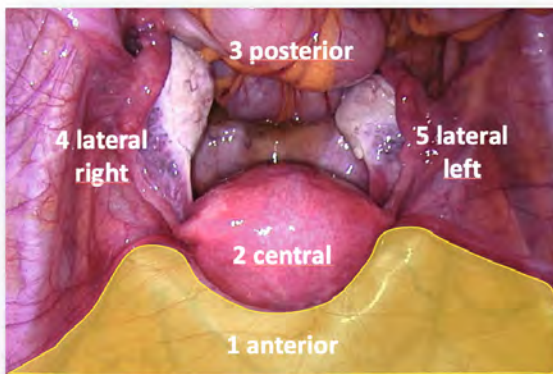
### 4.1.3 Vesicouterine region (VUR)

The vesicouterine region is a typical site for reduced or absent sliding mobility due to endometriotic adhesions or prior surgery, commonly seen after cesarean sections (► Video 9), but also for DE lesions (► Video 8), with or without the bladder wall being affected [24].



► Fig. 7 a QR code for #ENZIAN-App in App store (Apple iOS); b QR code for #ENZIAN-App in Google Play store (Android).

Definition	Ventral to White Sliding Line (WSL)	#ENZIAN
<b>Sliding</b>	<b>Vesicouterine region (VUR)</b> <b>Bladder dome</b>	Fb
<b>Lesions</b>	<b>Bladder wall (trigonom, base, dome, extraperitoneal)</b> <b>Vesicovaginal septum (VVS)</b> <b>Ureter right</b> <b>Ureter left</b>	Fb Fu Fu Fu




► Fig. 8 **Anterior compartment.** Image on the right: adapted from Schünke M, Schulte E, Schumacher U, Voll M, Wesker K. 6.23 Schnittbildanatomie des weiblichen Beckens. In: Schünke M, Schulte E, Schumacher U, Voll M, Wesker K, Hrsg. Prometheus LernAtlas – Innere Organe. 5. Auflage. Stuttgart: Thieme; 2018. doi:10.1055/b-006-149 645.



▶ OP-VIDEO

Anterior Compartment

Definition	Ventral to White Sliding Line (WSL)	BENZIAN
Sliding	Vesicouterine region (VUR) Bladder dome	Fb
Lesions	Bladder wall (trigonum, base, dome, extraperitoneal) Vesicovaginal Ureter Ureter I	Fb Fu Fu



▶ Video 7 Anterior compartment

▶ OP-VIDEO

Proposal for "VUR obliteration" definition:

**NO VUR obliteration is considered, if ...**  
**the bladder submucosa slides on the anterior cervix**  
**OR**  
**intestine slides down to the uterine s...**

No C-Section...



No obliteration. Intestine touches the isthmus. Submucosa slides freely.

After C-Section...



No obliteration. Intestine does not reach the isthmus. Submucosa slides freely.



Obliteration. Intestine does not reach the isthmus. Submucosa does not slide.

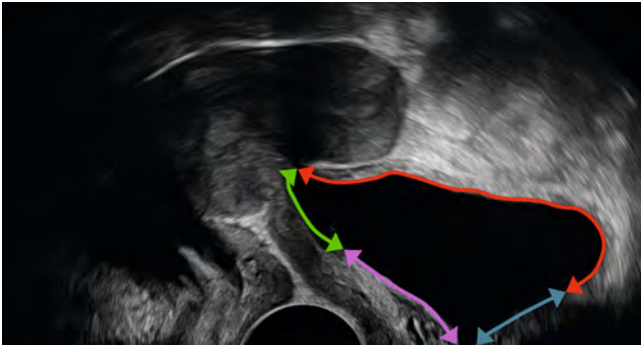


Obliteration? UVR not appropriately examined. Intestine does not reach the isthmus.



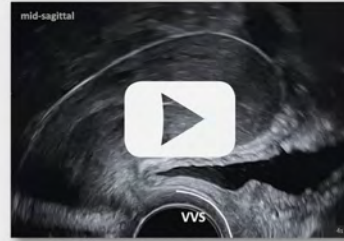
No obliteration. Intestine does not reach the isthmus. Submucosa slides freely.

▶ Video 9 Sliding in the vesicouterine region (VUR).



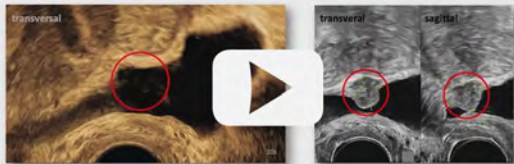
▶ Fig. 9 Bladder regions. The trigonal zone (purple) is a smooth triangular region bounded by the two ureteral openings and the internal urethral opening. The bladder base (green) is directed posteriorly and borders the vagina and the supravaginal portion of the uterine cervix. The bladder dome (red) is located above the base and is intraperitoneal. The extraperitoneal area (blue) of the bladder is located anteriorly or opposite the bladder dome.

▶ OP-VIDEO



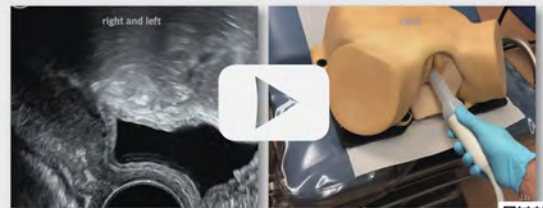▶ Video 10 Vesico-vaginal septum (VVS). Dynamic investigation.

▶ OP-VIDEO



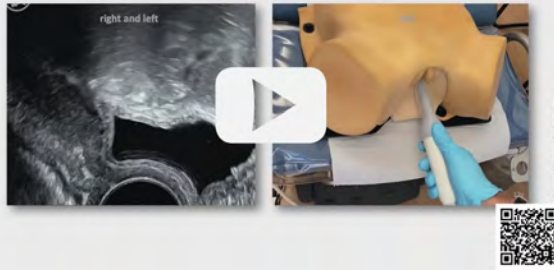▶ Video 8 Bladder wall lesion after hysterectomy. DE nodule at the bladder base (red circle), full thickness defect. #ENZIAN: FB.

▶ OP-VIDEO




▶ Video 11 Right distal ureter presentation

## ▶ OP-VIDEO



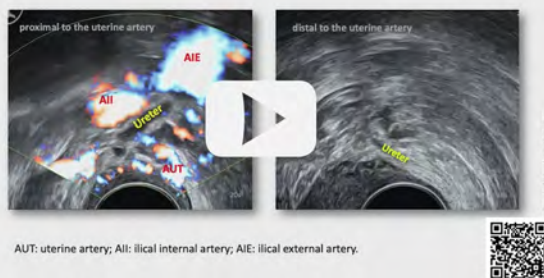
▶ Video 12 Left distal ureter presentation

## ▶ OP-VIDEO



▶ Video 13 Ureter jet sign. The jet sign occurs approximately 1 to 4 times per minute.

## ▶ OP-VIDEO



AUT: uterine artery; All: iliac internal artery; AIE: iliac external artery

▶ Video 14 Ureter course. AUT: uterine artery; All: iliac internal artery; AIE: iliac external artery

## 4.1.4 Bladder

DE of the bladder belongs to the most common sites (number 4 of the top 5, 6%) [15]. Lesions may be discovered by consciously steering the probe in a **sagittal** plane from right to left and then switching to the **transverse** plane, moving from cranial to caudal for scanning the entire bladder wall in all four zones (▶ Fig. 9) [8].

## 4.1.5 Vesicovaginal septum (VVS)

With correct **sagittal** exposure on TVS, the VVS appears as a thin white line, running from the pelvic floor to the cervix behind the vagina, representing its adventitia. The VVS is the ventral part of the WSL. No physiological sliding is visible at the VVS between the bladder wall or urethra and the vagina (▶ Video 10). These structures may only be stretched, accompanied by remarkable bladder and vaginal wall thinning and displacement. DE lesions are rarely observed at this site.

## 4.1.6 Right and left ureters

To assess the **hypoechoic tubular** right and left ureters, the internal urethral meatus should first be identified **sagittally** (▶ Video 11, 12). The probe is then gently moved right or left towards the investigated side, whereby the investigator's guiding hand may come close to the patient's contralateral thigh and rotated slightly outward (about 30 degrees clockwise for the right side and 30 degrees counterclockwise for the left side). Identifying the intramural part of the ureter is facilitated by a lightly or moderately filled bladder. Waiting for peristalsis, occurring approximately 1 to 4 times per minute, also called *vermiculation*, is particularly helpful as it confirms kidney function and ureter patency. Using CD, a high-flow urine jet into the bladder can often be documented, occasionally presenting color flow in the prevesical ureter (▶ Video 13). Visualization up to the under-crossing of the UVC is usually successful (▶ Video 14). Beyond the pelvis, the ureters and the kidneys should be assessed by TAS for hydronephrosis. A urethral inner diameter of more than 5 mm is suspicious for urethral obstruction [16]

DE lesions at the dorsolateral cervix, potentially obstructing the ureters, represent a common location (number 5 of the top 5, 2%) [15].

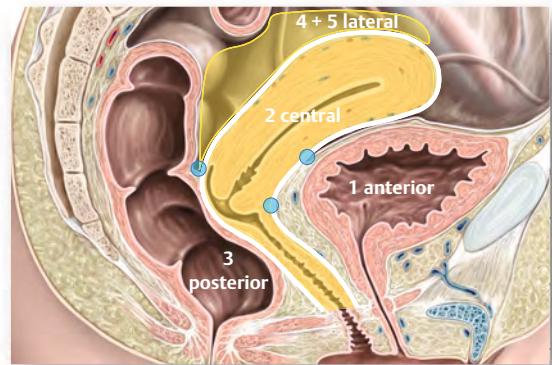
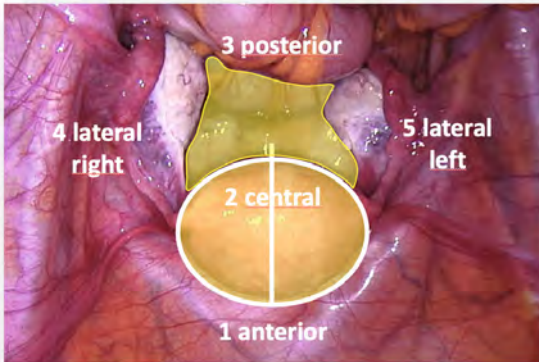
## 4.2 Central compartment

## 4.2.1 Definition

The central compartment is defined by organs and structures encircled by the WSL, principally represented by the uterus and vagina (*"gynecologic compartment"*) (▶ Table 2).

Sliding should be seen along the WSL on the entire free peritoneal surface, represented by the uterine serosa (▶ Fig. 10, ▶ Video 15). Impaired or absent sliding may be seen on all parts of the serosa and should be carefully worked out dynamically (▶ Video 16). DE lesions in this compartment are common, occurring preferably at the lower POD (levels II and III, ▶ Fig. 11) and the vaginal fornices, also affecting the vaginal wall [15]. Furthermore, the uterus is checked in detail for signs of adenomyosis [6].

Definition	Enclosed by WSL	#ENZIAN
<b>Sliding</b>	<b>Uterine serosa (WSL)</b> <b>Pouch of Douglas (POD)</b> <b>Tente Sign</b> (entire dorsal uterine serosa, transversal)	T2,3 T2,3 T2,3
<b>Lesion</b>	Uterus, <b>adenomyosis</b> <b>Vaginal wall anterior</b> <b>Vaginal fornix anterior</b> <b>Vaginal fornix posterior</b> <b>Vaginal wall posterior</b>	Fa A A A A



► **Fig. 10 Central compartment.** Image on the right: adapted from Schünke M, Schulte E, Schumacher U, Voll M, Wesker K. 6.23 Schnittbildanatomie des weiblichen Beckens. In: Schünke M, Schulte E, Schumacher U, Voll M, Wesker K, Hrsg. Prometheus LernAtlas – Innere Organe. 5. Auflage. Stuttgart: Thieme; 2018. doi:10.1055/b-006–149 645.

**OP-VIDEO**

**Central Compartment**

Definition	Enclosed by WSL	#ENZIAN
<b>Sliding</b>	Uterine serosa (WSL) Pouch of Douglas (POD) Tente Sign (entire dorsal uterine serosa, transversal)	T2,3 T2,3 T2,3
<b>Lesion</b>	Uterus, <b>adenomyosis</b> Vaginal wall anterior Vaginal fornix anterior Vaginal fornix posterior Vaginal wall posterior	Fa A A A A

► **Video 15** Central compartment

**OP-VIDEO**

Combine: dynamic navigation with TVS Probe ... and push with external hand.

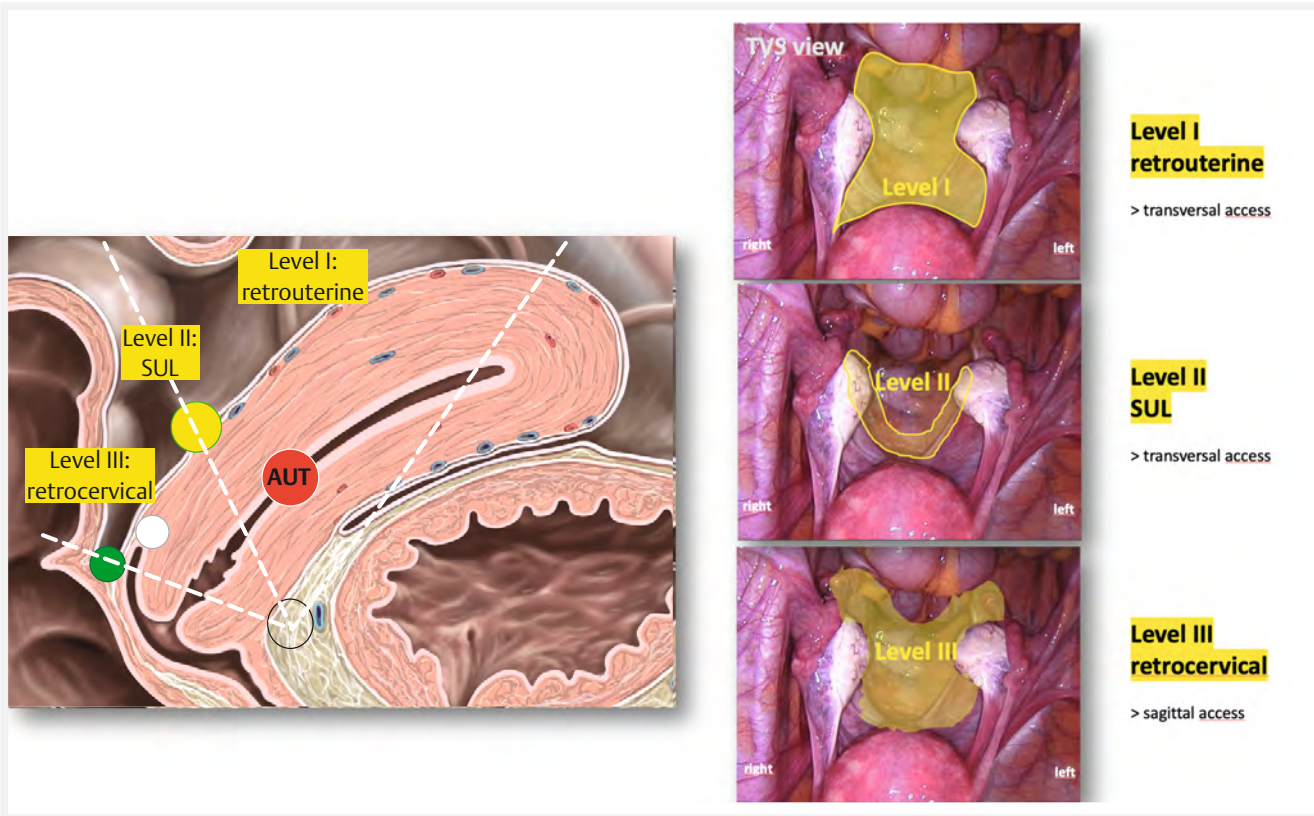
► **Video 16** Free uterus sliding

#### 4.2.2 Assessment

The anteфлекted uterus should be visualized first **sagittally** with the tip of the TVS probe in the anterior vaginal fornix and the retroфлекted uterus in the posterior vaginal fornix [17].

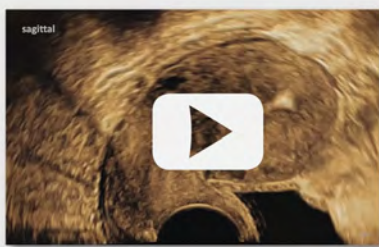The uterus' surface is checked for endometriotic lesions along the *WSL* in sagittal and parasagittal planes and transverse planes (*tente sign*), including a profound assessment of the POD by a highly dynamic investigation.

The anterior vaginal wall with the anterior fornix is inspected separately by pulling the TVS probe backward to the introitus while stretching the vaginal wall simultaneously, followed by examining the posterior vaginal wall the same way. These lesions are often smaller than 5 mm, so they do not fulfill the criteria of real DE. Therefore, we call them *endometriotic lesions* or simply *lesions*.



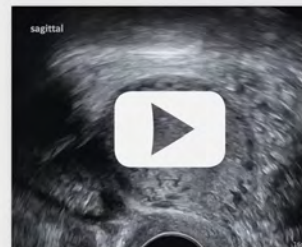
► **Fig. 11** Sonographic approach to the pouch of Douglas. SUL: sacrouterine ligament; AUT: uterine artery. Image on the left: adapted from Schünke M, Schulte E, Schumacher U, Voll M, Wesker K. 6.23 Schnittbildanatomie des weiblichen Beckens. In: Schünke M, Schulte E, Schumacher U, Voll M, Wesker K, Hrsg. Prometheus LernAtlas – Innere Organe. 5. Auflage. Stuttgart: Thieme; 2018. doi:10.1055/b-006-149645.

▶ OP-VIDEO



► **Video 17** Free POD sliding. POD: pouch of Douglas, definition by IDEA 2016: the space behind the uterus.

▶ OP-VIDEO



► **Video 18** Impaired POD sliding. #ENZIAN: T 3/0.

**▶ OP-VIDEO**



#ENZIAN T: tubo-ovarian conditions/adhesions to ...

- T1 pelvic sidewall
- T2 T1 and to uterus (POD)
- T3 T2 and to bowel and/or SUL

Observation



Sliding

- free
- reduced
- absent/no



▶ **Video 19** Sliding mobility – terminology

**▶ OP-VIDEO**



▶ **Video 22** Normal vaginal wall. Normal vaginal wall may be stretched to <3 mm thickness (dotted line).

**▶ OP-VIDEO**

▶ **Video 20** Question mark sign

**▶ OP-VIDEO**

▶ **Video 21** Adenomyosis. CYS: cystic inclusions; ISL: hyperechoic islands, LIN: echogenic sub-endometrial lines; BUD: buds

#### 4.2.3 Pouch of Douglas (POD)

The POD is defined as the entire space between the posterior uterus and the anterior rectum [8]. We follow the suggestion of IDEA 2016 of splitting the POD into three levels but propose the following division (▶ **Fig. 11**): The first level covers the area behind the uterine corpus from the fundus to the SULs. The SULs represent the narrow second level. The area behind the cervix from the SULs to the bottom of the pocket counts as the third level.

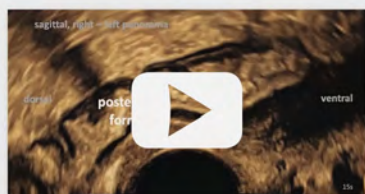Physiologically, the uterus freely slides within its serosa in the surrounding area (free sliding) (▶ **Video 17**). Impaired sliding typically occurs on the backside of the uterus along the WSL (▶ **Video 18**). With a specificity of 91–100 % and a sensitivity of 93–100 % for detecting local adhesions, it is a strong indicator of adhesions in the POD [19, 20]. Sliding may be judged as free, reduced, or absent (▶ **Video 19**), indicating the origin and end of a suspected adhesion, as well as the POD level (I, II, III) they affect. Occasionally, the uterus is found already in a forced position with the fundus leaning backward, leaving the cavity in the shape of a question mark (*question mark sign*) (▶ **Video 20**). This indicates significant adhesions pulling the uterine fundus or corpus backward to the bowel or the posterior pelvic wall.

A specific search should be conducted for adhesions and DE in the POD between the uterus and other structures, such as the bowel and ovaries. Levels II (SUL) and III (retrocervical) are most frequently affected. Adhesions in the POD are classified as #ENZIAN T2 or T3 (▶ **Fig. 7**) [16].

#### 4.2.4 Adenomyosis

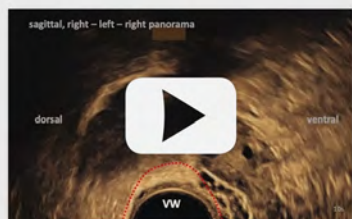The examiners should describe morphologic findings, especially all indicators of adenomyosis of the uterus, and assess them following the revised MUSA criteria [6]. Direct signs indicate the presence of an ectopic endometrium in the myometrium (cystic inclusions, hyperechoic islands, echogenic sub-endometrial lines, and buds) (▶ **Video 21**). Indirect signs may result from myometrium remodeling (globular uterus, asymmetric myometrial thickening, trans-lesional vascularity, fan-shaped acoustic shadows, irregular or disrupted junctional zone). Direct signs are diagnostic

## ▶ OP-VIDEO



▶ **Video 23** Thickened vaginal wall. Palpation reveals a hard line of tiny nodules,  $2 \times 0.5$  cm, 6 h, cranio-caudal in dorsal fornix. In TVS, the VW presents an increased thickness  $> 3$  mm (dotted red line) and inhomogeneous, small cystic irregularity. #ENZIAN: A2.

## ▶ OP-VIDEO

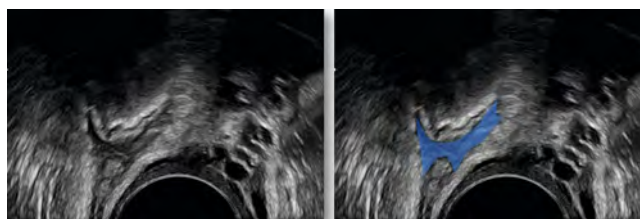


▶ **Video 24** Vaginal wall lesion – slip off sign. Palpation of a hard nodule of  $20 \times 5$  mm in the right dorsal fornix. In TVS, no proper nodule is visible. The vaginal wall (VW) only presents an increased thickness  $> 3$  mm (dotted red line) and inhomogeneous, small cystic irregularity, which tends to slip off. #ENZIAN: A2.

for adenomyosis, whereas indirect signs only serve as indicators. Adenomyosis is reported as #ENZIAN FA (▶ **Fig. 7**) [16].

#### 4.2.5 Vaginal wall

The vaginal walls belong to the three most common locations of endometriosis (number 3 of the top 5, 16%) [15]. They should be examined by palpation for single or multiple hard pinheads with a diameter of a few millimeters and then by ultrasound. The probe should be moved deliberately slowly from right to left over the anterior and posterior vaginal wall, including the fornices (▶ **Video 22**). Inhomogeneities, cysts, and small nodules in the vaginal wall are the typical findings (▶ **Video 23**). They tend to rush away (*slip off sign*). In our experience, the tip of the probe may stretch the healthy vaginal wall to a thickness of less than 3 mm (▶ **Video 24**). Local enlargements in the stretched vaginal wall exceeding 3 mm could be the sole ultra-



▶ **Fig. 12** Diabolo-like lesion. Left: Native DE lesion. Right: Marked DE lesion (blue).

sound representation of palpable, firm nodules. Furthermore, examiners should always search for the involvement of deeper structures: in the first layer, the VVS (anterior compartment) or the RVS (posterior compartment); in the second layer, the bladder wall anteriorly or the rectum wall posteriorly; and to the sides, the sacrouterine ligaments (SUL), the cardinal ligaments (CAL), and the ovaries (lateral compartments). Lesions in the vaginal wall are classified as #ENZIAN A1 for largest diameter  $< 1$  cm, A2 for 1 to 3 cm, and A3 for  $> 3$  cm (▶ **Fig. 7**) [16].

#### 4.2.6 Vaginal fornices

Suspicion of fornix endometriosis most frequently arises when a lesion occurs behind the cervix or when the posterior vaginal fornix appears thickened. Other possible involvement should be clarified (vagina, SUL, CAL, ureter, ovary, bowel). Rectovaginal lesions, which simultaneously involve the posterior fornix and the anterior rectal wall, are also referred to as “*diabolo-like lesions*” due to their typical angular hourglass-shaped appearance (▶ **Fig. 12**) [25]. These often-large lesions (with an average size of 3 cm) pass from the posterior fornix to the anterior rectal wall. They may be located below the peritoneum of the POD, rendering them poorly visible during laparoscopy [26]. Lesions in the vaginal fornices are classified as #ENZIAN A1 for largest diameter  $< 1$  cm, A2 for 1 to 3 cm, and A3 for  $> 3$  cm (▶ **Fig. 7**) [16].

### 4.3 Posterior compartment

#### 4.3.1 Definition

The posterior compartment is defined by organs and structures dorsal to the WSL, principally represented by the rectum/intestine (“*bowel compartment*”) (▶ **Table 2**).

Sliding mobility should be observable along the anterior rectal/intestinal serosa but not at the RVS (▶ **Fig. 13**, ▶ **Video 25**). DE lesions in this compartment occur preferably in the upper RVS and the anterior rectal wall.

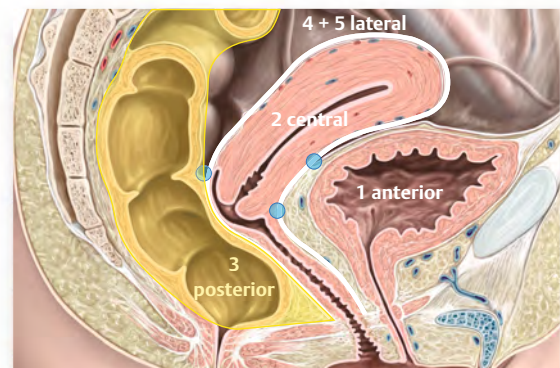
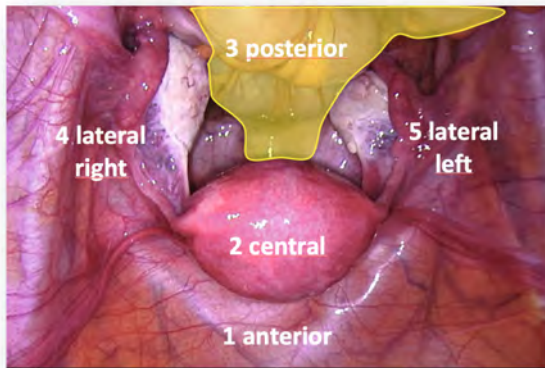
#### 4.3.2 Assessment

Examination of the rectum/intestine may be compromised by excessively meandering bowel loops with steep curves and the view obscuring faces. Nevertheless, the anterior wall of the rectum/intestine is usually visible up to the pelvic brim. Keeping the probe close to the target is crucial for appropriate image quality and judgment (▶ **Fig. 14**). Isolated DE lesions affecting the intestine are some of the most challenging lesions to detect.

**Definition:****Posterior to White Sliding Line (WSL)****#ENZIAN****Lesion**

Rectovaginal septum (RVS)  
 Rectum wall (<16cm to anal verge)  
 Intestinal wall (>16cm to anal verge)


A  
 C  
 Fi



► **Fig. 13 Posterior compartment.** Image on the right: adapted from Schünke M, Schulte E, Schumacher U, Voll M, Wesker K. 6.23 Schnittbild-anatomie des weiblichen Beckens. In: Schünke M, Schulte E, Schumacher U, Voll M, Wesker K, Hrsg. Prometheus LernAtlas – Innere Organe. 5. Auflage. Stuttgart: Thieme; 2018. doi:10.1055/b-006-149645.

▶ **OP-VIDEO**

Definition	Posterior to White Sliding Line (WSL)	#ENZIAN
Lesion	Rectovaginal septum (RVS) Rectal wall, anterior (<16cm to anal verge) Intestinal wall, anterior (>16cm to anal verge)	A C Fi



► **Video 25** Posterior compartment

We propose starting with RVS and bowel examination at the anal verge, proceeding from caudal to cranial in **sagittal** and parasagittal planes for RVS evaluation and then checking the anterior rectum/intestine from the posterior fornix following its center line (► **Video 25**). The bowel in the true pelvis, at least the anterior wall, may be visualized by TVS (8). Measuring rectal length is feasible [27].

At the deepest point of the peritoneal cavity, the RVS divides into an anterior branch, corresponding to the cervical serosa (WSL), and a posterior branch, corresponding to the rectal serosa

(► **Video 26**). This division is a topographic TVS landmark that represents the cranial end of the RVS and the beginning of the intra-abdominal free bowel.

#### 4.3.3 Rectovaginal septum (RVS) and bowel

In the case of reduced or absent sliding, examiners should describe the degree of suspicion for adhesions (► **Video 19**) and which organs are involved. DE lesions are judged to be either retrocervical, in the vaginal (fornix) wall, in the RVS (#ENZIAN A), or purely affecting the rectum (#ENZIAN C) (► **Fig. 7**) [16]. The largest diameter in a sagittal midline plane along the axis of the rectum is measured, and severity is assigned regarding the size: < 1 cm (A1 or C1, respectively), 1–3 cm (A2 or C2), > 3 cm (A3 or C3). The distance to the anal verge should be measured using the ultrasound probe as a measuring tool [27]. Lesions above 16 cm cranial to the anal verge are described as intestinal lesions (#ENZIAN Fi) (► **Fig. 7**) [16].

DE lesions of the bowel belong to the most common sites (number 2 of the top 5, 23%) [15]. Rectal DE lesions may be associated with a second intestinal lesion in more than 50% of cases [8]. Typically, bowel endometriosis appears as irregular, hypoechogenic lesions affecting the bowel wall (► **Video 27**). These lesions may present a regular elliptic shape but often exhibit an asymmetric, irregular shape, sometimes with spikes or tails. Working out the affected layers (► **Fig. 14**) is crucial since this has significant implications for surgical treatment. Retractions inside the anterior rectal wall may be visible if a bowel lesion is fixed

to the uterus or cervix. This phenomenon has been described as the *Indian headdress sign* or *moose antler sign* (▶ **Video 28**). Lesions with progressive narrowing, like a tail, have been described as the *comet sign* [8].

#### 4.4 Lateral compartments

##### 4.4.1 Definition

The right and left lateral compartments are defined by organs and structures lateral to the *WSL* (“*adnexal compartment*”): (▶ **Fig. 15**, ▶ **Video 29**, ▶ **Table 2**). The upper border of this compartment corresponds to the cranial border of the external and common iliac artery.

##### 4.4.2 Assessment

The lateral compartments are generally investigated starting in the ipsilateral fornix using a **transverse** plane.

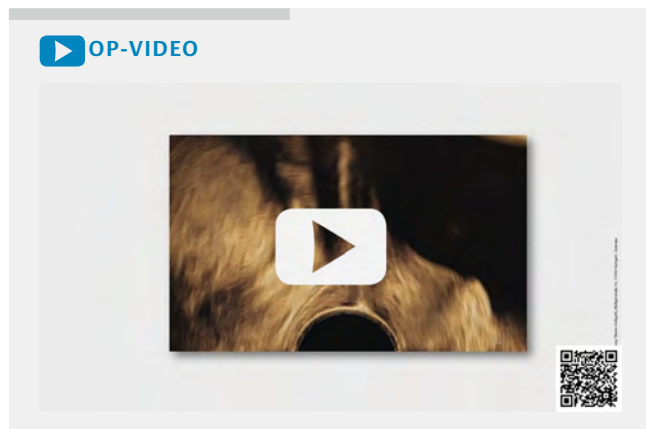
Sliding mobility should be verifiable along all peritoneal surfaces, except at the broad ligament, where only the dorsal sheet is

accessible (▶ **Video 30, 31**). The guiding sliding line is the **transversally** (horizontally) running *omega sign* (▶ **Video 5**), presentable on the backside of the uterus and broad ligaments.

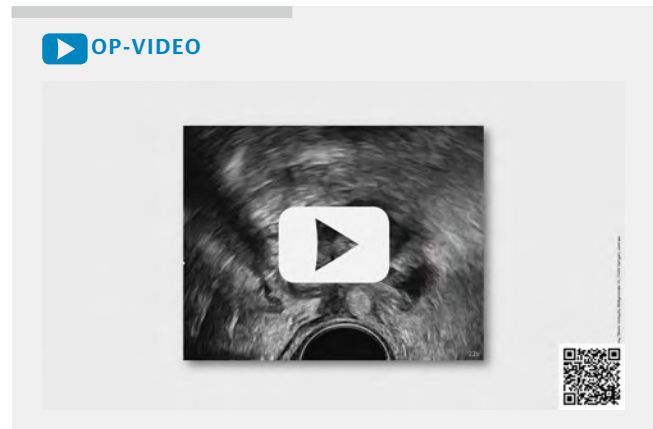
Whenever one or more tiny, hard nodules are palpated on the lateral posterior vaginal fornix, TVS should assign the nodule to the vaginal wall, SUL, or components and organs in the peritoneal cavity, such as the ovary and bowel. Several of them may appear stuck together, and move as a block (*block sign*, ▶ **Video 32**), which can also be recognized by the lack of physiological distance between them when the probe is withdrawn quickly.

##### 4.4.3 Ovaries

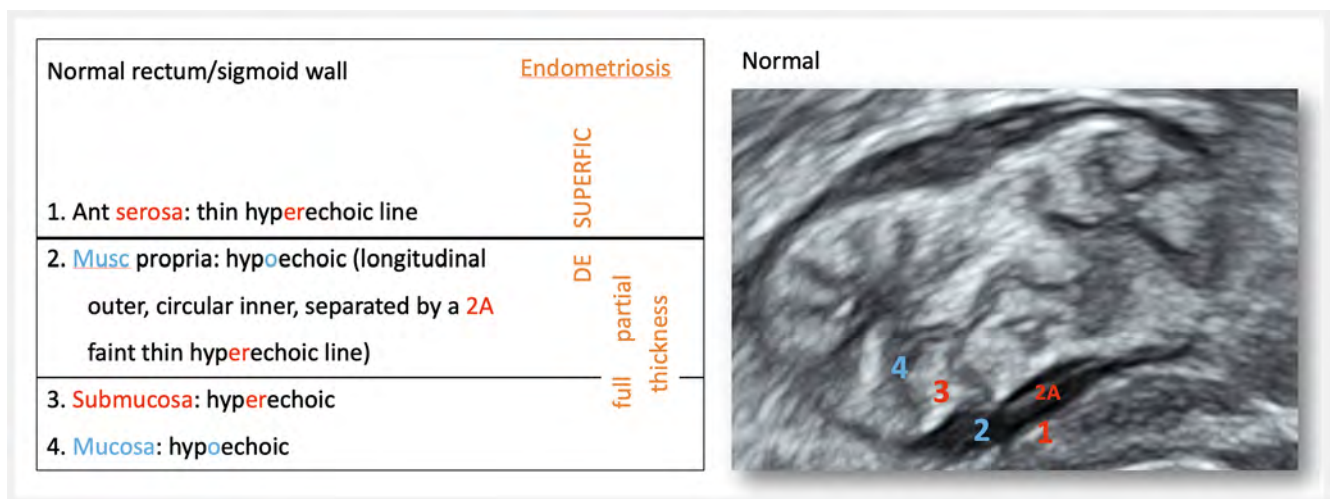
Endometriomas represent a proper entity of endometriosis manifestation [5]. They affect only the ovaries, are typically asymptomatic, and are found in > 10% of women with subfertility [28]. They appear as one of the typical four elementary benign adnexal tumors [29]. In about 50% of cases, endometriomas present a uniform pattern of a smooth-walled unilocular cyst of homogeneous ground glass echogenicity, containing no acoustic stream-



▶ **Video 26** Rectovaginal septum (RVS) “splitting”. Blue circle: upper end of RVS



▶ **Video 27** Intestinal DE lesion. Mushroom-shaped lesion. Full thickness defect. #ENZIAN: FI.



▶ **Fig. 14** Sonoanatomy of visceral organs.

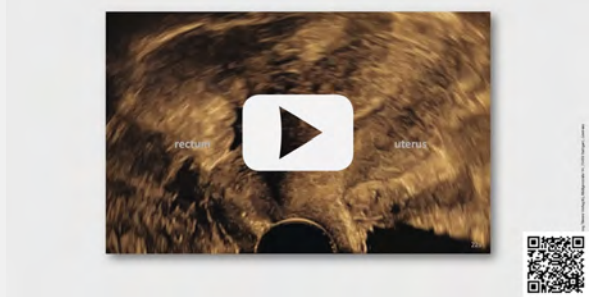


ing [5]. Endometriomas are rarely isolated findings [30]. They often occur with other potentially painful endometriotic lesions, such as adhesions in >70% of cases and DE in >50% [28, 31]. The most common differential diagnosis is the self-limiting hemorrhagic cyst, typically presenting a spider-web-like, retracting clot and resolving over time. Endometriomas should be documented in number, three perpendicular measurements each, and the type appearance (typical or atypical) [5]. The sum of all endometrioma diameters should be calculated for each ovary (side-separated) and classified by #ENZIAN; O1 (sum of diameters <3 cm), O2 (3–7 cm) or O3 (>7 cm) (▶ **Video 33**, ▶ **Fig. 7**) [16].

In a situs with one or more endometriomas, a careful and comprehensive evaluation should include the search for impaired sliding as an indication of adhesions and DE. Mobility terminology is not yet uniform (▶ **Video 19**). The ovaries are slightly pushed cranially by gently applying axial or paraxial pressure (▶ **Video 34**). If the ovaries do not slide against the pelvic sidewall, the broad ligament, or the surrounding bowels, lateral adhesions must be considered (#ENZIAN T1) (▶ **Video 35**). In our experience, it is less challenging to demonstrate free or impaired sliding against the medial structures (uterus, vagina). The tubal-ovarian complex with the indication of adhesions to the uterus is classified as #ENZIAN T2. Additional adhesions to the bowel or SULs are classified as #ENZIAN T3, leading to a moving block (*block sign*) (▶ **Video 32**, ▶ **Fig. 7**) [16].

The *kissing ovaries sign* describes both ovaries (with or without endometriomas) fixed together behind the uterus in the POD (▶ **Video 36**). Pushing the probe between them does not separate them but probably causes pain, leading to the conclusion of a high probability of adhesions corresponding to #ENZIAN T3. This is particularly important for preoperative planning [32] since intestinal involvement is more likely in patients with *kissing ovaries* than in those with other endometriosis manifestations [32].

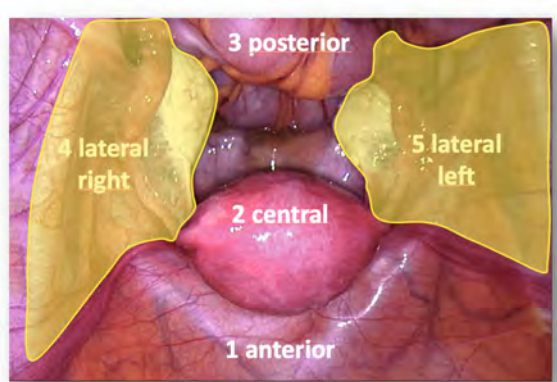
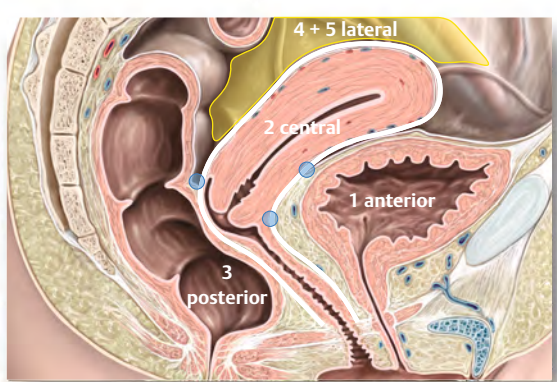
▶ **OP-VIDEO**



▶ **Video 28** Rectal DE lesion. Indian headdress sign or moose antler sign. Full thickness defect. #ENZIAN: C2.

Definition	Lateral to White Sliding Line (WSL), right / left	#ENZIAN
<b>Sliding</b>	<b>Tail Sign</b> Between tubes, ovaries, uterus, bowel, ligaments	T1,2,3 T1,2,3
<b>Lesion</b>	<b>Broad ligament</b> <b>Pelvic sidewall</b> Ovary, <b>endometrioma</b> <b>Tube</b> <b>Cardinal ligament (CAL)</b> <b>Sacrouterine ligament (SUL)</b>	B B O T B B

▶ **Fig. 15 Lateral compartments.** Image on the right: adapted from Schünke M, Schulte E, Schumacher U, Voll M, Wesker K. 6.23 Schnittbildanatomie des weiblichen Beckens. In: Schünke M, Schulte E, Schumacher U, Voll M, Wesker K, Hrsg. Prometheus LernAtlas – Innere Organe. 5. Auflage. Stuttgart: Thieme; 2018. doi:10.1055/b-006-149645.

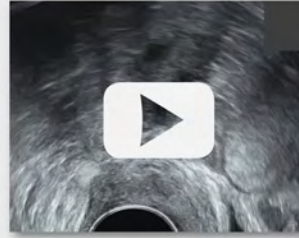
▶ OP-VIDEO

Definition	Lateral to White Sliding Line (WSL), right and left	#ENZIAN
Sliding	Tail signs Between ovaries, tubes, uterus, bowel, ligaments	T1,2,3 T1,2,3
Lesion	Ovaries (endometrioma) Tube (if visible) Broad ligaments (dorsal sheath) Pelvic side Cardinal Sacroute	O T B B B B




▶ Video 29 Lateral compartment

▶ OP-VIDEO



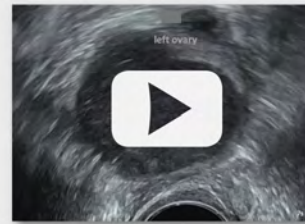▶ Video 32 Block sign. «Moving block» involving vaginal wall, SUL, ovary, bowel. #ENZIAN: A2 B3/0 T3/0.

▶ OP-VIDEO




▶ Video 30 Right tail sign

▶ OP-VIDEO



▶ Video 33 Endometrioma. «Moving block» involving vaginal wall, SUL, ovary, bowel. #ENZIAN: A2 B3/0 T3/0.

▶ OP-VIDEO



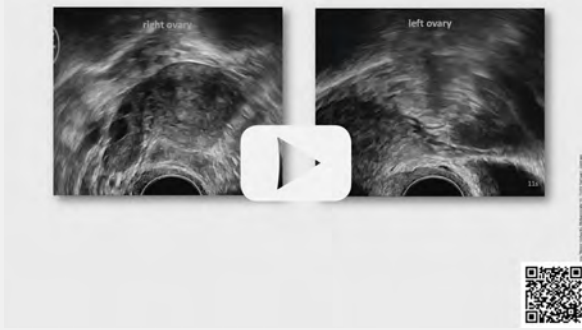▶ Video 31 Left tail sign

▶ OP-VIDEO



▶ Video 34 Completely free ovarian sliding

▶ OP-VIDEO




▶ **Video 35** Impaired ovarian sliding

▶ OP-VIDEO



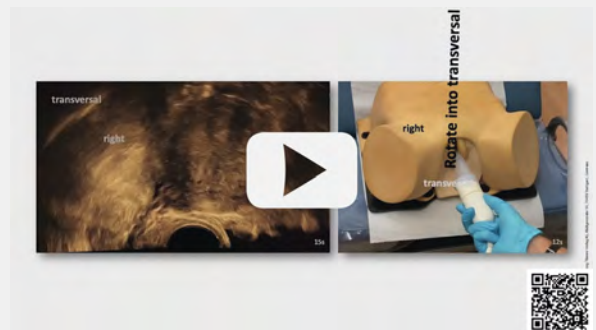
▶ **Video 38** Swashing pseudoperitoneal cyst

▶ OP-VIDEO




▶ **Video 36** Kissing ovaries sign. Fixed ovaries in “kissing position” behind the uterus, the so-called “kissing ovaries sign”, an example of the “block sign”

▶ OP-VIDEO



▶ **Video 39** Right CAL presentation. CAL: cardinal ligament

▶ OP-VIDEO



▶ **Video 37** Chronic sactosalpinx

▶ OP-VIDEO



▶ **Video 40** Left CAL presentation. CAL: cardinal ligament

## ▶ OP-VIDEO

## CAL:

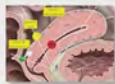## Morphologic Approach

The CALs appear as the echogenic, fibrotic surroundings of the UVC.

## SUL:

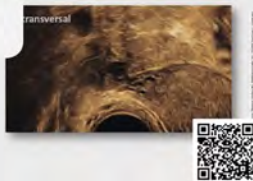## Morphologic Approach

The SULs appear as hyperechoic stripes starting from the cervix and pointing caudo-laterally in a semi-horizontal direction.



## CAL and SUL: Topographic Approach

1. Transversal (horizontal) plane through uterine corpus (Tail Sign, POD level)
2. Move to right or left (Tail Sign)
3. Lower until the UVC appears (CAL)
4. Lower until the a white stripe at the peritoneum appears (SUL, POD level II)
5. Turn the probe ccw for right, cw for left approx. 30° for complete SUL presentation

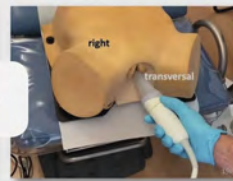
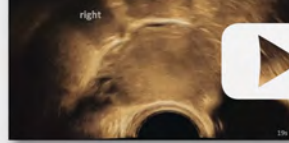
- ▶ **Video 41** CAL and SUL presentation. CAL: cardinal ligament; POD: pouch of Douglas; SUL: sacrouterine ligament; UTA: uterine artery; UVC: uterovascular complex. Image top right: adapted from Schünke M, Schulte E, Schumacher U, Voll M, Wesker K. 6.23 Schnittbildanatomie des weiblichen Beckens. In: Schünke M, Schulte E, Schumacher U, Voll M, Wesker K, Hrsg. Prometheus LemAtlas – Innere Organe. 5. Auflage. Stuttgart: Thieme; 2018. doi:10.1055/b-006-149 645

## ▶ OP-VIDEO

transversal

right

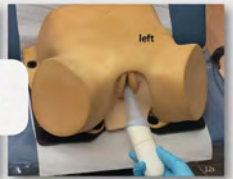

- ▶ **Video 43** Right SUL presentation. CAL: cardinal ligament, SUL: sacrouterine ligament

## ▶ OP-VIDEO

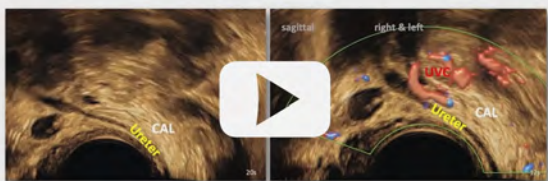
transversal

left



- ▶ **Video 44** Left SUL presentation. CAL: cardinal ligament, SUL: sacrouterine ligament

## ▶ OP-VIDEO



- ▶ **Video 42** CAL, ureter, UVC. CAL: cardinal ligament; UTA: uterine artery; UVC: utero-vascular complex

#### 4.4.4 Fallopian tubes

The Fallopian tubes are only visible on TVS if contrasted from inside or outside by a physiological or pathological collection of liquid. Endometriosis may cause hemato- or hydrosalpinges [17] (▶ **Video 37**) and peritoneal cysts [8], sometimes showing typical *swashing sails* (▶ **Video 38**). Chronic sactosalpinx carries the pathognomonic signs of *incomplete septa* or the *cogwheel sign* [33].

#### 4.4.5 Broad ligaments and pelvic sidewall

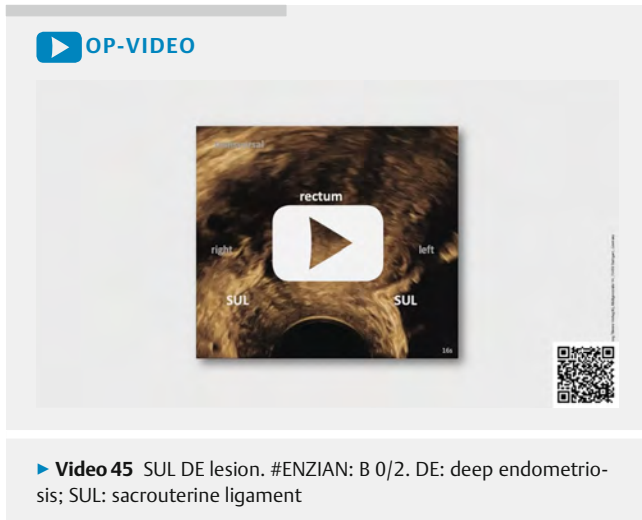
Dynamic investigation of the adnexal region, provoking sliding of bowels and ovaries along the *omega sign*, should demonstrate the free sliding between these organs, to the dorsal sheet of the broad ligaments, and the pelvic sidewalls (▶ **Video 30, 31**). Investigators should notice reduced or absent sliding, which can be classified for each side as #ENZIAN T1 (adhesions of adnexa to pel-

vic sidewall), T2 (T1 and adhesions to uterus), or T3 (T2 and adhesions to SULs or bowel). DE lesions appear mainly near the cervix (#ENZIAN B) (▶ **Fig. 7**) [16].

#### 4.4.6 Cardinal ligaments (CAL)

On TVS, the CALs become visible under an appropriate push as the echogenic, longish structure several centimeters in length at the caudal end of the broad ligament, containing the **UVC** with the uterine artery and many veins (▶ **Video 39–41**). They may be conveniently found when looking for the tail sign (dorsal sheet of the broad ligament) from the lateral fornix in a transverse plane running nearly horizontally through the right or left lateral compartment at the lower uterine corpus (▶ **Video 41**). They run from the lower lateral corpus, cervix, and vaginal fornix to the pelvic sidewall, whereby both borders fade into the neighboring structures. At the caudal end, the CALs connect directly to the SULs.

The **ureters** are the second leading structures in the CALs. They cross the CALs by passing under the UVC in a more or less straight course laterodorsally (▶ **Video 42**).



Lesions in this area should also be measured in their maximum lateral extent and assigned to #ENZIAN B separately for left and right (B1: < 1 cm, B2: 1–2 cm, B3: > 3 cm) (► **Fig. 7**) [16].

#### 4.4.7 Sacrouterine ligaments (SULs)

The SULs are preferably found topographically and not morphologically [14]. In a **transverse** plane, they directly connect caudally to the CALs as a bright, echogenic stripe in the dorsal peritoneum that extends laterally from the cervix. The probe should be rotated outwardly and downwardly to follow the SULs towards the pelvic sidewall (► **Video 43, 44**). If correctly exposed, the SULs will wrap around the tip of the TVS probe.

The SULs are the favored site of DE and harbor 53% of DE lesions [15]. They should be considered affected if the retrocervical sliding mobility is impaired, a hypoechoic thickening interrupts its hyperechoic presentation, or a substantial DE lesion affects one or both SULs or the torus in-between (► **Video 45**). Lesions may be isolated or multiple, affecting the vaginal wall, the ovaries, the bowel, the ureters, or some combination thereof (► **Video 32**) [8]. An advantage of using the **transverse** plane is the comparability of the right and left SULs and the inspection of the torus at a glance (► **Video 45**).

As with CAL lesions, SUL lesions are measured in the largest diameter and subsequently classified as side-separated according to #ENZIAN B (left/right). Note that central lesions on the torus, affecting the retrocervical area, have to be assigned to #ENZIAN A (► **Fig. 7**) [16].

## 5 Summary

Today, TVS is the primary diagnostic tool for suspected endometriosis, e. g., due to its cost-effectiveness, direct applicability by gynecologists, and excellent imaging quality. Although TVS is generally well tolerated, its dynamic application is mandatory for detecting sliding disorders and endometriotic lesions. Still, it requires specific expertise and poses a challenge for training at different levels.

This paper presents a practical, systematic, comprehensive, checklist-based sonographic approach for diagnosing pelvic endometriosis in five well-defined compartments. It includes detailed explanations, diagrams, and ultrasound videos based on IDEA 2016. It directly links the #ENZIAN classification, resulting in comparability across cases, imaging modalities, and disciplines.

### Conflict of Interest

Julian Metzler: Founder of Scanvio Medical AG.  
Michael Bajka: Founder of Scanvio Medical AG.

### References

- [1] Keckstein J, Hoopmann M. Endometriosis, ultrasound and #Enzian classification: the need for a common language for non-invasive diagnostics. *Ultraschall Med* 2023; 44: 233–239. doi:10.1055/a-2055-6712
- [2] Piketty M, Chopin N, Dousset B et al. Preoperative work-up for patients with deeply infiltrating endometriosis: transvaginal ultrasonography must definitely be the first-line imaging examination. *Human reproduction (Oxford, England)* 2009; 24: 602–607. doi:10.1093/humrep/den405
- [3] Keckstein J, Hoopmann M, Merz E et al. Expert opinion on the use of transvaginal sonography for presurgical staging and classification of endometriosis. *Archives of Gynecology and Obstetrics* 2022; 307: 5–19. doi:10.1007/s00404-022-06766-z
- [4] Montanari E, Bokor A, Szabo G et al. Accuracy of sonography for non-invasive detection of ovarian and deep endometriosis using #Enzian classification: prospective multicenter diagnostic accuracy study. *Ultrasound Obstet Gynecol* 2022; 59: 385–391. doi:10.1002/uog.24833
- [5] Van Holsbeke C, Van Calster B, Guerriero S et al. Endometriomas: their ultrasound characteristics. *Ultrasound in Obstetrics and Gynecology* 2010; 35: 730–740. doi:10.1002/uog.7668
- [6] Harmsen MJ, Van den Bosch T, de Leeuw RA et al. Consensus on revised definitions of Morphological Uterus Sonographic Assessment (MUSA) features of adenomyosis: results of modified Delphi procedure. *Ultrasound in Obstetrics & Gynecology* 2022; 60: 118–131. doi:10.1002/uog.24786
- [7] Krentel H, Keckstein J, Fuger T et al. Accuracy of ultrasound signs in two-dimensional transvaginal ultrasound for the prediction of adenomyosis: prospective multicenter study. *Ultrasound Obstet Gynecol* 2023; 62: 739–746. doi:10.1002/uog.26197
- [8] Guerriero S, Condous G, van den Bosch T et al. Systematic approach to sonographic evaluation of the pelvis in women with suspected endometriosis, including terms, definitions and measurements: a consensus opinion from the International Deep Endometriosis Analysis (IDEA) group. *Ultrasound in obstetrics & gynecology: the official journal of the International Society of Ultrasound in Obstetrics and Gynecology* 2016; 48: 318–332. doi:10.1002/uog.15955
- [9] Guerriero S, Ajossa S, Pascual MA et al. Ultrasonographic soft markers for detection of rectosigmoid deep endometriosis. *Ultrasound in Obstetrics & Gynecology* 2020; 55: 269–273. doi:10.1002/uog.20289
- [10] Manieri Rocha R, Leonardi M, Eathorne A et al. Anatomical distribution of endometriosis: A cross-sectional analysis of transvaginal ultrasound in symptomatic patients. *Australas J Ultrasound Med* 2023; 26: 131–141. doi:10.1002/ajum.12327
- [11] Pedrassani M, Guerriero S, Pascual MA et al. Superficial Endometriosis at Ultrasound Examination—A Diagnostic Criteria Proposal. *Diagnostics (Basel)* 2023; 13: 1876. doi:10.3390/diagnostics13111876
- [12] Savelli L, Ambrosio M, Salucci P et al. Transvaginal ultrasound features of normal uterosacral ligaments. *Fertility and Sterility* 2021; 116: 275–277. doi:10.1016/j.fertnstert.2020.11.019

- [13] Van den Bosch T, de Bruijn AM, de Leeuw RA et al. Sonographic classification and reporting system for diagnosing adenomyosis. *Ultrasound Obstet Gynecol* 2019; 53: 576–582. doi:10.1002/uog.19096
- [14] Freger SM, Turnbull V, McGowan K et al. Prospective diagnostic test accuracy of uterosacral ligament and torus uterinus endometriosis using transvaginal ultrasound posterior approach. *Ultrasound Obstet Gynecol* 2023. doi:10.1002/uog.27492
- [15] Chapron C, Chopin N, Borghese B et al. Deeply infiltrating endometriosis: pathogenetic implications of the anatomical distribution. *Hum Reprod* 2006; 21: 1839–1845. doi:10.1093/humrep/del079
- [16] Keckstein J, Saridogan E, Ulrich UA et al. The #Enzian classification: A comprehensive non-invasive and surgical description system for endometriosis. *Acta obstetrica et gynecologica Scandinavica* 2021; 100: 1165–1175. doi:10.1111/aogs.14099
- [17] Grab D, Merz E, Eichhorn K-H et al. Basic Gynecologic Ultrasound Examination (Level I): DEGUM, ÖGUM, and SGUM Recommendations. *Ultraschall Med* 2023; 44 (2): 151–161. doi:10.1055/a-1851-5157
- [18] Hoopmann M, Tutschek B, Merz E et al. Quality Requirements for gynecological ultrasound examinations of DEGUM level II – Recommendations of the Sections/Working Groups Gynecology and Obstetrics of DEGUM, ÖGUM and SGUM. *Ultraschall Med* 2022; 43: 146–158. doi:10.1055/a-1663-6322
- [19] Hudelist G, Fritzer N, Staettner S et al. Uterine sliding sign: a simple sonographic predictor for presence of deep infiltrating endometriosis of the rectum. *Ultrasound Obstet Gynecol* 2013; 41: 692–695. doi:10.1002/uog.12431
- [20] Reid S, Lu C, Casikar I et al. The prediction of pouch of Douglas obliteration using offline analysis of the transvaginal ultrasound “sliding sign” technique: inter- and intra-observer reproducibility. *Hum Reprod* 2013; 28: 1237–1246. doi:10.1093/humrep/det044
- [21] Roberts WH, Habenicht J, Krisingner G. The Pelvic and Perineal Fasciae and Their Neural and Vascular Relationships. *Anat Rec* 1964; 149: 707–720. doi:10.1002/ar.1091490414
- [22] Nadeem A, Habte A, Ahsan A et al. Deep Infiltrating Endometriosis: A Pictorial Essay. *J Ultrasound Med* 2023. doi:10.1002/jum.16318
- [23] Oliveira MAP, Raymundo TS, Pereira TD et al. Robotic Surgery for Bladder Endometriosis: A Systematic Review and Approach. *J Clin Med* 2023; 12: 5416. doi:10.3390/jcm12165416
- [24] Savelli L, Manuzzi L, Pollastri P et al. Diagnostic accuracy and potential limitations of transvaginal sonography for bladder endometriosis. *Ultrasound in obstetrics & gynecology: the official journal of the International Society of Ultrasound in Obstetrics and Gynecology* 2009; 34: 595–600. doi:10.1002/uog.7356
- [25] Squifflet J, Feger C, Donnez J. Diagnosis and Imaging of Adenomyotic Disease of the Retroperitoneal Space. *Gynecologic and Obstetric Investigation* 2002; 54: 43–51. doi:10.1159/000066294
- [26] Donnez J, Pirard C, Smets M et al. Surgical management of endometriosis. *Best Practice & Research Clinical Obstetrics & Gynaecology* 2004; 18: 329–348. doi:10.1016/j.bpobgyn.2004.03.004
- [27] Aas-Eng MK, Dauser B, Lieng M et al. Transvaginal sonography accurately measures lesion-to-anal-verge distance in women with deep endometriosis of the rectosigmoid. *Ultrasound Obstet Gynecol* 2020; 56: 766–772. doi:10.1002/uog.21995
- [28] Alson S, Jokubkiene L, Henic E et al. Prevalence of endometrioma and deep infiltrating endometriosis at transvaginal ultrasound examination of subfertile women undergoing assisted reproductive treatment. *Fertil Steril* 2022; 118: 915–923. doi:10.1016/j.fertnstert.2022.07.024
- [29] Timmerman D, Valentin L, Bourne TH et al. Terms, definitions and measurements to describe the sonographic features of adnexal tumors: a consensus opinion from the International Ovarian Tumor Analysis (IOTA) Group. *Ultrasound Obstet Gynecol* 2000; 16: 500–505. doi:10.1046/j.1469-0705.2000.00287.x
- [30] Redwine DB. Ovarian endometriosis: a marker for more extensive pelvic and intestinal disease. *Fertility and Sterility* 1999; 72: 310–315. doi:10.1016/S0015-0282(99)00211-3
- [31] Exacoustos C, De Felice G, Pizzo A et al. Isolated Ovarian Endometrioma: A History Between Myth and Reality. *J Minim Invasive Gynecol* 2018; 25: 884–891. doi:10.1016/j.jmig.2017.12.026
- [32] Ghezzi F, Raio L, Cromi A et al. “Kissing ovaries”: A sonographic sign of moderate to severe endometriosis. *Fertility and Sterility* 2005; 83: 143–147. doi:10.1016/j.fertnstert.2004.05.094
- [33] Timor-Tritsch IE, Lerner JP, Monteagudo A et al. Transvaginal sonographic markers of tubal inflammatory disease. *Ultrasound Obstet Gynecol* 1998; 12: 56–66. doi:10.1046/j.1469-0705.1998.12010056.x