

EUS-guided hepaticogastrostomy versus percutaneous transhepatic biliary drainage after failed ERCP: A propensity score-matched analysis



Authors

Nicholas J Koutlas¹, Swati Pawa¹, Greg Russell², Taylor Ferris³, Janardhana Ponnatapura⁴, Rishi Pawa¹

Institutions

- 1 Gastroenterology, Wake Forest School of Medicine, Winston-Salem, United States
- 2 Biostatistics, Wake Forest School of Medicine, Winston-Salem, United States
- 3 Department of Medicine, Wake Forest School of Medicine, Winston-Salem, United States
- 4 Interventional Radiology, Wake Forest School of Medicine, Winston-Salem, United States

Key words

Biliary tract, Endoscopic ultrasonography, Intervention EUS, Stones, Strictures

received 19.7.2023

accepted after revision 16.11.2023

Bibliography

Endosc Int Open 2024; 12: E108–E115

DOI 10.1055/a-2220-2740

ISSN 2364-3722

© 2024. The Author(s).

This is an open access article published by Thieme under the terms of the Creative Commons Attribution-NonDerivative-NonCommercial License, permitting copying and reproduction so long as the original work is given appropriate credit. Contents may not be used for commercial purposes, or adapted, remixed, transformed or built upon. (<https://creativecommons.org/licenses/by-nc-nd/4.0/>)

Georg Thieme Verlag KG, Rüdigerstraße 14,
70469 Stuttgart, Germany

Corresponding author

MBBS Rishi Pawa, Wake Forest School of Medicine,
Gastroenterology, Winston-Salem, United States
rpawa@wakehealth.edu

ABSTRACT

Background and study aims Percutaneous transhepatic biliary drainage (PTBD) is the traditional second-line option after unsuccessful endoscopic retrograde cholangiopancreatography (ERCP). Endoscopic ultrasound-guided hepaticogastrostomy (EUS-HG) is a viable alternative to PTBD. Our study aimed to compare outcomes of EUS-HG and PTBD for benign and malignant biliary diseases following failed ERCP.

Patients and methods This single-center study retrospectively analyzed patients undergoing EUS-HG and PTBD for benign and malignant biliary disorders. A propensity score-matched analysis was performed using age, sex, and Charlson Comorbidity Index. The primary outcome was clinical success, which we defined as a decrease in total bilirubin by $\geq 50\%$ at 2 weeks for malignant disease and resolution of the biliary disorder for benign disease.

Results In total, 41 patients underwent EUS-HG and 138 patients underwent PTBD. After propensity score matching in a 1:2 ratio, 32 EUS-HG patients were matched with 64 PTBD. Technical success was achieved in 29 of 32 (91%) for EUS-HG and 63 of 64 (98%) for PTBD ($P=0.11$). Clinical success was 100% for EUS-HG and 75% for PTBD ($P=0.0021$). EUS-HG was associated with a lower adverse event rate (EUS-HG 13% vs. PTBD 58%, $P<0.0001$), shorter procedure duration (median 60 vs. 115 minutes, $P<0.0001$), shorter post-procedure length of stay (median 2 vs. 4 days, $P<0.0001$), and fewer reinterventions (median 1 vs. 3, $P<0.0001$).

Conclusions Our results suggest that EUS-HG is superior to PTBD in the treatment of benign and malignant biliary disorders after failed ERCP.

Introduction

Endoscopic retrograde cholangiopancreatography (ERCP) is the standard of care for treating many biliary disorders. However, it is estimated that 3% to 12% of ERCPs for biliary obstruction are unsuccessful [1]. Common reasons for failure to achieve deep

biliary cannulation include surgically altered anatomy, gastric outlet obstruction, or papillary distortion. First reported in 1961, percutaneous transhepatic biliary drainage (PTBD) has become the traditional rescue therapy due to high technical success and widespread availability [2,3,4]. However, PTBD has several distinct disadvantages which include moderately

high adverse event rates (20% to 30%), frequent reinterventions, and decreased patient quality of life [1, 5].

Giovannini et al. first described endoscopic ultrasound (EUS)-guided biliary drainage (EUS-BD) in 2001 after creating a choledochoduodenostomy using a plastic biliary stent in a patient with a pancreatic head mass after failed ERCP [6]. EUS-BD now comprises EUS-guided rendezvous (EUS-RZ), EUS-guided antegrade stenting (EUS-AS), EUS-guided choledochoduodenostomy (EUS-CDS), and EUS-guided hepaticogastrostomy (EUS-HG). In comparative studies, EUS-BD has produced similar efficacy with fewer adverse events and lower cost than PTBD [7, 8, 9, 10].

Burmester and colleagues were the first to report successful EUS-HG in 2003 [11]. Initial studies have demonstrated EUS-HG to be an effective method of biliary drainage with technical and clinical success rates of 96% and 90%, respectively [12]. Adverse events (AEs) have been reported in 15% to 20% of cases and include bleeding, infection, bile leak, stent migration, and pneumoperitoneum [1, 13].

The current literature on EUS-HG and PTBD is relatively sparse. Prior studies have had small sample sizes and have primarily consisted of patients with malignant biliary obstruction (MBO) [14, 15]. As such, we aim to compare clinical outcomes of EUS-HG and PTBD after failed ERCP for benign and malignant biliary diseases using a propensity score-matched analysis.

Patients and methods

Study population and data collection

Consecutive patients undergoing EUS-HG or PTBD after failed ERCP at a single tertiary care center from January 2020 to December 2022 were identified and retrospectively analyzed. Patients with either benign or malignant biliary diseases were included. Preliminary chart review was conducted for each patient with age, gender, and comorbidities recorded. A Charlson Comorbidity Index (CCI) score was calculated for each patient. Following this, propensity score matching according to age, gender, and CCI was performed in a 1:2 ratio of EUS-HG to PTBD patients in order to mitigate the risk of selection bias. Procedure reports, provider notes, laboratory data, and imaging studies were reviewed for each matched patient. Recorded data was stored in a secured database in accordance with our local institutional review board policies (IRB number: 00069169).

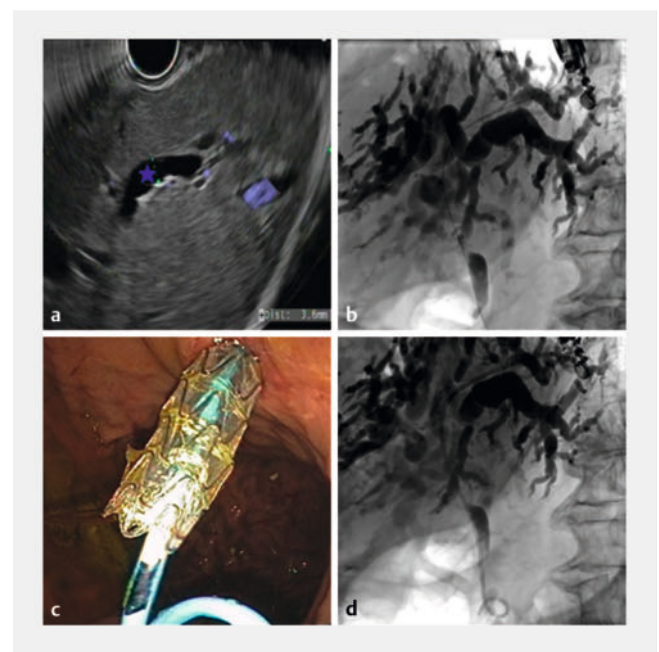
Outcomes

The primary outcome was clinical success. For malignant indications, this was defined as a decrease in serum total bilirubin by at least 50% at 2 weeks post-procedure. Clinical success for benign diseases was determined by resolution of the biliary disorder following EUS-HG or PTBD. Notable secondary outcomes included technical success, procedure duration, post-procedure hospital length of stay, AEs, and total biliary reinterventions. The lexicon created by the American Society of Gastrointestinal Endoscopy was used to define and classify AEs [16].

Procedure details

EUS-HG

All procedures were performed under general anesthesia by a single endosonographer (RP). A curvilinear echoendoscope (GF-UCT180; Olympus, Center Valley, Pennsylvania, United States) was used to identify a dilated segment 3 biliary radicle from the lesser curvature of the stomach (► Fig. 1a). An avascular path for needle puncture was confirmed by using color doppler. The biliary radicle was punctured using a 19-gauge fine-needle aspiration needle (EchoTip Ultra HD; Cook Medical, Winston-Salem, North Carolina, United States) followed by contrast injection to opacify the biliary tree. A 0.025 inch in diameter and 450 cm in length straight tip VisiGlide 2 wire (Olympus, Center Valley, Pennsylvania, United States) was then passed antegrade from the left intrahepatic duct into the distal bile duct and then the small bowel (► Fig. 1b). The HG tract was dilated using a 5.5F to 3.5F tapered Glo-Tip ERCP catheter (Cook Medical, Winston-Salem, North Carolina, United States) followed by sequential dilation of the tract with a 6 mm × 4 cm Hurricane biliary dilating balloon (Boston Scientific, Marlborough, Massachusetts, United States). Following this, a fully-covered, self-expandable, and non-foreshortening Gore Viabil biliary stent (W.L. Gore Associates, Flagstaff, Arizona, United States) was deployed across the HG tract. Lastly, attempts were made in all patients to place a 7F plastic double pigtail



► Fig. 1 Endoscopic ultrasound-guided hepaticogastrostomy. **a** Dilated segment 3 biliary radicle (blue star) seen on endoscopic ultrasound. **b** Fluoroscopic image showing dilated biliary tree with the guidewire past the ampulla in the small bowel. **c** Endoscopic image showing appropriate positioning of hepaticogastrostomy metal stent anchored with a plastic double pigtail stent. **d** Fluoroscopic image showing correct placement of hepaticogastrostomy metal stent and plastic double pigtail stent.

(DPT) stent through the metal HG stent with the distal end traversing the papilla (or bilioenteric anastomosis) in the small bowel and the proximal end in the stomach (► Fig. 1c, ► Fig. 1d). This was done to anchor the metal HG stent, prevent food impactions, and promote biliary drainage in an antegrade fashion thereby decreasing symptoms of bile reflux. If the guidewire was unable to traverse the stricture, the DPT stent was still placed into the distal bile duct. Patients were admitted overnight to monitor for early AEs. A repeat ERCP through the HG tract was scheduled in 3 to 4 weeks if required.

PTBD

Procedures were performed using either moderate sedation, monitored anesthesia care, or general anesthesia. A 21-gauge Chiba needle was inserted into an intrahepatic duct (laterality determined by proceduralist) under ultrasound guidance. Bile was aspirated and contrast injection was performed to opacify the biliary tree. A second fluoroscopically guided percutaneous biliary access was then acquired for more optimal positioning if needed. A 0.018-inch-diameter guidewire was passed through the needle into the left or right main hepatic duct. The needle was removed and a 6F coaxial dilator was placed over the wire. Following this, the 0.018-inch wire was exchanged for a 0.035-inch wire. A 4F Berenstein catheter was then advanced over the wire and through the dilator. Through wire and catheter manipulation, the system was advanced across the obstruction and subsequently the papilla (or bilioenteric anastomosis) and into the small bowel. The catheter was removed. Serial dilation was performed up to 10F or 12F. Following this, an 8F or 10F internal/external biliary drain was placed with the distal retention loop coiled in the small bowel. The wire was then removed and the catheter was secured to the skin with 2–0 Ethilon or 0–0 Prolene suture and connected to gravity drainage. Patients underwent repeat cholangiogram with possible capping of the biliary drain for internal drainage within 48 to 72 hours of the initial procedure. Subsequent procedures were performed as needed.

Statistical analysis

Propensity score matching utilizing a greedy-matching algorithm with no replacement was used to balance patients undergoing EUS-HG and PTBD in a 1:2 fashion. Following matching, the categorical variables were compared using Fisher's exact test and continuous outcomes were assessed using Student's independent t-tests. If significant, 95% confidence intervals are provided around mean differences using the Student t-test estimation method for continuous data and the exact binomial Miettinen-Nurminen method for categorical measures. For the subanalysis of non-malignant procedures, Wilcoxon Two-Sample Tests were used to assess differences between groups. $P < 0.05$ was used to determine statistical significance. SAS (version 9.4; Cary, North Carolina, United States) was used for all analyses.

Results

A total of 179 patients met inclusion criteria with 138 undergoing PTBD and 41 undergoing EUS-HG. After propensity score matching in a 1:2 ratio, 32 EUS-HG patients were matched with 64 PTBD patients resulting in a total of 96 patients. ► Table 1 and ► Table 2 summarize the variables included in the propensity score matching, presenting the standardized mean difference (SMD) for pre- and post-matched patients. Following matching, an SMD < 0.10 was used to determine whether a balanced covariate distribution was achieved between the two groups.

Following matching, it was noted that malignant etiology was present in 69% of EUS-HG patients and 56% of PTBD patients and accounted for the most common indication for biliary drainage ($P = 0.27$). Cholangitis was present in 25% of EUS-HG patients and 16% of PTBD patients ($P = 0.28$). Other indications including choledocholithiasis, bile leak, and benign biliary strictures were comparable between the two groups (► Table 3). Forty-four percent EUS-HG patients and 38% of PTBD patients had surgically altered anatomy ($P = 0.66$). Distribution of the type of surgeries is outlined in ► Table 3.

Pertinent clinical outcomes are summarized in ► Table 4. Technical success was achieved in 91% of patients (29/32) in the EUS-HG group and in 98% of patients (63/64) in the PTBD group ($P = 0.11$). Of the three EUS-HG technical failures, one patient was managed successfully with PTBD and another patient underwent successful ERCP via the biliopancreatic limb using EUS-guided rendezvous technique. The final EUS-HG technical failure was managed conservatively as the patient declined further intervention. There was one technical failure for PTBD which was complicated by a biloma. Repeat attempt at PTBD 2 days after the index procedure was successful. Of the 32 patients undergoing EUS-HG, follow up was available for 31 patients. One patient with advanced stage malignancy in the EUS-HG group pursued hospice measures shortly after the procedure and hence, the follow-up laboratory studies were not obtained and the patient was excluded from the final analysis.

Clinical success was achieved in 100% of EUS-HG patients (28/28) and 75% of patients (47/63) in the PTBD cohort ($P = 0.0021$, 95% CI of difference [12%–37%]). EUS-HG was also associated with a shorter procedure duration (median 60 vs. 115 minutes, $P < 0.0001$, 95% CI of difference [47]–[77]), and shorter post-procedure hospital length of stay (median 2 vs. 4 days, $P < 0.0001$, 95% CI [2.2–4.2]) compared with PTBD.

A total of 53% EUS-HG patients (17/32) and 89% PTBD patients (57/64) required reintervention for a median of one and three additional procedures, respectively ($P < 0.0001$, 95% CI [17%–54%]). Reinterventions in the PTBD group were primarily performed for routine catheter exchange and catheter dysfunction (dislodgement or occlusion). Catheter removal was also required for benign disease. Of the 17 reinterventions required in the EUS-HG group, eight were performed in patients with benign disease for management of choledocholithiasis and benign biliary strictures. Among patients with malignant disease, nine required reintervention, primarily for cholangioscopy with biopsies and/or brushings to confirm cancer diagnosis.

► **Table 1** Variable distribution prior to propensity score matching.

	EUS-HG (n = 41)	PTBD (n = 138)	SMD
Age, median (IQR)	67.5 (53, 76)	66 (57, 74)	0.06
Gender, n (%)			
▪ Male	21 (51%)	74 (54%)	0.02
▪ Female	20 (49%)	64 (46%)	
Charlson Comorbidity Index, median (IQR)	5 (3, 8)	6 (4, 8)	0.12

EUS-HG, endoscopic ultrasound-guided hepaticogastrostomy; PTBD, percutaneous transhepatic biliary drainage; SMD, standardized mean difference; IQR, interquartile range.

► **Table 2** Variable distribution after propensity score matching.

	EUS-HG (n = 32)	PTBD (n = 64)	SMD
Age, median (IQR)	66 (53.5, 74.5)	65.5 (55.5, 73.5)	0.07
Gender, n (%)			
▪ Male	18 (56%)	37 (58%)	0.04
▪ Female	14 (44%)	27 (42%)	
Charlson Comorbidity Index, median (IQR)	5 (3, 8)	6 (3, 8)	0.05

EUS-HG, endoscopic ultrasound-guided hepaticogastrostomy; PTBD, percutaneous transhepatic biliary drainage; SMD, standardized mean difference; IQR, interquartile range.

► **Table 3** Patient characteristics.

	EUS-HG (n = 32)	PTBD (n = 64)	P value
Etiology, n (%)			0.27
▪ Benign	10 (31%)	28 (44%)	
▪ Malignant	22 (69%)	36 (56%)	
Indication, n (%)			
▪ Choledocholithiasis	8 (25%)	7 (11%)	0.13
▪ Cholangitis	8 (25%)	10 (16%)	0.28
▪ Bile leak	0	6 (9%)	0.17
▪ Benign biliary stricture	6 (19%)	17 (27%)	0.46
▪ Malignant biliary strictures	22 (69%)	36 (56%)	0.27
▪ Surgically altered anatomy, n (%)	14 (44%)	24 (38%)	0.66
▪ Roux-en-Y gastric bypass	5 (16%)	4 (6%)	
▪ Roux-en-Y hepaticojejunostomy	2 (6%)	10 (16%)	
▪ Roux-en-Y choledochojejunostomy	0	2 (3%)	
▪ Whipple	4 (13%)	7 (11%)	
▪ Billroth II	3 (9%)	1 (2%)	
Reason for failed ERCP, n (%)			0.12
Inaccessible papilla	23 (72%)	35 (55%)	
Failed cannulation	9 (28%)	29 (45%)	

EUS-HG, endoscopic ultrasound-guided hepaticogastrostomy; PTBD, percutaneous transhepatic biliary drainage; ERCP, endoscopic retrograde cholangiopancreatography.

► **Table 4** Clinical outcomes for patients undergoing EUS-HG and PTBD.

	EUS-HG (n = 32)	PTBD (n = 64)	P value
Technical success, n (%)	29 (91%)	63 (98%)	0.11
Clinical success, n (%)	28 (100%)	47 (75%)	0.0021
Adverse events, n (%)	4 (13%)	37 (58%)	<0.0001
Procedure duration (minutes), median (IQR)	60 (47, 78)	115 (93, 149)	<0.0001
Number of re-interventions, median (IQR)	1 (0, 2)	3 (1, 5)	<0.0001
Post-procedure length of hospital stay (days), median (IQR)	2 (1, 4)	4 (2, 11.5)	<0.0001
Follow up duration (days), median (IQR)	138 (49, 248)	106 (28, 272)	0.11

EUS-HG, endoscopic ultrasound-guided hepaticogastrostomy; PTBD, percutaneous transhepatic biliary drainage; IQR, interquartile range.

► **Table 5** Clinical outcomes for patients undergoing EUS-HG and PTBD for benign indications.

	EUS-HG (n = 10)	PTBD (n = 28)	P value
Technical success, n (%)	80%	100%	0.064
Clinical success, n (%)	8/8 (100%)	26 (93%)	>0.99
Adverse events, n (%)	1/10 (10%)	15/28 (54%)	0.025
Procedure duration (minutes), median (IQR)	59.5 (52–69)	108.5 (83–152.5)	0.0002
Number of re-interventions, median (IQR)	1.5 (1–3)	4 (3–6)	0.0033
Post-procedure length of hospital stay (days), median (IQR)	2 (1–4)	4 (2–10.5)	0.047
Follow up duration (days), median (IQR)	203 (189–255)	241 (124–884.5)	0.46

EUS-HG, endoscopic ultrasound-guided hepaticogastrostomy; PTBD, percutaneous transhepatic biliary drainage; IQR, interquartile range.

In a subanalysis of patients with benign indications, EUS-HG demonstrated similar technical and clinical success with fewer AEs (10% vs. 54%, $P=0.025$, 95% CI [8%–65%]), fewer reinterventions (median 1.5 vs. 4, $P=0.0033$, 95% CI [0.7–3.9]), shorter procedure duration (median 59.5 vs. 108.5 minutes, $P=0.0002$, 95% CI [38]–[64]), and shorter post-procedure length of hospital stay (2 vs. 4 days, $P=0.047$, 95% CI [0.1–4.8]) when compared with PTBD (► **Table 5**). Compared with PTBD, EUS-HG was associated with similar technical success, superior clinical success (100% vs. 57%, $P=0.0003$, 95% CI [24%–59%]), lower AE rate (14% vs. 61%, $P=0.0004$, 95% CI [22%–66%]), fewer reinterventions (median 0 vs. 2, $P=0.0009$, 95% CI [0.5–1.8]), shorter procedure duration (median 58 vs. 116 minutes, $P<0.0001$, 95% CI [43]–[61]), and shorter post-procedure hospital length of stay (median 2 vs. 3 days, $P=0.012$, 95% CI [1.2–3.8]) in patients with MBO (proximal or distal) (► **Table 6**). Lastly, clinical outcomes for EUS-HG remained superior to PTBD when only comparing patients with distal MBO (► **Table 7**).

A total of four AEs occurred in four patients (13%) after EUS-HG compared with 48 AEs in 37 patients (58%) after PTBD ($P<0.0001$). All four AEs following EUS-HG were of moderate severity. In the PTBD group, there were five severe AEs with the remaining being mild to moderate in severity. Comparison of AEs between the two groups is summarized in ► **Table 8**.

In the EUS-HG group, there was one stent misdeployment which was managed endoscopically with stent removal and gastric defect closure with an over-the-scope clip. One patient had symptomatic pneumoperitoneum after EUS-HG which was successfully treated conservatively with intravenous fluids and antibiotics. Hematemesis secondary to bile acid reflux esophagitis was seen in one patient with a history of Roux-en-Y gastric bypass surgery. Diagnostic upper endoscopy did not reveal active bleeding. The patient received medical therapy with a proton pump inhibitor and sucralfate with no further bleeding. Lastly, one patient was readmitted for a post-procedure biloma that required percutaneous drain placement.

A total of 48 AEs occurred in the PTBD group. Notable AEs included tube dislodgement/obstruction ($n=29$), post-procedure bleeding ($n=5$), tube insertion site cellulitis ($n=3$), bile leak ($n=3$), cholangitis ($n=3$), cholecystitis ($n=1$), pancreatitis ($n=1$), diaphragm injury ($n=1$), and biliopleural fistula ($n=1$). Death occurred after PTBD in one patient secondary to hemodynamic instability thought to be related to bacterial translocation during the procedure. The patient's family pursued comfort care measures and the patient ultimately passed away.

► **Table 6** Clinical outcomes for patients undergoing EUS-HG and PTBD for malignant biliary obstruction.

	EUS-HG (n = 22)	PTBD (n = 36)	P value
Technical success, n (%)	21 (95%)	35 (97%)	>0.99
Clinical success, n (%)	20/20 (100%)	20/35 (57%)	0.0003
Adverse events, n (%)	3 (14%)	22 (61%)	0.0004
Procedure duration (minutes), median (IQR)	58 (39–83)	116 (96.5–147)	<0.0001
Number of reinterventions, median (IQR)	0 (0–1)	2 (1–3.5)	0.0009
Post-procedure length of hospital stay (days), median (IQR)	2 (1–4)	3 (2–11.5)	0.012
Follow up duration (days), median (IQR)	60 (20–198)	40.5 (17–106)	0.40

EUS-HG, endoscopic ultrasound-guided hepaticogastrostomy; PTBD, percutaneous transhepatic biliary drainage; IQR, interquartile range.

► **Table 7** Clinical outcomes for patients undergoing EUS-HG and PTBD for distal malignant biliary obstruction.

	EUS-HG (n = 21)	PTBD (n = 18)	P value
Technical success, n (%)	100%	94%	0.46
Clinical success, n (%)	20/20 (100%)	13 (72%)	0.017
Adverse events, n (%)	2 (10%)	11 (61%)	0.0015
Procedure duration (minutes), median (IQR)	52 (39–81)	105.5 (92–144)	0.013
Number of re-interventions, median (IQR)	0 (0–1)	1 (1–4)	0.0035
Post-procedure length of hospital stay (days), median (IQR)	2 (1–3)	3 (3–12)	0.43
Follow up duration (days), median (IQR)	60 (33–198)	43 (18–135)	0.14

EUS-HG, endoscopic ultrasound-guided hepaticogastrostomy; PTBD, percutaneous transhepatic biliary drainage; IQR, interquartile range.

Discussion

ERCP can be technically difficult or impossible in patients with surgically altered anatomy or a distorted papilla. EUS-HG has become a suitable alternative to PTBD following failed ERCP. Previous comparative studies have primarily analyzed patients with MBO [14, 15, 17]. As such, we retrospectively compared clinical outcomes for EUS-HG and PTBD in patients with benign and malignant biliary disorders using a propensity score-matched analysis.

In our study, EUS-HG demonstrated similar technical success and significantly higher clinical success compared to PTBD. In contrast, in a prospective study of 56 patients randomized to PTBD (n=21) or EUS-HG (n=35), the clinical success rates were similar between the two groups (PTBD 66.7% vs. EUS-HG 80%; P=0.35) [15]. Sportes et al. and Ogura et al. also reported no difference in clinical success between EUS-HG and PTBD [14, 17]. There are several potential explanations for our finding. First, a significant proportion of patients in our study had benign biliary obstruction contrary to the patient population in other studies [14, 15, 17]. Similarly high rates of clinical success were also observed in a retrospective study of 20 patients with surgically altered anatomy undergoing EUS-HG for benign biliary obstruction [5]. Second, at our institution, plastic DPT stents were routinely placed within the metal HG stent with

the proximal end in the stomach and the distal end across the papilla or surgical anastomosis and in the small bowel. This technique permits biliary drainage in both an antegrade and retrograde fashion, perhaps leading to superior decompression. Using a similar technique, Hathorn et al. reported a clinical success rate of 87% in a cohort of 102 patients including benign and MBO [18].

When compared with PTBD, we demonstrated that EUS-HG was associated with a lower adverse event rate, fewer reinterventions, and a shorter post-procedure hospital length of stay. The majority of AEs in our study for patients with PTBD were related to catheter dysfunction (29/48). This likely led to increased need for reinterventions and prolonged hospital stays. Sportes et al. also reported fewer reinterventions and shorter post-procedure length of stay in the EUS-HG group. AEs, however, were similar between the two cohorts [14]. Notably, in that study, HG tract dilation was performed with electrocautery, a factor that is known to increase the risk of bleeding following EUS-HG [19]. In contrast, in our study, electrocautery was not utilized for EUS-HG which may explain our lower adverse event rate and absence of bleeding. Our results suggest that when performed without the use of electrocautery, EUS-HG is safer than PTBD.

EUS-HG offers several important advantages. First, it does not require access to the papilla and as such, can be used in pa-

► **Table 8** Adverse events after EUS-HG and PTBD.

	EUS-HG (n = 32)	PTBD (n = 64)	P value
Total adverse events	4	48	<0.0001
Severe adverse events	0	5	0.17
Bleeding	–	2	
Diaphragm injury	–	1	
Biliopleural fistula	–	1	
Death	–	1	
Moderate/mild adverse events	4	43	<0.0001
Tube malfunction	–	29	
Bleeding	–	3	
Insertion site cellulitis	–	3	
Bile leak	1	3	
Cholangitis	–	3	
Cholecystitis	–	1	
Pancreatitis	–	1	
Stent misdeployment	1	–	
Symptomatic pneumoperitoneum	1	–	
Bile acid reflux esophagitis	1	–	

EUS-HG, endoscopic ultrasound-guided hepaticogastrostomy; PTBD, percutaneous transhepatic biliary drainage.

tients with malignant gastric outlet obstruction where EUS-RZ and EUS-CDS are technically difficult or impossible. Second, in patients with distal MBO, the HG metal stent is far from the obstructing tumor and thus, the risk of stent dysfunction secondary to tumor ingrowth is negligible compared with transpapillary self-expandable metallic stents (SEMS) [20]. Many of these patients also have duodenal tumor invasion, a known risk factor for early SEMS dysfunction [21]. The addition of a DPT stent through the metal stent further reduces the risk of metal stent occlusion from solid food debris. Third, EUS-HG is accompanied by a lower risk of reflux cholangitis, which likely explains higher stent patency for EUS-HG than EUS-CDS [22]. In addition, EUS-HG does not impact future curative surgery in patients with resectable disease should preoperative biliary drainage be deemed necessary [23, 24]. Lastly, the HG tract can serve as a conduit to perform further diagnostic and therapeutic interventions including brushings for cytology, cholangioscopy, antegrade stenting, and stone removal with extraction balloons and/or mechanical lithotripsy [5, 25, 26, 27].

Our study has several strengths. First, it is the largest direct comparative study of EUS-HG and PTBD. Second, this is the first study to include a significant proportion of patients with benign causes of biliary obstruction. Third, all EUS-HGs were performed by a single endoscopist utilizing a standardized procedural technique with a uniform post-procedure follow-up protocol, all completed at one institution.

The primary limitation of this study is its retrospective design which makes it susceptible to selection bias. Propensity score matching was performed to help mitigate this risk. Second, the number of EUS-HG patients, particularly those with benign disease, is still fairly small. In addition, all EUS-HG were performed at a high-volume, tertiary care center by a single experienced therapeutic endoscopist. As such, these results may not be fully generalizable.

Conclusions

In conclusion, EUS-HG demonstrated higher rates of clinical success with a more tolerable safety profile than PTBD in the management of patients with benign and malignant biliary diseases following failed ERCP. Prospective, randomized controlled trials are needed to validate our findings. Widespread utilization of EUS-HG should await further standardization of technique and development of dedicated EUS-HG devices.

Conflict of Interest

Rishi Pawa is a consultant for Boston Scientific and Cook Medical. None of the other authors have any conflicts of interest to disclose.

References

- [1] Giovannini M. EUS-guided hepaticogastrostomy. *Endosc Ultrasound* 2019; 8: S35–S39 doi:10.4103/eus.eus_47_19
- [2] Ferrucci JT, Mueller PR, Harbin WP. Percutaneous transhepatic biliary drainage: technique, results, and applications. *Radiology* 1980; 135: 1–13
- [3] Nakayama T, Ikeda A, Okuda K. Percutaneous transhepatic drainage of the biliary tract: technique and results in 104 cases. *Gastroenterology* 1978; 74: 554–559
- [4] Isayama H. Pancreato-biliary endoscopy: History of endoscopic biliary drainage. *Digest Endosc* 2022; 34: 111–115 doi:10.1111/den.14163
- [5] James TW, Fan YC, Baron TH. EUS-guided hepaticoenterostomy as a portal to allow definitive antegrade treatment of benign biliary diseases in patients with surgically altered anatomy. *Gastrointest Endosc* 2018; 88: 547–554 doi:10.1016/j.gie.2018.04.2353
- [6] Giovannini M, Moutardier V, Pesenti C et al. Endoscopic ultrasound-guided bilioduodenal anastomosis: a new technique for biliary drainage. *Endoscopy* 2001; 33: 898–900 doi:10.1055/s-2001-17324
- [7] Khashab MA, Valeshabad AK, Afghani E et al. A comparative evaluation of EUS-guided biliary drainage and percutaneous drainage in patients with distal malignant biliary obstruction and failed ERCP. *Dig Dis Sci* 2015; 60: 557–565
- [8] Bapaye A, Dubale N, Aher A. Comparison of endosonography-guided vs. percutaneous biliary stenting when papilla is inaccessible for ERCP. *United Europ Gastroenterol J* 2013; 1: 285–293
- [9] Sharaiha RZ, Kumta NA, Desai AP et al. Endoscopic ultrasound-guided biliary drainage versus percutaneous transhepatic biliary drainage: predictors of successful outcome in patients who fail endoscopic retrograde cholangiopancreatography. *Surg Endosc* 2016; 30: 5500–5505 doi:10.1007/s00464-016-4913-y
- [10] Yoon WJ, Shah ED, Lee TH et al. Endoscopic ultrasound-guided versus percutaneous transhepatic biliary drainage in patients with malignant biliary obstruction: Which is the optimal cost-saving strategy after failed ERCP? *Front Oncol* 2022; 12: 844083
- [11] Burmester E, Niehaus J, Leinweber T et al. EUS-cholangio-drainage of the bile duct: report of 4 cases. *Gastrointest Endosc* 2003; 57: 246–251
- [12] Paik WH, Park DH. Outcomes and limitations: EUS-guided hepaticogastrostomy. *Endosc Ultrasound* 2019; 8: S44–S49 doi:10.4103/eus.eus_51_19
- [13] Khoo S, Do NDT, Kongkam P. Efficacy and safety of EUS biliary drainage in malignant distal and hilar biliary obstruction: A comprehensive review of literature and algorithm. *Endosc Ultrasound* 2020; 9: 369–379 doi:10.4103/eus.eus_59_20
- [14] Sportes A, Camus M, Greget M et al. Endoscopic ultrasound-guided hepaticogastrostomy versus percutaneous transhepatic drainage for malignant biliary obstruction after failed endoscopic retrograde cholangiopancreatography: a retrospective expertise-based study from two centers. *Therap Adv Gastroenterol* 2017; 10: 483–493
- [15] Marx M, Caillol F, Autret A et al. EUS-guided hepaticogastrostomy in patients with obstructive jaundice after failed or impossible endoscopic retrograde drainage: A multicenter, randomized phase II Study. *Endosc Ultrasound* 2022; 11: 495–502 doi:10.4103/EUS-D-21-00108
- [16] Cotton PB, Eisen GM, Aabakken L et al. A lexicon for endoscopic adverse events: report of an ASGE workshop. *Gastrointest Endosc* 2010; 71: 446–454 doi:10.1016/j.gie.2009.10.027
- [17] Ogura T, Okuda A, Miyano A et al. EUS-guided versus percutaneous biliary access in patients with obstructive jaundice due to gastric cancer. *Digest Liver Dis* 2019; 51: 247–252
- [18] Hathorn KE, Canakis A, Baron TH. EUS-guided transhepatic biliary drainage: a large single-center U.S. experience. *Gastrointest Endosc* 2022; 95: 443–451 doi:10.1016/j.gie.2021.10.013
- [19] Ogura T, Higuchi K. Endoscopic ultrasound-guided hepaticogastrostomy: technical review and tips to prevent adverse events. *Gut Liver* 2021; 15: 196–205 doi:10.5009/gnl20096
- [20] Paik WH, Lee TH, Park DH et al. EUS-guided biliary drainage versus ERCP for the primary palliation of malignant biliary obstruction: a multicenter randomized clinical trial. *Am J Gastroenterol* 2018; 113: 987–997 doi:10.1038/s41395-018-0122-8
- [21] Hamada T, Isayama H, Nakai Y et al. Duodenal invasion is a risk factor for the early dysfunction of biliary metal stents in unresectable pancreatic cancer. *Gastrointest Endosc* 2011; 74: 548–555 doi:10.1016/j.gie.2011.04.046
- [22] Ogura T, Chiba Y, Masuda D et al. Comparison of the clinical impact of endoscopic ultrasound-guided choledochoduodenostomy and hepaticogastrostomy for bile duct obstruction with duodenal obstruction. *Endoscopy* 2016; 48: 156–163
- [23] Koutlas NJ, LePage EM, Lucioni T et al. Preoperative endoscopic ultrasound-guided hepaticogastrostomy facilitates decompression and diagnosis in patients with suspected malignant biliary obstruction: a case series. *Cureus* 2022; 14: e23209
- [24] Abdelfatah MM, Baron TH. Preoperative decompression and diagnosis of pancreatic head adenocarcinoma in a patient with Roux-en-Y gastric bypass by means of EUS-guided gastric pouch hepaticogastrostomy. *VideoGIE* 2017; 2: 143–144
- [25] Hosmer A, Abdelfatah MM, Law R et al. Endoscopic ultrasound-guided hepaticogastrostomy and antegrade clearance of biliary lithiasis in patients with surgically-altered anatomy. *Endosc Int Open* 2018; 6: E127–E130
- [26] Kawakami H, Itoi T, Ban T. Intrahepatic biliary stones extraction via an EUS-guided hepaticogastrostomy route confirmed by peroral trans-luminal video cholangioscopy (with video). *J Hepatobiliary Pancreat Sci* 2020; 27: E11–E12 doi:10.1002/jhbp.676
- [27] Sato T, Nakai Y, Kogure H et al. Electrohydraulic lithotripsy through a fistula of EUS-guided hepaticogastrostomy: a new approach for right intrahepatic stones. *VideoGIE* 2019; 4: 420–422