

# Transluminal antegrade drill dilation technique for hepaticojejunostomy stricture with cholangioscopic evaluation (with video)



## Authors

Takafumi Kanadani<sup>1</sup>, Takeshi Ogura<sup>1</sup>, Saori Ueno<sup>1</sup>, Atsushi Okuda<sup>1</sup>, Nobu Nishioka<sup>1</sup>, Junichi Nakamura<sup>1</sup>, Masanori Yamada<sup>2</sup>, Yuki Uba<sup>1</sup>, Mitsuki Tomita<sup>1</sup>, Nobuhiro Hattori<sup>1</sup>, Jun Sakamoto<sup>1</sup>, Hiroki Nishikawa<sup>1</sup>

## Institutions

- 1 2nd Department of Internal Medicine, Osaka Medical College, Takatsuki-shi, Japan
- 2 Endoscopic Center, Osaka Medical and Pharmaceutical University, Takatsuki, Japan

## Key words

Intervention EUS, Biliary tract

received 11.7.2023

accepted after revision 14.9.2023

accepted manuscript online 27.11.2023

## Bibliography

Endosc Int Open 2024; 12: E181–E187

DOI 10.1055/a-2218-1538

ISSN 2364-3722

© 2024. The Author(s).

This is an open access article published by Thieme under the terms of the Creative Commons Attribution-NonDerivative-NonCommercial License, permitting copying and reproduction so long as the original work is given appropriate credit. Contents may not be used for commercial purposes, or adapted, remixed, transformed or built upon. (<https://creativecommons.org/licenses/by-nc-nd/4.0/>)

Georg Thieme Verlag KG, Rüdigerstraße 14,  
70469 Stuttgart, Germany

## Corresponding author

Dr. Takeshi Ogura, Osaka Medical College, 2nd Department of Internal Medicine, 2-7 Daigaku-machi, 569-8686 Takatsuki-shi, Japan  
oguratakeshi0411@yahoo.co.jp

## ABSTRACT

**Background and study aims** Balloon dilation and plastic stent deployment have been performed as hepaticojejunostomy stricture (HJS) treatment techniques under endoscopic ultrasound guidance (EUS). Although these techniques have shown favorable clinical results, the treatment period can be long because stent deployment is required. In addition, HJS may recur even after treatment because the scar tissue itself remains. To overcome these challenges, we developed an EUS-guided antegrade drill dilation technique for treating HJS. The aim of this study was to evaluate the technical feasibility and safety of this technique in terms of the pre- and post-cholangioscopic findings.

**Patients and methods** This retrospective study included consecutive patients whose conditions were complicated with symptomatic HJS between November 2022 and February 2023. Transluminal antegrade drill dilation (TAD) using a novel drill dilator was attempted within 14 days after EUS-guided hepaticogastrostomy (HGS). HJS was diagnosed with cholangioscopy before TAD, and resolution was evaluated after TAD using cholangioscopy.

**Results** TAD was attempted at approximately 11 days after EUS-HGS. The cholangioscope was inserted successfully in all patients after this procedure. Cholangioscopy revealed stricture without evidence of malignancy in 19 patients. In the remaining three patients, stricture was not observed and these patients underwent stent exchange rather than TAD. Among the 19 patients, passage of the guidewire across the HJS into the intestine was unsuccessful in four patients, and the technical success rate for this procedure was 78.9%. TAD was successful in all 15 patients in whom passage of the guidewire was achieved.

**Conclusions** In conclusion, TAD appears to be technically feasible and safe.

## Introduction

Hepaticojejunostomy stricture (HJS) can occur as a complication after pancreatic or biliary surgery, with frequency ranging

from 4% to 10% [1]. As recent technological developments in diagnostic tools such as endoscopic ultrasound (EUS) begin to have an impact on the early detection of pancreato-biliary cancer and on patients considered eligible for neoadjuvant chemo-

therapy, the number undergoing pancreaticoduodenostomy (PD) or pylorus-preserving PD may increase, and therefore, the number complicated by HJS may also increase [2, 3, 4, 5, 6]. HJS is traditionally treated by the percutaneous transhepatic approach (PTBD) [7, 8]; however, PTBD has several limitations, including external drainage, which may lead to prolonged hospitalization, and the risk of self-removal of the tube. Double-balloon enteroscopy endoscopic retrograde cholangiopancreatography (DB-ERCP) has also been reported as a treatment option for HJS [8, 9, 10, 11] but has the disadvantages of prolonged procedure time and a relatively low technical success rate. Endoscopic ultrasound-guided biliary drainage (EUS-BD) has recently been reported as an alternative technique for failed ERCP and patients in whom PTBD is contraindicated [12, 13]. This technique has a high technical success rate; however, it has not been fully evaluated for HJS [14, 15, 16, 17].

Balloon dilation and plastic stent deployment have been performed as HJS treatment techniques by PTBD or under DB-ERCP guidance, and fully-covered self-expandable metal stent (FCSEMS) deployment has also been attempted with the aim of improving the efficacy of HJS resolution [2, 15, 18]. Although these techniques have shown favorable clinical results, the treatment period can be long because stent deployment is required. In addition, HJS may recur even after treatment because the scar tissue itself remains [19]. To overcome these challenges, we developed an EUS-guided antegrade drill dilation technique for treating HJS. The aim of this study was to evaluate the technical feasibility and safety of this technique in terms of the pre- and post-cholangioscopic findings.

## Patients and methods


This retrospective study included consecutive patients whose conditions were complicated by symptomatic HJS between November 2022 and February 2023. In this study, symptomatic HJS such as obstructive jaundice or cholangitis was included. Exclusion criteria comprised contraindications for endoscopic biliary drainage due to conditions such as massive ascites, or Eastern Cooperative Oncology Group (ECOG) performance status of 3 or 4, other severe organ failure, combined with other biliary drainage such as PTBD, or lack of consent for participation.

In our hospital, as first-line treatment strategy for HJS, an EUS-guided approach was performed. If this procedure failed, another biliary drainage technique such as PTBD or DB-ERCP was attempted. The study protocol conformed to the ethical guidelines of the 1975 Declaration of Helsinki as reflected in the a priori approval given by the human research committee at Osaka Medical College (IRB No. 2022–210).

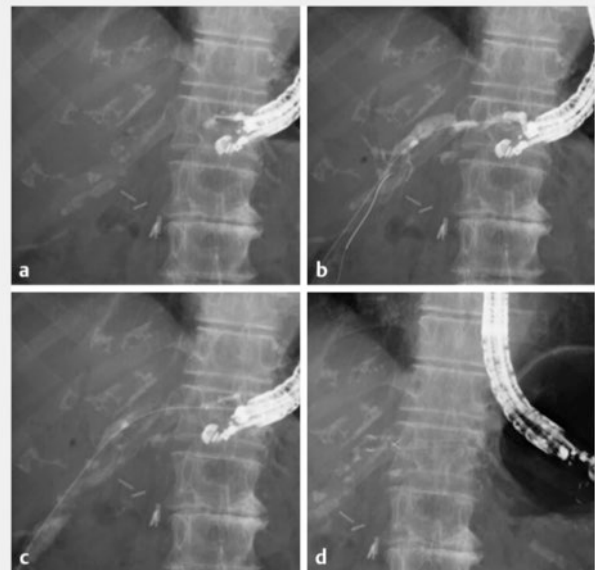
### Technical tips for EUS-HGS and antegrade drill dilation technique

An echoendoscope (UCT260; Olympus Optical, Tokyo, Japan) was inserted into the stomach and the left hepatic lobe was identified (▶ **Video 1**). The intrahepatic bile duct was punctured using a 19G or 22G needle (EZ Shot 3 Plus, Olympus), according to the diameter of the intrahepatic bile duct. After suc-

### ▶ VIDEO

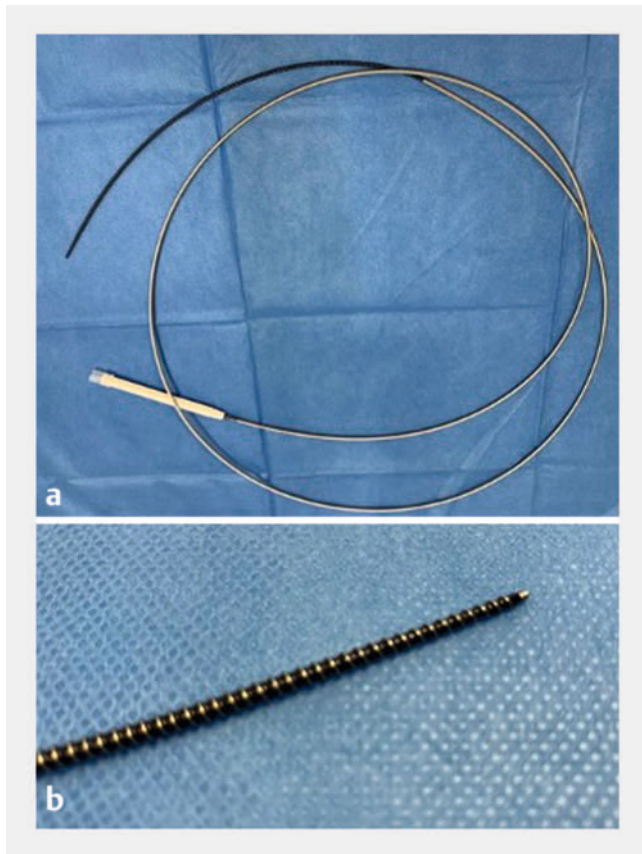


▶ **Video 1** The mesh of the metal stent is broken using an electrocautery device. An ERCP catheter is inserted into the biliary tract through the mesh, followed by antegrade insertion of a cholangioscope. Cholangioscopy confirms the presence of stricture, and antegrade dilation is performed using a drill dilator. After dilation, the cholangioscope is reinserted and the stricture is resolved without bleeding or perforation. Finally, a plastic stent is deployed from the intrahepatic bile duct to the stomach.



▶ **Fig. 1** a The intrahepatic bile duct is punctured using a 19G needle and contrast medium is injected. b A 0.025-inch guidewire is deployed in the biliary tract. c Tract dilation is performed using a balloon catheter. d A partially-covered self-expandable metal stent is deployed from the intrahepatic bile duct to the stomach.

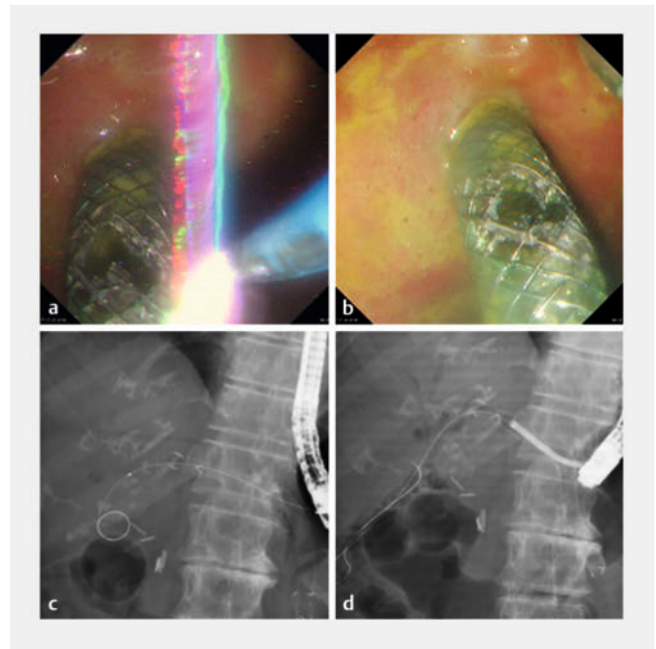
cessful puncture of the duct, contrast medium was injected to obtain cholangiography (▶ **Fig. 1a**) and a 0.025-inch (VisiGlide 1; Olympus) or 0.018-inch (Fielder; Olympus) guidewire was inserted into the biliary tract through the needle (▶ **Fig. 1b**). The intrahepatic bile duct and stomach wall were then dilated using a 4-mm balloon catheter (REN biliary balloon catheter; Kaneka, Osaka, Japan) or an ultra-tapered mechanical dilator (ES dilator; Zeon Medical Inc., Tokyo, Japan) (▶ **Fig. 1c**). Finally, a partially-



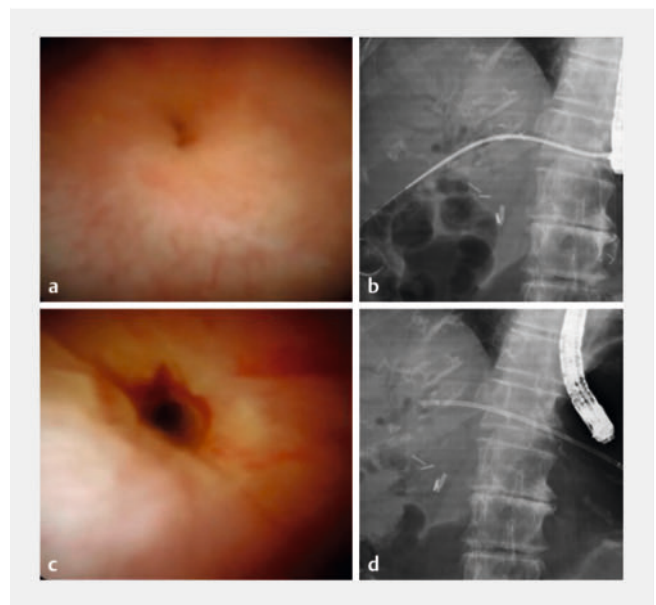
► **Fig. 2** a The drill dilator used in the described technique (Tornus ES; Asahi Intecc, Aichi, Japan). b The tapered tip of the drill dilator is shown with a 0.025-inch guidewire.

covered self-expandable metal stent (PCSEMS) (8-mm diameter, Spring Stopper; Taewoong Medical, Seoul, Korea) was deployed from the intrahepatic bile duct to the stomach using the intra-scope channel release technique (► **Fig. 1d**).

The tract was easily dilated by clockwise rotation of a drill dilator device (Tornus ES; Asahi Intecc, Aichi, Japan) (► **Fig. 2**) without needing to apply pushing force. Transluminal antegrade drill dilation (TAD) was attempted within 14 days after EUS-HGS. First, a standard ERCP catheter was inserted into the biliary tract through the EUS-HGS stent after dilation of the mesh of the EUS-HGS stent using balloon dilation or the trimming technique (► **Fig. 3a**, ► **Fig. 3b**). A cholangioscope (SpyGlass DS; Boston Scientific, Marlborough, Massachusetts, United States) was then inserted through the mesh into the biliary tract (► **Fig. 3c**) to evaluate the HJS site. If malignancy was suspected based on the cholangioscopic findings, antegrade biopsy was performed and the patient was excluded from the present study. Also excluded were those in whom stricture was not observed, because of the possibility that the symptoms might have been caused by reflux cholangitis. If stricture was confirmed by cholangioscopy (► **Fig. 4a**), a guidewire was inserted into the jejunum across the HJS site and TAD was performed using a drill dilator (► **Fig. 4b**). Finally, the cholangioscope was reinserted to evaluate the HJS site (► **Fig. 4c**), the PCSEMS was



► **Fig. 3** a EUS-HGS stent is broken using an electrocautery device. b The hole is made after trimming technique. c A standard ERCP catheter is inserted into the biliary tract through the EUS-HGS stent. d A cholangioscope (SpyGlass DS; Boston Scientific, Marlborough, Massachusetts, United States) is inserted through the mesh into the biliary tract.



► **Fig. 4** a Cholangioscopy confirms the presence of stricture. b Transluminal antegrade drill dilation is performed. c After dilation, the stricture is resolved without bleeding or perforation. d A plastic stent is deployed after removal of the metallic stent.

removed, and a plastic stent was deployed (REGULUS Biliary Tube Stent System; Japan Lifeline Co., Ltd. Tokyo, Japan) (► **Fig. 4d**).

## Definitions and statistical analysis

The primary outcome of this study was the technical success rate for TAD using a drill dilator. Technical success was defined as resolution of the HJS, based on the cholangioscopic findings. The secondary outcome was adverse events (AEs) associated with TAD such as bleeding or perforation. The cholangioscopic findings were classified as stricture, non-stricture, or malignancy. Bleeding associated with TAD was defined as visible continuous bleeding on cholangioscopy for a period of 60 seconds. The severity of bleeding associated with TAD was defined according to the lexicon of the American Society for Gastrointestinal Endoscopy [20]. Moderate bleeding was defined as that requiring transfusion, intensive care unit admission, angiographic intervention, or prolonged hospitalization for 4 to 10 days. Severe bleeding was defined as that requiring surgical intervention, prolonged hospitalization for > 10 nights, or an intensive care unit stay of > 1 day. Bleeding that could not be categorized as either of these was defined as mild bleeding. Perforation associated with TAD was defined as contrast medium observed in the abdominal cavity. Procedure time of EUS-HGS was measured from bile duct puncture to stent deployment. Also, procedure time of TAD was measured from duodenoscope insertion to removal. As we exchange plastic EUS-HGS stents every 3 to 4 months in our clinical practice, we checked for recurrence of HJS during this procedure. A lack of flow of contrast medium across the HJS from the biliary tract to the intestine was considered to indicate recurrence of HJS.

Descriptive statistics are presented as the mean  $\pm$  standard deviation (SD) or median and range for continuous variables, and as the frequency for categorical variables. All data were statistically analyzed using SPSS version 13.0 statistical software (SPSS, Chicago, Illinois, United States).

## Results

► **Table 1** lists patient characteristics. A total of 22 patients (median age, 75 years; 14 males, 8 females) were enrolled in this study. The clinical symptoms associated with HJS were cholangitis (n = 16) and obstructive jaundice (n = 6). The primary disease was pancreatic carcinoma (n = 8), cholangiocarcinoma (n = 6), chronic pancreatitis (n = 1), intraductal papillary mucinous adenoma (n = 4), and common bile duct stones (n = 4). B3 was mainly selected as the puncture site, and a 19G needle was used most commonly. Mean diameter of the intrahepatic bile duct at the puncture site was 3.85 mm. EUS-HGS was successfully performed in 20 of 22 patients. In the two failed cases, intrahepatic bile duct puncture itself was not performed because of insufficient bile duct dilatation, but EUS-HGS was successful when reattempted several days later. Therefore, the final technical success rate of EUS-HGS was 100% (22/22). Mean procedure time of EUS-HGS was 15.0 minutes. AEs were observed in three of 22 patients (13.6%; abdominal pain, n = 2; cholangitis, n = 1), all of which were treated conservatively.

► **Table 2** shows the results of the procedures. TAD was attempted at approximately 11 days after EUS-HGS. Prior to insertion of the cholangioscope into the biliary tract, the mesh

► **Table 1** Patient characteristics.

Characteristic	Variable
Total patients (n)	22
Median age (y, range)	75 (56–88)
Sex (male / female)	14 / 8
Clinical symptom	
▪ Cholangitis	16
▪ Obstructive jaundice	6
Primary disease, n	
▪ Pancreatic carcinoma	8
▪ Cholangiocarcinoma	6
▪ Chronic pancreatitis	1
▪ Intraductal papillary mucinous adenoma	3
▪ Common bile duct stone	4
Puncture site	
▪ B3	19
▪ B2	3
Puncture needle	
▪ 19G	20
▪ 22G	2
Mean diameter of intrahepatic bile duct at puncture site, mm ( $\pm$ SD)	3.85 $\pm$ 1.50
WBC (/ $\mu$ L, mean $\pm$ SD)	9129 $\pm$ 1112
CRP (mg/dL, mean $\pm$ SD)	3.0 $\pm$ 2.9
Hb (mg/dL, mean $\pm$ SD)	11.0 $\pm$ 2.0
T-Bil (mg/dL, mean $\pm$ SD)	4.3 $\pm$ 2.1
PLT ( $\times 10^3$ / $\mu$ L, mean $\pm$ SD)	25.1 $\pm$ 11.5
PT-INR (mean $\pm$ SD)	1.1 $\pm$ 0.1
Initial technical success rate of EUS-HGS, % (n)	90.9 (20/22)
Mean procedure time of EUS-HGS, min $\pm$ SD	15 (7–37)
Adverse events associated with EUS-HGS (n)	
▪ Abdominal pain	2
▪ Cholangitis	1

SD, standard deviation; WBC, white blood cell; CRP, C-reactive protein; Hb, hemoglobin; T-Bil, total bilirubin; PLT, platelets; PT-INR, prothrombin time-international normalized ratio; EUS-HGS, ultrasound-guided hepaticogastrostomy.

of EUS-HGS stent was dilated by balloon catheter in most cases (n = 20). The cholangioscope was inserted successfully in all patients after this procedure. Cholangioscopy revealed stricture without evidence of malignancy in 19 patients. In the remaining three patients, stricture was not observed and these patients underwent stent exchange rather than TAD. Among the 19 patients, passage of the guidewire across the HJS into the in-



► **Table 2** Results of procedures.

	Drill dilator
Period of transluminal antegrade drill dilation after EUS-HGS, days (median, range)	11 (7–19)
Type of SEMS dilation device, n	
▪ Balloon catheter	20
▪ Electrocautery dilator	2
Technical success rate of cholangioscope insertion into the biliary tract, % (n)	100 (22/22)
Cholangioscopic findings	
▪ Stricture	19
▪ Non-stricture	3
▪ Malignancy	0
Technical success rate of guidewire passage across HJS, % (n)	78.9 (15/19)
Mean procedure time of transluminal antegrade piecemeal drill dilation, min ± SD	22.8 ± 8.2
Cholangioscopic findings after antegrade drill dilation, % (n)	
▪ Bleeding	0
▪ Perforation	0
Fistula formation, % (n)	100 (19/19)
Adverse events associated with procedure, n	
▪ Cholangitis	1
Recurrence of HJS after antegrade dilation, % (n)	0 (0/19)
Mean follow-up period, days ± SD	127.4 ± 25.8
EUS-HGS, ultrasound-guided hepaticogastrostomy; SEMS, self-expanding metal stent; HJS, hepaticojunostomy; SD, standard deviation.	

testine was unsuccessful in four patients, and the technical success rate of this procedure was 78.9%. TAD was successful in all 15 patients in whom passage of the guidewire was achieved. After TAD, cholangioscopy identified no bleeding or perforation in any patient. Mean procedure time of TAD was 22.8 min. Finally, in our strategy, after HJS treatment, plastic stent exchange was performed every 3 months. After 12 months, the HGS stent might be removed if HJS recurrence was not observed. However, in our study, because of a short follow-up period, the clinical outcome could not be evaluated.

## Discussion

In the case of surgically altered anatomy, there are two access routes to a biliary lesion: percutaneous and endoscopic. In a recent study, Choi et al evaluated the outcomes of patients with HJS who underwent PTBD or DB-ERCP [8]. Among these patients, 82 underwent DB-ERCP for suspected HJS, in whom the endoscope could reach the desired site in 63 (technical success rate, 77%); and 41 patients were diagnosed with HJS. The clinical

success rate for DB-ERCP and/or PTBD was 71% (29/41). Among the clinically successful cases, only 20 patients underwent DB-ERCP, and AEs were observed in 7%. They concluded that DB-ERCP is an effective diagnostic and therapeutic tool for HJS, with low complication rates. However, the technical success rate was not as high in the present study; in fact, PTBD was required in 49% (20/41). In addition, the procedure time of DB-ERCP can be prolonged. As an alternative approach, EUS-guided techniques have recently emerged. Khashab et al conducted an international comparative study between EUS-guided (n = 49) and enteroscopic access (n = 49) among 98 patients with surgically altered anatomy [21]. Regarding the technical success rate, that of EUS-BD (48/49, 98%) was significantly higher than that of DB-ERCP (32/49, 65.3%) (OR 12.48, *P* = 0.001). In addition, procedure time was significantly shorter in EUS-BD compared with DB-ERCP (55 minutes vs 95 minutes, *P* < 0.01). Although AEs were observed more frequently in EUS-BD compared with DB-ERCP (20% vs 4%, *P* = 0.01), the majority of AEs were mild/moderate. Therefore, EUS-BD may be increasingly attempted for patients with surgically altered anatomy.

As HJS treatment techniques, balloon dilation, plastic stent, and metal stent deployment have been reported [2, 8, 9, 10, 11, 15, 16, 17, 18, 19, 22, 23, 24]. Although balloon dilation is a simple procedure with a high technical success rate, the restenosis rate has been reported to range from 34.3% to 52.2% [22, 23]. In contrast, Tomoda et al conducted a prospective evaluation study of balloon dilation with plastic stent deployment for HJS under DB-ERCP guidance [9]. Of the 40 patients enrolled in the study, cholangiography was successful and both balloon dilation and plastic stent deployment across the HJS were achieved in 39 patients without severe AEs. Kawasaki et al described double FCSEMS deployment for the left and right hepatic bile ducts under DB-ERCP guidance [2], which was successful in all 20 patients with safe procedure results. We have also previously described transluminal antegrade FCSEMS deployment through EUS-HGS [15], but our technique has the critical limitation of the risk of bilateral bile duct obstruction due to FCSEMS depending on the distance between the HJS and bifurcation of the right and left hepatic bile ducts; therefore, the technique of Kawasaki et al may be useful. However, despite encouraging results, their study had several limitations, including prolonged procedure time due to DB-ERCP, high costs, and a high rate of AEs.

We developed TAD for treatment of HJS after EUS-HGS using PCSEMS. In case of non-bile duct dilatation, because the gap between PCSEMS and bile duct is observed, hyperplasia or stent ductal induced change can be complicated [25]. However, in our study, PCSEMS is removed within 14 days. Therefore, this AE was not seen in any patients. In addition, stent dislocation is sometimes critical AEs. If fully-covered SEMS is used as EUS-HGS stent, stent dislocation should be considered. Therefore, in our study, PCSEMS was used although there is the possibility of difficult stent removal.

Also, several points about our technique should be discussed. First, the time required for TAD is short due to the simplicity of the technical step for HJS dilation. However, before TAD, EUS-HGS first should be performed, and several days are need-

ed until fistula creation between hepatic parenchyma and stomach. Therefore, the overall procedure time may be prolonged.

Second, the cost is less than that for balloon dilation combined with FCSEMS deployment for HJS site, as in our previous study [15]. However, our technique has a high cost compared with DB-ERCP because EUS-HGS was performed using a metal stent and balloon catheter, and after fistula creation, a cholangioscope was used. Third, HJS dilation was performed by compression effect in previous studies. In our technique, scar tissue can be scraped off, which may play an important role in preventing recurrence of HJS. A drill dilator may be effective for not only the site itself but also around it. Therefore, the rotating force of a drill dilator may scrape off not only the HJS site but also scar tissue around the HJS site. As a similar technique, HJS dilation using a Soehendra stent retriever (SSR) has been reported [26]. Although SSR may be useful for HJS dilation, technical success may not be obtained in all patients because of the large gap between the tip and the screw. In addition, SSR may not be suitable for antegrade dilation because the gap may become lodged in a bile duct branch during device insertion. In contrast, the tip of the drill dilator used in the present technique tapers to the 0.025-inch guidewire, and the diameter of the shaft of the device gradually increases; therefore, these matters may not be needed to be considered. We previously reported a similar technique for HJS using a fine-gauge electrocautery dilator [27]. Antegrade electrocautery dilation for HJS can penetrate a severe tight stricture. However, as mentioned above, scraping off scar tissue may be important to prevent recurrence of HJS. Electrocautery dilation might not be able to scrape off scar tissue, and in addition, electrocautery dilation itself might lead to stenosis due to a burn effect. Therefore, compared with electrocautery dilation, the present technique may be favorable, although these scenarios should be evaluated in a comparison study.

There are several limitations of the present study, including the small sample size, the lack of a control group, and a short period of follow up.

## Conclusions

In conclusion, TAD appears to be technically feasible and safe. Although it is necessary to conduct a randomized trial in comparison with other methods, with long-term follow-up, TAD may be a useful option for the treatment of HJS.

## Conflict of Interest

The authors declare that they have no conflict of interest.

## References

- [1] Csendes A, Navarrete C, Burdiles P et al. Treatment of common bile duct injuries during laparoscopic cholecystectomy: endoscopic and surgical management. *World J Surg* 2001; 25: 1346–1351
- [2] Kawasaki Y, Hijioka S, Nagashio Y et al. A novel endoscopic technique using fully-covered self-expandable metallic stents for benign strictures after hepaticojejunostomy: the saddle-cross technique (with video). *Surg Endosc* 2022; 36: 9001–9010
- [3] Versteijne E, van Dam JL, Suker M et al. Neoadjuvant chemoradiotherapy versus upfront surgery for resectable and borderline resectable pancreatic cancer: long-term results of the Dutch randomized PREOPANC Trial. *J Clin Oncol* 2022; 40: 1220–1230 doi:10.1200/JCO.21.02233
- [4] Ghaneh P, Palmer D, Cicconi S et al. Immediate surgery compared with short-course neoadjuvant gemcitabine plus capecitabine, FOLFIRINOX, or chemoradiotherapy in patients with borderline resectable pancreatic cancer (ESPAC5): a four-arm, multicentre, randomised, phase 2 trial. *Lancet Gastroenterol Hepatol* 2023; 8: 157–168 doi:10.1016/S2468-1253(22)00348-X
- [5] Cho IR, Jeong SH, Kang H et al. Diagnostic performance of endoscopic ultrasound elastography for differential diagnosis of solid pancreatic lesions: A propensity score-matched analysis. *Pancreatology* 2023; 23: 105–111 doi:10.1016/j.pan.2022.12.002
- [6] Dietrich CF, Shi L, Koch J et al. Early detection of pancreatic tumors by advanced EUS imaging. *Minerva Gastroenterol (Torino)* 2022; 68: 133–143 doi:10.23736/S1121-421X.20.02789-0
- [7] Angileri SA, Gorga G, Tortora S et al. Biliary injuries after pancreatic surgery: interventional radiology management. *Gland Surg* 2019; 8: 141–149 doi:10.21037/gs.2019.01.05
- [8] Choi KKH, Bonnichsen M, Liu K et al. Outcomes of patients with hepaticojejunostomy anastomotic strictures undergoing endoscopic and percutaneous treatment. *Endosc Int Open* 2023; 11: E24–E31
- [9] Tomoda T, Kato H, Ueki T et al. Efficacy of double-balloon enteroscopy-assisted endoscopic balloon dilatation combined with stent deployment for hepaticojejunostomy anastomotic stricture. *Dig Endosc* 2022; 34: 604–611
- [10] Tomoda T, Kato H, Miyamoto K et al. Comparison between endoscopic biliary stenting combined with balloon dilation and balloon dilation alone for the treatment of benign hepaticojejunostomy anastomotic stricture. *J Gastrointest Surg* 2020; 24: 1352–1358
- [11] Sato T, Kogure H, Nakai Y et al. Double-balloon endoscopy-assisted treatment of hepaticojejunostomy anastomotic strictures and predictive factors for treatment success. *Surg Endosc* 2020; 34: 1612–1620 doi:10.1007/s00464-019-06924-6
- [12] Kamal F, Khan MA, Lee-Smith W et al. Efficacy and safety of EUS-guided gallbladder drainage for rescue treatment of malignant biliary obstruction: A systematic review and meta-analysis. *Endosc Ultrasound* 2023; 12: 8–15 doi:10.4103/EUS-D-21-00206
- [13] Dell'Anna G, Ogura T, Vanella G et al. Endoscopic ultrasound guided biliary interventions. *Best Pract Res Clin Gastroenterol* 2022; 101810: 60–61
- [14] Matsunami Y, Itoi T, Sofuni A et al. EUS-guided hepaticoenterostomy with using a dedicated plastic stent for the benign pancreaticobiliary diseases: A single-center study of a large case series. *Endosc Ultrasound* 2021; 10: 294–304
- [15] Ogura T, Nishioka N, Yamada M et al. Novel transluminal treatment protocol for hepaticojejunostomy stricture using covered self-expandable metal stent. *Surg Endosc* 2021; 35: 209–215 doi:10.1007/s00464-020-07381-2
- [16] James TW, Fan YC, Baron TH. EUS-guided hepaticoenterostomy as a portal to allow definitive antegrade treatment of benign biliary diseases in patients with surgically altered anatomy. *Gastrointest Endosc* 2018; 88: 547–554 doi:10.1016/j.gie.2018.04.2353
- [17] Park DH, Jang JW, Lee SS et al. EUS-guided transhepatic antegrade balloon dilation for benign bilioenteric anastomotic strictures in a patient with hepaticojejunostomy. *Gastrointest Endosc* 2012; 75: 692–693

- [18] Sato T, Kogure H, Nakai Y et al. Endoscopic treatment of hepaticojunostomy anastomotic strictures using fully-covered metal stents. *Dig Endosc* 2021; 33: 451–457 doi:10.1111/den.13773
- [19] Inoue T, Ibusuki M, Kitano R et al. Radial incision and cutting combined with balloon dilation for refractory pancreaticojejunostomy anastomotic strictures. *Endosc Int Open* 2021; 9: E578–E582
- [20] Cotton PB, Eisen GM, Aabakken L et al. A lexicon for endoscopic adverse events: report of an ASGE workshop. *Gastrointest Endosc* 2010; 71: 446–454 doi:10.1016/j.gie.2009.10.027
- [21] Khashab MA, El Zein MH, Sharzei K et al. EUS-guided biliary drainage or enteroscopy-assisted ERCP in patients with surgical anatomy and biliary obstruction: an international comparative study. *Endosc Int Open* 2016; 4: E1322–E1327 doi:10.1055/s-0042-110790
- [22] Yamauchi H, Kida M, Miyata E et al. Endoscopic balloon dilation for benign bilioenteric stricture: outcomes and factors affecting recurrence. *Dig Dis Sci* 2019; 64: 3557–3567 doi:10.1007/s10620-019-05811-3
- [23] Tomoda T, Tsutsumi K, Kato H et al. Outcomes of management for biliary stricture after living donor liver transplantation with hepaticojunostomy using short-type double-balloon enteroscopy. *Surg Endosc* 2016; 30: 5338–5344
- [24] Sato T, Kogure H, Nakai Y et al. Endoscopic treatment of hepaticojunostomy anastomotic strictures using fully-covered metal stents. *Dig Endosc* 2021; 33: 451–457 doi:10.1111/den.13773
- [25] Yoo JJ, Lee JK, Moon JH et al. Intraductal placement of non-flared fully-covered metallic stent for refractory anastomotic biliary strictures after living donor liver transplantation: Long-term results of prospective multicenter trial. *J Gastroenterol Hepatol* 2020; 35: 492–498 doi:10.1111/jgh.14831
- [26] Inoue T, Ibusuki M, Kitano R et al. Severe biliary stricture dilation using the Soehendra stent retriever with a short-type balloon enteroscope in patients with surgically altered anatomies. *J Gastrointest Surg* 2019; 23: 953–958
- [27] Ogura T, Nishioka N, Yamada M et al. Technical feasibility and safety of transluminal antegrade dilation for hepaticojunostomy stricture using a novel fine-gauge electrocautery dilator (with video). *Endosc Int Open* 2020; 8: E733–E737