Characteristic endoscopic findings in early-stage autoimmune gastritis

Authors

Tohru Kotera[1], Maki Ayaki[2], Naoki Sumi[3], Rika Aoki[4], Katsuhiro Mabe[5], Kazuhiko Inoue[6], Noriaki Manabe[2], Tomoari Kamada[7], Ryoji Kushima[8], Ken Haruma[9]

Institutions

1 Department of Medical Examination, Uji Tokushukai Medical Center, Uji, Japan
2 Division of Endoscopy and Ultrasonography, Department of Clinical Pathology and Laboratory Medicine, Kawasaki Medical School, Okayama, Japan
3 Department of Health Care Medicine, Kawasaki Medical School, Kurashiki, Japan
4 Department of Health Screening, Tokushima Health Screening Center, Tokushima, Japan
5 Department of Gastroenterology, Junpukai Health Maintenance Center-Kurashiki, Kurashiki, Japan
6 Health Care Medicine, Junpukai Health Maintenance Center, Okayama, Japan
7 Department of Health Care Medicine, Kawasaki Medical School General Medical Center, Okayama, Japan
8 Department of Pathology, Shiga University of Medical Science, Otsu, Japan
9 Department of Internal Medicine 2, Kawasaki Medical School General Medical Center, Okayama, Japan

Keywords

autoimmune gastritis, early stage, endoscopy

received 12.5.2023
accepted after revision 16.11.2023
accepted manuscript online 21.11.2023

Bibliography

Endosc Int Open 2024; 12: E332–E338
DOI 10.1055/a-2215-3284
ISSN 2364-3722

Georg Thieme Verlag KG, Rüdigerstraße 14, 70469 Stuttgart, Germany

Corresponding author

Dr. Tohru Kotera, MD, PhD, Uji Tokushukai Medical Center, Department of Medical Examination, Uji, Japan
tohru.k326@hotmail.co.jp

ABSTRACT

Background and study aims Until recently, autoimmune gastritis (AIG) was usually diagnosed at late stages based on typical endoscopic findings, including corpus-dominant advanced atrophy. Early-stage AIG prior to complete gastric atrophy had rarely been diagnosed due to a lack of knowledge about its endoscopic characteristics. The present study sought to identify the endoscopic characteristics of early-stage AIG, enabling its early diagnosis.

Patients and methods The clinical and endoscopic findings of 12 patients diagnosed with early-stage AIG between 2016 and 2021 were retrospectively evaluated. Patients were included if they were: (1) positive for serum anti-parietal cell antibody; (2) diagnosed with histological early-stage AIG; and (3) endoscopically positive for folds on the greater curvature of the gastric corpus.

Results Two characteristic endoscopic findings of early-stage AIG were identified: longitudinal alignment of pseudopolyps (i. e., a bamboo joint-like appearance) and swelling of gastric areas with erythema (i. e., a salmon roe-like appearance).

Conclusions Endoscopic findings characteristic of early-stage AIG include a bamboo joint-like appearance and a salmon roe-like appearance. Studies in large numbers of patients with long-term follow-up are needed to confirm these findings.

Introduction

Autoimmune gastritis (AIG) is a type of chronic atrophic gastritis, in which immune-mediated destruction of fundic glands progresses toward severe gastric atrophy. AIG was previously considered a rare disease in Japan due to the low prevalence of pernicious anemia [1, 2]. More recently, however, reports of AIG have increased in Japan [3, 4], with a prevalence approaching that in western countries. Until recently, AIG was usually diagnosed during later stages based on typical endoscopic findings, including corpus-dominant advanced atrophy [3, 4]. Although histopathological evaluation has shown that AIG progresses from early to end stage [5], early-stage AIG has rarely been diagnosed prior to complete gastric atrophy, due to a lack of knowledge about its endoscopic characteristics. Several patients were recently diagnosed histologically and serologically with early-stage AIG [6, 7, 8, 9, 10, 11]. Since then, additional patients have been diagnosed with AIG before complete gastric atrophy. Eradication therapy in *Helicobacter pylori*-positive patients and steroid treatment in *H. pylori*-negative patients may halt its progression, or even cure this condition [12, 13, 14]. Although diagnostic criteria for AIG in Japan, including early-stage AIG, have been proposed, endoscopic findings of early-stage AIG were not included in the criteria [15]. The present study sought to identify the endoscopic characteristics of early-stage AIG, enabling its early diagnosis.

Patients and methods

Diagnostic criteria for early-stage AIG

The Japanese diagnostic criteria for AIG have recently been established [15], but the endoscopic findings for early-stage AIG were not part of these criteria. According to the proposed criteria, histological findings and gastric autoantibody positivity are required for the diagnosis of early-stage AIG. Histological findings of early-stage AIG were specified as follows: the parietal cell/mucous neck cell layer of the oxyntic glands is preserved without interruption; the remaining parietal cells exhibit degeneration and pseudohypertrophy; lymphocytic infiltration is observed between the oxyntic glands; and hyperplasia of enterochromaffin-like (ECL) cells is not always present.

Patients

The clinical and endoscopic characteristics of patients diagnosed with AIG prior to complete gastric atrophy between 2016 and 2021 were retrospectively reviewed. Patients were included if they were: (1) positive for serum anti-parietal cell antibody (PCA); (2) diagnosed histologically with early-stage AIG; and (3) endoscopically positive for folds on the greater curvature of the gastric corpus. Patients were excluded if endoscopy revealed severe gastric atrophy with marked vascular visibility and disappearance of folds, which is the most common endoscopic feature in advanced-stage AIG patients [4]. None of these patients had a history of long-term use of proton pump inhibitors.

Laboratory tests

Serum PCA concentrations were assessed by an indirect immunofluorescence test, with titers ≥ 1:10 considered positive. Serum gastrin concentrations were measured by radioimmunoassay (normal range: < 200 pg/mL). Serum concentrations of anti-*H. pylori* antibody (*H. pylori* Ab) were measured by enzyme-linked immunosorbent or latex immunoturbidimetric assays. *H. pylori* infection status was defined as: (1) uninfected in patients with no history of *H. pylori* eradication and *H. pylori* Ab < 3.0 U/mL; (2) previously infected in patients with a history of *H. pylori* eradication; (3) currently infected in patients with no history of *H. pylori* eradication and a *H. pylori* Ab titer of ≥ 10 U/mL; or (4) indeterminate in patients with no history of *H. pylori* eradication and *H. pylori* Ab 3.0 to 9.9 U/mL. Uninfected or currently infected *H. pylori* status was confirmed based on endoscopic findings [16].

Assessment of endoscopic appearance

The patients in this study had undergone endoscopy at six institutions: Uji-Tokushukai Medical Center, Sakaide City Hospital, Tokushima Health Screening Center, Kawasaki Medical School General Medical Center, Junpukai Health Maintenance Center, and Junpukai Health Maintenance Center-Kurashiki. Endoscopic images were retrospectively reevaluated by three endoscopists (T.K., M.A., and K.H.). The presence or absence of gastric mucosal atrophy was assessed in the antrum and the lesser and greater curvature of the corpus. The Kimura-Takemoto classification [17] was not used because the atrophic border could not be clearly determined in most patients in the present study. Associated local endoscopic findings were also evaluated.

Histopathological evaluations

Biopsy specimens were obtained from the greater curvature of the upper or middle corpus in all 12 patients and from the greater curvature of the antrum in eight of 12 patients, and histological gastritis was assessed by an expert pathologist (R.K.) according to the updated Sydney system [18]. Pseudopyloric metaplasia was examined in 10 patients together with immunostaining for MUC6 and pepsinogen I. Patients were diagnosed with histological early-stage AIG based on the presence of persisting oxyntic glands damaged by lymphocytic infiltration, and pseudohypertrophy of the remaining parietal cells [15] (▶ **Fig. 1**). All of these patients were positive for linear or nodular hyperplasia of ECL cells, as shown by immunostaining for chromogranin A, confirming the diagnosis of AIG. Biopsy specimens were taken from pseudopolyps of five patients, with findings in these specimens being histologically consistent with oxyntic mucosa pseudopolyps [19, 20, 21].

Statement of ethics

This study was conducted in accordance with the guidelines of the Declaration of Helsinki. The study protocol was reviewed and approved by the Ethics Committees of Uji-Tokushukai Medical Center (approval number TGE01906–007) and Kawasaki Medical School (approval number 5178–01). Written informed consent was obtained from each participant.

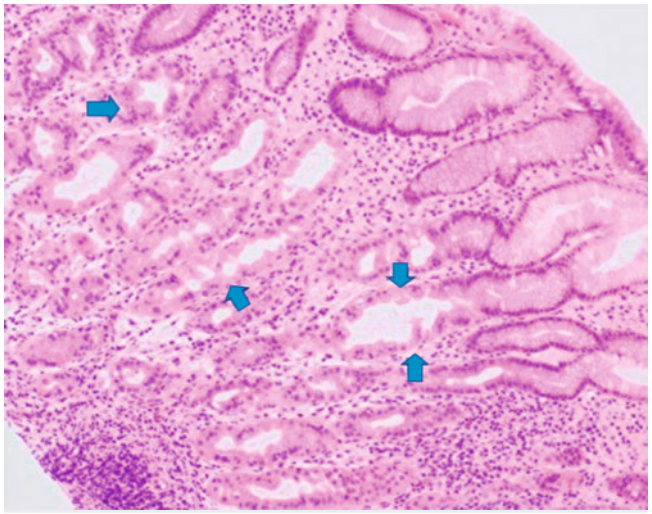

▶ **Fig. 1** A representative image of the histopathological findings of early-stage AIG. Pseudohypertrophy of residual parietal cells, exhibiting cytoplasmic protrusion into the lumen (*arrows*). (Greater curvature of the corpus in Patient 6; hematoxylin and eosin staining).

Results

Clinical profiles

The present study enrolled 12 patients, seven men and five women, mean age 56.2 years (range: 41–71 years) (▶ **Fig. 2**). Most of these patients underwent endoscopy as part of their health checkups, with reasons for endoscopy including a previous history of vitamin B_{12} deficiency, iron deficiency anemia, and abnormal serum pepsinogen (PG) levels. Serum PCA titers were ≥ 1:160 in 11 patients, with one having a PCA titer of 1:80. Serum gastrin levels (mean: 1350.1 pg/mL) were < 1000 pg/mL in six patients. Evaluation of *H. pylori* infection status showed that eight patients were uninfected, three were previously infected, and one was indeterminate. None of the patients were currently infected. Three patients had accompanying autoimmune diseases, including two with Basedow's disease, and one with type I diabetes. Case reports of seven of these patients have been published [6, 7, 8, 10, 11].

Endoscopic findings and histopathological evaluations

Endoscopic findings from the 12 patients, including the extent of endoscopic gastric atrophy and associated local appearances, are summarized in ▶ **Fig. 2**. Histopathological evaluations of gastritis are summarized in ▶ **Table 1**.

Endoscopically, three patients showed no atrophic changes in either the antrum or corpus. Corpus atrophy was observed in the other nine patients, seven of whom showed no atrophy in the greater curvature of the corpus and six of whom showed no atrophy in the antrum. Histologically, among 12 patients, no gastric atrophy of the corpus was observed in eight patients and mild atrophy was observed in four. Inflammation was mild in two patients, moderate in nine, and severe in one. Among eight patients studied, mild atrophy or inflammation of the antrum was observed in two patients, who had been previously infected with *H. pylori*. Pseudopyloric metaplasia was present in

	Age/sex	PCA (1:X)	Gastrin (pg/mL)	*H. pylori* status	Endoscopy findings					Reasons for endoscopy
					Atrophy			Bamboo joint-like appearance	Salmon roe-like appearance	
					Antrum	Corpus				
						Lesser curvature	Greater curvature			
1	66/M	320	338	U	-	-	-	-	-	Past VB_{12} deficiency
2	43/F	640	894	U	-	-	-	-	+	Checkup
3	45/M	320	1386	U	-	-	-	+	+	low PGI, PGI/PGII
4	70/M	≥160	730	U	-	+	-	+	+	Checkup
5	41/F	160	1804	I	+	+	-	-	+	Checkup
6	65/F	320	540	P	+	+	-	+	+	Checkup
7	48/M	160	697	U	-	+	-	+	+	Checkup
8	41/F	160	680	P	±	±	±	+	-	Fe deficiency
9	64/M	80	1049	U	-	±	±	+	-	Checkup
10	71/M	320	1018	P	-	+	-	+	+	Checkup
11	70/F	640	5265	U	-	+	-	+	-	Checkup
12	50/M	≥160	1800	U	-	+	-	+	-	Checkup

H. pylori status: uninfected (U), previously infected (P), indeterminate (I).
PCA, parietal-cell antibody; VB_{12}, vitamin B_{12}; PG, pepsinogen; +, diffusely present; ±, partially recognized.

▶ **Fig. 2** Clinical profiles and endoscopic findings of the patients included in the present study.

▶ **Table 1** Histological evaluations of gastritis.

	Antrum		Corpus		
	Atrophy	Inflammation	Atrophy	Inflammation	Pseudopyloric metaplasia
1	None	None	None	Moderate	Present
2	None	None	None	Moderate	Present
3	None	None	None	Moderate	Present
4	None	None	Mild	Moderate	NT
5	NT	NT	None	Moderate	Present
6	NT	NT	Mild	Severe	Present
7	NT	NT	None	Moderate	Present
8	Mild	Mild	Mild	Moderate	Present
9	None	None	Mild	Mild	Present
10	Mild	None	None	Moderate	Present
11	NT	NT	None	Moderate	Present
12	None	None	None	Mild	NT

NT, not tested.

all 10 patients studied, while intestinal metaplasia was absent in all 12 patients.

Multiple pseudopolyps were detected in seven patients (▶ **Fig. 3**). These pseudopolyps were longitudinally aligned in rows along the long axis of the gastric corpus, which had a bamboo joint-like appearance. Swollen folds were incompletely segmented by shallow furrows in two patients, showing a bamboo joint-like appearance (▶ **Fig. 4b**). Thus, a total of nine patients presented endoscopically with a bamboo joint-like appearance.

Edematous mucosa with enlarged gastric areas and erythema, called a salmon roe-like appearance, was observed in non-atrophic areas of the gastric corpus in seven patients (▶ **Fig. 4**). Histologically, these enlarged gastric areas exhibited persisting oxyntic glands damaged by lymphocytic infiltration. Four of these patients also presented with a bamboo joint-like appearance (▶ **Fig. 4b**).

One patient with a previous history of vitamin B_{12} deficiency was suspected of having AIG, despite presenting with a normal endoscopic appearance (▶ **Fig. 5a**, ▶ **Fig. 5b**, ▶ **Fig. 5c**) and lacking any of the characteristic endoscopic findings (Patient 1 in ▶ **Fig. 2**). A diagnosis of early-stage AIG in this patient was confirmed by histopathological findings (▶ **Fig. 5d**) and a high titer of PCA.

Discussion

To our knowledge, this study is the first to evaluate the endoscopic characteristics of patients with early-stage AIG. Two endoscopic findings were found in patients with AIG prior to complete gastric atrophy: longitudinal alignment of pseudopolyps (called a bamboo joint-like appearance) and swelling of gastric areas with erythema (called a salmon roe-like appearance).

The first clues by which patients were suspected of having AIG are shown with a light blue background in ▶ **Fig. 2**. Endoscopic findings were the first clues in 11 patients, with the possibility of AIG suggested by a combination of a bamboo joint-like or salmon roe-like appearance in the corpus and non-atrophic or slightly atrophic antrum. Because these endoscopic findings are uncommon in patients with *H. pylori* gastritis, they could have potential for the endoscopic detection of early-stage AIG. When AIG is suspected based on endoscopic findings or hematologic abnormalities, histological and serological studies are required. Although one biopsy from the greater curvature of the upper corpus is generally considered sufficient, an additional biopsy from the antrum is recommended [15].

Oxyntic mucosa pseudopolyps are a type of remnant oxyntic mucosa spared from atrophic changes in advanced AIG [4, 19, 20, 21]. These pseudopolyps are usually scattered on a background of atrophic mucosa in the proximal corpus and fundus of patients with advanced AIG. In the present study, these pseudopolyps were longitudinally aligned in the greater curvature and the anterior wall of the corpus. They resembled the bamboo joint-like appearance associated with Crohn's disease, in which swollen longitudinal folds traversed by erosive fissures are observed in the lesser curvature of the proximal stomach [22, 23]. Histologically, the bamboo joint-like appearance in patients with Crohn's disease is characterized by edematous stroma of the lamina propria [22], which is different from the oxyntic mucosa pseudopolyps observed in the present study. In one patient, the pseudopolyps were not sessile but semi-pedunculated, mimicking fundic gland polyps, although they were histologically consistent with oxyntic mucosa pseudopolyps (▶ **Fig. 3b**). A case report showed that pseudopolyps initially seen along the gastric folds in the corpus disappeared after 3 years, accompanied by regression of the folds [24]. Thus, pseudopolyps in the gastric corpus presenting with a bamboo joint-like appearance could be an endoscopic manifestation of early-stage AIG in patients with ongoing gastric atrophy.

Swelling of gastric areas with erythema was observed in seven patients, and these areas had a salmon roe-like appearance that resembled the snakeskin (mosaic) pattern reported previously [25], which is a characteristic of portal hypertensive gastropathy and also referred to as red colored caviar-like gastritis [26]. The salmon roe-like appearance also resembles the diffuse redness in *H. pylori* gastritis with current infection [27, 28]. None of these seven patients had portal hypertension or active *H. pylori* infection at the time of endoscopy: four were uninfected, one had been previously infected, and one was indeterminate. However, it may be difficult to observe a salmon

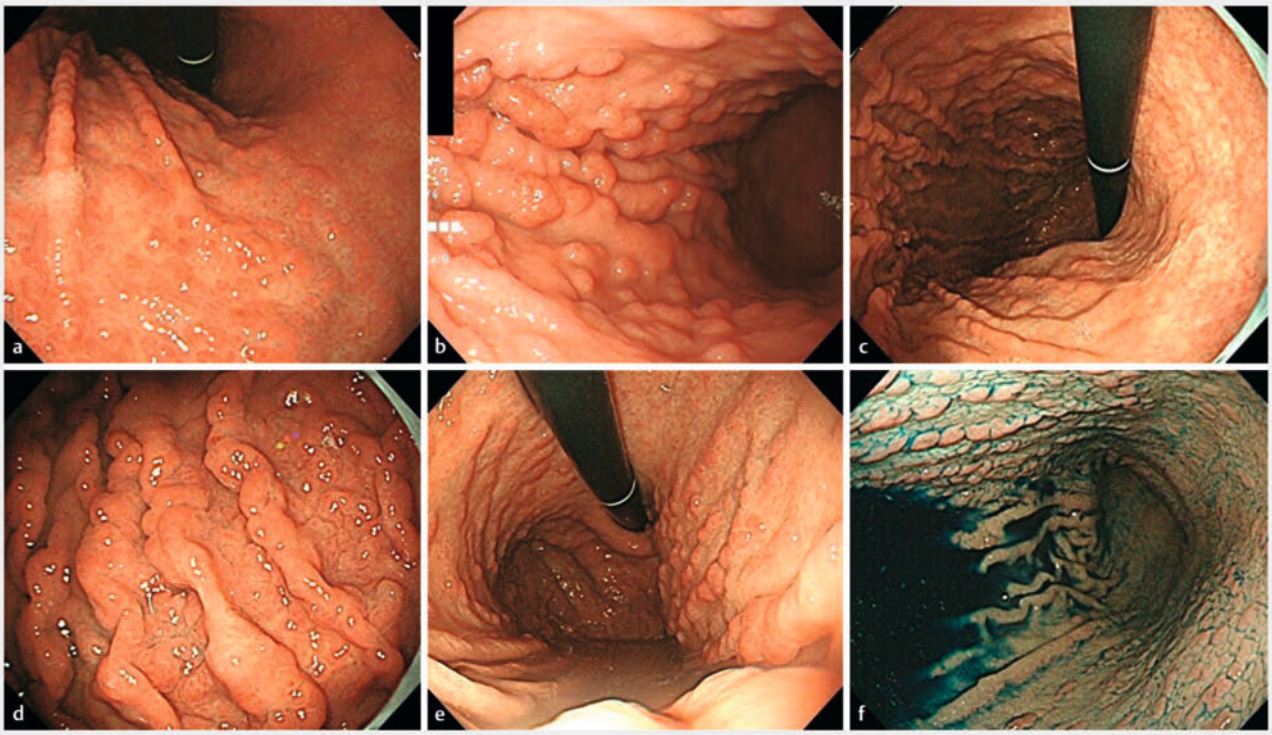

▶ **Fig. 3** Bamboo joint-like appearance on endoscopy of the patients included in this study. **a** Patient 7. **b** Patient 9. **c, d** Patient 10. **e, f** Patient 11, presenting with the bamboo joint-like appearance highlighted with indigo carmine dye in **f**.

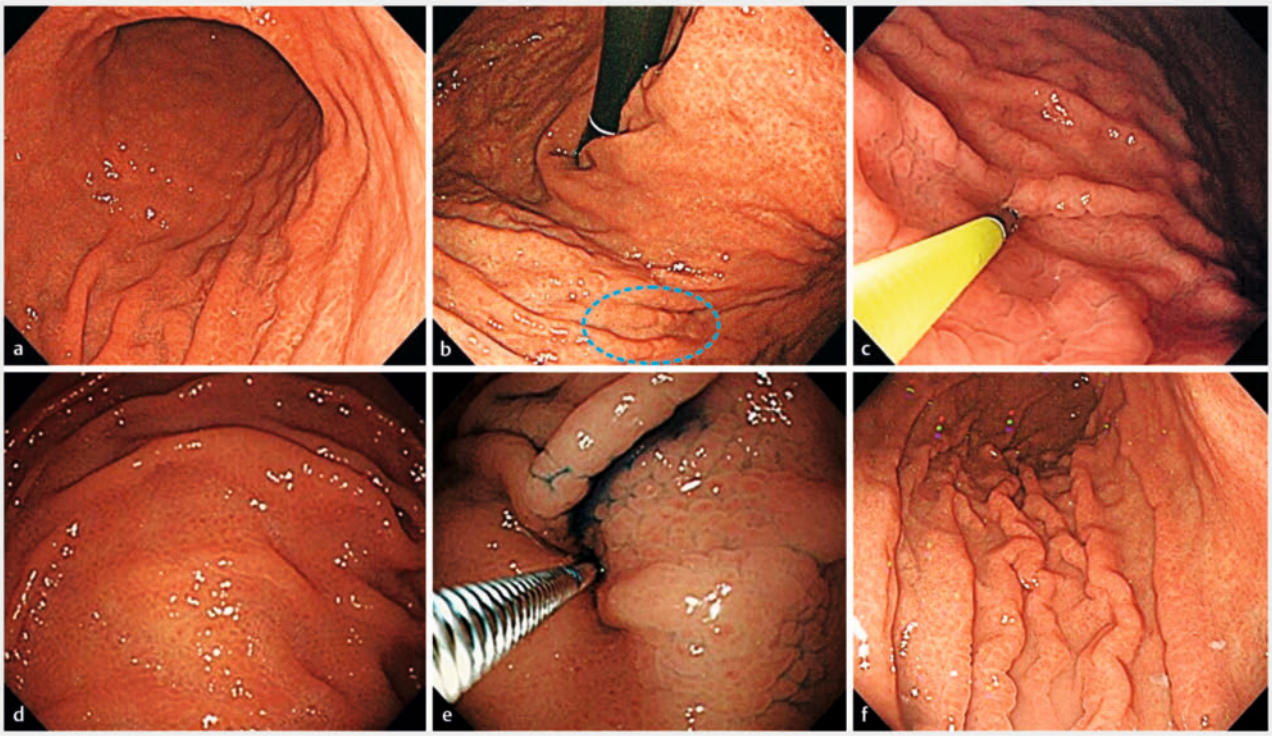

▶ **Fig. 4** Salmon roe-like appearance on endoscopy of the patients included in this study. **a, b** Patient 3, also presenting with a bamboo joint-like appearance (*dotted ellipse* in **b**). **c** Patient 7, showing a close-up view of a salmon roe-like appearance. **d** Patient 5 (accepted for publication by the Japanese Society of Internal Medicine). **e** Patient 5, showing a close-up view highlighted with indigo carmine dye. **f** Patient 6.

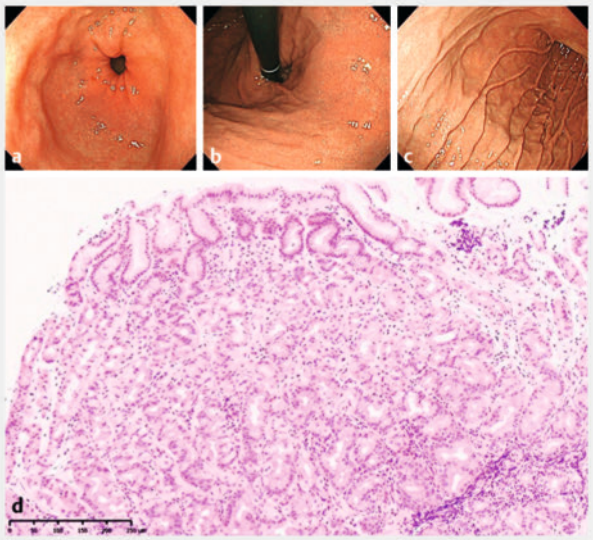

▶ **Fig. 5** A patient with early AIG presenting with a normal endoscopic appearance (Patient 1). **a, b, c** Endoscopic findings. **d** Histopathological findings in the greater curvature of the middle corpus, showing oxyntic glands damaged by lymphocytic infiltration (hematoxylin and eosin staining).

roe-like appearance in AIG patients with active *H. pylori* infection.

Endoscopically, the antrum was atrophic to some extent in three of the nine patients with corpus atrophy. These findings are consistent with those of a previous study of advanced AIG [4], in which fewer than half the cases showed normal coloration of the antral mucosa. Because in the present study, two patients had a previous *H. pylori* infection and infection status was indeterminate in one, the antrum could have been affected by the previous infection of *H. pylori* as well as by bile reflux.

Serum PCA was strongly positive in 11 of these patients, with titers ≥ 1:160. A recent retrospective study of patients with histologically proven AIG showed that their mean PCA titer was significantly higher during the early or florid phase than during the end phase [29], suggesting that the progressive destruction of parietal cells and the resultant decrease in the targeted proton pumps could lead to a reduction in PCA titer. The high PCA titers in the present study indicated that these patients retained sufficient parietal cells to be targeted by lymphocytes, a finding confirmed histopathologically. This hypothesis may be confirmed by long-term follow-up of these patients.

This study had several limitations. First, it was a retrospective study that did not include a control group. Second, the sample size was small, suggesting that the endoscopic findings in these patients may not be indicative of the overall endoscopic findings in patients with early-stage AIG. Other limitations included the use of original selection criteria and the lack of follow-up of all included patients. Although there was a considerable risk of selection bias in the present study, as stated above, an analysis employing a large sample size without selection bias may be impossible due to the rarity of AIG.

Conclusions

In conclusion, the present study suggested that the endoscopic findings observed in this series of patients, including bamboo joint-like and salmon roe-like appearances, could be characteristic of early-stage AIG. Studies in large numbers of patients with long-term follow-up are needed to confirm these findings. These results may contribute to determining the overall endoscopic characteristics associated with early-stage AIG.

Acknowledgement

The authors would like to thank Nicola Edwards (Bioedit Limited) for language editing.

Conflict of Interest

The authors declare that they have no conflict of interest.

References

[1] Haruma K, Komoto K, Kawaguchi H et al. Pernicious anemia and Helicobacter pylori infection in Japan: Evaluation in a country with a high prevalence of infection. Am J Gastroenterol 1995; 90: 1107–1110

[2] Nagao T, Hirokawa M. Diagnosis and treatment of macrocytic anemias in adults. J Gen Fam Med 2017; 18: 200–204

[3] Notsu T, Adachi K, Mishiro T et al. Prevalence of autoimmune gastritis in individuals undergoing medical checkups in Japan. Intern Med 2019; 58: 1817–1823

[4] Terao S, Suzuki S, Yaita H et al. Multicenter study of autoimmune gastritis in Japan: Clinical and endoscopic characteristics. Dig Endosc 2020; 32: 364–372

[5] Miceli E, Vanoli A, Lenti MV et al. Natural history of autoimmune atrophic gastritis: A prospective, single centre, long-term experience. Aliment Pharmacol Ther 2019; 50: 1172–1180

[6] Kotera T, Oe K, Kushima R et al. Multiple pseudopolyps presenting as reddish nodules are a characteristic endoscopic finding in patients with early-stage autoimmune gastritis. Intern Med 2020; 59: 2995–3000

[7] Kotera T, Takemoto T, Kushima R et al. A case of autoimmune gastritis with fundic gland polyp-like pseudopolyps presenting with nodular enterochromaffin-like cell hyperplasia. Clin J Gastroenterol 2021; 14: 98–102

[8] Ayaki M, Aoki R, Matsunaga T et al. Endoscopic and upper gastrointestinal barium X-ray radiography images of early-stage autoimmune gastritis: A report of two cases. Intern Med 2021; 60: 1691–1696

[9] Kishino M, Yao K, Hashimoto H et al. A case of early autoimmune gastritis with characteristic endoscopic findings. Clin J Gastroenterol 2021; 14: 718–724

[10] Kotera T, Yamanishi M, Kushima R et al. Early autoimmune gastritis presenting with a normal endoscopic appearance. Clin J Gastroenterol 2022; 15: 547–552

[11] Kotera T, Yoshioka U, Takemoto T et al. Evolving autoimmune gastritis initially hidden by active Helicobacter pylori gastritis. Case Rep Gastroenterol 2022; 16: 103–109

[12] Müller H, Rappel S, Wündisch T et al. Healing of active, non-atrophic autoimmune gastritis by H. pylori eradication. Digestion 2001; 64: 30–39

[13] Jeffries GH, Todd JE, Sleisenger MH. The effect of prednisolone on gastric mucosal histology, gastric secretion, and vitamin B 12 absorption in patients with pernicious anemia. J Clin Invest 1966; 45: 803–812

[14] Biondo M, Field J, Toh BH et al. Prednisolone promotes remission and gastric mucosal regeneration in experimental autoimmune gastritis. J Pathol 2006; 209: 384–391

[15] Kamada T, Watanabe H, Furuta T et al. Diagnostic criteria and endoscopic and histological findings of autoimmune gastritis in Japan. J Gastroenterol 2023; 58: 185–195

[16] Haruma K, Kato M, Inoue K et al. Kyoto classification of gastritis. 2nd ed. (in Japanese). Nihon Medical Center; Tokyo: 2018

[17] Kimura K, Takemoto T. An endoscopic recognition of the atrophic border and its significance in chronic gastritis. Endoscopy 1969; 1: 87–96

[18] Dixon MF, Genta RM, Yardley JH et al. Classification and grading of gastritis. The updated Sydney System. International Workshop on the Histopathology of Gastritis, Houston 1994. Am J Surg Pathol 1996; 20: 1161–1181

[19] Krasinskas AM, Abraham SC, Metz DC et al. Oxyntic mucosa pseudopolyps: A presentation of atrophic autoimmune gastritis. Am J Surg Pathol 2003; 27: 236–241

[20] Park JY, Cornish TC, Lam-Himlin D et al. Gastric lesions in patients with autoimmune metaplastic atrophic gastritis (AMAG) in a tertiary care setting. Am J Surg Pathol 2010; 34: 1591–1598

[21] Okano A, Takakuwa H, Matsubayashi Y. Parietal-cell hyperplasia mimicking sporadic fundic gland polyps in the atrophic mucosa of autoimmune gastritis . Gastrointest Endosc 2007; 66: 394–395

[22] Yokota K, Saito Y, Einami K et al. A bamboo joint-like appearance of the gastric body and cardia: possible association with Crohn's disease. Gastrointest Endosc 1997; 46: 268–272

[23] Nomura Y, Moriichi K, Fujiya M et al. The endoscopic findings of the upper gastrointestinal tract in patients with Crohn's disease. Clin J Gastroenterol 2017; 10: 289–296

[24] Ikeda T, Senoue I, Hara M et al. Gastric pseudopolyposis: A new clinical manifestation of type A gastritis. Am J Gastroenterol 1985; 80: 82–90

[25] McCormack TT, Sims J, Eyre-Brook I et al. Gastric lesions in portal hypertension: inflammatory gastritis or congestive gastropathy? Gut 1985; 26: 1226–1232

[26] Tsukada Y. Studies on the red spots on gastric mucosa in patients with chronic liver disease. Niigata Igakkai Zasshi (Niigata Med J) 1987; 101: 797–803 (in Japanese, Abstract in English)

[27] Nishino K, Kawanaka M, Manabe N et al. Portal hypertensive gastropathy in liver cirrhosis: Prevalence, natural history, and risk factors. Intern Med 2022; 61: 605–613

[28] Furuichi Y, Koyama Y, Abe M et al. Discrimination between portal hypertensive gastropathy and Helicobacter pylori-related gastritis. Intern Med 2022; 61: 601–603

[29] Nishizawa T, Watanabe H, Yoshida S et al. Decreased anti-parietal cell antibody titer in the advanced phase of autoimmune gastritis. Scand J Gastroenterol 2022; 57: 143–148