

Mid-gastric peroral endoscopic myotomy in the treatment of post-sleeve gastrectomy gastric tube twist: Four cases

OPEN
ACCESS

Authors

Angelique Mugnier¹, Veronique Vitton¹, Marc Barthet¹, Jean-Michel Gonzalez¹ 

Institutions

1 Hôpital Nord, Gastroenterologie, AP-HM, Marseille, France

Keywords

POEM, GI surgery, Benign strictures

received 3.5.2023

accepted after revision 8.11.2023

Bibliography

Endosc Int Open 2024; 12: E139–E144

DOI 10.1055/a-2211-8903

ISSN 2364-3722

© 2024. The Author(s).

This is an open access article published by Thieme under the terms of the Creative Commons Attribution-NonDerivative-NonCommercial License, permitting copying and reproduction so long as the original work is given appropriate credit. Contents may not be used for commercial purposes, or adapted, remixed, transformed or built upon. (<https://creativecommons.org/licenses/by-nc-nd/4.0/>)

Georg Thieme Verlag KG, Rüdigerstraße 14,
70469 Stuttgart, Germany

Corresponding author

Dr. Jean-Michel Gonzalez, AP-HM, Hôpital Nord,
Gastroenterologie, Marseille, France
jean-michel.gonzalez@ap-hm.fr

ABSTRACT

Background and study aims Laparoscopic sleeve gastrectomy (LSG) may lead to symptomatic mid-gastric twist in 0.1% to 4% of cases. Endoscopic balloon dilatation often fails, requiring a switch to Roux-en-Y bypass. Submucosal endoscopic treatment is expanding, so we propose a new technique of fibrosis incision after tunnelization, called medio-gastric peroral endoscopic myotomy (MG-POEM).

Patients and methods Four patients aged 41 to 70 years underwent MG-POEM in 2020 for symptomatic post-LSG medio-gastric twist. The aim was to describe the technique, and document the efficacy, using the Gastric Outlet Obstruction Scoring System (GOOSS) score and a quality-of-life scale (QOLS). The procedures consisted of a POEM with myotomy and fibrosis incision.

Results Median preoperative GOOSS and QOLS were 1/3 ([0]–[3]) and 1.75/10 [0]–[10], respectively. All procedures were technically successful. One patient had immediate postoperative complications, which were treated conservatively. The median follow-up was 18 months. All patients had improved quality of life and food intake, with median postoperative GOOSS and QOLS of 3/3 and 6.5/10 [6]–[8], respectively. Two patients required additional pneumatic dilatation for scarring strictures. Follow-up endoscopies and esophagograms showed that the twist had disappeared.

Conclusions MG-POEM shows promise for safe and effective management of post-LSG mid-gastric twist, despite requiring a high level of endoscopic skill to perform submucosal tunneling.

Introduction

Obesity is a public health problem and the number of bariatric surgical procedures is increasing, indicated in patients with a body mass index (BMI) >40 kg/m² with or without comorbidities, or patients with a BMI between 35 and 40 kg/m² with complications related to obesity that may improve after surgery. The most frequent surgical approach is laparoscopic sleeve gastrectomy (LSG) [1].

Along with fistulas, gastric strictures are the most frequent post-LSG complications. Their incidence varies between 0.1%

and 4% [1,2] and they induce nausea, vomiting, epigastric pain, reflux and consequently dehydration, metabolic deficiency, and under-nutrition. The median time of symptom onset varies between 1 and 61 months depending on the study [2,3,4]. Among the identified etiologies of post-LSG stenosis is mid-gastric twist with a volvulus-like mechanism for which management is routinely a failure with endoscopic management. Endoscopic management includes stenting (with covered metallic stent), pneumatic balloon dilatation (Rigiflex, Boston Scientific, United States), or hydraulic dilation requiring iterative sessions every 2 to 4 weeks [5,6,7]. Surgery is another, more radical op-

tion, consisting of conversion toward Roux-en-Y bypass (RYGB) [8,9,10].

The success rate of endoscopic approaches varies between 44% and 100% according to the literature, with mainly short-term benefits and high recurrence rates [11,12,13]. Thus, the rate of surgical conversion to RYGB after failure of endoscopic treatment can reach 56% [14]. As for pneumatic dilatation, it is safe but often requires iterative dilatation sessions every 2 to 4 weeks, and thus, repeated general anesthesia. Few studies also suggest the potential problem of decreased benefit concerning long-term weight loss in patients who underwent pneumatic dilatation with 40-mm Rigiflex [5,6]. Regarding endoscopic stenting, migration remains a problem with a rate higher than 50%, which may itself induce complications such as bleeding, occlusion, or perforations [7]. Moreover, the benefit of this technique, evaluated at 100% in the short term, is not consistent in the long-term period, because symptoms recurrence occurs in more than 60% of patients after removal [7,11]. The overall complication rate for surgical RYGB is between 5% and 10%, limiting the clinical benefit for its indication as a switch [15].

Recently, submucosal endoscopy has been developed for treating achalasia and gastroparesis. Per oral endoscopic myotomy (POEM) consists of the creation of a submucosal tunnel for the realization of a myotomy of the lower esophageal sphincter in achalasia [16,17] or pyloric in gastroparesis [18,19]. Submucosal management of post-LSG stricture has also been briefly suggested, with promising results [20]. Thus, we propose our experience of medio-gastric POEM for the management of post-LSG gastric tube twist.

Patients and methods

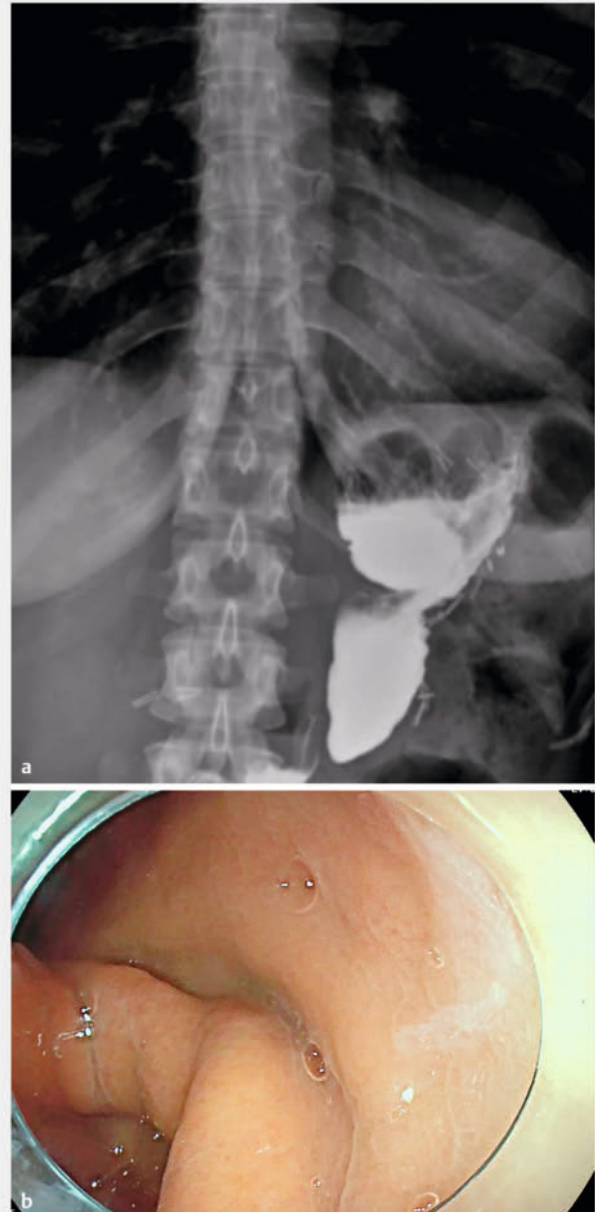
This was a single-center series of four consecutive patients aged 40 to 71 years performed at the Hôpital Nord, Marseille.

Patients

The patients included had all undergone surgical sleeve gastrectomy within the previous 10 years, complicated with mid-gastric twist post-sleeve gastrectomy managed by mid-gastric POEM (MG-POEM). The gastric tube twist was diagnosed by the realization of an esophagogram and an upper gastrointestinal endoscopy (► **Fig. 1a** and ► **Fig. 1b**). All patients were symptomatic with significant clinical impact on food intake (nausea +/- vomiting +/- reflux +/- abdominal pain +/- dehydration +/- under-nutrition), and thus, decreased quality of life (QoL). All the patients had undergone a previous endoscopic treatment that was a failure. The patients included were not eligible for revision surgery because of patient or surgeon refusal (surgery too risky or not feasible). The decision to propose MG-POEM was validated during a Multidisciplinary Obesity Meeting and after patients signed an informed consent.

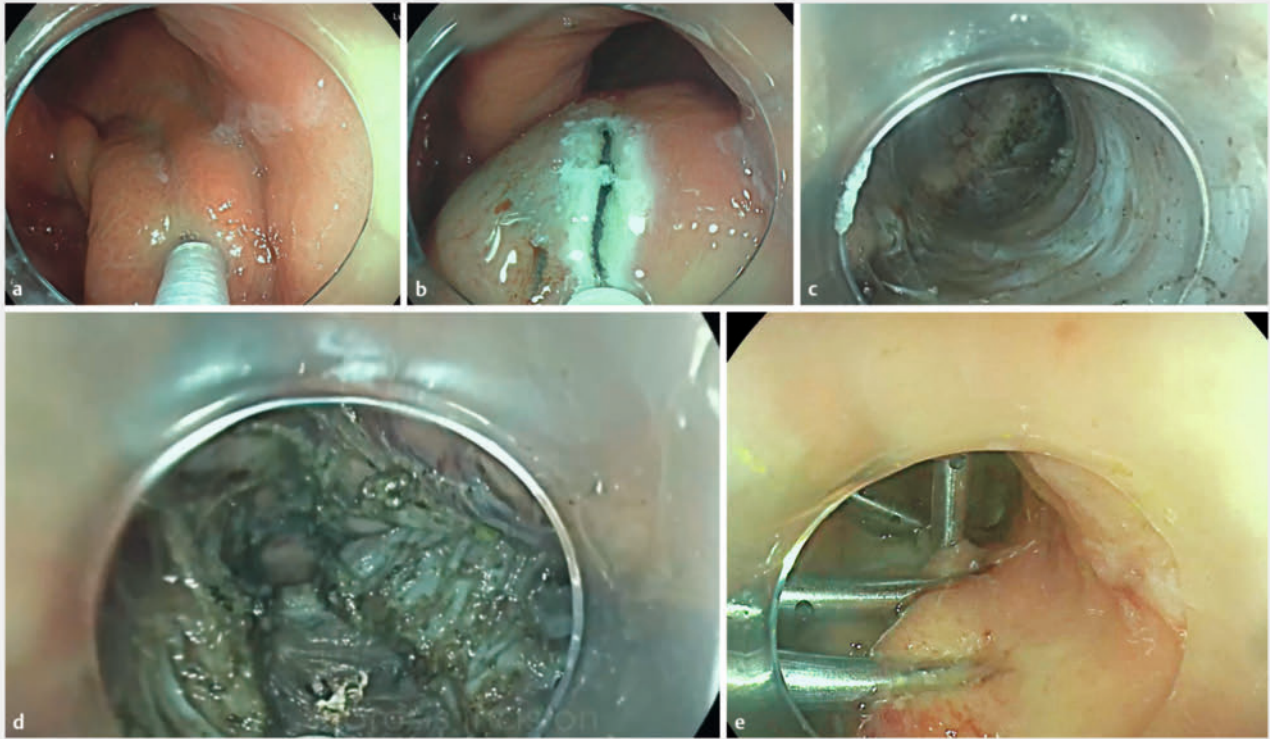
Endoscopic procedure

The procedure (► **Video 1**) was performed under general anesthesia in a supine intubated patient. A large-channel gastro-scope with CO₂ insufflation and a fitted-cap was used (Fuji 3.8



► **Fig. 1** a Preoperative barium radiological study showing the mid-gastric twist b Upper gastrointestinal endoscopy showing the mucosal aspect of the medio-gastric twist responsible for the symptoms

mm, Japan), as well as a Triangle Knife J type dissection knife (Olympus, Japan). The procedure consisted of the following steps (► **Fig. 2**): 1) injection of blue-tinted saline 4 to 5 cm upstream from the twist on the posterior side of the stomach; 2) mucosal incision to access the submucosal space; 3) creation of a tunnel extending beyond the twisted area and ending in the antrum; 4) gastric myotomy of the entire twisted area up to the mucosal opening; and 5) closure of the mucosal access by through-the-scope clips.



► **Fig. 2** **a** Injection of blue-tinted saline 4 to 5 cm upstream from the twist on the posterior gastric wall. **b** Mucosal incision to access the sub-mucosal space. **c** Creation of a tunnel extending beyond the twisted area and ending in the level of the antrum. **d** Gastric myotomy and fibrotomy of the entire twisted area up to the mucosal opening. **e** Closure of the mucosal access by TTS clips.

Patient follow-up and assessment scores

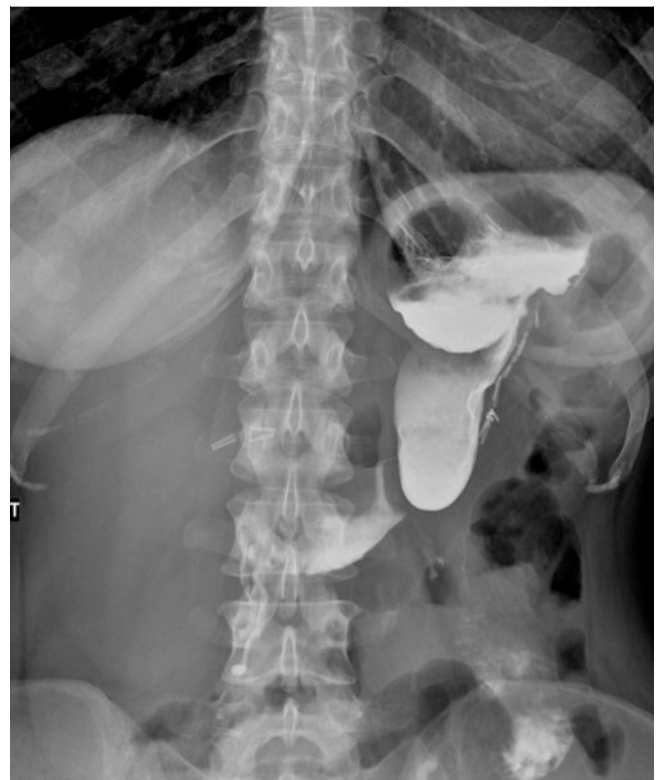After the intervention, patients were clinically followed up regularly at 1, 3, and 6 months and then annually (phone or consultations). The assessment included gastric outlet obstruction scoring system (GOOSS) calculation currently used for the evaluation of symptoms before and after treatment of mechanical gastric obstructions and a QoL assessment applying a classical numerical scale (NS) from 0 to 10 (0 = very poor QoL, 10 = very satisfactory QoL).

Results

Patient characteristics

Four patients aged 41 to 70 years (all female) underwent MG-POEM for the management of post-LSG twist with a median of 5.5 years [1, 2, 3, 4, 5, 6, 7, 8, 9, 10] after surgery.

The four patients included had been previously managed by endoscopic techniques, which did not improve their symptoms: one patient had one session, and another one had two sessions of dilatation with a 15-mm hydraulic balloon; two patients had benefited from pneumatic dilatation (diameter 30 mm). In two patients, the severe under-nutrition caused by the presence of the mid-gastric twist required the implementation of long-term parenteral nutrition (PN); these patients had not been able to be weaned from their artificial nutrition after the initial endoscopic treatment.



► **Fig. 3** Postoperative barium study showing the decreasing of the mid-gastric twist.

► **Table 1** Preoperative history, evaluation, and postoperative outcomes in four patients.

Patient number	Gender/age	Background	Date of LSG	Initial endoscopic treatment of twist post LSG	Preop GOOSS (/3)	Preop QoL scale (/10)	Adverse events	Length of post MG-POEM stay (days)	Follow-up (months)	Endoscopic revision	GOSS at last follow-up (/3)	QoL scale at last follow-up (/10)
1	F 70	Gastric banding 2009, NIDD	2014	1 session of dilatation with a hydraulic balloon (15 mm)	0 (PN)	2	0	3	17	Pneumatic dilatation x 2 for residual stenosis at M2 et M4	3	6
2	F 41	NIDD	2015	1 session of dilatation with a pneumatic balloon 30 mm	1	2	Collection in contact with the myotomy area (abdominal pain and fever) Antibiotics	10	16	0	3	6
3	F 51	Gastric banding 2004	2019	2 sessions of dilatation with a hydraulic balloon (15 mm)	0 (PN)	0	0	5	15	0	3	6
4	F 41	Fibromyalgia, functional colopathy	2010	1 session of dilatation with a pneumatic balloon 30 mm	3	3	0	3	14	Pneumatic dilatation x 1 of a residual stenosis at M5	3	8

QoL, quality-of-life; GOOSS, gastric outlet obstruction scoring system; NIDD, non-insulin-dependent diabetes; HH, hiatal hernia; PN, parenteral nutrition.

The median preoperative GOSS score was 1/3 (0–3) for all four patients and the median NS for QoL assessment was 1.75/10 (0–3).

Procedure and complications

MG-POEM was technically successful in all the patients without intraoperative adverse events in 92 +/- 25 minutes. One patient presented with immediate post-endoscopy complications with abdominal pain and fever associated with the appearance of a biological inflammatory syndrome related to a collection in contact with the myotomy area; the evolution was favorable after the administration of antibiotics for a total of 10 days. The average hospital stay was 5.25 days (3–10 days).

Efficacy

The median follow-up was 15.5 months [14, 15, 16, 17]. Clinical improvement occurred initially during the first months of follow-up in all the patients. Two patients experienced recurrence of mild symptoms with some vomiting and decrease in food intake. Early endoscopic and radiological control showed no more twist (► **Fig. 3**) but a trend toward stenosis induced by a post

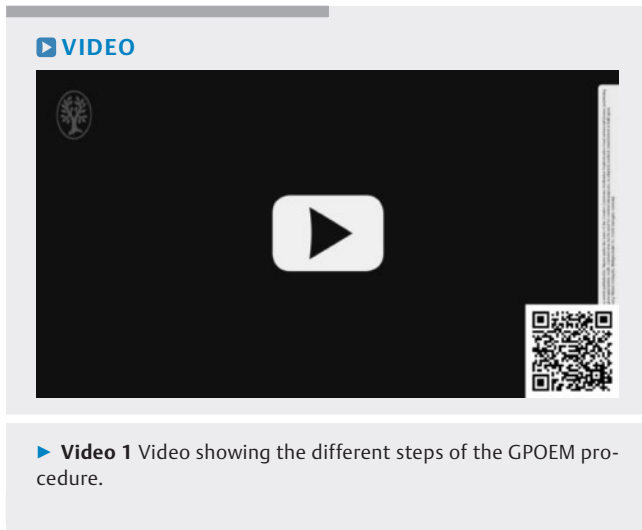MG-POEM scar. Pneumatic dilatation was performed successfully in those two patients (Rigiflex 35 mm) in one and two sessions. The two patients who had total PN were free of artificial nutrition at 2 months.

At the end of follow-up, the median GOOSS score was 3 and the mean QoL index was 6.5/10 [6, 7, 8]. The weight of all patients stabilized postoperatively.

All the outcomes and patient information are summarized in ► **Table 1**.

Discussion

Mid-gastric twist post LSG is a rare complication but may lead to refractory digestive symptoms, including in the long term under-nutrition, sometimes severe, and impairment of QoL. The most effective solution to date remains conversion to RYGB, which has no negligible rates of morbidity and mortality, particularly from a nutritional point of view, with the worsening of vitamin deficiencies in patients who have already lost weight following their first bariatric surgery.



POEM is an endoscopic technique in full expansion and the variation applied in this series seems to be an interesting therapeutic alternative for the management of post-LSG mid-gastric twists. In this short case series, the MG-POEM procedure demonstrated promising clinical results, although very preliminary. Indeed, the success rate in terms of dysphagia was good, with weight regain and substantial QoL improvement in all our patients. The side effects, which required antibiotic therapy and a longer hospital stay, did not require surgery.

However, the procedure is technically more complex than a regular POEM because of fibrosis, vascularization, and the twist itself, and requires a high level of skill in submucosal endoscopy and dissection. Consequently, this technique has to be performed in an expert center, and its indication validated by a multidisciplinary staff.

Moreover, in our series, in 50% of the patients, additional pneumatic dilatation sessions were necessary despite the disappearance of the medio-gastric twist post-LSG on the endoscopic controls. This is explained by the appearance of a scar inducing a post MG-POEM stenosis, which evolves favorably after one to two additional sessions of pneumatic dilatation, with good clinical results after more than 1 year of follow-up.

Conclusions

In conclusion, MG-POEM is promising and warrants future study prospectively in a larger population to establish a clear decision tree for a rare pathology for which the management is not clearly codified to date.

Conflict of Interest

JM Gonzalez and M Barthet are consultants for Boston Scientific, Pentax Medical and Fujifilm.

References

- [1] Brethauer SA, Hammel JP, Schauer PR. Systematic review of sleeve gastrectomy as staging and primary bariatric procedure. *Surg Obes Relat Dis* 2009; 5: 469–475 doi:10.1016/j.soard.2009.05.011
- [2] Rebibo L, Hakim S, Dhahri A et al. Gastric stenosis after laparoscopic sleeve gastrectomy: diagnosis and management. *Obes Surg* 2016; 26: 995–1001 doi:10.1007/s11695-015-1883-4
- [3] Parikh A, Alley JB, Peterson RM et al. Management options for symptomatic stenosis after laparoscopic vertical sleeve gastrectomy in the morbidly obese. *Surg Endosc* 2012; 26: 738–746 doi:10.1007/s00464-011-1945-1
- [4] Burgos AM, Csendes A, Braghetto I. Gastric stenosis after laparoscopic sleeve gastrectomy in morbidly obese patients. *Obes Surg* 2013; 1481–1486 doi:10.1007/s11695-013-0963-6
- [5] Al Sabah S, Al Haddad E. Endoscopic management of post-laparoscopic sleeve gastrectomy stenosis. *Surg Endosc* 2017; 3559–3563 doi:10.1007/s00464-016-5385-9
- [6] Deslauriers V, Beauchamp A, Garofalo F et al. Endoscopic management of post-laparoscopic sleeve gastrectomy stenosis. *Surg Endosc* 2018; 32: 601–609
- [7] Fayad L, Simsek C, Oleas R et al. Safety and efficacy of endoscopically secured fully covered self-expandable metallic stents (FCSEMS) for post-bariatric complex stenosis. *Obes Surg* 2019; 29: 3484–3492
- [8] Donatelli G, Dumont JL, Pourcher G et al. Pneumatic dilatation for functional helix stenosis after sleeve gastrectomy: long term follow up (with videos). *Surg Obes Relat Dis* 2017; 13: 943–950
- [9] Shnell M, Fishman S, Eldar S et al. Balloon dilatation for symptomatic gastric sleeve stricture. *Gastrointest Endosc* 2014; 79: 521–524
- [10] Lorenzo D, Gkolfakis P, Lemmers A et al. Endoscopic dilation of post-sleeve gastrectomy stenosis: long-term efficacy and safety results. *Obes Surg* 2021; 31: 2188–2196
- [11] Ogra R, Kini GP. Evolving endoscopic management options for symptomatic stenosis post laparoscopic sleeve gastrectomy for morbid obesity: Experience at a large bariatric surgery unit in New Zealand. *Obes Surg* 2015; 25: 242–248
- [12] Agnihotri A, Barola S, Hill C et al. An algorithmic approach to the management of gastric stenosis following laparoscopic sleeve gastrectomy. *Obes Surg* 2017; 27: 2628–2636 doi:10.1007/s11695-017-2689-3
- [13] Costa MN, Capela T, Seves I et al. Endoscopic treatment of early gastric obstruction after sleeve gastrectomy: report of two cases. *GE Port J Gastroenterol* 2015; 23: 46–49 doi:10.1016/j.jpge.2015.07.008
- [14] Lazzati A, Bechet S, Jouma S et al. Revision surgery after sleeve gastrectomy: a nationwide study with 10 years of follow-up. *Surg Obes Relat Dis* 2020; 16: 1497–1504
- [15] Acquafresca PA, Palermo M, Rogula T et al. Early surgical complications after gastric by-pass: a literature review. *Arq Bras Cir Dig* 2015; 28: 74–80 doi:10.1590/S0102-67202015000100019
- [16] Schlottmann F, Luckett DJ, Fine J et al. Laparoscopic Heller myotomy versus peroral endoscopic myotomy (POEM) for achalasia: A systematic review and meta-analysis. *Ann Surg* 2018; 267: 451–460 doi:10.1097/SLA.0000000000002311
- [17] Mohan BP, Chandan S, Jha LK et al. Clinical efficacy of gastric per-oral endoscopic myotomy (G-POEM) in the treatment of refractory gastroparesis and predictors of outcomes: a systematic review and meta-analysis using surgical pyloroplasty as a comparator group. *Surg Endosc* 2020; 34: 3352–3367 doi:10.1007/s00464-019-07135-9
- [18] Farha J, Fayad L, Kadhim A et al. Gastric per-oral endoscopic myotomy (G-POEM) for the treatment of gastric stenosis post-laparoscopic sleeve gastrectomy (LSG). *Obes Surg* 2019; 29: 2350–2354 doi:10.1007/s11695-019-03893-6

[19] Zhang LY, Canto MI, Schweitzer MA et al. Gastric per-oral endoscopic myotomy (G-POEM) for the treatment of gastric sleeve stenosis: a feasibility and safety study. *Endoscopy* 2022; 54: 376–381
doi:10.1055/a-1544-4923

[20] De Moura EGH, de Moura DTH, Sakai CM et al. Endoscopic tunneled stricturotomy with full-thickness dissection in the management of a sleeve gastrectomy stenosis. *Obes Surg* 2019; 29: 2711–2712
doi:10.1007/s11695-019-03919-z