

Device-assisted enteroscopy in the surveillance of intestinal hamartomas in Peutz-Jeghers syndrome



Authors

Omar Wahid Mohamed Elfeky¹, Suraj Panjwani², David Cave², Daniel Wild³, Daniel Raines⁴

Institutions

- 1 Internal Medicine, LSU Health New Orleans, New Orleans, United States
- 2 Gastroenterology, University of Massachusetts Chan Medical School Department of Medicine, Worcester, United States
- 3 Gastroenterology, Duke University Medical Center, Durham, United States
- 4 Gastroenterology, LSU Health New Orleans, New Orleans, United States

Key words

Small bowel endoscopy, Laparoscopy

received 6.4.2023

accepted after revision 24.10.2023

accepted manuscript online 27.11.2023

Bibliography

Endosc Int Open 2024; 12: E128–E134

DOI 10.1055/a-2197-8554

ISSN 2364-3722

© 2024. The Author(s).

This is an open access article published by Thieme under the terms of the Creative Commons Attribution-NonDerivative-NonCommercial License, permitting copying and reproduction so long as the original work is given appropriate credit. Contents may not be used for commercial purposes, or adapted, remixed, transformed or built upon. (<https://creativecommons.org/licenses/by-nc-nd/4.0/>)

Georg Thieme Verlag KG, Rüdigerstraße 14,
70469 Stuttgart, Germany

Corresponding author

Dr. Omar Wahid Mohamed Elfeky, LSU Health New Orleans,
Internal Medicine, 2000 Canal Street, 70112-2784 New
Orleans, United States
omar.elfeky10@gmail.com

ABSTRACT

Background and study aims Peutz-Jeghers syndrome (PJS) is an autosomal-dominant genetic disorder characterized by the formation of hamartomatous polyps in the gastrointestinal tract. These polyps result in significant morbidity due to adverse events (AEs) including intestinal obstruction, bleeding, and malignancy. The aim of this study was to describe the role of device-assisted enteroscopy (DAE) in monitoring and prophylactic polypectomy within the small bowel.

Patients and methods Electronic medical records were surveyed to identify all DAE procedures performed in patients with PJS at three US referral centers between January 1, 2007 and January 1, 2020. Individual charts were reviewed to collect and analyze specific data points. Primary end points included AEs associated with DAE-related polypectomy and the rate of laparotomy in PJS patients prior to, and following, index DAE. Secondary data points included patient characteristics, procedural details, and size/location/distribution of small bowel hamartomas.

Results Twenty-three patients met our inclusion criteria. Of these, 18 (75%) had previously undergone small bowel surgery prior to index DAE. Between 2007 and 2020, 46 DAEs were performed in these patients with an average of one exam every 2.5 years. A total of 131 polypectomies were performed with an AE rate of 1.5%. None of our cohort required emergent surgery related to AEs of small bowel hamartomas over 336 years of aggregated follow-up.

Conclusions Endoscopic management of small bowel polyps in patients with PJS using DAE is an effective strategy for prophylactic removal of hamartomas. DAE surveillance and endoscopic polypectomy is safe and may decrease the need for repeated laparotomy in patients with PJS.

Introduction

First described by Peutz in 1921 [1] and Jegher in 1949 [2], Peutz-Jeghers Syndrome (PJS) is an autosomal-dominant genetic disorder affecting 1 in 120,000 births [3]. It is characterized by the formation of hamartomatous polyps in the gastrointesti-

nal tract and mucocutaneous melanin pigmentation. When compared with the general population, patients with PJS carry a significantly increased risk for the development of malignancies, particularly of the breast and pancreas. This risk has been reported to be as high as 93% for developing any cancer by the age of 64 while the average lifetime risks of colorectal, gastric

and small-bowel cancer are 39%, 29%, and 13% respectively [3, 4].

A diagnosis of PJS is made by either: ≥ 2 confirmed PJS-type hamartomatous polyps; or any number of PJS-type polyps in a patient with characteristic mucocutaneous pigmentation or family history of PJS in a close relative; or characteristic mucocutaneous pigmentation combined with a family history of PJS in a close relative [5]. Histopathologically, PJS-associated hamartomas are characterized by interdigitating smooth muscle bundles in a characteristic arborizing “branching tree” or “christmas-tree” like appearance throughout their lamina propria and lobular organization of mucosal crypts [6]. PJS should also be considered in males with gynecomastia secondary to estrogen-producing Sertoli cell testicular tumors and in individuals with an unexplained history of intussusception as a child or young adult.

Intestinal hamartomas frequently cause intussusception or hemorrhage [7]. Management of these adverse events (AEs) typically requires repeated emergency surgery leading to sequela such as short gut and small-bowel obstruction from adhesions [2]. Given the prevalence of these AEs, surveillance and pre-emptive resection of intestinal hamartomas has been suggested as intervention to reduce morbidity and mortality in this patient population. In 1995, intraoperative enteroscopy (IOE) was widely accepted as the gold standard method to manage PJS patients based on the observation of the decrease in adverse events and a surveillance program published in the *British Journal of Surgery* in 1995 recommended IOE for removal of small-bowel polyps in patients with PJS [8].

However, data published to date is inadequate to promote guideline recommendations in favor of device-assisted enteroscopy (DAE) for prophylactic removal of hamartomas. Guidelines for surveillance of gastrointestinal hamartomas in PJS have been published and recommend evaluation by upper gastrointestinal endoscopy, colonoscopy, and video capsule endoscopy every 2 to 3 years after age 18 [3,9, 10].

The development of video capsule endoscopy (VCE) and DAE in 2001 revolutionized the diagnostic and therapeutic capabilities of endoscopy in the management of small-bowel pathology, including PJS [11]. With the progressive adoption of DAE, the deep small bowel can now be accessed for endoscopic polypectomy. Emergent surgery is commonly required in PJS patients for management of AEs associated with hamartomas. Forty-four percent of patients with PJS require laparotomy by the age 10 and 40% of patients who require an initial laparotomy require a repeat laparotomy within 5 years [12]. We hypothesized that DAE is effective and safe for small-bowel monitoring and prophylactic removal of small-bowel hamartomas in patients with PJS with a goal of reducing the incidence of emergent surgery related to small-bowel hamartomas.

Patients and methods

Study design

We conducted a retrospective study in three US high-volume referral centers for DAE: Louisiana State University Health Sciences Center, New Orleans, Louisiana, United States; Duke Uni-

versity Medical Center, Durham, North Carolina, United States, and University of Massachusetts Medical Center, Worcester, Massachusetts, United States. These sites care for a broad and diverse group of patients across a wide geographic section of the United States. The endoscopists who performed the DAEs were all highly experienced having each performed > 200 DAE exams. All of the participating centers obtained approval from their respective institutional review boards prior to study initiation. Using endoscopy reporting software as a database (Provation: Minneapolis-St. Paul, Minnesota, United States), we identified all adult patients who underwent DAE during the investigational period. We then conducted a medical record chart review to analyze data on all DAEs performed in patients with PJS. Double-balloon enteroscopy (DBE) was the most commonly utilized DAE technique. Using a REDCap (Research Electronic Data Capture) database, we recorded information related to the patient population and endpoints across the three centers. At the end of the study period, patients were contacted via telephone to obtain longitudinal data regarding any laparotomies or PJS related adverse events experienced after initial DAE.

Polypectomy

DAE was pursued with a goal of clearing the small bowel of all hamartomas > 10 mm in size. Polypectomy was commonly performed through endoscopic mucosal resection involving submucosal saline injection followed by hot snare resection, this technique was used to separate the stalk of the polyp from the intestinal wall to avoid bowel injury during polypectomy. The use of hemostatic clips and/or detachable snares were performed, and use was based upon physician preference and performed on a case-by-case basis. None of our patients experienced clinically significant bleeding after polypectomy. European Society of Gastrointestinal Endoscopy guidelines recommend elective polypectomy for small-bowel hamartomas starting at 15 mm [13]. However, our three centers independently arrived at the threshold of 10 mm for polypectomy. This was based upon previous studies in the literature using 10 mm as a minimum that showed a significant decrease in the need for polyp-related emergent surgery [14, 15, 16]. As hamartomas grow in size, the serosa invaginates into the stalk of the polyp resulting in increased risk of perforation during polypectomy. In addition, the risk of malignant potential associated with hamartomas correlates with a size > 10 mm [17].

Patient population and data points

Adult patients (aged > 18 years) with a clinical diagnosis of PJS who underwent DAE between January 2007 and January 2020 were included in this study whereas longitudinal data were collected until May 2022. Using the REDCap database, we recorded patient characteristics including age, gender, use of antithrombotics, previous history of DAE, and previous history of laparotomy; DAE characteristics including approach, technique, and procedure time; size, location, and number of endoscopically resected small-bowel hamartomas; and AEs. In our study, major AEs were defined as perforation, pancreatitis, excessive bleeding, and any AE requiring hospitalization or emergent surgery.

► **Table 1** Patient characteristics.

	All patients (N = 23)
Gender	
▪ Female	14
▪ Male	9
Antithrombotics	None
Manifestations of PJS	
▪ Mucocutaneous	6
▪ Hamartomas	23
▪ Other tumors/cancer	1
Laparotomy prior to enrollment %	75
PJS, Peutz-Jeghers syndrome.	

► **Table 2** DAE data.

	Total procedures (N = 46)
DAE	46
Anterograde	33
Retrograde	13
No. of polypectomies	131
Size of polypectomies (mm)	Median (IQR)
▪ Duodenum	12 (11–13)
▪ Jejunum	19 (15–25)
▪ Ileum	17 (15–20)
Adverse events	2
Average time to follow up in years	2.5
Number of surgeries after enrollment	2
DAE, device-assisted enteroscopy; IQR, interquartile range.	

Results

Patients

Twenty-three patients met inclusion criteria across the three centers: LSU New Orleans (n = 10), UMass (n = 10), and Duke (n = 3) between 2007 and 2020. Patient ages ranged from 15 to 59 with a mean age of 32 at index surveillance DAE. The majority of subjects (63%) were female. None of the patients had undergone DAE prior to the study period. Prior to index surveillance DAE, all patients had a clinical diagnosis of PJS and all had undergone VCE and/or cross-sectional imaging with computed tomography or magnetic resonance imaging confirming the presence of small-bowel polyps. The average interval between index surveillance DAE and repeat surveillance DAE was 2.5 years. Patient characteristics are shown in ► **Table 1**.

DAE data points

A total of 46 DAE exams were performed, 33 by an anterograde (oral) and 13 by a retrograde (rectal) approach. The preferred initial route was anterograde enteroscopy after review of imaging as the burden of hamartomas was more prevalent in the proximal small bowel in our patient population. Retrograde DAE was not necessary in cases in which anterograde DAE was successful in examining the entire small bowel (total enteroscopy). Anterograde and retrograde procedures were performed on separate days due to length of each procedure time. Endoscopic polypectomy was performed in 87% of these exams with a goal of removing all hamartomas > 10 mm. All 23 patients were observed to have gastric polyps that were not removed. Of the 13 retrograde enteroscopies, four patients had < 10-mm polyps removed that were confirmed as adenomatous by histology. The average number of polypectomies performed per procedure was 2.85. The average size of resected hamartomas was 15.2 mm with a mean polyp size of 18.4 mm in the jejunum (median, interquartile range [IQR] 19, range 15–25), 15.7 mm in the ileum (median, IQR 17, range 15–20), and 10.9 mm in the duodenum (median, IQR 12, range 11–13). Ad-

ditional information regarding data points for all 23 patients is shown in ► **Table 2**. Data from all our patients are shown in ► **Table 3**.

Adverse events

Two AEs occurred in 131 small-bowel polypectomies. One perforation occurred following removal of a 10-mm hamartoma with a thin stalk (3 mm) using hot snare without saline-lift. We theorized that lack of a cushion of fluid to absorb the electrical current was a risk factor for transmural injury in this case. A second patient developed post-polypectomy (serositis) syndrome which led to a 48-hour hospitalization for observation. No additional AEs were discovered by electronic medical record review of all patients or follow-up phone interview of 17 patients.

Rate of laparotomy

Eighteen patients (75%) had undergone one or more emergent laparotomies for small-bowel hamartomas prior to index surveillance DAE. The incidence of these surgeries was fairly consistent after age 5 (► **Fig. 1**).

Following index surveillance DAE, only one emergent laparotomy was required across 366 years of combined patient follow-up. This patient required emergent surgery for perforation as an AE of hot snare resection of a jejunal hamartoma as described above. She recovered from this surgery and was discharged 4 days after admission. A second patient required elective laparotomy for removal of a large hamartoma which could not be reached by DAE. No additional laparotomies were found upon follow-up interview and medical record review for all patients.

► **Table 3** Cohort surveillance data.

Patient	Gender	Polypectomies	Polyp location	Complications	Observation time (years)
1	Male	4	D, J	None	16
2	Female	6	J	Serositis	16
3	Male	3	J	None	9
4	Female	12	D, J	None	16
5	Female	4	I	Perforation	16
6	Female	4	J	None	16
7	Female	3	I	None	14
8	Female	14	J, I	None	16
9	Male	7	J	None	16
10	Male	2	I	None	10
11	Female	12	D, J, I	None	16
12	Male	8	J	None	15
13	Female	3	J	None	16
14	Female	3	J, I	None	7
15	Female	11	D, J	None	16
16	Female	7	J	None	16
17	Female	5	J	None	16
18	Male	6	D, J	None	13
19	Female	3	D, J	None	16
20	Female	4	I	None	16
21	Male	5	J	None	16
22	Male	2	J	None	12
23	Male	3	J	None	16

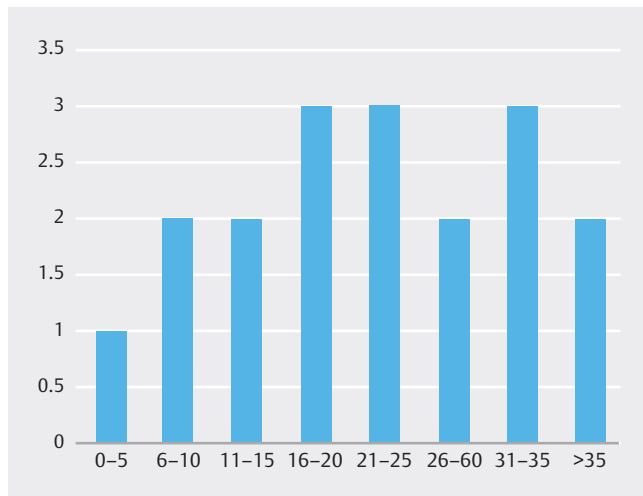
D, duodenum; J, jejunum; I, ileum.

Discussion

Our study suggests that DAE is safe and effective in removing hamartomas from the small bowel to prevent future AEs and need for emergent laparotomy. Historical data have shown that patients with PJS commonly require repeated emergent surgery related to intestinal hamartomas. In one study, 68% of patients with PJS had undergone an emergent laparotomy for intussusception related to small-bowel hamartomas by age 18 years and the majority of these patients required a second laparotomy within 5 years of initial surgery. In 20 patients interviewed between 1943 and 1987 at St. Mark's Hospital in London, 12 had repeat laparotomies within 10 years of their first surgery and four of those occurred the first year. In a cohort study including 110 PJS patients, 69% developed at least one intussusception leading to surgery at a median age of 16 years [18, 19].

If surgery is required, elective surgery is preferred over emergent surgery. Historical data have shown that 70% of laparotomies performed for intestinal hamartomas are emergency interventions [5]. IOE has been studied to perform a “clean sweep” of all significant hamartomas from the small bowel and has been demonstrated to reduce the need for future surgery [20, 21]. The data from studies of IOE for PJS support the benefit of regular surveillance, in that no patients on the surveillance program developed polyp-related AEs requiring emergency surgery. In 1995, IOE was accepted as a standard method to manage intestinal hamartomas in patients with PJS [8].

The medical literature contains 19 previous studies describing experiences with DAE for endoscopic removal of small-bowel hamartomas [15, 16, 22, 23, 24, 25, 26, 27, 28, 29, 30, 31, 32, 33, 34, 35, 36, 37, 38]. These articles vary significantly in regard to number of patients, geographic location, and observation period. Belsha et al. followed a pediatric population in the United States of 16 patients and demonstrated that DBE-facilitated



► **Fig. 1** Incidence of surgeries in cohort by age.

polypectomy is an effective therapeutic option in pediatric patients with PJS over 26 months [16]. The safety of DAE in prophylactic removal of hamartomas by DAE was described in 16 patients in Germany followed by two patients in Japan [22, 23, 24]. Gao et al. examined 13 patients over 356 combined patient months to conclude that DBE is clinically useful and safe for diagnosis and therapy of small-bowel polyps in patients with PJS and it may decrease the need for laparotomy [25]. These results were replicated by Akarsu et al (7 patients), Gorospe et al (22 patients), Bizzari et al (10 patients), Torroni et al (6 patients) and Kroner et al (12 patients) and Blanco-Velasso (4 patients) [26, 27, 28, 29, 30, 31, 32]. Kopacova et al. also compared the efficacy of IOE with DAE in their cohort of PJS patients in 2010 to demonstrate DAE to be as efficacious as IOE in the removal of polyps and less morbid [33]. These studies attest to the capability and safety of DAE in removal of intestinal hamartomas but most of these lack longer-term follow up with repeated

DAE examinations at scheduled intervals as evaluated in our study.

Of the 19 studies referenced above, six studies evaluated the use of DAE in an adult PJS population and recorded surgical data similar to our study [13, 28, 34, 35, 36, 37]. The findings of these studies are summarized in ► **Table 4**. Wang et al [35] reported a significant decrease in size of hamartomas removed by DAE over an approximately 19-month average follow-up period. Mean polyp size on follow-up anterograde DAE decreased from 36 mm to 21 mm while mean polyp size on retrograde DAE decreased from 3 mm to 1.2 mm. Following this report, Perrod et al. [36] published a retrospective study of PJS patients registered in the Predisposition Digestive Ile-de-France network. This study showed that DAE was successful in clearing all polyps > 10 mm in the majority (76%) of patients with PJS. More recently, a retrospective observational study published by Valdivia describes an Italian experience with DAE in 23 PJS patients, of whom 22 were followed over an extended time frame (mean follow up of 9 years). Only 9% of these patients required emergent surgery for AEs from small-bowel hamartomas after index surveillance DAE compared with 27% prior to index surveillance DAE. In all studies, there was a significant improvement in the rate of surgery after initiation of small-bowel surveillance (► **Table 4**).

Our study provides similar data over an extended follow-up period with a diverse population across the United States, thus building upon previous studies. We recognize that our study also has limitations. The total number of subjects was small, which is expected for such a rare disease. A retrospective design did not allow for prospective data collection. The surveillance protocol utilized across the three study sites was similar but not as uniform as would be found in a prospective trial with standardized management.

► **Table 4** Data published on efficacy of DAE and rate of surgery.

References	No. patients	Observation time	DAE interval (years)	Procedure complication rate	Pre-enrollment surgery	Surgeries post-enrollment (during study period)
Wang et al.	97	46.7 (median)	2.5, 1.5	4.40%	57%	0
Perrod et al.	25	60 (median)	VCE or MRE 2–3	6%	64%	8%
Sakamoto et al.	15	29.9 (mean)	Yearly	6.80%	86.70%	6%
Chen et al.	6	32 (mean)	1.66 ± 4 years AND 6–12 mo small-bowel series	0%	50%	0
Serrano et al.	25	56.5 (median)	NA	2.50%	74%	0
Valdivia et al.	24	108 (median)	NA	8.50%	66.7	9.10%

Summary of the data from studies published examining the efficacy of DAE on rate of surgeries pre and post enrollment in study. We note the number of patients, study time, interval DAE if applicable, procedure complication rate as well as pre- and post-enrollment rate of surgery. DAE, device-assisted enteroscopy.

Conclusions

Our study shows that patients with PJS can be safely and effectively surveilled for small-bowel hamartomas using DAE. This intervention should result in fewer laparotomies, particularly emergent laparotomies, compared with historical management. We observed a decrease in the rate of laparotomy from 75% to 8% over our study period after index surveillance DAE with a mean surveillance interval of 2.5 years. We propose that patients with PJS who have confirmed small-bowel hamartomas be surveilled in capable centers by using DAE every 2 to 3 years, starting at the age of 18, to remove all hamartomas \geq 10 mm. Removal of hamartomas using saline-lift combined with hot snare is recommended as the single perforation observed in 131 polypectomies was observed in the setting of hot snare resection alone.

Conflict of Interest

Daniel Raines, MD Consultant: Fujifilm Speaker: Medtronic. All other authors declare that they have no conflicts of interest.

References

- [1] Peutz JLA. Appendix: Peutz's original report on Peutz-Jeghers syndrome. In: Riegert-Johnson D, Boardman L, Hefferon T (eds.) *Cancer Syndromes*. et al. 2009; 10: 134–146
- [2] Jeghers H, Katz K. Generalized intestinal polyposis and melanin spots of the oral mucosa, lip and digits: a syndrome of diagnostic significance. *N Engl J Med* 1949; 241: 1031–1036 doi:10.1056/NEJM194912222412501
- [3] Giardiello F, Bersinger J, Tersmette A et al. Very high risk of cancer in familial Peutz-Jeghers syndrome. *Gastroenterology* 2000; 119: 1447–1453
- [4] Bessette J, Maglente D, Kelvin F et al. Primary malignant tumors in the small bowel: a comparison of the small-bowel enema and conventional follow-through examination. *AJR Am J Roentgenol* 1989; 153: 741–744 doi:10.2214/ajr.153.4.741
- [5] Hinds R, Philp C, Hyer W et al. Complications of childhood Peutz-Jeghers syndrome: implications for pediatric screening. *J Pediatr Gastroenterol Nutr* 2004; 39: 219–220 doi:10.1097/00005176-200408000-00027
- [6] Ylikorkala A, Avizienyte E, Tomlinson I et al. Mutations and impaired function of LKB1 in familial and non-familial Peutz-Jeghers syndrome and a sporadic testicular cancer. *Hum Mol Genet* 1999; 8: 45–51 doi:10.1093/hmg/8.1.45
- [7] Cunningham J, Vine A, Karch L et al. The role of laparoscopy in the management of intussusception in the Peutz-Jeghers syndrome: case report and review of the literature. *Surg Laparosc Endosc* 1998; 8: 17–20
- [8] Wirtzfeld D, Petrelli N, Rodriguez-Bigas M. Hamartomatous polyposis syndromes: molecular genetics, neoplastic risk, and surveillance recommendations. *Ann Surg Oncol* 2001; 8: 319–27 doi:10.1007/s10434-001-0319-7
- [9] McGrath DR, Spigelman AD. Preventive measures in Peutz-Jeghers syndrome. *Fam Cancer* 2001; 1: 121–125 doi:10.1023/a:1013896813918
- [10] Tomlinson I, Houlston R. Peutz-Jeghers syndrome. *J Med Genet* 1997; 34: 1007–1011 doi:10.1136/jmg.34.12.1007
- [11] Parsi M, Burke C. Utility of capsule endoscopy in Peutz-Jeghers syndrome. *Gastrointest Endosc Clin N Am* 2004; 14: 159–167 doi:10.1016/j.giec.2003.10.012
- [12] van Lier M, Mathus-Vliegen E, Wagner A et al. High cumulative risk of intussusception in patients with Peutz-Jeghers syndrome: time to update surveillance guidelines? *Am J Gastroenterol* 2011; 106: 940–945
- [13] van Leerdam M, Roos V, van Hooft J et al. Endoscopic management of Lynch syndrome and of familial risk of colorectal cancer: European Society of Gastrointestinal Endoscopy (ESGE) Guideline. *Endoscopy* 2019; 51: 1082–1093 doi:10.1055/a-1016-4977
- [14] Latchford A, Neale K, Phillips R et al. Peutz-Jeghers syndrome: intriguing suggestion of gastrointestinal cancer prevention from surveillance. *Dis Colon Rectum* 2011; 54: 1547–1551
- [15] Chen T, Lin W, Su M et al. Balloon-assisted enteroscopy with prophylactic polypectomy for Peutz-Jeghers syndrome: experience in Taiwan. *Dig Dis Sci* 2011; 56: 1472–1475
- [16] Belsha D, Urs A, Attard T et al. Effectiveness of double-balloon enteroscopy-facilitated polypectomy in pediatric patients with Peutz-Jeghers syndrome. *J Pediatr Gastroenterol Nutr* 2017; 65: 500–502
- [17] Stryker S, Wolff B, Culp C et al. Natural history of untreated colonic polyps. *Gastroenterology* 1987; 93: 1009–1013 doi:10.1016/0016-5085(87)90563-4
- [18] McGarrity T, Amos C, Baker M. Peutz-Jeghers Syndrome. In: Adam MP, Mirzaa GM, Pagon RA (eds.) *GeneReviews* [Internet]. 2001: et al. Seattle (WA): University of Washington, Seattle;
- [19] Spigelman A, Thomson J, Phillips R. Towards decreasing the relaparotomy rate in the Peutz-Jeghers syndrome: the role of preoperative small bowel endoscopy. *Br J Surg* 1990; 77: 301–302 doi:10.1002/bjs.1800770320
- [20] Edwards D, Khosraviani K, Stafferton R et al. Long-term results of polyp clearance by intraoperative enteroscopy in the Peutz-Jeghers syndrome. *Dis Colon Rectum* 2003; 46: 48–50 doi:10.1007/s10350-004-6495-3
- [21] Oncel M, Remzi F, Church J et al. Benefits of 'clean sweep' in Peutz-Jeghers patients. *Colorectal Dis* 2004; 6: 332–335 doi:10.1111/j.1463-1318.2004.00623.x
- [22] Ohmiya N, Taguchi A, Shirai K et al. Endoscopic resection of Peutz-Jeghers polyps throughout the small intestine at double-balloon enteroscopy without laparotomy. *Gastrointest Endosc* 2005; 61: 140–147
- [23] Plum N, May A, Manner H et al. Peutz-Jeghers syndrome: endoscopic detection and treatment of small bowel polyps by double-balloon enteroscopy. *Z Gastroenterol* 2007; 45: 1049–1055 doi:10.1055/s-2007-963345
- [24] Ohmiya N, Nakamura M, Takenaka H et al. Management of small-bowel polyps in Peutz-Jeghers syndrome by using enteroclysis, double-balloon enteroscopy, and videocapsule endoscopy. *Gastrointest Endosc* 2010; 72: 1209–1216
- [25] Gao H, van Lier M, Poley J et al. Endoscopic therapy of small-bowel polyps by double-balloon enteroscopy in patients with Peutz-Jeghers syndrome. *Gastrointest Endosc* 2010; 71: 768–773
- [26] Akarsu M, Uğur Kantar F, Akpınar H. Double-balloon endoscopy in patients with Peutz-Jeghers syndrome. *Turk J Gastroenterol* 2012; 23: 496–502 doi:10.4318/tjg.2012.0356
- [27] Gorospe E, Alexander J, Bruining D et al. Performance of double-balloon enteroscopy for the management of small bowel polyps in hamartomatous polyposis syndromes. *J Gastroenterol Hepatol* 2013; 28: 268–273 doi:10.1111/jgh.12058
- [28] Serrano M, Mão-de-Ferro S, Pinho R et al. Double-balloon enteroscopy in the management of patients with Peutz-Jeghers syndrome: a retrospective cohort multicenter study. *Rev Esp Enferm Dig* 2013; 105: 594–599

- [29] Bizzarri B, Borrelli O, de'Angelis N et al. Management of duodenal-jejunal polyps in children with peutz-jeghers syndrome with single-balloon enteroscopy. *J Pediatr Gastroenterol Nutr* 2014; 59: 49–53
- [30] Torroni F, Romeo E, Rea F et al. Conservative approach in Peutz-Jeghers syndrome: Single-balloon enteroscopy and small bowel polypectomy. *World J Gastrointest Endosc* 2014; 6: 318–323 doi:10.4253/wjge.v6.i7.318
- [31] Kröner P, Sancar A, Fry L et al. Endoscopic mucosal resection of jejunal polyps using double-balloon enteroscopy. *GE Port J Gastroenterol* 2015; 22: 137–142 doi:10.1016/j.jpge.2015.04.005
- [32] Blanco-Velasco G, Hernández-Mondragón O, Blancas-Valencia J et al. Safety and efficacy of small bowel polypectomy using a balloon-assisted enteroscope in pediatric patients with Peutz-Jeghers syndrome. *Rev Gastroenterol Mex (Engl Ed)* 2018; 83: 234–237
- [33] Kopáčová M, Bures J, Ferko A et al. Comparison of intraoperative enteroscopy and double-balloon enteroscopy for the diagnosis and treatment of Peutz-Jeghers syndrome. *Surg Endosc* 2010; 24: 1904–1910 doi:10.1007/s00464-009-0868-6
- [34] Sakamoto H, Yamamoto H, Hayashi Y et al. Nonsurgical management of small-bowel polyps in Peutz-Jeghers syndrome with extensive polypectomy by using double-balloon endoscopy. *Gastrointest Endosc* 2011; 74: 328–333
- [35] Wang Y, Bian J, Zhu H et al. The role of double-balloon enteroscopy in reducing the maximum size of polyps in patients with Peutz-Jeghers syndrome: 12-year experience. *J Dig Dis* 2019; 20: 415–420
- [36] Perrod G, Samaha E, Perez-Cuadrado-Robles E et al. Small bowel polyp resection using device-assisted enteroscopy in Peutz-Jeghers Syndrome: Results of a specialised tertiary care centre. *United European Gastroenterol J* 2020; 8: 204–210 doi:10.1177/2050640619874525
- [37] Cortegoso Valdivia P, Rondonotti E, Pennazio M. Safety and efficacy of an enteroscopy-based approach in reducing the polyp burden in patients with Peutz-Jeghers syndrome: experience from a tertiary referral center. *Ther Adv Gastrointest Endosc* 2020; 13: 2631774520919369 doi:10.1177/2631774520919369
- [38] Kirakosyan E, Lokhmatov M. High-tech diagnostic methods and enteroscopic treatment of children with Peutz-Jeghers syndrome. *Eur J Pediatr Surg* 2020; 30: 529–535 doi:10.1055/s-0039-3400286