

Successful removal of a fractured pancreatic stent using a novel thin-tapered drill dilator ▶



Introduction

Endoscopic pancreatic stenting is performed to prevent main pancreatic duct obstruction and relieve painful symptoms of chronic pancreatitis.

In some cases, it is quite challenging to remove pancreatic stents using devices such as forceps, balloons, and snares.

We herein report a case in which a fractured pancreatic stent was successfully retrieved using a novel thin-tapered drill dilator after failed removal using various other devices.

A 51-year-old man with chronic pancreatitis was admitted for exchange of an obstructed 10F pancreatic stent. We were unable to negotiate a guidewire through or beside the stent. We used a snare to remove the stent; however, the stent did not move and eventually fractured. The fractured pancreatic stent could not be removed using forceps, a Soehendra stent retriever or a 3 mm-wide thin-tipped balloon catheter.

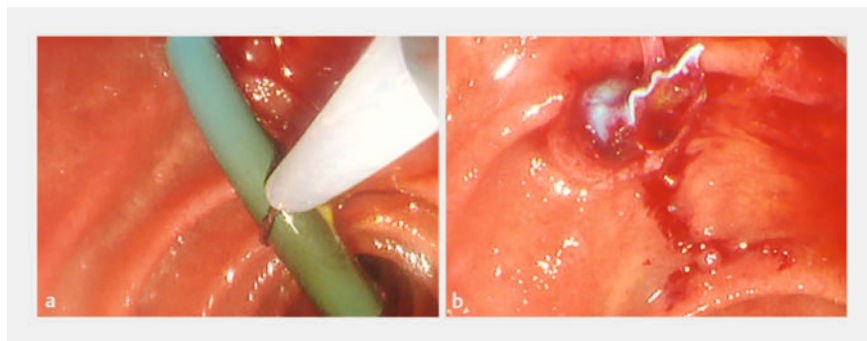
The stent was completely obstructed, and we were unable to pass the guidewire over the stent. We inserted a novel tapered drill dilator inside the stent and twisted the dilator.

The stent clung to the dilator and was successfully retrieved with no adverse events. Finally, we inserted a new pancreatic stent.

Conclusion

The technique described here using this thin-tapered drill dilator might be a useful option for removing a pancreatic stent.

Endoscopic pancreatic stenting is performed to prevent main pancreatic duct obstruction and relieve painful symptoms of chronic pancreatitis [1,2,3]. In some cases, it is quite challenging to remove pancreatic stents using devices such as forceps, balloons, and snares. We report a case in which a fractured pancreatic stent was successfully re-



▶ **Fig. 1** Attempt to remove a pancreatic stent. **a** Failure to remove the stent using a snare. **b** The fractured pancreatic stent.

trieved using a novel thin-tapered drill dilator after failed attempts at removal using various other devices.

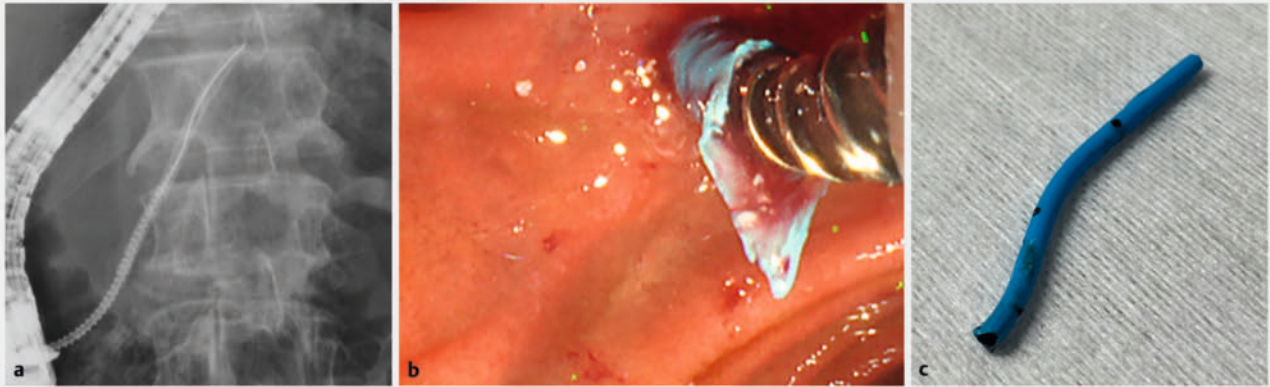
A 51-year-old man with chronic pancreatitis was admitted for exchange of an obstructed 10F pancreatic stent. We were unable to negotiate a guidewire through or beside the stent. We used a snare to remove the stent; however, the stent did not move and eventually fractured (▶ **Fig. 1**). The fractured pancreatic stent could not be removed using forceps, a

Soehendra stent retriever (Cook Medical Inc., Bloomington, Indiana, United States), or a 3-mm-wide thin-tipped balloon catheter (REN Biliary Balloon Dilation Catheter; Kaneka Corporation, Osaka, Japan) [4]. The stent was completely obstructed, and we were unable to pass the guidewire over it. Therefore, we inserted a novel tapered drill dilator (Tornus ES; Asahi Intecc, Aichi, Japan) into the stent and twisted the dilator. The stent clung to the dilator and was suc-

▶ **VIDEO**

▶ **Video 1** Successful removal of a fractured pancreatic stent using a novel thin-tapered drill dilator.

We inserted a novel tapered drill dilator inside the stent and twisted the dilator. The stent clung to the dilator and was successfully retrieved with no adverse events.



► **Fig. 2** Successful removal of the fractured pancreatic stent. **a** We inserted a novel tapered drill dilator (Tornus ES; Asahi Intecc, Aichi, Japan) into the stent and twisted the dilator. **b** The stent clung to the dilator and was successfully retrieved with no adverse events. **c** The retrieved fractured pancreatic stent.



► **Fig. 3** Image of the drill dilator. The tip of the dilator was gently tapered with a drill shape adapted to a 0.018- or 0.025-inch guidewire.

cessfully retrieved with no adverse events (► **Fig. 2**, ► **Video 1**). Finally, we inserted a new pancreatic stent. This novel drill dilator was developed to facilitate endoscopic ultrasound-guided interventions (► **Fig. 3**) [5]. Because the device does not require strong pressing, excessive pressure against target organs can be avoided. In the present case, we completed the procedure without damaging the pancreas or inducing upstream migration of the pancreatic stent toward the main pancreatic duct. Furthermore, the dilator is thin-tapered and easy to insert. The technique described here using this thin-tapered drill dilator might be a useful option for removing a pancreatic stent.

Conflict of Interest

The authors declare that they have no conflict of interest.

The authors

Yasuki Hori¹, **Akihisa Kato**¹, **Kenta Kachi**¹, **Yuka Ichino**¹, **Itaru Naitoh**¹, **Michihiro Yoshida**¹, **Hiromi Kataoka**¹

¹ Department of Gastroenterology and Metabolism, Nagoya City University Graduate School of Medical Sciences and Medical School, Nagoya, Japan

Corresponding author

Dr. Yasuki Hori

Nagoya City University Graduate School of Medical Sciences and Medical School, Department of Gastroenterology and Metabolism, Nagoya, Japan
yhori@med.nagoya-cu.ac.jp

Funding

The Hori Sciences and Arts foundation-JOSE205003

References

- [1] Hori Y, Vege SS, Chari ST et al. Classic chronic pancreatitis is associated with prior acute pancreatitis in only 50% of patients in a large single-institution study. *Pancreatology* 2019; 19: 1078–1079

- [2] Binmoeller KF, Jue P, Seifert H et al. Endoscopic pancreatic stent drainage in chronic pancreatitis and a dominant stricture: long-term results. *Endoscopy* 1995; 27: 638–644 doi:10.1055/s-2007-10057808903975
- [3] Hori Y, Ichino Y, Naitoh I et al. Impact of physiologically shaped pancreatic stent for chronic pancreatitis. *Sci Rep* 2021; 11: 8285 doi:10.1038/s41598-021-87852-133859301
- [4] Inoue T, Ishii N, Kobayashi Y et al. Successful retrieval of an immovable pancreatic stent using a novel thin-tipped balloon catheter. *Endoscopy* 2017; 49: E157–E159 doi:10.1055/s-0043-10673428464203
- [5] Okuno N, Hara K, Haba S et al. Novel drill dilator facilitates endoscopic ultrasound-guided hepaticogastrostomy. *Dig Endosc* 2023; 35: 389–393 doi:10.1111/den.1444736170547

Bibliography

Endosc Int Open 2023; : –
DOI 10.1055/a-2197-3820
ISSN 2364-3722

© 2023. The Author(s).

This is an open access article published by Thieme under the terms of the Creative Commons Attribution-NonDerivative-NonCommercial License, permitting copying and reproduction so long as the original work is given appropriate credit. Contents may not be used for commercial purposes, or adapted, remixed, transformed or built upon. (<https://creativecommons.org/licenses/by-nc-nd/4.0/>)
Georg Thieme Verlag KG, Rüdigerstraße 14, 70469 Stuttgart, Germany

