

Cold snare resection for non-ampullary sporadic duodenal adenomas: systematic review and meta-analysis



Authors

Mihai Ciocirlan¹, Diana Lavinia Opri¹, Dana Maria Bilous¹, Daniel-Corneliu Leucuta², Elena Tianu³, Catalina Vladut¹

Institutions

- 1 "Agrippa Ionescu" Clinical Emergency Hospital, "Carol Davila" University of Medicine and Pharmacy, Bucharest, Romania
- 2 Medical Informatics and Biostatistics, Iuliu Haiegedanu University of Medicine and Pharmacy, Cluj-Napoca, Romania
- 3 Pathology Department, "Agrippa Ionescu" Clinical Emergency Hospital, Bucharest, Romania

ciocirlan@gmail.com

ciocirlan@hey.com

Additional material is available at <https://doi.org/10.1055/a-2185-6192>

Key words

Neoplasia, Endoscopy Small Bowel, Small intestinal bleeding, Endoscopy Upper GI Tract

received 26.4.2023

accepted after revision 27.9.2023

accepted manuscript online 4.10.2023

Bibliography

Endosc Int Open 2023; 11: E1020–E1025

DOI 10.1055/a-2185-6192

ISSN 2364-3722

© 2023. The Author(s).

This is an open access article published by Thieme under the terms of the Creative Commons Attribution-NonDerivative-NonCommercial License, permitting copying and reproduction so long as the original work is given appropriate credit. Contents may not be used for commercial purposes, or adapted, remixed, transformed or built upon. (<https://creativecommons.org/licenses/by-nc-nd/4.0/>)

Georg Thieme Verlag KG, Rüdigerstraße 14,
70469 Stuttgart, Germany

Corresponding author

Dr. Mihai Ciocirlan, "Carol Davila" University of Medicine and Pharmacy, "Agrippa Ionescu" Clinical Emergency Hospital, 7 Ion Mincu St., 011356 Bucharest, Romania

ABSTRACT

Background and study aims The role of cold snare polypectomy (CSP) in curative resection of non-ampullary sporadic duodenal adenomas (NASDA) is debated. We conducted a systematic review and meta-analysis to investigate the efficacy and safety of CSP for NASDA.

Patients and methods In this systematic review and meta-analysis, we identified published series of patients with CSP for NASDA by searching PubMed and Google Scholar, which resulted in six papers (205 lesions). The main outcome was the rate of local remission after repeated CSP, the secondary outcomes were rates of local remission at first control and rates for delayed bleeding and immediate perforations. We computed the weighted summary proportions under the fixed and random effects model.

Results The pooled proportion of local remission after repeated CSP was 88% (95% confidence interval [CI] 57%–100%). The pooled proportion of local remission at first control was 81% (95% CI 55%–98%), the pooled proportion of delayed bleeding was 1% (95% CI 0%–4%) and the pooled proportion of immediate perforation was 0% (95% CI 0%–2%).

Conclusions Our meta-analysis suggests that CSP should be considered as the first-line therapy for NASDA.

Introduction

Duodenal adenomas are rare, counting for 7% of duodenal polyps. They may appear in familial adenomatous polyposis syndrome (FAP) or may be sporadic [1, 2].

Sporadic duodenal adenomas can be ampullary and non-ampullary. When referring to non-ampullary sporadic duodenal

adenomas (NASDA), these are usually found in the second part of the duodenum and may be tubular or villous [3].

Risk factors for NASDA include smoking, Barrett's esophagus, synchronous gastric glandular polyps, and history of malignancy [4].

Duodenal adenomas have a higher risk of progression to adenocarcinoma than colonic adenomas, especially the ampul-

lary and the villous ones [4, 5]. Excision with curative intent is recommended. Surgery is reserved for adenomas with areas of suspected deep carcinomatous infiltration. Less invasive lesions may be resected endoscopically. Endoscopic excision in the duodenum represents a challenge due to certain anatomic characteristics: a narrow lumen, a “C-loop” shape that makes it difficult to maintain scope position, Brunner’s glands which stiffen the wall, making lifting difficult, a thin muscular layer with high perforation risk, an increased bleeding risk due to the vascularization through the gastroduodenal artery, and challenging access for surgery [5, 6]. The European Society for Gastrointestinal Endoscopy (ESGE) 2021 guideline for the management of superficial non-ampullary duodenal tumors recommends cold-snare polypectomy (CSP) for lesions < 6 mm and endoscopic mucosal resection (EMR) for larger lesions [4]. The 2022 ESGE guideline on endoscopic submucosal dissection for superficial gastrointestinal lesions does not recommend its use for duodenal lesions, but only for expert centers [7].

We performed a systematic review and meta-analysis of all reported series of NASDA treated by CSP with the aim to assess the procedure outcomes. The main outcome was the rate of local remission after repeated resections, the secondary outcomes were rates of local remission after first control and rates for delayed bleeding and immediate perforations.

Patients and methods

We identified all existing published series of patients treated with CSP for NASDA until the present by searching PubMed and Google Scholar databases, including gray literature [8]. The search terms were “duodenal adenoma” and “cold snare.” Two reviewers independently assessed each result and excluded FAP-related adenomas, ampullary adenomas, and duplicate publications. Egger’s test and Begg’s test were performed to estimate publication bias, with a *P* value of 0.05 as a cut-off for significance. Collected data were expressed as absolute values and/or percentages. Continuous variables were expressed as median and range values.

All meta-analyses were carried out in R environment for statistical computing and graphics (R Foundation for Statistical Computing, Vienna, Austria), version 4.3.1 [9], with the help of the meta-R package. The summary measure was the proportion on which an arcsine transformation was used, and the inverse variance method was used for pooling the studies. A random effects meta-analysis was performed for each outcome, assuming clinical heterogeneity between the studies. The heterogeneity of the studies was assessed with I^2 and the *Q* tests. In case of important heterogeneity, a leave-one-out sensitivity analysis was performed, and influence studies were identified through statistical methods. The pooled estimates were presented along with their 95% confidence interval and *P* value. The prediction interval was computed for each outcome.

Results

Six series have been published on endoscopic therapy of non-ampullary sporadic adenomas, five of them in the last 2 years [10, 11, 12, 13, 14, 15]. A seventh series had overlapping patients with an already included one and it was excluded [16]. Three series were retrospective and three were prospective. Two series compared CSP with EMR-resected lesions, either from historical separate cohorts [12] or within the same time frame, but without random allocation [15]. There was no publication bias (**Supplementary file**).

The characteristics of the lesions are presented in ► **Table 1**. There were 197 patients with 205 NASDA; in three studies, some patients had multiple lesions [12, 13, 15]. Most lesions were in the second duodenum, their sizes ranging from 2 to 70 mm.

The results of the CSP series are presented in ► **Table 2**. One series did not report remission rates [10]. In two series, patients were partially lost to follow-up, hence remission was reported only for followed-up lesions [12, 15].

Local remission after repeated CSP

The pooled proportion of local remission after repeated CSP was 88% (95% CI 57%-100%) (► **Fig. 1**). The heterogeneity was assessed, and we found an I^2 of 80.2% (95% CI 53.5%-91.6%) and the *Q* test for heterogeneity gave *P* < 0.001. The high heterogeneity was explored with a leave-one-out sensitivity analysis, but no matter which study was excluded, the heterogeneity remained high. The study with the most influence on heterogeneity was Trivedi et al [15], and its removal diminishes the I^2 to 69% (**Supplementary file**). The prediction interval was 0% to 100%.

Local remission at first control

The pooled proportion of local remission at first control was 81% (95% CI 55% - 98%) (► **Fig. 2**). The heterogeneity was assessed, and we found an I^2 of 93.2% (95% CI 87.1%-96.4%) and the *Q* test for heterogeneity gave *P* < 0.001. The high heterogeneity was explored with a leave-one-out sensitivity analysis, but no matter which study was excluded, the heterogeneity remained high. Okimoto et al [13] has a high influence on the results, and its omission diminishes the I^2 to 84% (**Supplementary file**). The prediction interval was 0% to 100%.

Delayed bleeding

The pooled proportion of delayed bleeding was 1% (95% CI 0%-4%) (► **Fig. 3**). The heterogeneity was assessed, and we found an I^2 of 39.2% (95% CI 0%-75.9%) and the *Q* test for heterogeneity gave *P* = 0.144. The prediction interval was 0% to 11%.

Immediate perforation

The pooled proportion of immediate perforation was 0% (95% CI 0%-2%) (► **Fig. 4**). The heterogeneity was assessed, and we found an I^2 of 18.4% (95% CI 0%-63.2%) and the *Q* test for heterogeneity gave *P* = 0.294. The heterogeneity was low and not statistically significant. The study with the most influence was Wang et al [12], and if excluded the meta-analysis, heterogene-

► **Table 1** Characteristics of NASDA included in the meta-analysis.

Study	Type	Patients	Lesions	Size (mm)	Second duodenum	Lifting	En-bloc	Clip closure
Choski et al. 2015 [10]	Prospective	15	15	24 (10–60)	NR	14 (93.3%)	NR, but high rate	0 (0%)
Dang et al. 2022 [11]	Retrospective	39	39	26.5 (10–70)	27 (69.2%)	39 (100%)	NR, but high rate	0 (0%)
Wang et al. 2023 [12]	Prospective	49	50	30 (19–40)	37 (74%)	50 (100%)	0 (0%)	0 (0%)
Okimoto et al. 2022 [13]	Retrospective	35	37*	4 (2–7)	40 of 46* (86.9%)	0 (0%)	45 of 46* (97.8%)	NR, but high rate
Takizawa et al. 2022 [14]	Prospective	18	18**	8 (3–10)	19 of 21† (90.5%)	0 (0%)	17 (94.4%)	15 of 21† (71.4%)
Trivedi et al. 2022 [15]	Retrospective	41	46	12 (5–20)	26 (56.5%)	17 (36.9%)	22 (47.8%)	14 (30.4%)

*Thirty-seven adenomas included of 46 resected lesions, 9 lesions were excluded as hyperplastic lesions or “inflamed duodenal mucosa”.

†Cold snare was successful for 18 of 21 attempted lesions, EMR was done for the remaining 3.

NASDA, non-ampullary sporadic duodenal adenoma; NR, not reported; EMR, endoscopic mucosal resection.

► **Table 2** Results of CSP for NASDA studies.

Study	Lesions	Lesions followed-up	Remission after repeated resections	Remission at first control	Delayed bleeding	Immediate perforation
Choski et al. 2015 [10]	15	NR	NR	NR	1 (6.6%)	0 (0%)
Dang et al. 2022 [11]	39	39	35 (89.7%)	18 (46.2%)	1 (2.3%)	0 (0%)
Wang et al. 2023 [12]	50	41	40 (97.5%)	31 (75.6%)	2 (4%)	2 (4%)
Okimoto et al. 2022 [13]	37	37	37 (100%)	37 (100%)	0 (0%)	0 (0%)
Takizawa et al. 2022 [14]	18	18	18 (100%)	17 (94.4%)	0 (0%)	0 (0%)
Trivedi et al. 2022 [15]	46	19	14 (73.7%)	12 (63.2%)	0 (0%)	0 (0%)

CSP, cold-snare polypectomy; NASDA, non-ampullary sporadic duodenal adenoma; NR, not reported.

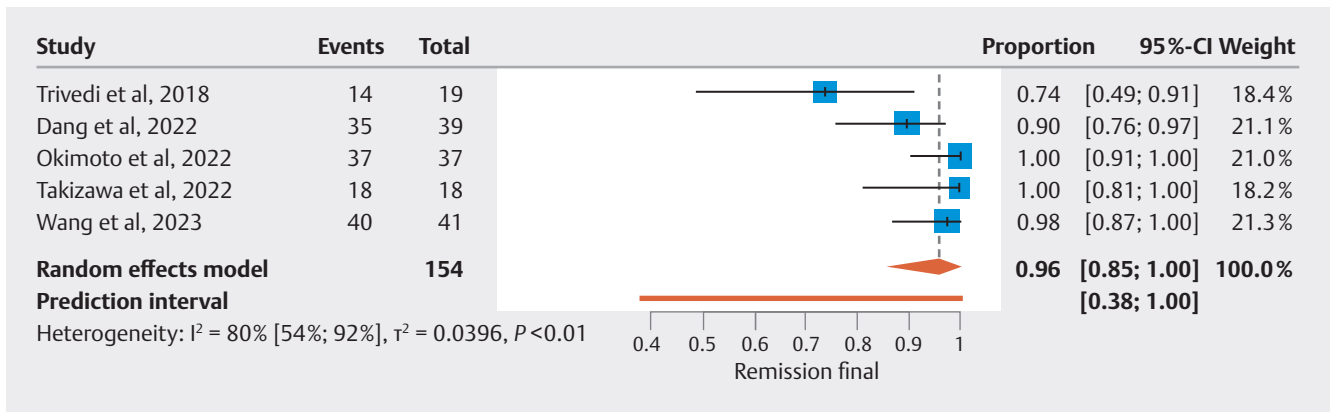
ity measured by I^2 drops to 0% (**Supplementary file**). The prediction interval was 0% to 6%.

Discussion

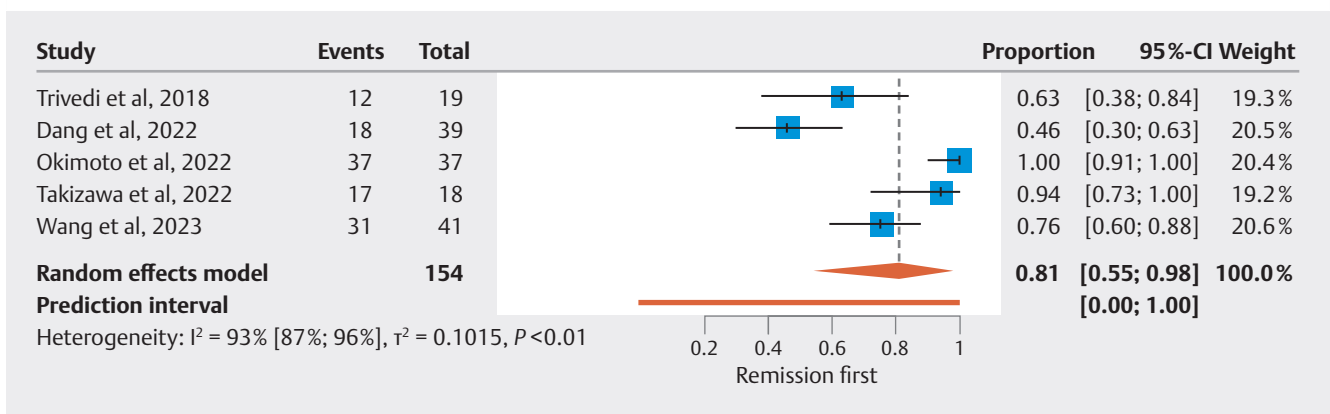
In our meta-analysis studies, submucosal saline lifting and final clipping were dependent on series median lesion size: Three series with larger lesions (median size > 20 mm) had almost universal lifting and no clipping [10, 11, 12], two series with smaller lesions (median size < 10 mm) had no lifting and high rates of clipping [13, 14], while one series with intermediary size lesions (median 12 mm) had about one-third of lesions with submucosal lifting and one-third with prophylactic clipping [15]. Because ESGE recommends cold snare for duodenal lesions with diameter < 6 mm and lifting (EMR) for larger lesions, we

may conclude that a cut-off value of 10 mm for submucosal saline lifting would be advisable: lesion size < 10 mm – CSP without lifting, lesion size above 10 mm – CSP with submucosal lifting.

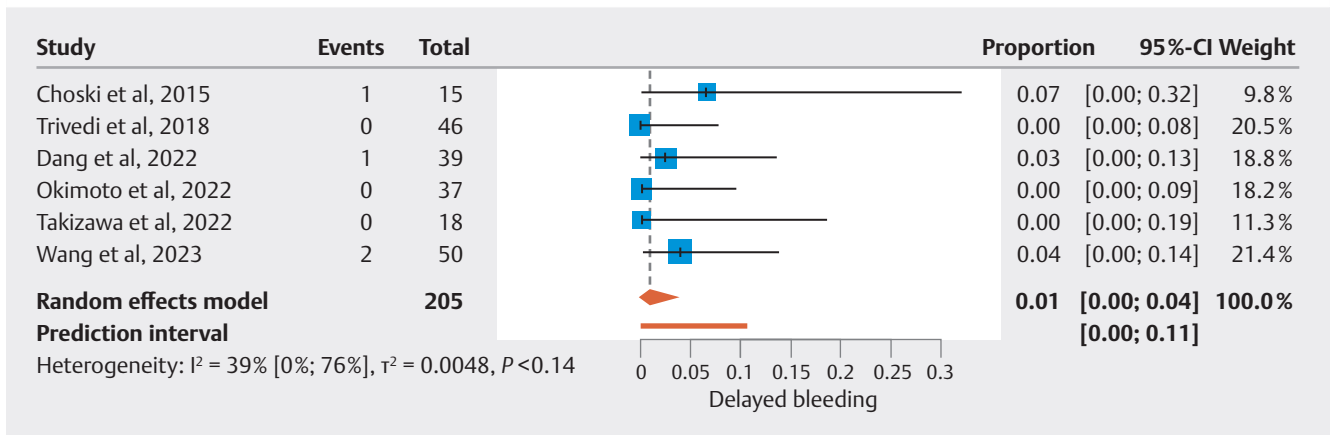
In one of two comparative series, the rate of local remission at first control was significantly lower for CSP than for EMR (75.6% vs. 97.7%) [132]. However, in this series, the authors used argon plasma coagulation to ablate the resection margins after EMR. Ablating the margins after EMR is a known effective way to increase local remission rates after piecemeal EMR of colorectal lesions [17]. However, after repeated resections, in both comparative series, there were no significant differences between CSP and EMR in local remission rates (73.7% vs 91.4% and 97.5% vs. 100%) [12, 15].



► **Fig. 1** Local remission after repeated CSP. Forest plot, five studies.



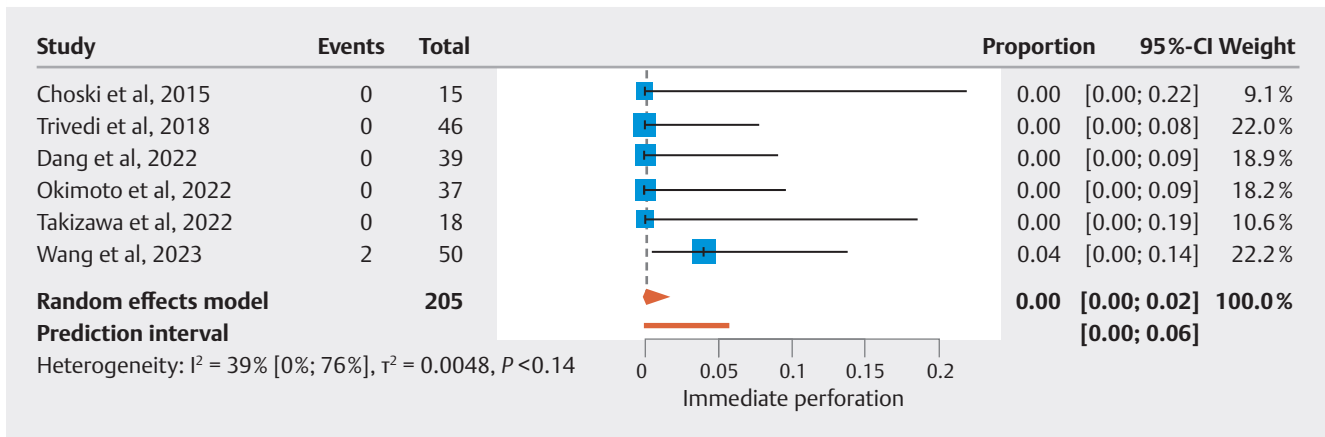
► **Fig. 2** Local remission at first control. Forest plot, five studies.



► **Fig. 3** Delayed bleeding rate. Forest plot, six studies.

We did not study CSP immediate bleeding rates; as for colorectal lesions, this is usually self-limited [18,19]. Delayed bleeding prevention by clipping after CSP of large lesions (median > 20 mm) was not done because it was considered unhelpful and with certain risks [10, 11, 12]. Smaller lesions (median < 10 mm) were clipped after CSP and there was no delayed bleeding [13, 14]. For intermediate-size lesions (median 12 mm) clip-

ping after CSP significantly reduced delayed bleeding rate compared with EMR (8.1% delayed bleeding rate) [15]. This failure of clipping to prevent delayed bleeding after EMR was already described in larger series [20,21]. In addition, clipping after EMR was reported to induce traumatic duodenal wall perforation [22]. The cut-off for prophylactic clipping to prevent delayed bleeding should probably be somewhere between 10 to



► Fig. 4 Perforation rate. Forest plot, six studies.

20 mm: lesion size < 10–20 mm – clipping, lesion size > 10–20 mm – no clipping.

The only two cases of immediate perforation were due to pulling of entrapped duodenal adenomatous tissue against the scope tip [12]. This peculiar technique was described as a “salvage maneuver” in colonic lesions when the initial CSP attempt fails because the snare has captured too much tissue [23]. The authors concluded that smaller bite-size portions of large polyps should be snared to avoid the pulling maneuver [12]. As above, a cut-off of 10 mm would be prudent for a bite-size and attempting en-bloc resection: lesion size ≤ 10 mm – en-bloc CSP, lesion size > 10 mm – piecemeal CSP with each bite-size of about 10 mm. This proposed 10-mm cut-off is empirical. Additional arguments are the 9-mm cut-off recommended by ESGE guidelines for en-bloc CSP for 6- to 9-mm colorectal polyps, the increasing use of piecemeal CSP for large colorectal sessile serrated lesions, and the availability of the 9- to 10-mm transverse diameter dedicated cold snares [24, 25, 26, 27, 28].

The CSP favorable safety profile findings were confirmed by a recent large study in FAP patients [29]. Cold snare was used to excise 2413 duodenal adenomas in 57 patients. There were 28 median adenomas per patient (minimum 5, maximum 166), with a mean size of 10 mm (2–50 mm). Four patients experienced bleeding, one immediate and three delayed (0.15%, 4 of 2413 adenomas) and there were no perforations. The individual efficacy was not possible to assess; however, the Spiegelman stage was significantly reduced at 1-year follow-up endoscopy [2].

Of note, occasionally CSP is not feasible, as reported here for three lesions in one series [14].

One limitation of the meta-analysis is the inclusion of observational studies. Nevertheless, we made all efforts to adhere to the highest methodology and reporting standards [30].

Another limitation is that clustering of the lesions could not be accounted for because individual patient data were not available for studies that included patients with multiple lesions [12, 13, 15].

Conclusions

Is this the time for cold snare for all NASDA? Should we trade a lesser bleeding risk with a higher number of endoscopies needed to finally achieve remission? Possibly, but patients also should have their say. However, randomized comparative trials with other resection methods (EMR, underwater EMR) and stratifying for lesion diameter are necessary.

Conflict of Interest

The authors declare that they have no conflict of interest.

References

- Gaspar JP, Stelow EB, Wang AY. Approach to the endoscopic resection of duodenal lesions. *World J Gastroenterol* 2016; 22: 600–617 doi:10.3748/wjg.v22.i2.600
- Spigelman AD, Williams CB, Talbot IC et al. Upper gastrointestinal cancer in patients with familial adenomatous polyposis. *Lancet* 1989; 2: 783–785
- Sellner F. Investigations on the significance of the adenoma-carcinoma sequence in the small bowel. *Cancer* 1990; 66: 702–715 doi:10.1002/1097-0142
- Vanbiervliet G, Moss A, Arvanitakis M et al. Endoscopic management of superficial nonampullary duodenal tumors: European Society of Gastrointestinal Endoscopy (ESGE). *Endoscopy* 2021; 53: 522–534
- Abbass R, Rigaux J, Al-Kawas FH. Nonampullary duodenal polyps: characteristics and endoscopic management. *Gastrointest Endosc* 2010; 71: 754–759 doi:10.1016/j.gie.2009.11.043
- Hatzaras I, Palesty JA, Abir F et al. Small-bowel tumors: epidemiologic and clinical characteristics of 1260 cases from the Connecticut Tumor Registry. *Arch Surg* 2007; 142: 229–235
- Pimentel-Nunes P, Libânio D, Bastiaansen BAJ et al. Endoscopic submucosal dissection for superficial gastrointestinal lesions: European Society of Gastrointestinal Endoscopy (ESGE) Guideline – Update 2022. *Endoscopy* 2022; 54: 591–622 doi:10.1055/a-1811-7025
- Haddaway NR, Collins AM, Coughlin D et al. The role of Google Scholar in evidence reviews and its applicability to grey literature searching. *PLoS One* 2015; 10: e0138237 doi:10.1371/journal.pone.0138237

- [9] R Core Team. R: A Language and Environment for Statistical Computing. R Foundation for Statistical Computing. Vienna, Austria. <https://www.R-project.org/> 2023
- [10] Choksi N, Elmunzer BJ, Stidham RW et al. Cold snare piecemeal resection of colonic and duodenal polyps ≥ 1 cm. *Endosc Int Open* 2015; 3: E508–E513 doi:10.1055/s-0034-1392214
- [11] Dang DT, Suresh S, Vance RB et al. Outcomes of cold snare piecemeal EMR for nonampullary small-bowel adenomas larger than 1 cm: a retrospective study. *Gastrointest Endosc* 2022; 95: 1176–1182
- [12] Wang H, Sidhu M, Gupta S et al. Cold snare endoscopic mucosal resection for the removal of large duodenal adenomas. *Gastrointest Endosc* 2023; 97: 1100–1108
- [13] Okimoto K, Maruoka D, Matsumura T et al. Long-term outcomes of cold snare polypectomy for superficial non-ampullary duodenal epithelial tumors. *J Gastroenterol Hepatol* 2022; 37: 75–80 doi:10.1111/jgh.15666
- [14] Takizawa K, Kakushima N, Tanaka M et al. Cold snare polypectomy for superficial non-ampullary duodenal epithelial tumor: a prospective clinical trial (pilot study). *Surg Endosc* 2022; 36: 5217–5223 doi:10.1007/s00464-021-08899-9
- [15] Trivedi M, Klapheke R, Youssef F et al. Comparison of cold snare and hot snare polypectomy for the resection of sporadic nonampullary duodenal adenomas. *Gastrointest Endosc* 2022; 96: 657–664 doi:10.1016/j.gie.2022.05.007
- [16] Maruoka D, Matsumura T, Kasamatsu S et al. Cold polypectomy for duodenal adenomas: a prospective clinical trial. *Endoscopy* 2017; 49: 776–783 doi:10.1055/s-0043-107028
- [17] Meulen LWT, Bogie RMM, Winkens B et al. Thermal ablation of mucosal defect margins to prevent local recurrence of large colorectal polyps: a systematic review and meta-analysis. *Endosc Int Open* 2022; 10: E1127–E1135 doi:10.1055/a-1869-2446
- [18] Qu J, Jian H, Li L et al. Effectiveness and safety of cold versus hot snare polypectomy: A meta-analysis. *J Gastroenterol Hepatol* 2019; 34: 49–58 doi:10.1111/jgh.14464
- [19] Thoguluva Chandrasekar V, Spadaccini M, Aziz M et al. Cold snare endoscopic resection of nonpedunculated colorectal polyps larger than 10 mm: a systematic review and pooled-analysis. *Gastrointest Endosc* 2019; 89: 929–936
- [20] Tomizawa Y, Ginsberg GG. Clinical outcome of EMR of sporadic, non-ampullary, duodenal adenomas: a 10-year retrospective. *Gastrointest Endosc* 2018; 87: 1270–1278 doi:10.1016/j.gie.2017.12.026
- [21] Probst A, Freund S, Neuhaus L et al. Complication risk despite preventive endoscopic measures in patients undergoing endoscopic mucosal resection of large duodenal adenomas. *Endoscopy* 2020; 52: 847–855 doi:10.1055/a-1144-2767
- [22] Klein A, Nayyar D, Bahin FF et al. Endoscopic mucosal resection of large and giant lateral spreading lesions of the duodenum: success, adverse events, and long-term outcomes. *Gastrointest Endosc* 2016; 84: 688–696 doi:10.1016/j.gie.2016.02.049
- [23] Tribonias G, Komeda Y, Voudoukis E et al. Cold snare polypectomy with pull technique of flat colonic polyps up to 12 m: a porcine model. *Ann Gastroenterol* 2015; 8: 141–143
- [24] Ferlitsch M, Moss A, Hassan C et al. Colorectal polypectomy and endoscopic mucosal resection (EMR): European Society of Gastrointestinal Endoscopy (ESGE) Clinical Guideline. *Endoscopy* 2017; 49: 270–297 doi:10.1055/s-0043-102569
- [25] van Hattem WA, Shahidi N, Vosko S et al. Piecemeal cold snare polypectomy versus conventional endoscopic mucosal resection for large sessile serrated lesions: a retrospective comparison across two successive periods. *Gut* 2021; 70: 1691–1697 doi:10.1136/gutjnl-2020-321753
- [26] STERIS Healthcare. Exacto cold snare. <https://www.steris.com/health-care/products/endoscopy-devices/polypectomy-and-tissue-acquisition-devices/exacto-cold-snare#ProductOverview>
- [27] Olympus. Cold and hot snares. https://et-catalog.olympus.eu/products.html?level_1_id=11951
- [28] Boston Scientific. Captivator cold single-use snare. <https://www.bostonscientific.com/en-US/products/snares/captivator-cold-single-use-snare.html>
- [29] Takeuchi Y, Hamada K, Nakahira H et al. Efficacy and safety of intensive downstaging polypectomy (IDP) for multiple duodenal adenomas in patients with familial adenomatous polyposis: a prospective cohort study. *Endoscopy* 2023; 55: 515–523
- [30] Faber T, Ravaud P, Riveros C et al. Meta-analyses including non-randomized studies of therapeutic interventions: a methodological review. *BMC Med Res Methodol* 2016; 16: 35 doi:10.1186/s12874-016-0136-0