



Transvaginal Ovarian Cyst Drainage in Third Trimester to Facilitate Vaginal Delivery

Vivienne T. Meljen, MD^{1,2} Carmen M. Avram, MD¹ Nicole P. Kerner, MD³ Eleanor H. J. Rhee, MD⁴
 Jeffrey A. Kuller, MD⁴ Sarahn M. Wheeler, MD⁴ 

¹Department of Obstetrics and Gynecology, Duke University Health System, Durham, North Carolina

²Department of Obstetrics and Gynecology, Washington State University Elson S. Floyd School of Medicine, Spokane, Washington

³Division of Women and Community Population Health, Department of Obstetrics and Gynecology, Duke University Health System, Durham, North Carolina

Address for correspondence Carmen M. Avram, MD, Duke University Medical Center, 2301 Erwin Road, Durham, NC 27710 (e-mail: carmen.avram@duke.edu).

⁴Division of Maternal-Fetal Medicine, Department of Obstetrics and Gynecology, Duke University Health System, Durham, North Carolina

AJP Rep 2023;13:e82–e84.

Abstract

Adnexal masses in the third trimester of pregnancy may obstruct the pelvic outlet precluding labor induction and vaginal delivery. Expectant versus surgical management of adnexal cysts in pregnancy must carefully weigh maternal–fetal benefits and risks. Simple benign appearing cysts with low likelihood of malignancy may be amenable to percutaneous drainage as a bridge to interval postpartum laparoscopic cystectomy. We demonstrated posterior culdocentesis as a safe, minimally invasive technique to decompress a simple benign appearing left adnexal cyst obstructing the pelvic outlet in the third trimester at the time of labor induction to facilitate vaginal delivery and prevent primary cesarean delivery. Detailed sonographic cyst evaluation and counseling on underlying risk of malignancy must be considered to guide shared decision-making.

Keywords

- ▶ adnexal
- ▶ culdocentesis
- ▶ cyst
- ▶ ovarian
- ▶ pregnancy
- ▶ transvaginal

Adnexal masses in pregnancy are rare, occurring in 0.05 to 2.4% of pregnancies.¹ Management is expectant or surgical by aspiration, laparoscopy, or laparotomy. The goal of surgical intervention is to prevent maternal–fetal complications related to the mass such as adnexal torsion, cyst rupture, progression to malignancy, labor dystocia, preterm delivery, or cesarean delivery.² In the third trimester, adnexal cysts have the potential to obstruct the pelvic outlet precluding vaginal delivery. In these cases, the modality of intervention must

carefully consider maternal–fetal well-being. Several cases of transvaginal and transabdominal aspiration of simple benign-appearing cysts in pregnancy have been described, averting the need for antepartum laparoscopy or laparotomy which has been associated with increased risk of preterm delivery.^{3–6} We present the case of a large adnexal cyst obstructing the pelvic outlet at the time of induction of labor and a minimally invasive two-stage approach that permitted vaginal delivery followed by an interval laparoscopic ovarian cystectomy.

received
 November 6, 2022
 accepted
 September 10, 2023
 accepted manuscript online
 September 29, 2023

DOI <https://doi.org/10.1055/a-2184-0548>.
 ISSN 2157-6998.

© 2023. The Author(s).

This is an open access article published by Thieme under the terms of the Creative Commons Attribution-NonDerivative-NonCommercial-License, permitting copying and reproduction so long as the original work is given appropriate credit. Contents may not be used for commercial purposes, or adapted, remixed, transformed or built upon. (<https://creativecommons.org/licenses/by-nc-nd/4.0/>)

Thieme Medical Publishers, Inc., 333 Seventh Avenue, 18th Floor, New York, NY 10001, USA

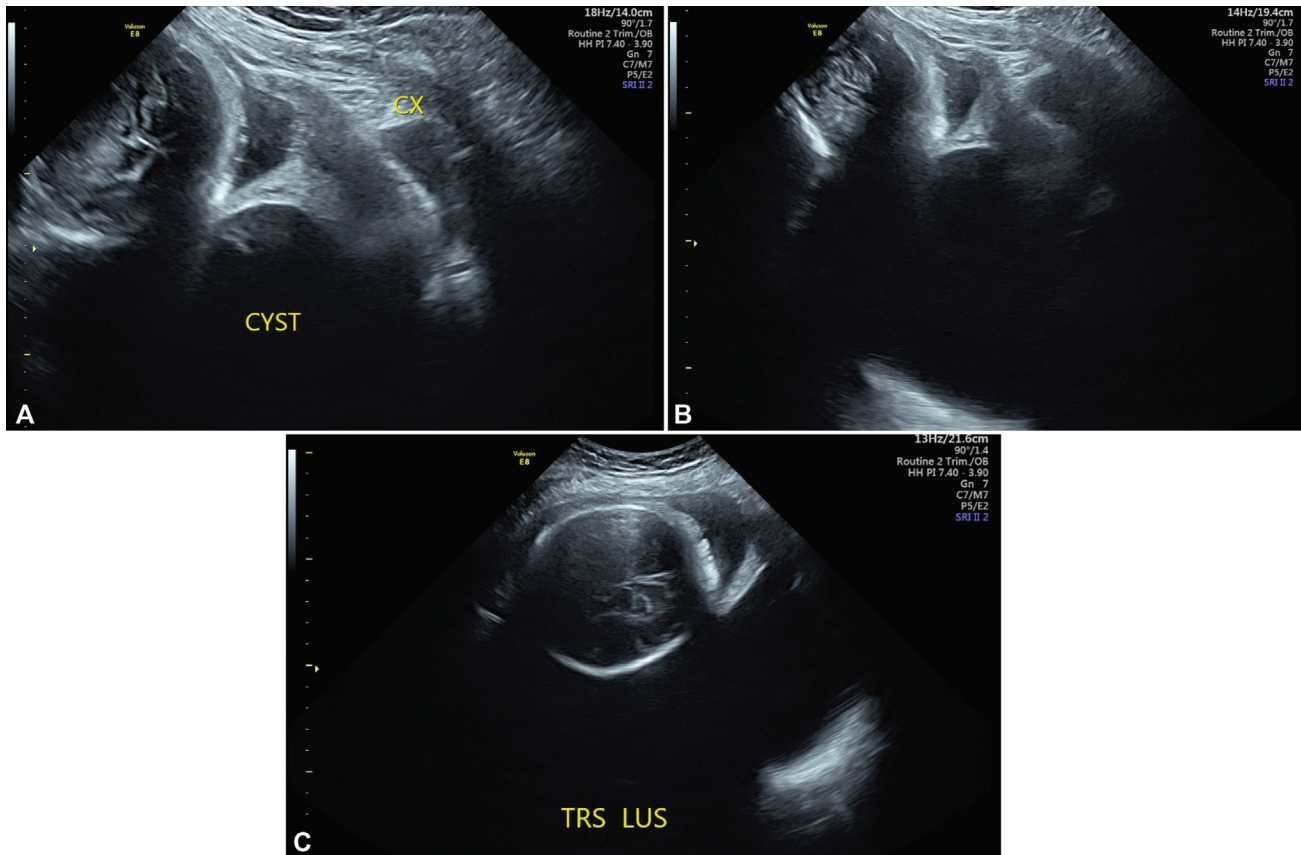


Fig. 1 Transabdominal ultrasound at 32^{3/7} weeks demonstrating large (14.2 × 13.2 × 9.5 cm) simple-appearing ovarian cyst occluding the posterior cul-de-sac and displacing the fetal vertex cephalad and the cervix anteriorly. (A) Sagittal, zoomed, labeled (cx—cervix, cyst). (B) Sagittal, without zoom. (C) Transverse, through lower uterine segment (TRS LUS) with fetal head visible.

Case

The patient was a 32-year-old primigravida at 32^{6/7} weeks who was transferred to our hospital for preterm delivery in setting of severe pre-eclampsia. Her pregnancy was also complicated by a large simple appearing maternal left adnexal cyst. The left adnexal cyst measured 14.2 × 13.2 × 9.5 cm on a 32-week ultrasound (►Fig. 1A–C). The cyst did not have septations, papillary projections, internal nodularity, or blood flow. On admission, pelvic examination demonstrated a closed cervix that was displaced anteriorly by the cyst, which filled the posterior cul-de-sac. A vaginal delivery was suspected to be unsuccessful due to pelvic outlet obstruction from the cyst. As an alternative to primary cesarean delivery, a posterior culdocentesis was proposed for cyst drainage and decompression to relieve the pelvic obstruction, facilitate induction of labor, and increase likelihood of vaginal delivery. A gynecologic oncology consultation was obtained, and the patient consented to the procedure with the acknowledgement that it was not possible to exclude the presence of malignancy.

Following spinal epidural placement, the patient was placed in dorsal lithotomy position. A sterile speculum was inserted to expose the posterior fornix. A blunt probe was used to confirm the target anatomy with transabdominal ultrasound guidance. The vagina was prepped and a 12-cm 22G spinal needle was placed through the vaginal wall, into the cyst (►Fig. 2A). Approximately 150 mL of straw-colored serosan-

guinous fluid was drained and sent to cytology. Additional fluid drained spontaneously through the puncture sites with transabdominal pressure. Once the maximum cyst dimension was less than 7 cm on ultrasound, it was allowed to drain spontaneously, and the fetal head was noted to be more applied to the cervix. The patient underwent mechanical cervical ripening with a balloon catheter (►Fig. 2B) and ultimately had a spontaneous vaginal delivery.

The patient was scheduled for interval laparoscopy at approximately 1 month postpartum. Prior to laparoscopy, cytology results revealed predominantly macrophages and scattered peripheral blood elements. Rare epithelioid cells were noted, but these were too degenerated to characterize the lesion. At the time of surgery, transvaginal examination once again revealed a large smooth-surfaced and mobile cyst filling the posterior cul-de-sac, deviating the cervix anteriorly. The cyst extended to approximately 2 cm caudal to the umbilicus. The uterus was small, anteverted, and mobile. Laparoscopy revealed a large smooth-walled cyst arising from the left ovary which was occupying the posterior cul-de-sac with some adhesions to the peritoneum requiring gentle upward traction to extract it from the pelvis (►Fig. 3). This exposed a raw peritoneal surface once removed. The cyst was drained. Ovarian contents revealed straw-colored yellow fluid and small amounts of thick white fluid. The walls appeared somewhat thickened and friable once exposed. There was a small pocket, which drained chocolate-colored fluid

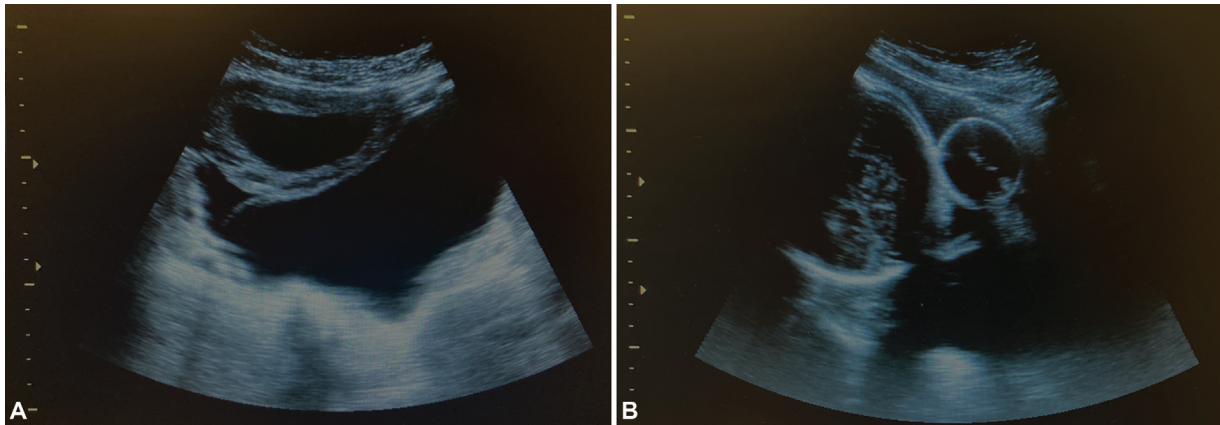


Fig. 2 Transabdominal ultrasound at the time of transvaginal cyst drainage. (A) Transverse, reduced cyst size and lower uterine segment. (B) Sagittal, reduced cyst size and cervical ripening Foley balloon in lower uterine segment adjacent to fetal head.

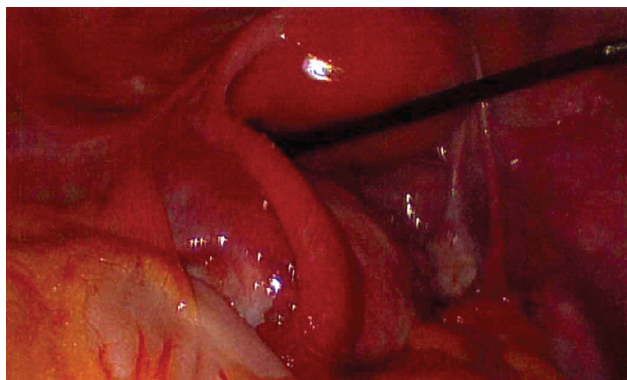


Fig. 3 Images of cyst at the time of interval laparoscopic ovarian cystectomy. A large left ovarian cyst occluding posterior cul-de-sac.

consistent with the appearance of an endometrioma. The cyst wall was excised in its entirety. Otherwise, the pelvic and abdominal surveys were within normal limits. Final pathology revealed a cyst wall with marked acute and chronic inflammation and granulation tissue (9.7 cm in aggregate), consistent with abscess and no evidence of malignancy. Notably, these changes were thought to be related to the transvaginal drainage, as there were no signs of infection throughout her evaluation. This case was exempt from Duke University Institutional Review Board review, and the patient provided written informed consent of the use of her images.

Comment

The case of a labor obstruction due to a simple cyst with low risk of malignancy permits the use of percutaneous drainage given that it does not require immediate removal to relieve labor obstruction. This prevents cesarean delivery, and the need for antepartum laparoscopy or laparotomy, which though safe, is more resource intensive. There are several previously described cases of pregnant patients undergoing transvaginal aspiration of simple cysts with benign appearance on ultrasound in the first or second trimester.³⁻⁶ Needle aspiration has been associated with a high risk of recurrence of the cyst but has short-term advantages as demon-

strated in this case. Notably, our case documents the most advanced gestational age reported for such a technique.

Important considerations prior to aspiration include thorough sonographic assessment of the mass conferring low risk of malignancy, shared decision-making with the patient, and interval laparoscopic approach to ovarian cystectomy. Risk factors of malignancy include size greater than 10 cm, papillary or solid components, irregularity, Doppler flow, and elevated serum biomarkers.⁷ Ultrasound-guided transvaginal needle aspiration is a safe, minimally invasive technique to decrease the size of ovarian cysts with low concern for malignancy among pregnant patients.

Financial Support

None.

Conflict of Interest

None declared.

References

- Montes de Oca MK, Dotters-Katz SK, Kuller JA, Previs RA. Adnexal masses in pregnancy. *Obstet Gynecol Surv* 2021;76(07):437-450
- Whitecar MP, Turner S, Higby MK. Adnexal masses in pregnancy: a review of 130 cases undergoing surgical management. *Am J Obstet Gynecol* 1999;181(01):19-24
- Khaw KT, Walker WJ. Ultrasound guided fine needle aspiration of ovarian cysts: diagnosis and treatment in pregnant and non-pregnant women. *Clin Radiol* 1990;41(02):105-108
- Lee DJ, Heggen DM, VanderKolk HL. Transvaginal aspiration of an ovarian tumor with a benign ultrasound appearance during the second trimester of pregnancy. *J Clin Ultrasound* 1992;20(02):135-138
- Bannon LC, Hayes KG, Porter KB. Percutaneous drainage of a rapidly enlarging simple ovarian cyst in the third trimester. *Mil Med* 2015;180(10):e1118-e1120
- Duke D, Colville J, Keeling A, Broe D, Fotheringham T, Lee MJ. Transvaginal aspiration of ovarian cysts: long-term follow-up. *Cardiovasc Intervent Radiol* 2006;29(03):401-405
- American College of Obstetricians and Gynecologists' Committee on Practice Bulletins—Gynecology. Practice Bulletin No. 174: evaluation and management of adnexal masses. *Obstet Gynecol* 2016;128(05):e210-e226