

Duodenal neuroendocrine tumors: Short-term outcomes of endoscopic submucosal dissection performed in the Western setting



Authors

Sunil Gupta^{1,2}, Puja Kumar^{1,3}, Rocio Chacchi⁴, Alberto Murino⁴, Edward J Despott⁴, Arnaud Lemmers⁵, Mathieu Pioche⁶, Michael J. Bourke^{1,2}

Institutions

- 1 Gastroenterology and Hepatology, Westmead Hospital, Westmead, Australia
- 2 Medicine, The University of Sydney Westmead Clinical School, Westmead, Australia
- 3 Division of Gastroenterology and Hepatology, University of Calgary Faculty of Medicine, Calgary, Canada
- 4 Royal Free Unit for Endoscopy, The Royal Free Hospital, University College London Institute for Liver and Digestive Health, London, United Kingdom of Great Britain and Northern Ireland
- 5 Gastroenterology, Hepatopancreatology and Digestive Oncology, Erasme University Hospital, Université Libre de Bruxelles (ULB), Bruxelles, Belgium
- 6 Endoscopy Unit, Digestive Disease Department, Hôpital Edouard Herriot, Lyon, France

Key words

Neoplasia, Quality and logistical aspects, Performance and complications, GI Pathology

received 2.4.2023

accepted after revision 1.9.2023

accepted manuscript online 25.9.2023

Bibliography

Endosc Int Open 2023; 11: E1099–E1107

DOI 10.1055/a-2181-0320

ISSN 2364-3722

© 2023. The Author(s).

This is an open access article published by Thieme under the terms of the Creative Commons Attribution-NonDerivative-NonCommercial License, permitting copying and reproduction so long as the original work is given appropriate credit. Contents may not be used for commercial purposes, or adapted, remixed, transformed or built upon. (<https://creativecommons.org/licenses/by-nc-nd/4.0/>)

Georg Thieme Verlag KG, Rüdigerstraße 14,
70469 Stuttgart, Germany

Corresponding author

Prof. Michael J. Bourke, Westmead Hospital, Gastroenterology and Hepatology, Cnr of Hawkesbury and Darcy Rd, 2145 Westmead, Australia
michael@citywestgastro.com.au

ABSTRACT

Background and study aims Endoscopic resection (ER) is recommended for the management of duodenal neuroendocrine tumors (D-NETs) confined to the submucosal layer, without lymph node or distant metastasis. While this is accepted practice for lesions < 10 mm, consensus for larger lesions remains unclear. Although endoscopic submucosal dissection (ESD) has been proposed as the preferred ER technique for DNETs ≥10 mm, there are limited data on efficacy and safety, particularly in the Western setting.

Patients and methods We performed a retrospective analysis of patients with D-NETs who underwent ESD between 2012 and 2022 in three tertiary referral centers in Australia, France, and Belgium.

Results Fourteen patients with 15 D-NETs were evaluated. Median patient age was 64 years (interquartile range [IQR] 58–70 years). All D-NETs were confined to the duodenal bulb. Median D-NET size was 10 mm (IQR 7–12 mm) and specimen size was 15 mm (IQR 15–20 mm). Median procedure time was 60 minutes (IQR 25–90 minutes). The rate of en bloc resection was 100%. Intra-procedural perforation occurred in four patients (26.7%), with all closed endoscopically without long-term sequelae. There were no episodes of clinically significant bleeding. No local recurrence, lymph node or distant metastasis was observed at a median follow-up of 19.9 months (IQR 10.3–49.3 months).

Conclusions In experienced hands, ESD for D-NETs can achieve a 100% en bloc resection rate. There were no cases of local recurrence or distant metastatic spread, indicating that ESD may be a viable option for patients with D-NETs 10 to 15 mm that are not surgical candidates.

Introduction

Duodenal neuroendocrine tumors (D-NETs) are uncommon neoplastic entities, primarily arising within the duodenal bulb. Between 1983 and 2010, there was a 400% increase in the incidence of D-NETs [1], likely owing to improved optical evaluation and advancements in endoscope technology [2]. The majority of D-NETs (80%) are non-ampullary [3], with current guidelines advocating for resection when ≤ 20 mm in size, in the absence of lymph node involvement [4, 5]. This is primarily due to their metastatic potential, with the ability to spread to regional lymph nodes and distant organs such as the liver.

Although surgical intervention offers a greater chance of resection with clear margins when compared with endoscopic resection (ER), it is highly invasive and not without risk [4]. The utility of ER remains unclear, with relevant literature limited to small volume case-series [6, 7, 8, 9, 10, 11, 12, 13, 14, 15, 16, 17, 18, 19] that describe a myriad of methods, including cold-snare polypectomy, endoscopic mucosal resection (EMR), band-EMR and band-EMR without resection (BWR). However, because D-NETs are subepithelial lesions (SELs), there is an inherent risk of incomplete resection with these techniques. Furthermore, any failed attempts at ER may promote formation of submucosal fibrosis and therefore render subsequent attempts difficult.

Endoscopic submucosal dissection (ESD) is an attractive alternative because it offers the potential to achieve en bloc resection with clear margins. However, the current evidence base pertaining to the outcomes of ESD for non-ampullary D-NETs is limited to case series of less than 10 patients, predominantly from Asia [6, 20, 21, 22]. We sought to evaluate the performance and safety of ESD in the management of non-ampullary D-NETs in a multi-centered Western setting.

Methods

Study population

We reviewed prospectively maintained ESD databases from three tertiary referral centers in Australia, France, and Belgium between January 2012 and June 2022. A total of 14 patients with 15 D-NETs underwent ESD at one of the three expert endoscopy centers. In each case, a baseline gastroscopy, endoscopic ultrasound (EUS), and axial imaging in the form of computed tomography (CT) and/or somatostatin receptor imaging were performed prior to ESD to ensure that there was no evidence of regional lymph node enlargement or distant metastasis. The primary goal of ESD was to obtain an en bloc excision, with clear horizontal and vertical margins. Thus, the indications for ESD were lesion size 10 to 15 mm, difficult access or suspected submucosal fibrosis as demonstrated by a poor lift with suctioning. Approval to maintain prospective databases was provided by the research and ethics committees of each respective hospital. Informed consent was gained from each patient prior to ESD.

Endoscopic resection

All endoscopic procedures were performed by a study investigator (accredited gastroenterologist with interventional endoscopy training and an established tertiary referral practice). All ESD procedures were performed with general anesthesia with endotracheal intubation. A single-channel upper gastrointestinal endoscope with a water-jet system was used. Carbon dioxide insufflation was used during all ESD cases. A Dual Knife or Dual Knife J 1.5 mm (Olympus, Tokyo, Japan) was used to mark out the lesion using soft coagulation, with a 3- to 5-mm rim of normal duodenal mucosa to reduce the risk of positive horizontal margins. A submucosal injection of a colloid chromoinjectate was performed to lift the lesion. At the discretion of the proceduralist, adrenaline (1:100,000) was added to the chromoinjectate in some cases.

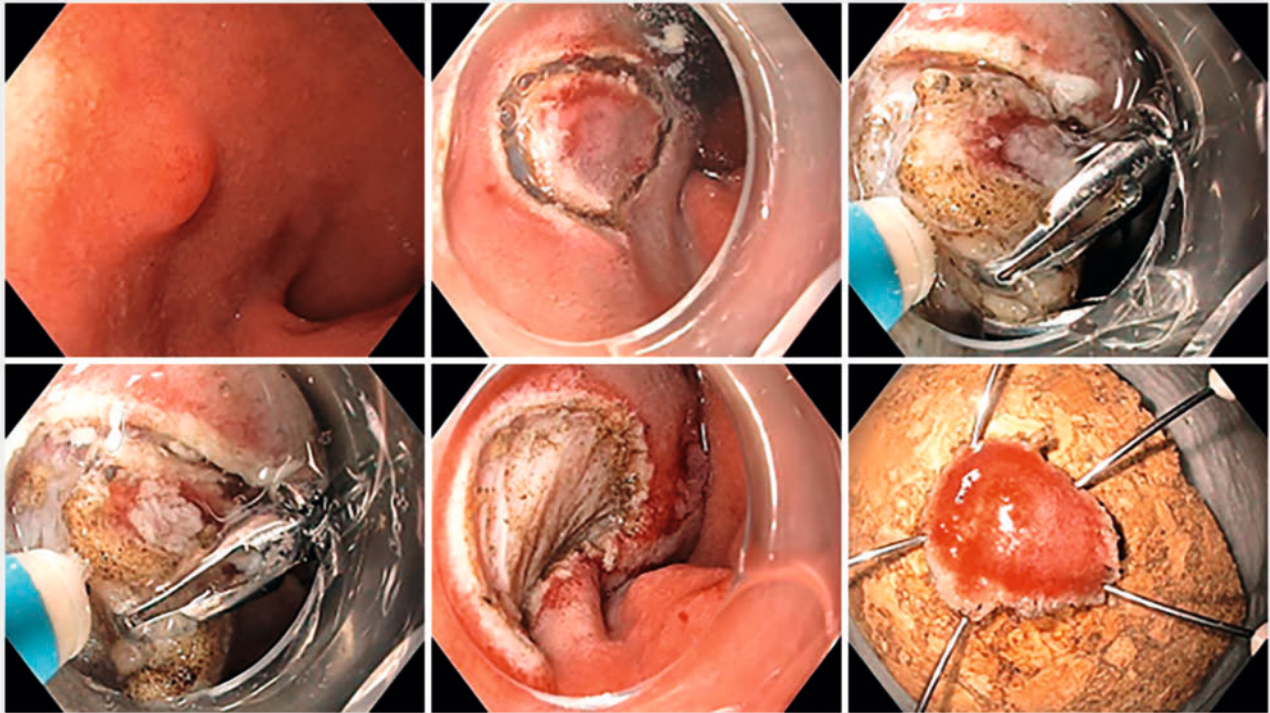
Subsequently, a mucosal incision was performed to expose the submucosal plane, ensuring the soft coagulation markings were kept within the field of resection. In the majority of cases, the mucosal incision was extended circumferentially, following which submucosal dissection was performed as close to the muscle layer as possible. In one case, due to the challenging location of the D-NET, a submucosal tunnel was created from the pylorus into the duodenal bulb. Once that was complete, a mucosal incision was created on either side of the tunnel to remove the lesion en bloc. Traction was employed if submucosal fibrosis was encountered (► Fig. 1). A microprocessor-controlled generator (ERBE VIO 300 D or VIO3; ERBE, Tübingen, Germany) was used during mucosal incision and submucosal dissection (► Fig. 2). Large vessels were treated prophylactically with hemostatic forceps using soft coagulation. Minor intra-procedural bleeding was considered an accepted part of routine ESD and was commonly encountered. This was readily treated with the Dual Knife on a Swift coagulation setting or hemostatic forceps on a soft coagulation setting.

Histological evaluation

Once retrieved, the lesion was fixed in 10% formalin. Following serial sectioning, the resected specimens were assessed independently by two subspecialist gastrointestinal pathologists. The histological type, macroscopic appearance, tumor size, depth of invasion, lymphatic and vascular involvement, and horizontal and vertical margins were assessed. The Ki-67 index was assessed in all cases to classify tumors as grade 1, 2 or 3 according to the World Health Organization (WHO) 2019 classification [23].

Definitions

En bloc resection was defined as resection of the lesion in a single piece with no endoscopically visible residual tumor. R0 resection was defined as en bloc resection with histologically clear horizontal and vertical margins. Presence of any tumor cells at the resected margin was considered a positive margin. As per the 2023 European Neuroendocrine Tumor Society (ENETS) guideline, curative resection was defined as an R0 resection, lesion size ≤ 15 mm, WHO Grade 1 histology and without lymphovascular invasion [4].



► **Fig. 1** A 10-mm duodenal bulb neuroendocrine tumor removed by endoscopic submucosal dissection, employing endoclips for traction to expose the submucosal plane.

Peri-procedural adverse events, including bleeding, perforation, and stenosis were recorded. Clinically significant intra-procedural bleeding was defined as the requirement of hemostatic techniques other than the use of hemostatic forceps or the Dual Knife J on Swift coagulation. Delayed bleeding was defined as hematemesis or melena that required an additional endoscopic procedure and necessitated the use of hemostatic forceps or endo-clips within the first 2 weeks post-ESD.

Perforation was subdivided into intra-procedural and delayed. Delayed perforation was diagnosed when a patient presented with fevers and peritoneal or retroperitoneal free air on CT imaging, in the absence of intraoperative perforation. Stenosis was defined as inability to pass a standard gastroscope beyond the site of ESD at time of endoscopic follow-up or if a patient presented with clinical signs of obstruction.

Follow-up

Post-ESD, patients were kept fasted and observed in the hospital overnight on intravenous (IV) fluids and a continuous IV proton pump inhibitor (PPI) infusion. The following morning, patients were started on clear fluids. Patients were discharged if stable, afebrile, pain-free, and tolerating fluids. All patients were prescribed twice-daily oral PPI therapy for 2 months. At follow-up gastroscopy 6-months post-ESD, if there was endoscopic concern for recurrence, biopsies were taken to assess for histologic evidence of recurrence.

Statistical analysis

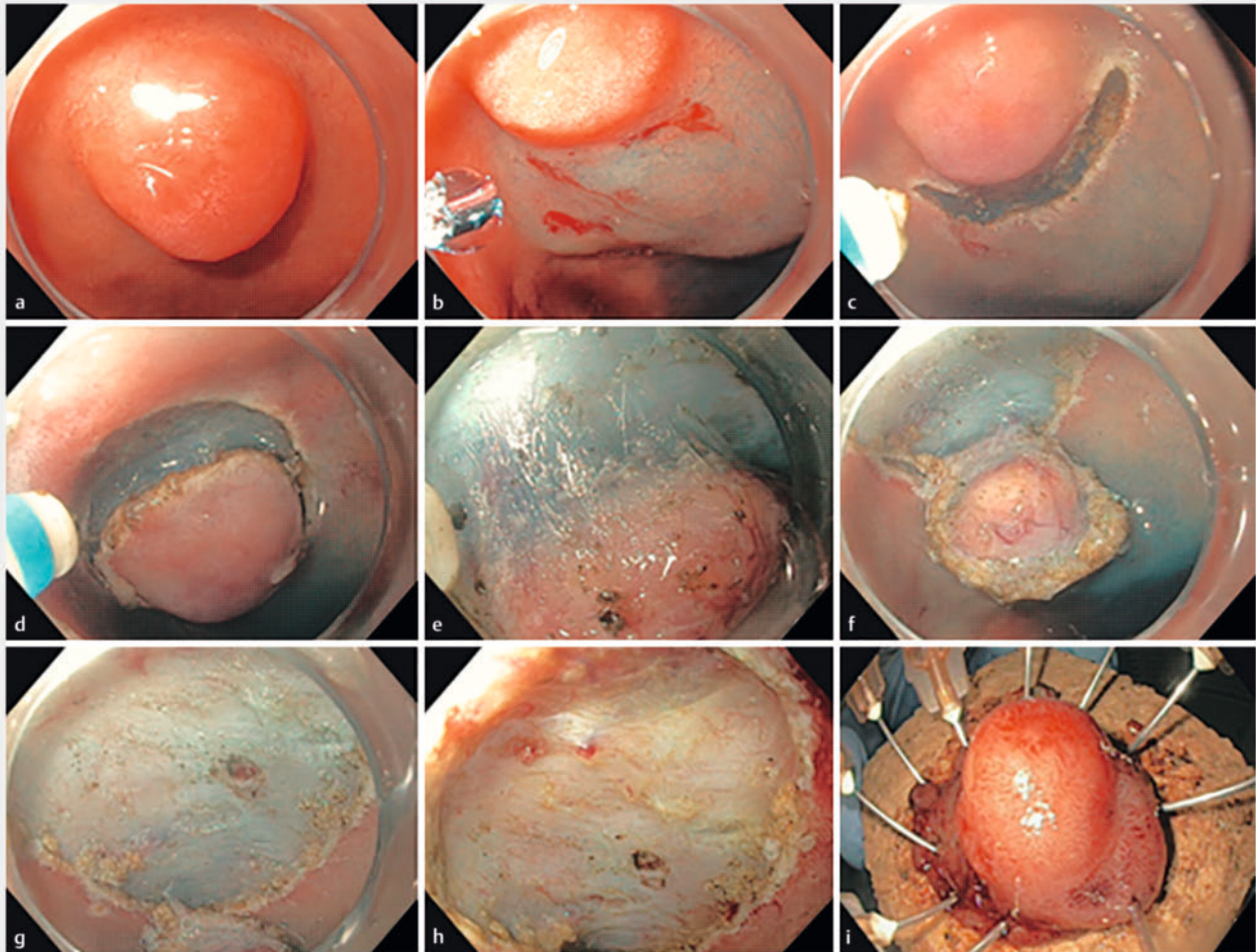
SPSS version 26.0 (IBM, Armonk, New York, United States) was used for data analysis. Variables were analyzed per lesion. Continuous variables were summarized using median and interquartile range (IQR). Categorical variables were summarized as frequencies (%). All analyses were exploratory and two-tailed tests with a 5% significance level were used throughout. To test for association between categorical variables, the Pearson χ^2 or the Fisher Exact tests were used, where appropriate.

Results

Patient and lesion characteristics

A total of 15 D-NETs in 14 patients underwent ESD (► **Table 1**). The median age of the patients was 64 years (IQR 58–70 years) and the majority were male ($n=9$, 64.3%). All D-NETs were located within the duodenal bulb. There were two patients (14.3%) with concomitant D-NETs identified at index gastroscopy. One had a 2- to 3-mm lesion that was easily accessible and resected via EMR later. The other had their concomitant D-NET removed via ESD at a later date, and is included within this dataset.

Endoscopic morphology was either Paris Is ($n=9$, 60%) or Paris IIa ($n=6$, 40%). One lesion was ulcerated (6.7%). Most of the D-NETs appeared to originate from Layer 3 (submucosa) based on EUS examination ($n=13$, 86.7%) and demonstrated tumor avidity on 68-Ga-DOTATATE positron emission tomography (PET) scan imaging ($n=10$, 66.7%). The median size of the D-NETs at index gastroscopy was 10 mm (IQR 7–12 mm).



► **Fig. 2** Endoscopic submucosal dissection technique. **a** Duodenal neuroendocrine tumor observed in duodenal bulb. **b** Submucosal injection. **c** Mucosal incision. **d** Circumferential incision completed. **e** Submucosal dissection. **f** Submucosal tumor completely dissected. **g** Completion of dissection. **h** Post-ESD defect. **i** En bloc pinned specimen.

Procedure and histologic outcomes

The majority of the patients underwent ESD at the lead site ($n = 9$, 66.7%; ► **Table 2**). The median specimen size was 15 mm (IQR 15–20 mm) and time taken to complete ESD was 60 minutes (IQR 25–90 minutes). Histological analysis classified 5 (33.3%) D-NETs as Grade 1 and 10 (66.7%) as Grade 2.

En bloc resection was achieved in all 15 lesions (100%) (► **Table 3**). A conventional approach was utilized in nine (60%). One (6.7%) required the creation of a submucosal tunnel from the pylorus into the duodenal bulb. The remainder required traction ($n = 5$, 33.3%) due to the presence of submucosal fibrosis.

Horizontal R0 margins were achieved in all 15 (100%) and vertical R0 margins in seven patients (46.7%). Thus, R0 resection was achieved in seven patients total (46.7%). Of the seven cases with positive vertical margins, the length of the involved interface was a median of 0.90 mm (IQR 0.18–3.48 mm). Lymphovascular invasion was present in one Grade 2 D-NET (6.7%), which had clear margins. By ENETS 2023 criteria, a curative re-

section was achieved in three cases (20%). There were no predictors of R0 or curative resection.

Adverse events

There were no episodes of clinically significant intra-procedural bleeding, delayed bleeding, delayed perforation, or stenosis.

Intra-procedural perforation occurred in four cases (26.7%). All were managed conservatively at the time of the index-ESD, with through-the-scope endoscopic clip closure performed successfully in three cases. All four patients were admitted to the hospital for close observation. In addition to standard care with IV fluids and PPI therapy, they were started on IV antibiotics. Three of the four patients were discharged the next day. The fourth case (► **Fig. 3**) involved significant submucosal fibrosis due to a previous attempt at resection with EMR. During traction-assisted ESD, two small areas of perforation were identified and promptly closed with an over-the-scope clip (OTSC). Cross-sectional imaging confirmed the presence of capno-peritoneum. The patient was managed conservatively in consulta-

► **Table 1** Patient and lesion characteristics.

Characteristics	Value
Age in years, median (IQR)	64 (58–70)
Sex n (%)	
▪ Male	9 (60%)
▪ Female	6 (40%)
NET location n (%)	
▪ Bulb	15 (100%)
Depth based on EUS examination n (%)	
▪ Layer 2	2 (13.3%)
▪ Layer 3	13 (86.7%)
Tumor morphology, n (%)	
▪ Paris 0-Is	9 (60%)
▪ Paris 0-IIa	6 (40%)
Ulceration of NET n (%)	1 (6.7%)
Tumor size on endoscopy, median mm (IQR)	10 (7–12)
IQR, interquartile range; EUS, endoscopic ultrasound; NET, neuroendocrine tumor.	

tion with the local upper gastrointestinal surgical team. Patient-controlled analgesia for pain and IV antibiotics were administered and patient was discharged on Day 7 post-ESD.

ESD was significantly longer in patients experiencing perforation (120.3 ± 81.1 minutes vs. 47.8 ± 26.8 minutes; $P=0.017$). By univariate analysis, the only risk factor for perforation was non-avidity on PET imaging D-NETs ($n=3$, 75% vs. $n=1$, 10%; $P=0.041$). However, when adjusted for patient age, gender, layer of origin, and presence of ulceration, there was no significance ($P=0.999$).

None of the patients with perforation required salvage surgical intervention and there were no long-term sequelae.

Short-term outcomes

Patients were followed up for a median of 19.9 months (IQR 10.3–49.3 months) after ESD (► **Table 2**). None of the patients showed evidence of local endoscopic recurrence, metachronous lymph node metastasis or distant metastasis on PET scan during the follow-up period.

Discussion

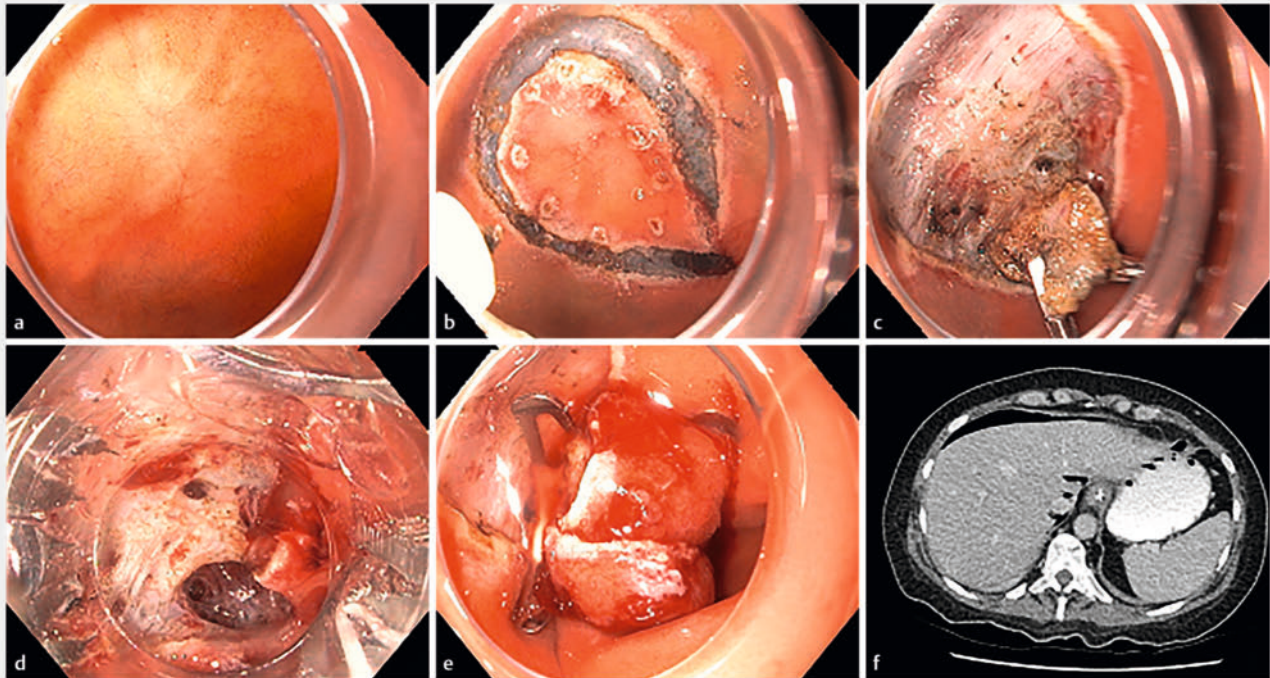
In this study, we assessed the procedural and short-term treatment outcomes of ESD for non-ampullary D-NETs. To the best of our knowledge, this is the largest case-series to date and the first in a Western setting. We showed that ESD is technically feasible in expert centers, achieving a 100% en bloc resection rate for D-NETs 10 to 15 mm. The rate of positive vertical margins was high (53.3%), although it did not translate into short-term local recurrence or lymph node/distant metastases at a median follow-up of 19.9 months. Reassuringly, all intra-proce-

► **Table 2** Procedural and short-term outcomes.

Characteristic/outcome	Value
ESD duration min (IQR)	60 (25–90)
Specimen size, median mm (IQR)	15 (15–20)
Technique n (%)	
▪ Conventional	9 (60%)
▪ Tunnelling	1 (6.7%)
▪ Traction	5 (33.3%)
WHO grade, n (%)	
▪ Grade 1	5 (33.3%)
▪ Grade 2	10 (66.7%)
▪ Grade 3	0 (0%)
Lymphovascular invasion n (%)	1 (6.7%)
Complications n (%)	
▪ Post procedural bleeding	0 (0%)
▪ Delayed bleeding	0 (0%)
▪ Intraprocedural perforation	4 (26.7%)
▪ Delayed perforation	0 (0%)
▪ Stenosis	0 (0%)
En bloc resection completed n (%)	15 (100%)
R0 margins n (%)	
▪ R0 horizontal margin	15 (100%)
▪ R0 vertical margin	7 (46.7%)
Curative resection n (%)	3 (20%)
Follow-up time median, months (IQR)	19.9 (10.3–49.3)
Local recurrence n (%)	0 (0%)
Lymph metastasis n (%)	0 (0%)
Distant metastasis n (%)	0 (0%)
IQR, interquartile range; WHO, World Health Organization.	

dural perforations were detected promptly within the index-ESD procedure and managed with clip closure, without any sequelae. While longer-term follow-up is required to determine the efficacy of ESD for D-NETs 10 to 15 mm, our findings suggest that this is a viable option to consider, particularly in those that are not candidates for surgical resection.

Although D-NETs are uncommon, they can lead to serious consequences, and thus, mandate intervention. While current guidelines recommend ER for non-ampullary D-NETs <10 mm [2, 24], for larger lesions it remains unclear whether a surgical or ER approach is superior [24]. Traditional ER methods, such as cold-snare polypectomy, EMR, band-EMR and BWR, are limited by high rates of positive margins [6, 11, 14, 15, 16, 17, 18, 19, 20, 21, 25]. One advantage of ESD over traditional ER techniques is that we were able to achieve 100% R0 horizontal mar-



► **Fig. 3** **a** Scar from prior D-NET removed by EMR with positive margins. **b** Circumferential incision completed. **c** Submucosal dissection with traction technique. **d** Two areas of deep mural injury (black arrows). **e** Over-the-scope endoscopic clip closure. **f** Evidence of pneumoperitoneum on CT post procedure.

gins. However, we noted that eight (53.3%) had a positive vertical margin. Because the submucosal layer of the duodenal cap is thin, subepithelial lesions such as D-NETs are in close proximity to the muscularis propria (► **Fig. 1**). Thus, to achieve a histologically free vertical margin is extremely challenging. Interestingly, the median length of the involved interface at this margin was only 0.9 mm. Furthermore, some D-NETs may be encapsulated [26, 27, 28, 29], and therefore, with resection it is possible that the margin is void of tumor cells. Reassuringly, disease-free survival in our cohort was 100%, with none of the patients in our series demonstrating local endoscopic recurrence or lymph node/distant metastasis during a median follow-up period of 19.9 months. Comparatively, the rates of local recurrence with EMR are reported upwards of 18% [6, 9, 10, 11, 12, 13, 30]. Although longer follow-up of data is required, our results demonstrate that the ESD of D-NETs 10 to 15 mm in size is technically feasible.

The low rate of curative resection (20%) achieved in our study was predominantly independent of the resection technique and rather driven by tumor biology, with 10 of the 12 non-curative cases (83.3%) due to WHO Grade 2 histology. Following discussion at local multi-disciplinary team meetings, surveillance was chosen in all non-curative cases due to a combination of factors, including patient age, underlying comorbidities, and personal preference. As aforementioned, there were no cases of endoscopic recurrence noted at follow-up, in keeping with studies in an Eastern setting [6, 20, 21, 25, 30]. As an alternative to ESD, endoscopic full-thickness resection

(EFTR) may be an option for D-NETs because it may address the issue of positive vertical margins. However, in comparison to ESD, precise control over depth and lateral margins of excision are not assured. Furthermore, the technique is limited by expense, lesion size, maneuverability of the device within the duodenum, and the risk of delayed perforation [19]. Alternatively, the risk of invasive surgery may well exceed the potential for recurrence after ESD for 10- to 15-mm D-NETs. Therefore, further studies are required, particularly comparing short- and long-term outcomes of ESD with EFTR.

ESD for non-ampullary D-NETs is more technically difficult than for stomach, esophageal or rectal lesions owing to the fact that the duodenal wall is very thin and the lumen is narrower, therefore affecting maneuverability [31, 32]. This may account for the higher rates of intra-procedural perforation experienced with ESD for D-NETs, ranging from 13% to 67% [20, 21, 22]. In the present study, our intra-procedural perforation rate was similar at 26.7%. Reassuringly, all perforations were identified and managed promptly. One case required an OTSC closure; however, this was a technically challenging case with significant submucosal fibrosis secondary to a prior EMR attempt. Importantly, there was no need for salvage surgery or long-term sequelae. Although non-avidity on PET imaging was identified as a risk factor for perforation, this is likely a Type 1 statistical error due to the small number of cases. Furthermore, there was no significance noted when adjusted for age, gender, layer of origin, and presence of ulceration. Thus, we have demonstrated that when ESD is performed by experi-

Table 3 Characteristics of 15 ESDs performed in 14 patients with D-NETs located in the duodenal bulb.

Case	Age (yr)	Sex	Size (mm)	Depth	Duration (min)	Method	Morphology (Paris)	Pathologic grade	LVI	R0 resection	Curative resection	Intra-procedural perforation
1	61	M	16†	SM	240	Tu	0-Is	1	No	No	No (R1, size)	Yes
2	77	M	15	MM	100	S	0-Is	1	No	Yes	Yes	No
3	68	M	4	SM	28	Tr	0-IIa	2	No	Yes	No (Grade 2)	No
4	58	F	10	SM	18	Tr	0-Is	2	Yes	Yes	No (Grade 2, LVI)	No
5	58	F	5	MM	73	Tr	0-Is	1	No	No	No (R1)	No
6	65	F	10	SM	25	S	0-IIa	2	No	No	No (Grade 2, R1)	No
7	82	M	15	SM	60	S	0-Is	2	No	No	No (Grade 2, R1)	No
8*	55	M	12	SM	60	S	0-Is	2	No	Yes	No (Grade 2)	No
9	55	M	8	SM	60	S	0-Is	2	No	No	No (Grade 2, R1)	No
10	70	F	7	SM	90	Tr	0-Is	2	No	Yes	No (Grade 2)	Yes
11	77	F	12	SM	20	S	0-Is	2	No	No	No (Grade 2, R1)	No
12	62	M	8	SM	91	Tr	0-IIa	2	No	No	No (Grade 2, R1)	Yes
13	64	F	10	SM	60	S	0-IIa	2	No	No	No (Grade 2, R1)	No
14	52	F	7	SM	60	S	0-IIa	1	No	Yes	Yes	Yes
15	65	F	10	SM	22	S	0-IIa	1	No	Yes	Yes	No

*Numbers 8 and 9 were the same patient.

†Specimen contained two separate NETs sized 15 and 16 mm.

ESD, endoscopic submucosal dissection; D-NET, duodenal neuroendocrine tumor; LVI, lymphovascular invasion; M, male; F, female; B, duodenal bulb; SM, submucosa; MM, muscular mucosa; S, standard ESD technique; Tr, traction technique; Tu, tunnelling technique.

enced endoscopists in tertiary referral centers, complications such as perforation can be readily managed, without long-term impact on the patient.

The present study had several limitations. First, it was a retrospective study that assessed the outcomes of ESD for D-NETs. Thus, we did not have access to data pertaining to the total number of D-NETs that were detected or resected by other means during the study period. Second, despite being multi-center, the overall number of patients was small. However, to the best of our knowledge, this is the largest number of patients undergoing ESD for D-NETs reported to date. Third, the follow-up period and method of follow-up were variable. The duration was somewhat insufficient for detecting metastasis in all cases. A larger number of patients enrolled prospectively involving multiple centers of excellence with standardized follow-up for a minimum of 5 years is required to best determine the efficacy and safety of ESD for D-NETs.

Conclusions

In conclusion, if there is no evidence of lymph node or distant metastasis during workup for a D-NET, ESD is an effective and safe ER technique when performed in an expert center. ESD should be the preferred modality for 10- to 15-mm D-NETs. Although tumor biology negatively impacted curative resection rates, current alternatives include highly comorbid surgeries. While the lack of short-term recurrence is encouraging, the impact of positive vertical margins with ESD is yet to be determined. Further studies are required, including with longer-term follow-up and comparisons with EFTR.

Conflict of Interest

Michael J. Bourke: Research Support: Olympus, Cook Medical, Boston Scientific. The remaining authors have no conflicts of interest to disclose.

References

- [1] Fitzgerald TL, Dennis SO, Kachare SD et al. Increasing incidence of duodenal neuroendocrine tumors: Incidental discovery of indolent disease? *Surgery* 2015; 158: 466–471 doi:10.1016/j.surg.2015.03.042
- [2] Delle Fave G, Kwekkeboom DJ, Van Cutsem E et al. ENETS Consensus Guidelines for the management of patients with gastroduodenal neoplasms. *Neuroendocrinology* 2012; 95: 74–87
- [3] Randle RW, Ahmed S, Newman NA et al. Clinical outcomes for neuroendocrine tumors of the duodenum and ampulla of Vater: a population-based study. *J Gastrointest Surgery* 2014; 18: 354–362 doi:10.1007/s11605-013-2365-4
- [4] Panzuto F, Ramage J, Pritchard DM et al. European Neuroendocrine Tumor Society (ENETS) 2023 Guidance Paper for Gastroduodenal NET G1–G3. *J Neuroendocrinology* 2023; 35: e13306 doi:10.1111/jne.13306
- [5] Kulke MH, Shah MH, Benson AB et al. Neuroendocrine tumors, version 1.2015. *Journal of the National Comprehensive Cancer Network* 2015; 13: 78–108 doi:10.6004/jnccn.2015.0011
- [6] Kim GH, Kim JI, Jeon SW et al. Endoscopic resection for duodenal carcinoid tumors: a multicenter, retrospective study. *J Gastroenterol Hepatol* 2014; 29: 318–324 doi:10.1111/jgh.12390
- [7] Dasari BVM, Al-Shakhshir S, Pawlik TM et al. Outcomes of surgical and endoscopic resection of duodenal neuroendocrine tumours (NETs): a systematic review of the literature. *J Gastrointest Surg* 2018; 22: 1652–1658 doi:10.1007/s11605-018-3825-7
- [8] Massironi S, Campana D, Partelli S et al. Heterogeneity of duodenal neuroendocrine tumors: an Italian multi-center experience. *Ann Surg Oncol* 2018; 25: 3200–3206 doi:10.1245/s10434-018-6673-5
- [9] Mahmud N, Tomizawa Y, Stashek K et al. Endoscopic resection of duodenal carcinoid tumors: a single-center comparison between simple polypectomy and endoscopic mucosal resection. *Pancreas* 2019; 48: 60–65
- [10] Gincul R, Ponchon T, Napoleon B et al. Endoscopic treatment of sporadic small duodenal and ampullary neuroendocrine tumors. *Endoscopy* 2016; 48: 979–986 doi:10.1055/s-0042-112570
- [11] Oono Y, Shinmura K, Hori K et al. Endoscopic submucosal resection using a ligation device without injection for duodenal neuroendocrine tumors. *Surg Endosc* 2019; 33: 2008–2014
- [12] Min B-H, Kim ER, Lee JH et al. Management strategy for small duodenal carcinoid tumors: does conservative management with close follow-up represent an alternative to endoscopic treatment? *Digestion* 2013; 87: 247–253
- [13] Park SB, Kang DH, Choi CW et al. Clinical outcomes of ligation-assisted endoscopic resection for duodenal neuroendocrine tumors. *Medicine* 2018; 97: e0533 doi:10.1097/MD.00000000000010533
- [14] Fujimoto A, Sasaki M, Goto O et al. Treatment results of endoscopic mucosal resection with a ligation device for duodenal neuroendocrine tumors. *Intern Med* 2019; 58: 773–777
- [15] Lee SW, Sung JK, Cho YS et al. Comparisons of therapeutic outcomes in patients with nonampullary duodenal neuroendocrine tumors (NADNETs): a multicenter retrospective study. *Medicine* 2019; 98: e16154
- [16] Tashima T, Ryozaawa S, Tanisaka Y et al. Endoscopic resection using an over-the-scope clip for duodenal neuroendocrine tumors. *Endosc Int Open* 2021; 9: E659–E666 doi:10.1055/a-1374-6141
- [17] Khara HS, Shovlin GJ, Johal AS et al. Endoscopic banding without resection (BWR) technique for treatment of diminutive neuroendocrine tumors in the duodenum. *Endosc Int Open* 2019; 7: E302–E307
- [18] Karagiannis S, Eshagzaïy K, Duecker C et al. Endoscopic resection with the cap technique of a carcinoid tumor in the duodenal bulb. *Endoscopy* 2009; 41: E288–E289
- [19] Bauder M, Schmidt A, Caca K. Endoscopic full-thickness resection of duodenal lesions—a retrospective analysis of 20 FTRD cases. *United European Gastroenterol J* 2018; 6: 1015–1021 doi:10.1177/2050640618773517
- [20] Suzuki S, Ishii N, Uemura M et al. Endoscopic submucosal dissection (ESD) for gastrointestinal carcinoid tumors. *Surg Endosc* 2012; 26: 759–763 doi:10.1007/s00464-011-1948-y
- [21] Nishio M, Hirasawa K, Ozeki Y et al. Short- and long-term outcomes of endoscopic submucosal dissection for non-ampullary duodenal neuroendocrine tumors. *Ann Gastroenterol* 2020; 33: 265–271 doi:10.20524/aog.2020.0477
- [22] Matsumoto S, Miyatani H, Yoshida Y. Endoscopic submucosal dissection for duodenal tumors: a single-center experience. *Endoscopy* 2013; 45: 136–137 doi:10.1055/s-0032-1310123
- [23] Nagtegaal ID, Odze RD, Klimstra D et al. The 2019 WHO classification of tumours of the digestive system. *Histopathology* 2020; 76: 182 doi:10.1111/his.13975
- [24] Delle Fave G, O'Toole D, Sundin A et al. ENETS Consensus Guidelines Update for Gastroduodenal Neuroendocrine Neoplasms. *Neuroendocrinology* 2016; 103: 119–124

- [25] Li Q-L, Zhang Y-Q, Chen W-F et al. Endoscopic submucosal dissection for foregut neuroendocrine tumors: an initial study. *World J Gastroenterol* 2012; 18: 5799 doi:10.3748/wjg.v18.i40.5799
- [26] Orttz H, Ortega JS, Bernat R et al. Carcinoids of the first part of the duodenum. *J Br Surgery* 1976; 63: 235–236
- [27] Bourke M. Endoscopic resection in the duodenum: current limitations and future directions. *Endoscopy* 2013; 45: 127–132 doi:10.1055/s-0032-1326177
- [28] Kaliounji A, Alkoutami S, Farraj M et al. A rare presentation of a duodenal neuroendocrine tumor. *Cureus* 2023; 15: doi:10.7759/cureus.33747
- [29] Neumann H, Ramesh J, Wilcox C et al. Resection of carcinoids in the duodenal bulb using the band ligation technique with the Duette mucosectomy device. *Endoscopy* 2013; 45: E365–E366
- [30] Kim SH, Park CH, Ki HS et al. Endoscopic treatment of duodenal neuroendocrine tumors. *Clin Endosc* 2013; 46: 656–661 doi:10.5946/ce.2013.46.6.656
- [31] Hoteya S, Furuhashi T, Takahito T et al. Endoscopic submucosal dissection and endoscopic mucosal resection for non-ampullary superficial duodenal tumor. *Digestion* 2017; 95: 36–42 doi:10.1159/000452363
- [32] Pérez-Cuadrado-Robles E, Quénéhervé L, Margos W et al. ESD versus EMR in non-ampullary superficial duodenal tumors: a systematic review and meta-analysis. *Endosc Int Open* 2018; 6: E998–E1007 doi:10.1055/a-0579-9050