



# Awake Uniportal VATS for the Evacuation of an Extensive, Superinfected Hemothorax in a Patient with Advanced Mediastinal SMARCA4-Deficient Tumor

Dominik Lobinger<sup>1</sup> Alicia Reiche<sup>1</sup> Andreas Hiebinger<sup>1</sup> Johannes Bodner<sup>1</sup>

<sup>1</sup>Department of Thoracic Surgery, München Klinik Bogenhausen, München, Germany

Thorac Cardiovasc Surg Rep 2023;12:e54–e56.

**Address for correspondence** Dominik Lobinger, MD, Department of Thoracic Surgery, München Klinik Bogenhausen, Engelschalkingerstraße 77, München 81925, Germany (e-mail: dominik.lobinger@muenchen-klinik.de).

## Abstract

### Keywords

- ▶ thoracic surgery
- ▶ mediastinal tumor
- ▶ minimally invasive surgery
- ▶ pathology
- ▶ pleural disease
- ▶ thoracoscopy/VATS

**Background** The so-called nonintubated or awake video-assisted thoracoscopic surgery (NIVATS) is performed on spontaneously breathing patients, which was shown to reduce postoperative complications and shorten hospital stay.

**Case Description** Awake uniportal VATS was indicated for the evacuation of an extensive, superinfected hemothorax with symptomatic mediastinal shift in a patient with advanced mediastinal SMARCA4-deficient tumor and declined condition, who did not allow a general anesthetic procedure and was not a candidate for extensive surgery.

**Conclusion** This short microinvasive intervention was a prerequisite to stabilize the threat to the patient's life and thus potentially enable any further tumor-specific therapy.

## Introduction

SMARCA4-deficient thoracic malignancies are rare sarcomas, identified by certain genetic mutations, particularly in the SMARCA4 gene, encoding important ATP-dependent transcription and chromatin reconfiguration mechanisms.<sup>1</sup> They were defined for the first time by transcriptome analysis and gene profiling among unclassified sarcomas only a few years ago and can be located in the mediastinum, pleura, or lung. On histopathology, the tumors showed rhabdoid to epithelioid patterns with high proliferation and mitotic activity.<sup>2,3</sup> Beside the typical poorly differentiated morphology, diagnosis is confirmed by the loss of SMARCA4 expression and further special immunohistochemistry staining procedures. In the literature, the affected patients are described as middle-aged, mostly between 40 and 50 years, and smoking is considered a possible risk factor. Despite novel and innovative therapeutic approaches, including systemic chemo- and immunotherapies, as well as radiotherapy, possibly by particle therapy, SMARCA4-deficient tumors show limited

treatment response and are associated with relatively poor prognosis.<sup>3,4</sup>

During recent years, minimally invasive procedures by video-assisted thoracoscopic surgery (VATS), and more recently robotic-assisted thoracoscopic surgery (RATS), have become the new standard for many indications in thoracic surgery.<sup>5</sup> VATS is most often performed via three access sites but can also be done via one single thoracotomy, called uniportal-VATS (uVATS).<sup>6</sup> Besides minimizing the pure surgical trauma, anesthesiological adoptions may also contribute to reduced overall procedural invasiveness and faster recovery. Nonintubated (NI) VATS are performed on nearly awake, spontaneously breathing patients.<sup>7</sup>

## Case Description

A male patient in his 50's was referred to our thoracic surgery department for further treatment of an extensive left-sided pleural effusion. The underlying diagnosis of an undifferentiated SMARCA4-deficient mediastinal tumor was made by

received

May 11, 2023

accepted after revision

September 11, 2023

accepted manuscript online

September 19, 2023

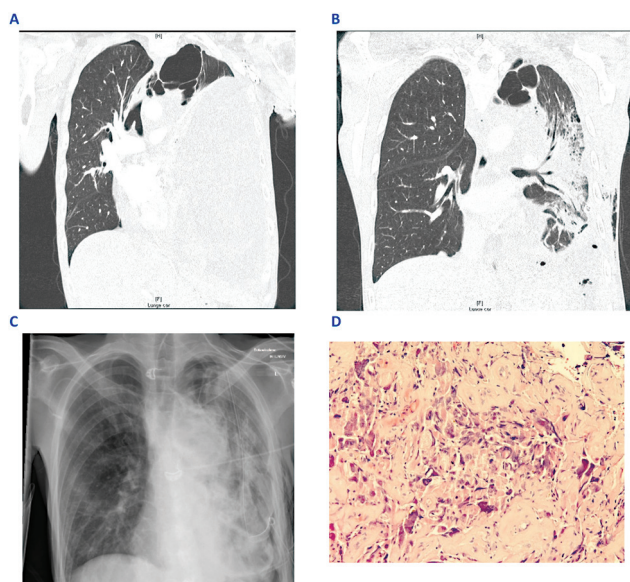
DOI <https://doi.org/10.1055/a-2178-0485>.

ISSN 2194-7635.

© 2023. The Author(s).

This is an open access article published by Thieme under the terms of the Creative Commons Attribution-NonDerivative-NonCommercial-License, permitting copying and reproduction so long as the original work is given appropriate credit. Contents may not be used for commercial purposes, or adapted, remixed, transformed or built upon. (<https://creativecommons.org/licenses/by-nc-nd/4.0/>)

Georg Thieme Verlag KG, Rüdigerstraße 14, 70469 Stuttgart, Germany



**Fig. 1** (A) Extensive, loculated left-sided pleural effusion with intense mediastinal shift presurgery in computed tomography (CT) scan. Postoperative (B) CT scan and (C) X-ray confirmed significantly decreased left-sided opacity with a, respectively, better expanded left lung and regression of the mediastinal shift. (D) Histological image of the described SMARCA4-deficient tumor with rhabdoid morphology (in cooperation with Prof. Helmberger and Prof. Nerlich).

radiologically guided biopsy during workup of extensive weight loss several months before. Initial systemic chemotherapy included carboplatin and etoposide; later pembrolizumab and paclitaxel were included. In addition, simultaneous radiation therapy with protons up to a cumulative dose of 50 Gy was performed at a particle irradiation center. On restaging, the mediastinal tumor showed minimal regression in size; a newly emerged left-sided pleural effusion was treated by insertion of a small chest tube, and the patient was discharged in a stable condition. Two days after an outpatient follow-up in cardiopulmonary stable status at our emergency unit, the patient re-presented himself in a very poor clinical condition, with tachycardia (~150 beats per minute), hypotension, severe dyspnea, and increased inflammation parameters (leukocytes 23.3/nL, C-reactive protein [CRP] 71 mg/L). On emergency computed tomography (CT) scan, an extensive, loculated left-sided pleural effusion with intense mediastinal shift was shown (► Fig. 1A). No immediate chest tube was reapplied due to effusion morphology with distinct loculations, solid tissue organizations, and potential postinterventional major bleeding. Suspecting an acute, potentially superinfected hemothorax (Hb level decreased from 8.8 to 5.7 g/dL) with progressive, hemodynamically effective mediastinal shift, we chose a minimally invasive thoracoscopic evacuation. Because of the patient's poor condition, the procedure was performed in close collaboration with the department of anesthesiology under local anesthesia in the awake and spontaneously breathing patient. After disinfection according to the WHO standards and sterile draping, a multilevel intercostal nerve infiltration with bupivacaine was performed. One single thoracocentesis was placed in the fifth

intercostal space at the anterior axillary line. After blunt opening of the pleura, a soft-tissue retractor was placed and the hemothorax was evacuated; approximately 2 L of mostly coagulated, organized effusion was aspirated. No active bleeding was detected. Pneumopleural adhesions were taken down and the lung was carefully mobilized. Only then, could the mediastinal tumor be exposed and approached, and several biopsies were taken (histological picture; see ► Fig. 1D). After insertion of a (24-Ch) chest drain and extensive irrigation, the wound was closed in several layers. The operative time was 30 minutes, during which the patient was breathing spontaneously and communicating. Postoperative CT scan and X-ray (► Fig. 1B and C) confirmed significantly decreased left-sided opacity with a better-expanded left lung and regression of the mediastinal shift. Postoperatively, the vital signs, especially the heart rate, normalized immediately and leukocytes decreased to 13.6/nL within 5 days. In addition, the patient's dyspnea improved gradually, allowing him to take short walks around the ward. The patient showed a clinically significantly improved condition after surgery, which allowed us to consider further tumor-specific therapies (including tumor debulking surgery) shortly after. Eleven days after the initial micro-invasive uniportal VATS approach in the awake and spontaneously breathing patient, a second elaborate surgery was performed under general anesthesia for evacuation of residual hemothorax and tumor debulking. After 20 days following the awake VATS intervention, the patient was able to leave the hospital in a reduced but stable general condition. The patient was seen again by his primary oncologist to consider further tumor-specific therapy.

## Discussion

Uniportal VATS on spontaneously breathing patients without any relaxation, with only minimal sedation and adequate local anesthesia ("awake uVATS"), is for now the least invasive concept in thoracic surgery. Although different types of thoracic procedures including extensive anatomic pulmonary resections have been shown to be feasible by this approach, awake uVATS is not an established standard approach and it remains unclear which patient groups benefit most from it.<sup>8</sup> It might be effective for operating on a specific cohort of severely comorbid patients with restricted cardio-respiratory function, which otherwise would not qualify for any type of surgery. Our oncological end-stage patient tolerated the procedure well and quickly recovered from the procedure despite his devastated condition. This case suggests that awake uVATS should be considered for short interventions in high-risk patients and could be a link between purely conservative and more invasive therapeutic strategies. Although awake uVATS may never be the routine standard approach in thoracic surgery, it is a very helpful tool in challenging situations and thus should be a part of the portfolio of every advanced thoracic unit.

## Funding

None.

**Conflict of Interest**

None declared.

**References**

- 1 Le Loarer F, Watson S, Pierron G, et al. SMARCA4 inactivation defines a group of undifferentiated thoracic malignancies transcriptionally related to BAF-deficient sarcomas. *Nat Genet* 2015; 47(10):1200–1205
- 2 Perret R, Chalabreysse L, Watson S, et al. SMARCA4-deficient thoracic sarcomas: clinicopathologic study of 30 cases with an emphasis on their nosology and differential diagnoses. *Am J Surg Pathol* 2019;43(04):455–465
- 3 Sauter JL, Graham RP, Larsen BT, Jenkins SM, Roden AC, Boland JM. SMARCA4-deficient thoracic sarcoma: a distinctive clinicopathological entity with undifferentiated rhabdoid morphology and aggressive behavior. *Mod Pathol* 2017;30(10):1422–1432
- 4 Nambirajan A, Jain D. Recent updates in thoracic SMARCA4-deficient undifferentiated tumor. *Semin Diagn Pathol* 2021;38(05):83–89
- 5 Jin R, Zheng Y, Yuan Y, et al. Robotic-assisted versus video-assisted thoracoscopic lobectomy: short-term results of a randomized clinical trial (RVlob trial). *Ann Surg* 2022;275(02):295–302
- 6 Bulgarelli Maqueda L, García-Pérez A, Minasyan A, Gonzalez-Rivas D. Uniportal VATS for non-small cell lung cancer. *Gen Thorac Cardiovasc Surg* 2020;68(07):707–715
- 7 Gelzinis T. The anesthetic management of patients undergoing nonintubated video-assisted thoracic surgery. *Curr Anesthesiol Rep* 2021;11(04):437–445
- 8 Zhang K, Chen HG, Wu WB, et al. Non-intubated video-assisted thoracoscopic surgery vs. intubated video-assisted thoracoscopic surgery for thoracic disease: a systematic review and meta-analysis of 1,684 cases. *J Thorac Dis* 2019;11(08):3556–3568