


A novel concept of passive loop-forming wire-guided biliary cannulation using an ultra-deep angled tip guidewire (with video)

OPEN
ACCESS

Authors

Tesshin Ban^{1,2} , Yoshimasa Kubota¹, Takuya Takahama¹, Shun Sasoh¹, Satoshi Tanida¹, Tomoaki Ando¹, Makoto Nakamura¹, Takashi Joh¹

Institutions

- 1 Department of Gastroenterology and Hepatology, Gamagori City Hospital, Gamagori, Japan
- 2 Department of Medicine, Division of Gastroenterology, Jichi Medical University, Shimotsuke, Japan

Key words

Pancreatobiliary (ERCP/PTCD), ERC topics, Quality and logistical aspects, Performance and complications

received 8.3.2023

accepted after revision 17.8.2023

accepted manuscript online 21.8.2023

Bibliography

Endosc Int Open 2023; 11: E963–E969

DOI 10.1055/a-2157-3941

ISSN 2364-3722

© 2023. The Author(s).

This is an open access article published by Thieme under the terms of the Creative Commons Attribution-NonDerivative-NonCommercial License, permitting copying and reproduction so long as the original work is given appropriate credit. Contents may not be used for commercial purposes, or adapted, remixed, transformed or built upon. (<https://creativecommons.org/licenses/by-nc-nd/4.0/>)

Georg Thieme Verlag KG, Rüdigerstraße 14,
70469 Stuttgart, Germany

Corresponding author

Dr. Tesshin Ban, Gamagori City Hospital, Department of Gastroenterology and Hepatology, Gamagori, Japan
venzosan0204@gmail.com

ABSTRACT

Background and study aims Wire-guided biliary cannulation (WGBC) is a standard technique during endoscopic retrograde cholangiopancreatography-related interventions. However, no dedicated guidewire is available. We investigated a novel “passive loop-forming WGBC” concept using a 0.035-inch ultra-deep angled tip guidewire.

Patients and methods This single-arm, single-center, retrospective study included consecutive 111 patients who underwent passive loop-forming WGBC as the first biliary intervention between October 2021 and December 2022.

Results WGBCs were completed within 5 minutes and overall were performed at a median papillary negotiation time of 81 seconds (interquartile range [IQR], 39–170) and 114 seconds (IQR, 49–303) in 83 (74.8%) and 106 (95.5%) cases, respectively. Logistic regression analysis identified age \geq 80 years (odds ratio [OR]: 3.56, 95% confidence interval [CI]: 1.12–11.31) and unintentional pancreatic guidewire insertion (OR: 17.67, 95% CI: 5.75–54.31) as significant risk factors for failed WGBC within 5 minutes. Among the 106 obtained cannulations, the guidewire leading part formed a small-looped tip and wide-looped body in 83 (78.3%) and 23 (21.7%) cases, respectively. Adverse events included post-procedure pancreatitis (2/111 [1.8%]) and guidewire penetration (3/111 [2.7%]).

Conclusions Passive loop-forming WGBC using an ultra-deep angled tip guidewire is a feasible procedure.

Introduction

Wire-guided biliary cannulation (WGBC) is recommended for post-endoscopic retrograde cholangiopancreatography (ERCP) pancreatitis (PEP) and biliary cannulation [1, 2]. Considering the papilla of Vater, WGBC can be achieved in two steps: 1) selection of the biliary narrow distal segment (NDS) at the biliary-pancreatic bifurcation; and 2) advancement of the guidewire through the NDS. The NDS, which includes dense inner mucosal

folds as check valves, may have a reverse-S or N shape [3, 4, 5]. Although previous studies have focused on the characteristics of the guidewire used for WGBC, a dedicated guidewire has not been established [6, 7, 8, 9]. WGBC is more difficult in patients with a larger papilla of Vater because the dense mucosal folds in the tortuous NDS interfere with guidewire advancement [10, 11, 12, 13]. A guidewire may be designed to take advantage of this interference, wherein its leading part would passively loop when entrapped in the NDS and advance

through. However, the inverting points of current guidewires are located over 1.0 cm from the tip [14, 15]; therefore, it is impossible to realize our concept in clinical practice. Hence, we used an ultra-deep angled tip guidewire (UD-GW), which actualizes our concept of passive loop-forming WGBC.

Patients and methods

Aim and study design

This was a single-arm, single-center, retrospective study aimed at evaluating passive loop-forming WGBC using a UD-GW.

Study population

After obtaining protocol approval from the Institutional Review Board of Gamagori City Hospital, we reviewed our ERCP database and full-length recorded videos of consecutive patients who underwent their first ERCP between October 2021 and December 2022.

The inclusion criteria comprised patients: (1) aged ≥ 20 years; (2) with a naïve papilla of Vater; (3) who provided written consent; and (4) who underwent ERCP-related biliary interventions.

The exclusion criteria comprised patients: (1) aged < 20 years; (2) with surgically altered gastrointestinal anatomy (excluding Billroth I reconstruction); (3) with a history of endoscopic sphincterotomy (EST)/endoscopic papillary large balloon dilation; (4) with a papilla of Vater with tumor invasion; (5) with gallstone pancreatitis in the active phase; (6) who underwent direct precutting; (7) with duodenoscope intubation failure; and (8) who were deemed ineligible owing to other reasons.

We extracted data on the following factors of interest from the ERCP database: age, sex, malignant biliary obstruction (MBO), endoscopist expertise, negotiation time for WGBC, completion of WGBC (< 5 minutes and overall in a single session), unintentional pancreatic guidewire insertion (p-GW), precutting, double guidewire technique (DGT), endoscopic pancreatic stenting (EPS), periampullary diverticulum (PAD) type, papilla of Vater bulge, and adverse events (AEs). Physicians with an experience of over 1,000 ERCP procedures and who were educated at a specialized facility were defined as advanced endoscopists; the remaining physicians were defined as trainees. The negotiation time for WGBC (in seconds) was obtained by subtracting timestamps indicating when the ERCP cannula was set on the papilla of Vater and when the guidewire was fluoroscopically advanced into the biliary tree. We inspected the guidewire tip behavior throughout the WGBC using a high-end, low X-ray-exposure, programmed fluoroscopic model (CUREVISTA Open, FUJIFILM, Tokyo, Japan) with aperture control and a four-way shielding curtain for minimizing X-ray exposure. The papilla of Vater bulge was defined based on the optical ratio of the oral protrusion length to the transverse papilla's orifice diameter. The ratio ≥ 2 was considered a large papilla, and the remaining was a non-large papilla [12]. The PAD was classified as follows: no PAD, type I (intra-diverticulum papilla), type II (papilla located at the diverticulum margin), and

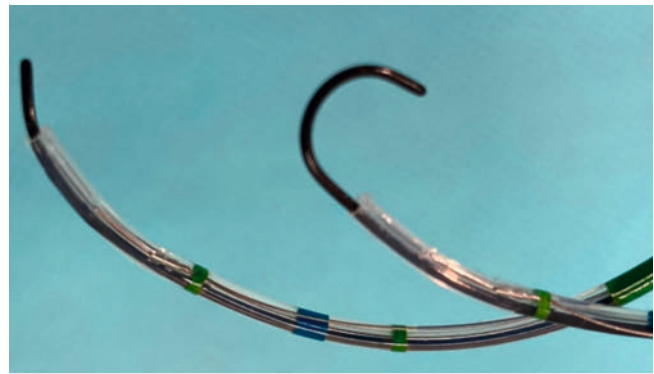
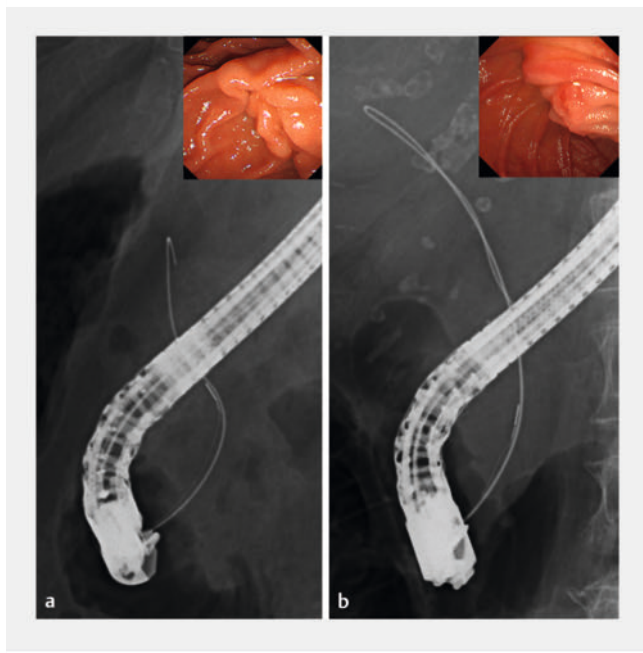


Fig. 1 A 0.035-inch, ultra-deep angled tip guidewire preloaded through a sphincterotomy knife cannula. Left, a 0.035-inch, ultra-deep angled tip guidewire is preloaded straight in the cannula. This guidewire advances straight when slightly protruded. Right, the guidewire quickly transforms into a looped feature when the inflection point is extruded from the cannula. This guidewire is entirely coated by a hydrophilic polymer and has an ultra-deep angled tip of 3.0 mm radius.

type III (papilla located close to the diverticulum) [16]. We defined types I and II as PAD-involved papillae.

Passive loop-forming WGBC using a UD-GW

Passive loop-forming WGBC was performed using a 0.035-inch UD-GW (Radifocus Guide Wire M, RF-GB35263; TERUMO, Tokyo, Japan) preloaded straight through an EST knife (Clever Cut 3 V, Olympus, Tokyo, Japan) with the guidewire top upwardly protruded 1.0 mm from the cannula. This guidewire is composed of an entirely hydrophilic polymer coated with an ultra-deep angled tip with a 3.0 mm radius (**Fig. 1**). A previous study demonstrated that the leading part of a guidewire formed a hairpin-shaped tip outside the cannula before WGBC [8]; conversely, we preloaded the tip of the UD-GW straight inside the cannula. Thereafter, the slightly upwardly protruding guidewire top from the cannula was gently advanced into the papillary orifice. Subsequently, the guidewire tip with the cannula was advanced to the first entrapment point in the NDS. Then, the leading part “passively” transformed into a small-looped tip (first break), followed by a wide-looped body (double break) in some cases, with simple pushing or in-and-out movements (**Fig. 2**, **Video 1**) [17]. Finally, the leading part of the guidewire advanced into the biliary tree. The timing for precutting was determined by referring to the definition of difficult biliary cannulation as follows [1]; mainly using needle knife fistulotomy (NKF) by salvage needle cannula if papillary negotiation lasted for more than 5 minutes, or transpancreatic sphincterotomy (TPS) by starting sphincterotomy knife cannula in cases of multiple p-GWs. Exceptionally, in cases with type I PAD, DGT was allowed before the precutting if papillary negotiation lasted for more than 5 minutes, followed by EPS whenever possible if the DGT resulted in failure or repetitive p-GW. Prophylactic administration of non-steroidal anti-inflammatory drugs, aggressive hydration, and sublingual glyceryl trinitrate [1] were unapproved in Japan.



► **Fig. 2** Passively looped guidewire tip during wire-guided biliary cannulation using an ultra-deep angled tip guidewire. **a** In a non-large papilla with the ratio of the oral protrusion length to the papilla's orifice diameter < 2 , a 0.035-inch ultra-deep angled tip guidewire (UD-GW) passively creates a small-looped tip (first break) where entrapped in the narrow distal segment (NDS). Thereafter, the guidewire tip typically passes through the NDS with this feature. **b** In a large papilla with the ratio ≥ 2 , the guidewire passively transforms into a wide-looped body (double break) following the small-looped tip (first break) when it advances through the NDS in some cases.

Outcome measures

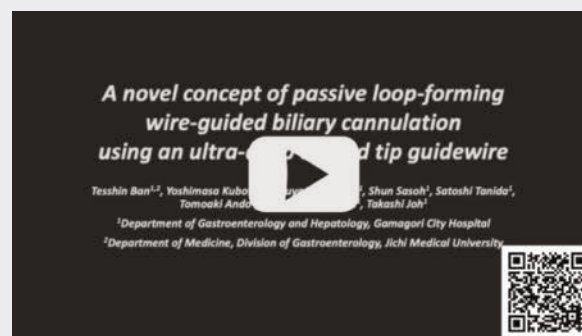
Primary outcome measures were WGBC completed within 5 minutes and overall (in one session), as well as the papillary negotiation time. Additionally, we evaluated the factors associated with WGBC failure within 5 minutes.

Secondary outcomes were as follows: appearance of the guidewire's leading part when it advanced through the NDS (small-looped tip or wide-looped body), under fluoroscopic imaging and AEs according to a previous lexicon [18].

Statistical analysis

Categorical variables (expressed as percentages) were dichotomized as follows: sex (man/woman); MBO (yes/no); expertise (advanced/trainee); WGBC completion < 5 minutes and overall (yes/no); unintentional p-GW (yes/no); precut (yes/no); PAD-involved papilla (yes/no); and papilla of Vater bulge (large/not large). Continuous variables are expressed as medians and interquartile ranges (IQRs). The Youden's index: the point revealing the maximum value of "sensitivity + specificity - 1", calculated using a receiver operating characteristic curve, determined the cutoff for the continuous variables. Potential risk factors for failed WGBC within 5 minutes, including age, sex, MBO, expertise, unintentional p-GW, precut, DGT, PAD, and papilla of Vater bulge, were estimated using the chi-square or

VIDEO



► **Video 1** A novel concept of passive loop-forming wire-guided biliary cannulation using an ultra-deep angled tip guidewire.

Fisher's exact tests. Statistical significance was set at $P < 0.05$. Finally, significant factors were determined using logistic regression analysis after controlling for potential confounders; these are expressed as odds ratios (ORs) with 95% confidence intervals (CIs). Secondary outcome variables are expressed as percentages. SPSS Statistics 28 (IBM Japan, Ltd., Tokyo, Japan) was used for statistical analyses.

Ethical statement

This study was conducted in accordance with the ethical standards of the responsible committee on human experimentation, and the Helsinki Declaration of 1964 and its later versions. An opt-out approach was used to obtain informed consent. The study protocol was approved by the Institutional Review Board of Gamagori City Hospital (Approval number: 367–9).

Results

Characteristics of passive loop-forming WGBC

The cohort comprised 111 patients (61 men [55.0%]); their characteristics are summarized in ► **Table 1**. The median age was 80 years (IQR, 72–85 years). The cohort included 24 MBOs (21.6%), 68 WGBCs performed by experienced hands (61.3%), 34 unintentional p-GW insertions (30.6%), 20 precuttings (18.0%), 10 DGTs (9.0%), three EPSs (2.7%), 31 PAD-involved papillae (27.9%), and 49 large papilla bulges (44.1%). Patients with a precut included nine NKF (8.1%), 10 TPSs (9.0%), and one with both (0.9%).

Passive loop-forming WGBC completed within 5 minutes and overall described with the papillary negotiation time, and factors for failed WGBC within 5 minutes

WGBC completed within 5 minutes, and overall were as follows: 83 cases (74.8%) at the median papillary negotiation time of 81 seconds (IQR, 39–170 s) and 106 cases (95.5%) at 114 seconds (IQR, 49–303 s), respectively. The median negotiation time in the cohort was 125 seconds (IQR, 51–389 s; ► **Table 2**). WGBC failed in five patients (4.5%); two patients with MBO were sal-

Table 1 Characteristics of passive loop-forming wire-guided biliary cannulation, N = 111.

Age	Years	Median (IQR)	80	(72–85)
Sex	Man	Number (%)	61	(55.0)
MBO	Yes	Number (%)	24	(21.6)
Expertise	Advanced	Number (%)	68	(61.3)
Unintentional p-GW	Yes	Number (%)	34	(30.6)
Precut	Yes	Number (%)	20	(18.0)
	NKF	Number (%)	9	(8.1)
	TPS	Number (%)	10	(9.0)
	NKF + TPS	Number (%)	1	(0.9)
DGT	Yes	Number (%)	10	(9.0)
EPS	Yes	Number (%)	3	(2.7)
PAD-involved papilla	Yes	Number (%)	31	(27.9)
Vater's papilla bulge	Large	Number (%)	49	(44.1)

N, total number; MBO, malignant biliary obstruction; p-GW, pancreatic guidewire insertion; DGT, double guidewire technique; EPS, endoscopic pancreatic stenting; PAD, periampullary diverticulum; NKF, needle knife fistulotomy; TPS, transpancreatic sphincterotomy; IQR, interquartile range.

Table 2 Achieved passive loop-forming wire-guided biliary cannulation, N = 111.

	WGBC				
	Obtained in five minutes		Obtained in overall		In cohort
Number (%)	83	(74.8%)	106	(95.5%)	111
Seconds, Median (IQR)	81	(39–170)	114	(49–303)	125 (51–389)

N, total number; WGBC, wire-guided biliary cannulation; IQR, interquartile range.

vaged under endoscopic ultrasonography-guided biliary drainage the following day, two with choledocholithiasis were managed with a second ERCP, and one with transient acute cholangitis underwent watchful waiting.

Univariate analysis revealed the following as significant factors for WGBC failure within 5 minutes (**Table 3**): age \geq 80 years (34.5% [20/58], $P = 0.019$), unintentional p-GW insertion (61.8% [21/34], $P < 0.001$), and a large papilla bulge (34.7% [17/49], $P = 0.041$). Logistic regression analysis revealed age \geq 80 years (OR: 3.56, 95% CI: 1.12–11.31) and unintentional p-GW insertion (OR: 17.67, 95% CI: 5.75–54.31) as significant risk factors for failed WGBC within 5 minutes (**Table 3**). We excluded precutting and DGT from the risk factor analyses for the following reasons: TPS and DGT were strongly related to unintentional p-GW, and NKF and DGT were introduced when 5 minutes had elapsed for WGBC.

Inspection of guidewire behavior in passive loop-forming WGBC under fluoroscopic imaging

Using fluoroscopic imaging, we inspected the passage of the guidewire through the NDS in all 106 completed WGBCs. The leading part of the guidewire advanced through the NDS and transformed into a small-looped tip and wide-looped body in

83 (78.3%) and 23 (21.7%) passages, respectively (**Fig. 2, Video 1**).

Adverse events

Six AEs (5.4%) were observed, including cases of two PEPs (1.8%, one mild and one moderate), one post-EST bleed (0.9%, moderate), and three guidewire penetrations (2.7%, mild). The case with moderate delayed post-EST bleeding (on Day 4) was managed with endoscopic hemostasis. The causes of mild and moderate PEP were suspected to be metallic stent-derived and unintentional p-GW. The cases of guidewire penetration comprised two with intra-diverticular penetration and one with extraluminal penetration. No sequelae or deaths occurred in this cohort.

Discussion

This study advocates for a new concept of passive loop-forming WGBC using a UD-GW. With this concept, the guidewire advanced through the NDS in 74.8% of patients (median time, 81 seconds) within 5 minutes and overall in 95.5% of patients (median time, 114 seconds); it subsequently transformed into a looped leading part (small-looped tip, 78.3%; wide-looped

► **Table 3** Risk factors for failed biliary cannulation within 5 minutes under passive loop-forming wire-guided biliary cannulation.

		Failed WGBC		Univariate	Multivariate		
		n/N, %		P value	P value	Odds ratio (95% CI)	
Age	< 80 years	8/53	(15.1)	0.019*	0.031*	3.56	(1.12–11.31)
	≥ 80 years	20/58	(34.5)				
Sex	Female	13/50	(26.0)	0.865			
	Male	15/61	(24.6)				
MBO	Yes	9/24	(37.5)	0.118			
	No	19/87	(21.8)				
Expertise of endoscopist	Trainee	9/43	(20.9)	0.407			
	Advanced	19/68	(27.9)				
Unintentional p-GW	Yes	21/34	(61.8)	< 0.001*	< 0.001*	17.67	(5.75–54.31)
	No	7/77	(9.1)				
PAD-involved papilla	Yes	8/31	(25.8)	0.930			
	No	20/80	(25.0)				
Vater's papilla bulge	Not large	11/62	(17.7)	0.041*	0.109	2.45	(0.82–7.32)
	Large	17/49	(34.7)				

WGBC, wire-guided biliary cannulation; N, total number; n, number; MBO, malignant biliary obstruction; p-GW, pancreatic guidewire insertion; PAD, periampullary diverticulum; CI, confidence interval. * $P < 0.05$.

body, 21.7%). An unintentional p-GW was the greatest risk factor for WGBC failure within 5 minutes with an OR of 17.67.

Compared to a previous meta-analysis on wire-guided cannulation, the primary WGBC rate was lower in our study (85.3% vs. 74.8%) because we introduced the early precutting algorithm [1]; however, the overall WGBC rate was similar (93.9% vs. 95.5%). Notably, we obtained a 95.5% WGBC rate with a median time of 114 seconds.

Densely grown mucosal folds in the NDS were recognized with a mean of 3.1 mm from the top of the Vater's orifice. These folds were distributed over a mean distance of 7.3 mm along the NDS. In addition, the closer the orifice is, the higher these folds grow [5]. Based on these anatomical structures, the guidewire obstruction could develop within 10 mm from the Vater's orifice. Therefore, the first looping point of the guidewire should be within 10 mm from its top. Moreover, the second looping point should be created without coiling up. Several high-performance 0.025-inch guidewires, including MICHISUJI, Jagwire, M-through, VisiGlide 2, Revowave, and Pathcorse have emerged to create the passive looped guidewire in the luminal structure. However, these guidewires have wide-radius tips. Therefore, these guidewire tips tend to advance linearly in the NDS, which might cause guidewire penetration (► **Video 1**). An in vitro study demonstrated that these high-performance guidewires, with a looping point of over 10 to 50 mm from the guidewire top, could resist transformation into a wide-looped body and become coiled up [14] (► **Video 1**).

In the passive loop-forming WGBC, the UD-GW with a tip of a 3.0 mm radius is straight preloaded into the cannula with the

guidewire top protruding 1.0 mm from it. Then, the tip quickly and consistently inverted when we advanced the preloaded guidewire tip beyond the outside of the cannula. Based on our hypothesis, the leading part quickly could transform into a small-looped tip (first break) and advance with this feature if the distance between the entrapped point and the bile duct was short. Alternatively, the leading part gradually and consecutively could create a subsequent wide-looped body (double break) if this length was long (► **Video 1**). Theoretically, the guidewire top possibly could advance into the bile duct without looped feature (without entrapment) if this length was extremely short (unfortunately, we did not encounter this case in this study). However, there is no in vitro study of the 0.035-inch UD-GW regarding the appropriate looping point and guidewire stiffness for the first-breaking and double-breaking without coiling up.

We observed unintentional p-GW (a well-known risk factor for PEP) in 30.6% of the patients [2]. The incidence of unintentional p-GW was comparable to that of 39.0% in a well-designed multicenter prospective study [19]. Anatomically, the distal bile duct and main pancreatic duct merge to form the "common channel" with a 3.0- to 8.0-mm length in most patients (68.0%-86.0%) [3]. Therefore, when the mucosal folds entrap the guidewire top before this merging into the sigmoidal common channel, the guidewire is potentially flicked off into the pancreatic duct when creating the looped feature. This unintentional p-GW significantly delayed WGBC attainment (within 5 minutes) in our study. However, the unintentional p-GW is a secondary surrogate indicator developed by the microstruc-

tures inside the papilla, including its actual luminal length, diameter, curvature, and mucosal fold density/ length. Therefore, accurately, we should consider these microstructural factors for analysis due to the impacts on the time for obtaining the WGBC and guidewire entrapment with looped feature (small-looped tip/wide-looped body). However, examining these microstructures might be possible only in patients undergoing autopsy. Therefore, we used this surrogate indicator of unintentional p-GW as with the optical feature of the papilla bulge.

In previous studies, a surrogate optical feature of a large papilla bulge was a significant risk factor for delayed WGBC attainment [10, 11, 12, 13]. However, in the present study, a large papilla bulge was an insignificant risk factor for WGBC failure within 5 minutes using the logistic regression analysis. In the post-hoc power analysis, the statistical power ($1-\beta$) was calculated to be 0.53 using the parameters of sample size = 111, α error = 0.05, degrees of freedom = 1, and effect size = 0.194. It was potentially underpowered due to the small sample size and effect size.

Despite occurrence of 30.6% of unintentional p-GW, the PEP occurred at a rate of 1.8% (0.9% of p-GW-induced PEP) in this study. This may be because we inspected the guidewire behavior throughout WGBC using fluoroscopy, and quickly withdrew the guidewire when unintentional p-GWs were recognized. The looped leading part of the guidewire and cautious fluoroscopic inspection can be protective against pancreatic parenchymal injuries. In addition, in patients with multiple unintentional p-GWs, early TPS was attempted using the starting knife cannula. However, avoiding possible unintentional p-GW is an issue in passive loop-forming WGBC with this UD-GW. In the passive loop-forming WGBC, concomitant advancement of the cannula top beyond the biliary-pancreatic bifurcation could be a clue for avoiding the unintentional p-GW. Eventually, an appropriate radius and stiffness of the UD-GW should be assessed for the passive loop-forming WGBC.

Guidewire-specific penetration develops in 2.0% to 3.4% of cases [20, 21], and significantly increases to 12.5% in cases of PAD-involved papilla [21]. In the present study, the overall incidence of guide penetration was 2.7% (3/111). All three guidewire penetrations were only observed in PAD-involved papilla [3/31(9.7%)], which developed before the guidewire transformed into a looped feature.

The WGBC using a hoop-shaped (closed-looped) tip guidewire significantly decreased the PEP rate compared with the standard contrast-assisted biliary cannulation (5.0% vs. 12.0%). Furthermore, it demonstrated the equivalent primary biliary cannulation rate (81.0% versus 73.0%) [22]. Comparing a hoop-shaped tip guidewire with a straight-tip one, the primary biliary cannulation rate (86.5% versus 77.1%) and PEP rate (5.2% versus 8.3%) were equivalent. However, the rate of unintentional p-GW significantly decreased (14.6% versus 28.1%) [9]. Although the hoop-shaped tip guidewire mimics the UD-GW regarding the looped leading part, subsequent passive transformation into a wide-looped body (double break) of the hoop-shaped tip guidewire is challenging due to its rigid stiffness. Moreover, this ready-made closed-looped feature with a 2.0-mm radius is unfit for the quite small papilla orifice. In contrast,

the straight preloaded UD-GW enabled advancement even in this minimum papilla orifice. The advantages of hoop-shaped tip guidewire compared with the UD-GW might be as follows. First, this ready-made closed-looped feature could be atraumatic for the PAD-involved papilla, avoiding guidewire penetration [9, 22]. Our study included three cases (2.7%) of guidewire penetration, all in the PAD-involved papilla. Second, the rate of unintentional p-GW might decrease (14.6% vs. 30.6%) [9]. However, both the hoop-shaped tip guidewire and UD-GW were unfit for seeking the biliary tree and cystic duct.

Conclusions

In conclusion, passive loop-forming WGBC using a UD-GW is feasible in terms of WGBC achievement and AEs. However, in 25.2% of the cohort, the looped guidewire could not advance into the bile duct at 5 minutes. Microstructures of the papilla vary depending on individual differences. Eventually, an abundant lineup of the guidewire radius/ stiffness would facilitate the WGBC. Subsequent studies on head-to-head comparisons among novel UD-GW and conventional guidewires are warranted to confirm this concept because this study was limited by a small sample size and single-center and single-armed study design.

Conflict of Interest

The authors declare that they have no conflict of interest.

References

- [1] Testoni PA, Mariani A, Aabakken L et al. Papillary cannulation and sphincterotomy techniques at ERCP: European Society of Gastrointestinal Endoscopy (ESGE) Clinical Guideline. *Endoscopy* 2016; 48: 657–683 doi:10.1055/s-0042-108641
- [2] Dumonceau JM, Kapral C, Aabakken L et al. ERCP-related adverse events: European Society of Gastrointestinal Endoscopy (ESGE) guideline. *Endoscopy* 2020; 52: 127–149 doi:10.1055/a-1075-4080
- [3] Paulsen FP, Bobka T, Tsokos M et al. Functional anatomy of the papilla Vateri: biomechanical aspects and impact of difficult endoscopic intubation. *Surg Endosc* 2002; 16: 296–301 doi:10.1007/s00464-001-9073-y
- [4] Horiguchi S, Kamisawa T. Major duodenal papilla and its normal anatomy. *Dig Surg* 2010; 27: 90–93 doi:10.1159/000288841
- [5] Purvis NS, Mirjalili SA, Stringer MD. The mucosal folds at the pancreaticobiliary junction. *Surg Radiol Anat* 2013; 35: 943–950 doi:10.1007/s00276-013-1128-y
- [6] Bassan MS, Sundaralingam P, Fanning SB et al. The impact of wire caliber on ERCP outcomes: a multicenter randomized controlled trial of 0.025-inch and 0.035-inch guidewires. *Gastrointest Endosc* 2018; 87: 1454–1460 doi:10.1016/j.gie.2017.11.037
- [7] Kitamura K, Yamamiya A, Ishii Y et al. 0.025-inch vs 0.035-inch guide wires for wire-guided cannulation during endoscopic retrograde cholangiopancreatography: a randomized study. *World J Gastroenterol* 2015; 21: 9182–9188
- [8] Tsuchiya T, Itoi T, Maetani I et al. Effectiveness of the J-tip guidewire for selective biliary cannulation compared to conventional guidewires

- (the JANGLE study). *Dig Dis Sci* 2015; 60: 2502–2508 doi:10.1007/s10620-015-3658-0
- [9] Hwang JC, Yoo BM, Yang MJ et al. A prospective randomized study of loop-tip versus straight-tip guidewire in wire-guided biliary cannulation. *Surg Endosc* 2018; 32: 1708–1713 doi:10.1007/s00464-017-5851-z
- [10] Haraldsson E, Kylänpää L, Grönroos J et al. Macroscopic appearance of the major duodenal papilla influences bile duct cannulation: a prospective multicenter study by the Scandinavian Association for Digestive Endoscopy Study Group for ERCP. *Gastrointest Endosc* 2019; 90: 957–963 doi:10.1016/j.gie.2019.07.014
- [11] Chen PH, Tung CF, Peng YC et al. Duodenal major papilla morphology can affect biliary cannulation and complications during ERCP, an observational study. *BMC Gastroenterol* 2020; 20: 310
- [12] Watanabe M, Okuwaki K, Kida M et al. Transpapillary biliary cannulation is difficult in cases with large oral protrusion of the duodenal papilla. *Dig Dis Sci* 2019; 64: 2291–2299
- [13] Canena J, Lopes L, Fernandes J et al. Influence of a novel classification of the papilla of Vater on the outcome of needle-knife fistulotomy for biliary cannulation. *BMC Gastroenterol* 2021; 21: 147 doi:10.1186/s12876-021-01735-3
- [14] Ogura T, Ueno S, Okuda A et al. Experimental study of loop shape using 0.025-inch ERCP guidewires (with videos). *Endosc Int Open* 2021; 9: E427–E437
- [15] Ogura T, Yamada M, Nishioka N et al. Gastrointestinal: knuckle guidewire insertion: safe techniques of guidewire insertion into the pancreatobiliary tract using a novel 0.025-inch guidewire. *J Gastroenterol Hepatol* 2020; 35: 707
- [16] Boix J, Lorenzo-Zúñiga V, Añãos F et al. Impact of periampullary duodenal diverticula at endoscopic retrograde cholangiopancreatography: a proposed classification of periampullary duodenal diverticula. *Surg Laparosc Endosc Percutan Tech* 2006; 16: 208–211 doi:10.1097/00129689-200608000-00002
- [17] Lella F, Bagnolo F, Colombo E et al. A simple way of avoiding post-ERCP pancreatitis. *Gastrointest Endosc* 2004; 59: 830–834 doi:10.1016/s0016-5107(04)00363-3
- [18] Cotton PB, Eisen GM, Aabakken L et al. A lexicon for endoscopic adverse events: report of an ASGE workshop. *Gastrointest Endosc* 2010; 71: 446–454 doi:10.1016/j.gie.2009.10.027
- [19] Sasahira N, Kawakami H, Isayama H et al. Early use of double-guidewire technique to facilitate selective bile duct cannulation: the multicenter randomized controlled EDUCATION trial. *Endoscopy* 2015; 47: 421–429 doi:10.1055/s-0034-1391228
- [20] Kawakami H, Maguchi H, Mukai T et al. A multicenter, prospective, randomized study of selective bile duct cannulation performed by multiple endoscopists: the BIDMEN study. *Gastrointest Endosc* 2012; 75: 362–372 doi:10.1016/j.gie.2011.10.012
- [21] Takano Y, Nagahama M, Yamamura E et al. Perforation of the papilla of Vater in wire-guided cannulation. *Can J Gastroenterol Hepatol* 2016; 2016: 5825230 doi:10.1155/2016/5825230
- [22] Masci E, Mangiavillano B, Luigiano C et al. Comparison between loop-tip guidewire-assisted and conventional endoscopic cannulation in high risk patients. *Endosc Int Open* 2015; 3: E464–E470