Accepted Manuscript online: 2023-08-10 Article published online: 2023-09-28

Prevalence of sonographic signs in women with uterine sarcoma: a systematic review and meta-analysis

Prävalenz sonografischer Zeichen bei Frauen mit Uterusssarkom: Eine systematische Übersicht und Meta-Analyse

Authors

Antonio Raffone[1], Diego Raimondo[2], Daniele Neola[3], Antonio Travaglino[4], Marisol Doglioli[1, 2], Marco Ambrosio[5], Ivano Raimondo[6], Lucia De Meis[2], Luigi Carlo Turco[4], Francesco Cosentino[7], Renato Seracchioli[1, 2], Paolo Casadio[2], Antonio Mollo[8]

Affiliations

1 Department of Medical and Surgical Sciences (DIMEC), University of Bologna, Bologna, Italy
2 Division of Gynaecology and Human Reproduction Physiopathology, IRCCS Azienda Ospedaliero-Universitaria di Bologna, Bologna, Italy
3 Department of Neuroscience, Reproductive Sciences and Dentistry, University of Naples Federico II, Napoli, Italy
4 Department of Woman's Health Science, University Hospital Agostino Gemelli, Roma, Italy
5 Mother-Child Department, Azienda Unità Sanitaria Locale di Bologna, Bologna, Italy
6 Department of Medical, Surgical and Experimental Sciences, University of Sassari, Sassari, Italy
7 Department of Medicine and Health Science, University of Molise, Campobasso, Italy
8 Department of Medicine, Surgery and Dentistry "Schola Medica Salernitana", University of Salerno, Fisciano, Italy

Key words

malignancy, myomata, leiomyosarcoma, prediction, preoperative assessment

received 24.03.2023
accepted 10.08.2023
accepted manuscript online 10.08.2023
published online 28.09.2023

Bibliography

Ultraschall in Med 2024; 45: 293–304
DOI 10.1055/a-2151-9205
ISSN 0172-4614

Georg Thieme Verlag KG, Rüdigerstraße 14, 70469 Stuttgart, Germany

Correspondence

Dr. Diego Raimondo
Division of Gynaecology and Human Reproduction Physiopathology, IRCCS Azienda Ospedaliero-Universitaria di Bologna, 40138 Bologna, Italy
raidie@libero.it

Additional material is available at https://doi.org/10.1055/a-2151-9205.

ABSTRACT

Objective To assess the prevalence of sonographic signs in women with uterine sarcoma.

Materials and Methods A systematic review and meta-analysis were performed. Five electronic databases were searched from inception to June 2022 for all studies allowing calculation of the prevalence of sonographic signs in women with uterine sarcoma. Pooled prevalence with 95 % confidence intervals was calculated for each sonographic sign and was a priori defined as "very high" when it was ≥ 80 %, "high" when it ranged from 80 % to 70 %, and less relevant when it was ≤ 70 %.

Results 6 studies with 317 sarcoma patients were included. The pooled prevalence was:

- 25.0 % (95 %CI:15.4–37.9 %) for absence of visibility of the myometrium
- 80.5 % (95 %CI:74.8–85.2 %) for solid component
- 78.3 % (95 %CI:59.3–89.9 %) for inhomogeneous echogenicity of solid component
- 47.9 % (95 %CI:41.1–54.8 %) for cystic areas
- 80.7 % (95 %CI:68.3–89.0 %) for irregular walls of cystic areas
- 72.3 % (95 %CI:16.7–97.2 %) for anechoic cystic areas
- 54.8 % (95 %CI:34.0–74.1 %) for absence of shadowing
- 73.5 % (95 %CI:43.3–90.9 %) for absence of calcifications
- 48.7 % (95 %CI:18.6–79.8 %) for color score 3 or 4
- 47.3 % (95 %CI:37.0–57.8 %) for irregular tumor borders
- 45.4 % (95 %CI:27.6–64.3 %) for endometrial cavity not visualizable
- 10.9 % (95 %CI:3.5–29.1 %) for free pelvic fluid
- 6.4 % (95 %CI:1.1–30.2 %) for ascites
- 21.2 % (95 %CI:2.1–76.8 %) for intracavitary process
- 81.5 % (95 %CI:56.1–93.8 %) for singular lesion.

Conclusion Solid component, irregular walls of cystic areas, and singular lesions are signs with very high prevalence, while inhomogeneous echogenicity of solid component, anechoic cystic areas, and absence of calcifications are signs with high prevalence. The remaining signs were less relevant.

ZUSAMMENFASSUNG

Ziel Bewertung der Prävalenz sonografischer Zeichen bei Frauen mit Uterussarkom.

Material und Methoden Es wurden eine systematische Überprüfung und eine Meta-Analyse durchgeführt. Fünf elektronische Datenbanken wurden von Anfang bis Juni 2022 nach allen Studien durchsucht, die eine Berechnung der Prävalenz sonografischer Zeichen bei Frauen mit Uterussarkom ermöglichten. Die gepoolte Prävalenz mit 95 %-Konfidenzintervallen wurde für jedes sonografische Zeichen berechnet und a priori als „sehr hoch" definiert, wenn sie ≥ 80 % war, „hoch", wenn sie zwischen 80 % und 70 % lag, und als weniger relevant, wenn sie ≤ 70 % lag.

Ergebnisse Es wurden 6 Studien mit 317 Sarkom-Patientinnen eingeschlossen. Die gepoolte Prävalenz betrug:

- 25,0 % (95 %-CI: 15,4–37,9 %) bei fehlender Sichtbarkeit des Myometriums
- 80,5 % (95 %-CI: 74,8–85,2 %) für eine solide Komponente
- 78,3 % (95 %-CI: 59,3–89,9 %) für inhomogene Echogenität der soliden Komponente
- 47,9 % (95 %-CI: 41,1–54,8 %) für zystische Bereiche
- 80,7 % (95 %-CI: 68,3–89,0 %) für unregelmäßige Wände der zystischen Bereiche
- 72,3 % (95 %-CI: 16,7–97,2 %) für echofreie zystische Bereiche
- 54,8 % (95 %-CI: 34,0–74,1 %) für das Fehlen von Schattenbildung für keine Abschattung
- 73,5 % (95 %-CI: 43,3–90,9 %) für das Fehlen von Verkalkungen
- 48,7 % (95 %-CI: 18,6–79,8 %) für den Farbscore 3 oder 4
- 47,3 % (95 %-CI: 37,0–57,8 %) für unregelmäßige Tumorgrenzen
- 45,4 % (95 %-CI: 27,6–64,3 %) für eine nicht sichtbare Gebärmutterhöhle
- 10,9 % (95 %-CI: 3,5–29,1 %) für freie Beckenflüssigkeit
- 6,4 % (95 %-CI: 1,1–30,2 %) für Aszites
- 21,2 % (95 %-CI: 2,1–76,8 %) für einen intrakavitären Prozess
- 81,5 % (95 %-CI: 56,1–93,8 %) für singuläre Läsionen.

Schlussfolgerung Zeichen mit sehr hoher Prävalenz sind eine solide Komponente, unregelmäßige Wände der zystischen Bereiche und singuläre Läsionen, während Zeichen mit hoher Prävalenz eine inhomogene Echogenität der soliden Komponente, echofreie zystische Bereiche und das Fehlen von Verkalkungen sind. Die übrigen Zeichen waren weniger relevant.

Introduction

Uterine sarcomas are rare malignant mesenchymal lesions, constituting 1 % of female genital tract malignancies and 3–7 % of all uterine malignancies [1]. They are aggressive neoplasias, with a 5-year overall survival rate which ranges from 0 % to 68 % for leiomyosarcomas and is even lower for undifferentiated sarcomas [2].

The preoperative differentiation between these tumors and benign lesions, such as uterine leiomyomas, is an unsolved issue, since uterine sarcomas and myomas can present similar symptoms and overlapping imaging features [3].

Ultrasound is the first-line imaging technique within the diagnostic workup of myometrial lesions, as it is noninvasive, quick, cheap, and widely available in clinical practice [4]. Uterine fibroids have been described as well-defined round lesions, often showing shadows at the edge of the lesion and/or inside it, with circumferential flow on color or power Doppler imaging. On the other hand, uterine sarcomas have been described as purely myometrial lesions, typically single and large, with a regular or irregular outline, frequent irregular anechoic areas, and irregular vascularization [4]. Unfortunately, ultrasound's diagnostic value in the detection of uterine sarcomas is affected by common overlap in ultrasound appearance between degenerating leiomyomas and malignancy [5]. Therefore, ultrasound's value for uterine sarcoma is still uncertain in clinical practice.

The aim of this study was to assess the prevalence of sonographic signs in women with uterine sarcomas through a systematic review and meta-analysis of the literature.

Materials and methods

Study protocol

Two authors independently concluded each study step according to an *a priori* defined study protocol. In the case of disagreements, a discussion among all authors was adopted as a solution. The Preferred Reporting Item for Systematic Reviews and Meta-analyses (PRISMA) statement and checklist [6] was followed for reporting the whole study.

We searched 5 electronic databases (MEDLINE, Web of Sciences, Google Scholar, Scopus, and ClinicalTrial.gov) from their inception to June 2022, using a combination of the following words: "uter*", "cancer"; "carcinoma"; "tumor"; "tumour"; "malignancy"; "neoplas*"; "myom*"; "leiomyom*"; "sarcoma", "different*"; "distinguis*"; "diagnos*"; "preoperat*"; "before surgery"; "presurg*; "ultrasound"; "ultrasonograph*"; "ultrasound"; "sonograph*"; "scan"; "sign*".

The list of references for each eligible study were also screened for missed studies.

We included all peer-reviewed studies that allowed calculation of the pooled prevalence of sonographic signs in women with uterine sarcomas. In particular, we included all studies that reported the presence or absence of the different sonographic signs and an unbiased postoperative histological diagnosis of uterine sarcoma.

We *a priori* defined reviews and case reports as exclusion criteria.

Data extraction

Original data from included studies were extracted without modification and according to the PICO items [6]. The "population" of our study was women with histologically confirmed uterine sarcoma; "intervention" (or risk factor) was the presence of each ultrasound sign; "comparator" was not applicable due to the study design (i. e., systematic review and meta-analysis of prevalence); "outcomes" were the prevalence of each assessed sonographic sign in women with histologically confirmed uterine sarcomas.

Data extracted from the study by Chiappa *et al.* [7] for meta-analysis referred to subjective ultrasound evaluation before application of radiomics and machine-learning models.

In the study from Bonneau *et al.* [8], 4 cases of STUMP were considered sarcomas and it was not possible to exclude them from quantitative analysis.

Risk of bias assessment

The Methodological Index for Non-Randomized Studies (MINORS) was followed to assess the risk of bias within studies [9]. Six applicable domains were evaluated: Aim (if the study had a clearly stated aim); inclusion of consecutive patients (if patient selection included all eligible patients during the study period); prospective collection of data (if data collection was performed following a protocol *a priori* defined); endpoints appropriate to the aim (if data about the presence of sonographic signs in women with histologically confirmed uterine sarcomas were reported); unbiased assessment of the study endpoints (if assessment of sonographic signs and histological examination were unbiased, e. g., ultrasound performed by expert sonographers, blinded evaluation of histological examination by at least 2 pathologists, and use of updated pathological criteria).

The risk of bias was categorized as "high risk", "unclear risk", or "low risk" if data about each domain were "reported but inadequate", "not reported", or "reported and adequate", respectively.

Data analysis

The prevalence of each assessed sonographic sign in women with histologically confirmed uterine sarcoma was calculated as the number of women with the specific sonographic sign divided by the total number of women with histologically confirmed uterine sarcomas. Prevalence was calculated as individual and pooled estimates, and graphically reported on forest plots with 95 % confidence intervals (CI). Prevalence was *a priori* defined as "very high" when it was ≥ 80 %, "high" when it ranged from 80 % to 70 %, and less relevant when it was ≤ 70 %.

Statistical heterogeneity among the included studies was evaluated by the inconsistency index I^2. In detail, heterogeneity was judged as null for $I^2 = 0\,\%$, minimal for $0\,\% < I^2 \leq 25\,\%$, low for $25 < I^2 \leq 50\,\%$, moderate for $50 < I^2 \leq 75\,\%$, and high for $I^2 > 75\,\%$, as previously reported [10, 11, 12, 13].

The random effect model of DerSimonian and Laird was adopted for all analyses independently from the statistical heterogeneity.

Meta-DiSc version 1.4 (Clinical Biostatistics Unit, Ramon y Cajal Hospital, Madrid, Spain) and Review Manager 5.4 (Copenhagen: The Nordic Cochrane Centre, Cochrane Collaboration, 2014) were used as data analysis software.

Results

Study selection

At the end of the database searches, 4,242 studies were identified. The removal of duplicates and title screening processes yielded 510 and 74 studies, respectively. After abstract screening, 14 studies were evaluated for eligibility [7, 8, 14, 15, 16, 17, 18, 19, 20, 21, 22, 23, 24, 25]. Of them, 8 studies were excluded because they did not report the presence of sonographic signs in women with sarcoma [14, 15, 16, 17]. Finally, 6 studies with 317 sarcoma patients were included in the qualitative and quantitative analyses [7, 8, 18, 19, 20, 21] (**Supplementary Figure 1**).

All included studies were designed as observational retrospective studies: three were case-control studies and three were observational retrospective studies (**Supplementary Table 1**).

The mean age of women with uterine sarcomas ranged from to 38 to 72.7 years. From studies with extractable data, 25.1 % of women were nulliparous and 50.2 % were menopausal. With respect to symptoms, 39.7 % of women had abnormal uterine bleeding, 15.5 % pelvic pain, and 4.5 % a palpable mass, while 12.9 % were asymptomatic. 74.2 % of sarcomas were International Federation of Gynecology and Obstetrics (FIGO) stage I-II (**Supplementary Table 2**).

The following sonographic signs were assessed (**Supplementary Table 3**):

- myometrium not visible, defined as absence of visibility of the myometrium;
- presence of a solid component, defined as a structure that has echogenicity suggestive of tissue;
- inhomogeneous echogenicity of a solid component;
- presence of cystic areas, defined as rounded lesions within the myometrium which may be anechoic, of low-level echogenicity, of ground-glass appearance, or of mixed echogenicity;
- irregular walls of cystic areas, considered positive if at least one cyst cavity had irregular contours;
- anechoic cystic areas, distinguishing from low level, hemorrhagic, ground glass, or other cystic areas;
- absence of shadowing, defined as a signal void behind structures that strongly absorb or reflect ultrasonic waves and described as either "fan-shaped shadowing" or "internal shadows";
- absence of calcification, defined as hyperechoic foci with shadowing behind;
- abnormal vascularization, defined as a color score of 3 or 4, where a color score of 3 means that a moderate amount of color Doppler signal was detected; and a score of 4 that abundant signal was detected [26];
- irregularity of the borders of the lesion, considered positive if at least one myometrial lesion had irregular contours;
- absence of visualization of endometrial cavity, considered positive if the endometrium was not visible for the presence of the myometrial lesion;

- presence of fluid in the pouch of Douglas;
- ascites, defined as the presence of fluid outside the pouch of Douglas;
- single lesion, defined as the presence of no more than one myometrial mass;
- intracavitary processes, defined as the presence of lesions within the uterine cavity.

Risk of bias assessment

All included studies were judged to be at low risk of bias for each domain, except for the "Unbiased assessment of the study endpoints" domain, where three studies were judged to be at unclear risk of bias for different reasons. In particular, the study by Bonneau *et al.* considered four cases of STUMP to be malignant sarcomas [8]. The study by Exacoustos et al. adopted not updated pathological criteria for the diagnosis of uterine sarcoma [18]. The study by Park et al. did not report a blinded evaluation of histological examination by at least 2 pathologists [21] (**Supplementary Figure 2**).

Meta-analysis

Among the total number of studies included in calculating pooled prevalence of each sonographic sign, 3 studies [7, 20, 21] included the absence of visibility of the myometrium and the presence of a solid component; 4 studies [7, 8, 19, 20] included inhomogeneous echogenicity of a solid component, 6 studies [7, 8, 18, 19, 20, 21] included the presence of cystic areas; 2 studies [19, 20] included irregular walls of cystic areas; 2 studies [20, 21] included the presence of anechoic cystic areas; 4 studies [7, 8, 19, 20] included the absence of shadowing and absence of calcifications; 5 studies [7, 8, 18, 20, 21] included color score 3 or 4; 5 studies [7, 8, 19, 20, 21] included irregularity of the borders of the lesion; 3 studies [7, 20, 21] included the absence of visualization of endometrial cavity; 2 studies [7, 20] included the presence of fluid in the pouch of Douglas; 3 studies[7, 8, 20] for presence of ascites; 3 studies [8, 19, 20] included the presence of an intracavitary process; 5 studies [7, 8, 18, 19, 21] included the presence of a single lesion.

In 2 studies [20] some sonographic signs were not assessed in all included patients. Therefore, when calculating the pooled prevalence of those signs, we considered only patients with the assessed sign. Moreover, for the study by Exacoustos *et al.* [18] which reported both peripheral and central vascularization of the lesion, we exclusively considered central vascularization of the lesion when calculating the prevalence of the sign "color score".

The pooled prevalence was:

- 25.0 % (95 %CI: 15.4–37.9 %; I^2:0 %) for the absence of visibility of the myometrium (▶ **Fig. 1**);

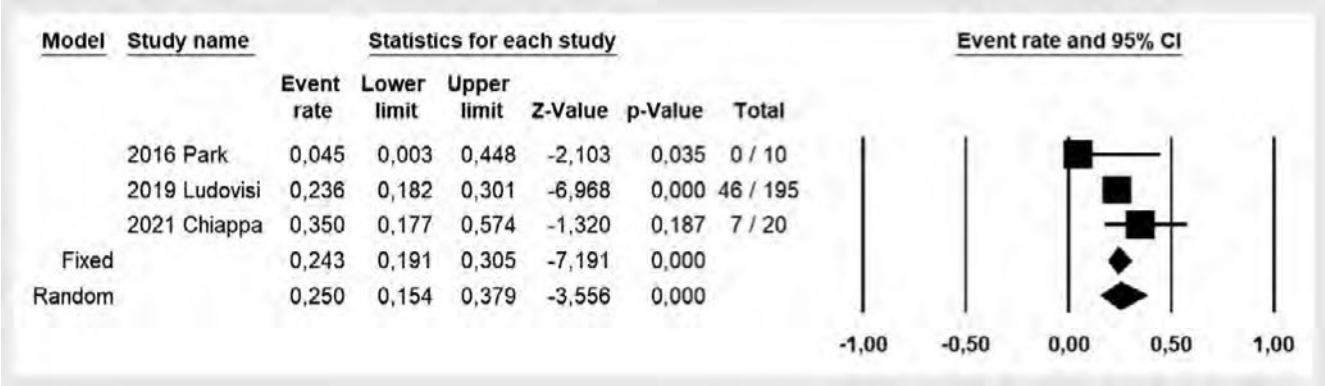

▶ **Fig. 1** Forest plots of individual studies and pooled for absence of visibility of the myometrium.

- 80.5 % (95 %CI: 74.8–85.2 %; I^2:0 %) for the presence of a solid component (▶ **Fig. 2**);

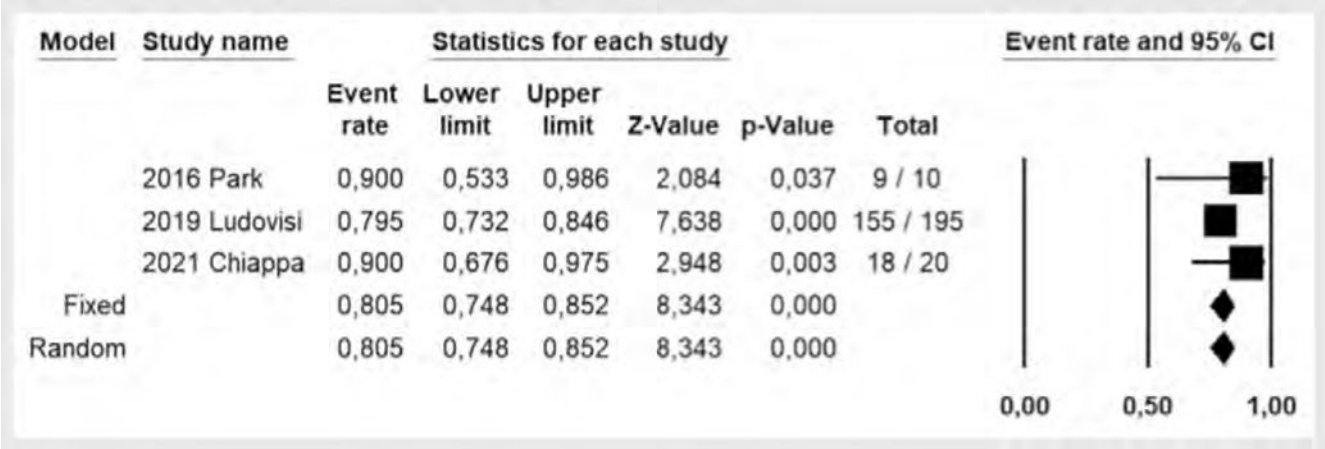

▶ **Fig. 2** Forest plots of individual studies and pooled for presence of solid component.

- 78.3 % (95 %CI: 59.3–89.9 %; I^2:0 %) for inhomogeneous echogenicity of a solid component (▶ **Fig. 3**);

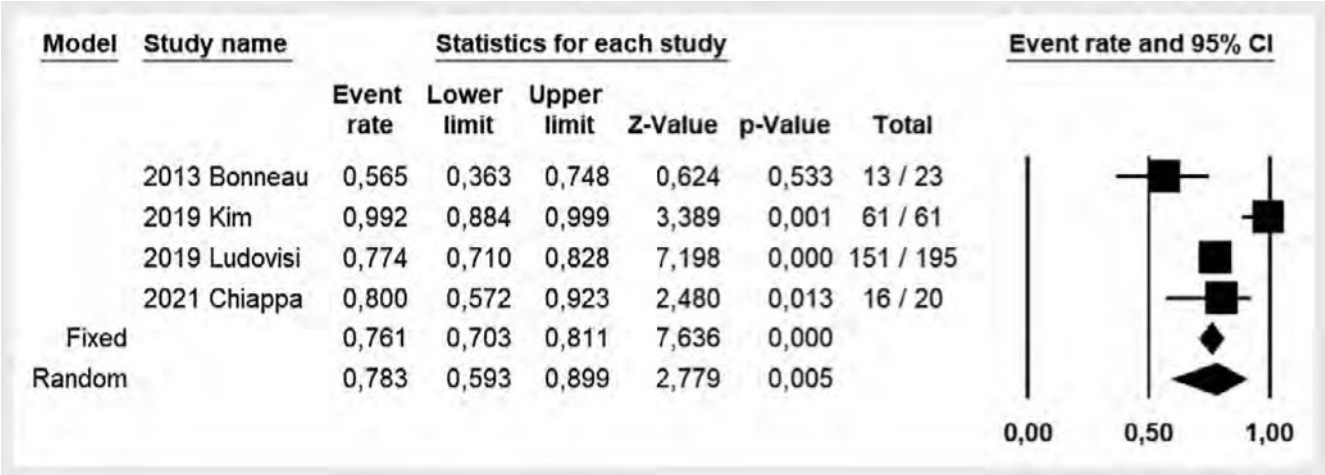

▶ **Fig. 3** Forest plots of individual studies and pooled for inhomogeneous echogenicity of solid component.

- 47.9 % (95 %CI: 41.1–54.8 %; I^2:0 %) for the presence of cystic areas (▶ **Fig. 4**);

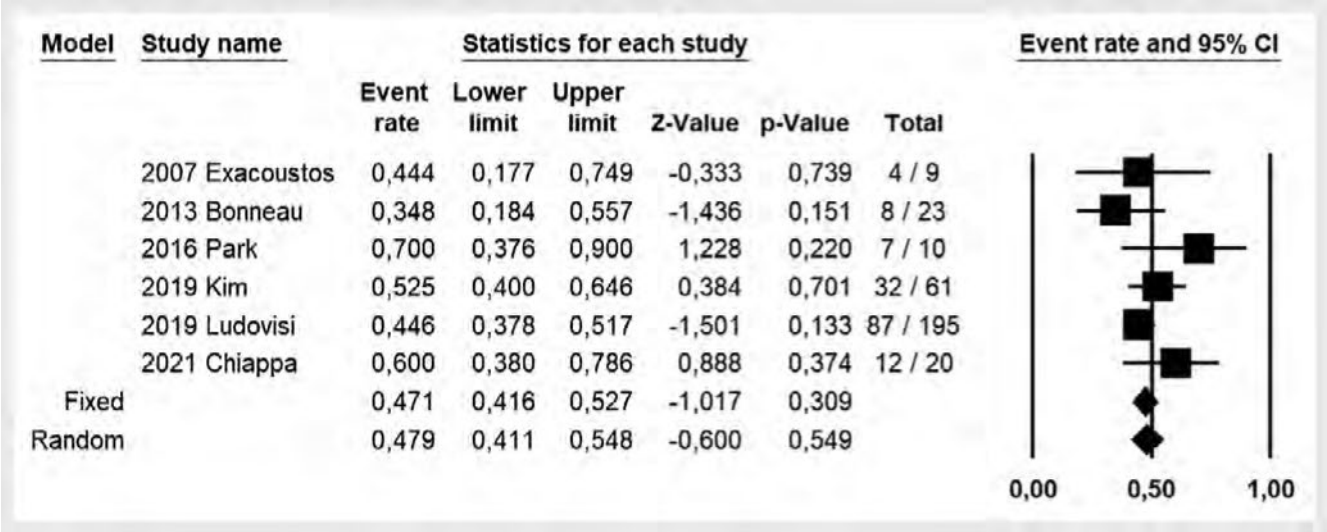

Model	Study name	Event rate	Lower limit	Upper limit	Z-Value	p-Value	Total
	2007 Exacoustos	0,444	0,177	0,749	-0,333	0,739	4 / 9
	2013 Bonneau	0,348	0,184	0,557	-1,436	0,151	8 / 23
	2016 Park	0,700	0,376	0,900	1,228	0,220	7 / 10
	2019 Kim	0,525	0,400	0,646	0,384	0,701	32 / 61
	2019 Ludovisi	0,446	0,378	0,517	-1,501	0,133	87 / 195
	2021 Chiappa	0,600	0,380	0,786	0,888	0,374	12 / 20
Fixed		0,471	0,416	0,527	-1,017	0,309	
Random		0,479	0,411	0,548	-0,600	0,549	

▶ **Fig. 4** Forest plots of individual studies and pooled for presence of cystic areas.

- 80.7 % (95 %CI: 68.3–89.0 %; I^2: not assessable) for irregular walls of cystic areas (▶ **Fig. 5**);

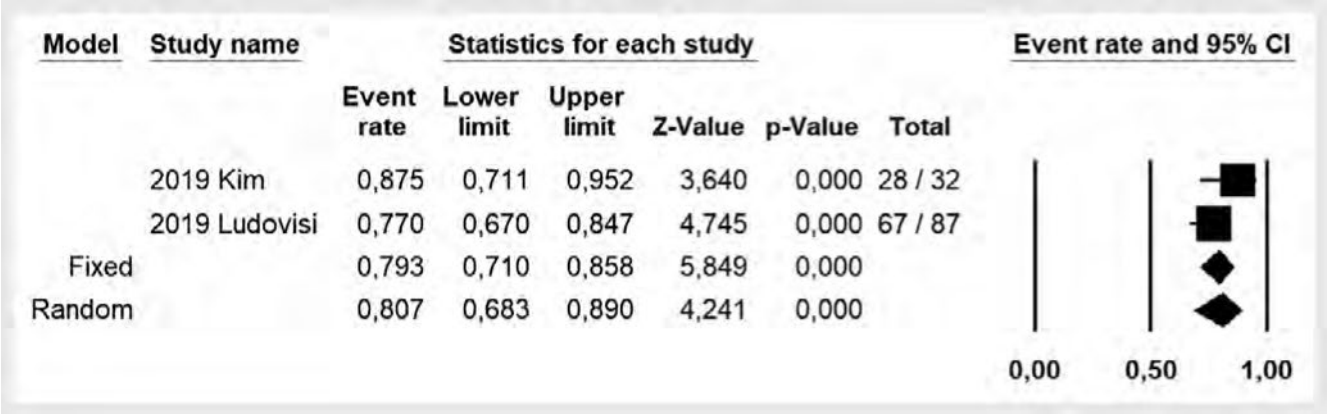

Model	Study name	Event rate	Lower limit	Upper limit	Z-Value	p-Value	Total
	2019 Kim	0,875	0,711	0,952	3,640	0,000	28 / 32
	2019 Ludovisi	0,770	0,670	0,847	4,745	0,000	67 / 87
Fixed		0,793	0,710	0,858	5,849	0,000	
Random		0,807	0,683	0,890	4,241	0,000	

▶ **Fig. 5** Forest plots of individual studies and pooled for irregular walls of cystic areas.

- 72.3 % (95 %CI: 16.7–97.2; I^2: not assessable) for anechoic cystic areas (▶ **Fig. 6**);

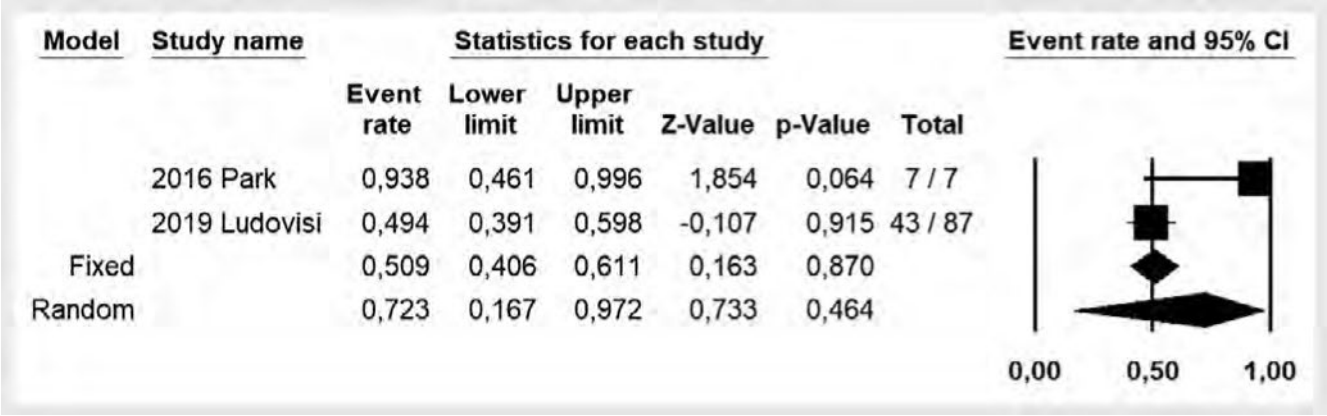

Model	Study name	Event rate	Lower limit	Upper limit	Z-Value	p-Value	Total
	2016 Park	0,938	0,461	0,996	1,854	0,064	7 / 7
	2019 Ludovisi	0,494	0,391	0,598	-0,107	0,915	43 / 87
Fixed		0,509	0,406	0,611	0,163	0,870	
Random		0,723	0,167	0,972	0,733	0,464	

▶ **Fig. 6** Forest plots of individual studies and pooled for anechoic cystic areas.

- 54.8 % (95 %CI: 34.0–74.1 %; I^2:0 %) for the absence of shadowing (▶ **Fig. 7**);

Model	Study name	Event rate	Lower limit	Upper limit	Z-Value	p-Value	Total
	2013 Bonneau	0,217	0,093	0,428	-2,534	0,011	5 / 23
	2019 Kim	0,557	0,432	0,676	0,894	0,371	34 / 61
	2019 Ludovisi	0,749	0,683	0,805	6,613	0,000	146 / 195
	2021 Chiappa	0,600	0,380	0,786	0,888	0,374	12 / 20
Fixed		0,661	0,603	0,715	5,204	0,000	
Random		0,548	0,340	0,741	0,442	0,658	

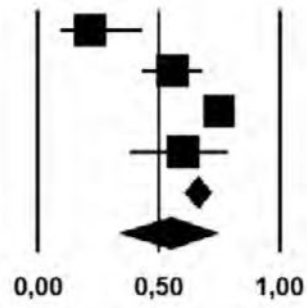

▶ **Fig. 7** Forest plots of individual studies and pooled for absence of shadowing.

- 73.5 % (95 %CI: 43.3–90.9 %; I^2:0 %) for the absence of calcifications (▶ **Fig. 8**);

Model	Study name	Event rate	Lower limit	Upper limit	Z-Value	p-Value	Total
	2013 Bonneau	0,217	0,093	0,428	-2,534	0,011	5 / 23
	2019 Kim	0,902	0,798	0,955	5,153	0,000	55 / 61
	2019 Ludovisi	0,836	0,777	0,882	8,420	0,000	163 / 195
	2021 Chiappa	0,800	0,572	0,923	2,480	0,013	16 / 20
Fixed		0,802	0,748	0,847	8,770	0,000	
Random		0,735	0,433	0,909	1,551	0,121	

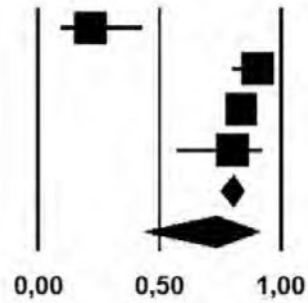

▶ **Fig. 8** Forest plots of individual studies and pooled for absence of calcifications.

- 48.7 % (95 %CI: 18.6–79.8 %; I^2:0 %) for color score 3 or 4 (▶ **Fig. 9**);

Model	Study name	Event rate	Lower limit	Upper limit	Z-Value	p-Value	Total
	2007 Exacoustos	0,944	0,495	0,997	1,947	0,052	8 / 8
	2013 Bonneau	0,174	0,067	0,382	-2,832	0,005	4 / 23
	2019 Kim	0,115	0,056	0,222	-5,086	0,000	7 / 61
	2019 Ludovisi	0,651	0,582	0,715	4,157	0,000	127 / 195
	2021 Chiappa	0,750	0,522	0,892	2,127	0,033	15 / 20
Fixed		0,566	0,502	0,627	2,011	0,044	
Random		0,487	0,186	0,798	-0,074	0,941	

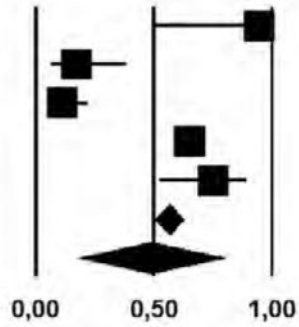

▶ **Fig. 9** Forest plots of individual studies and pooled for color score 3 or 4.

- 47.3 % (95 %CI: 37.0–57.8 %; I^2:0 %) for irregular tumor borders (▶ **Fig. 10**);

Model	Study name	Event rate	Lower limit	Upper limit	Z-Value	p-Value	Total
	2013 Bonneau	0,217	0,093	0,428	-2,534	0,011	5 / 23
	2016 Park	0,400	0,158	0,703	-0,628	0,530	4 / 10
	2019 Kim	0,492	0,369	0,615	-0,128	0,898	30 / 61
	2019 Ludovisi	0,528	0,458	0,597	0,787	0,431	103 / 195
	2021 Chiappa	0,600	0,380	0,786	0,888	0,374	12 / 20
Fixed		0,503	0,447	0,559	0,110	0,913	
Random		0,473	0,370	0,578	-0,501	0,616	

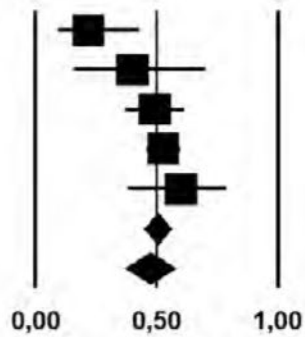

▶ **Fig. 10** Forest plots of individual studies and pooled for irregular tumor borders.

- 45.4 % (95 %CI: 27.6–64.3 %; I^2:0 %) for endometrial cavity not visualizable (▶ **Fig. 11**);

Model	Study name	Event rate	Lower limit	Upper limit	Z-Value	p-Value	Total
	2016 Park	0,045	0,003	0,448	-2,103	0,035	0 / 10
	2019 Ludovisi	0,508	0,438	0,577	0,215	0,830	99 / 195
	2021 Chiappa	0,500	0,294	0,706	0,000	1,000	10 / 20
Fixed		0,500	0,434	0,566	0,006	0,995	
Random		0,454	0,276	0,643	-0,469	0,639	

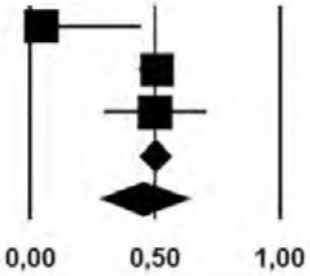

▶ **Fig. 11** Forest plots of individual studies and pooled for endometrial cavity not able to be visualized.

- 10.9 % (95 %CI: 3.5–29.1 %; I^2: not assessable) for the presence of fluid in the pouch of Douglas (▶ **Fig. 12**);

Model	Study name	Event rate	Lower limit	Upper limit	Z-Value	p-Value	Total
	2019 Ludovisi	0,067	0,039	0,111	-9,193	0,000	13 / 195
	2021 Chiappa	0,200	0,077	0,428	-2,480	0,013	4 / 20
Fixed		0,085	0,053	0,133	-9,310	0,000	
Random		0,109	0,035	0,291	-3,396	0,001	

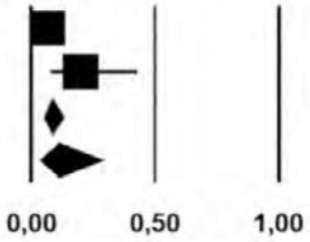

▶ **Fig. 12** Forest plots of individual studies and pooled for presence of fluid in the pouch of Douglas.

- 6.4 % (95 %CI: 1.1–30.2 %; I^2:0 %) for the presence of ascites (▶ **Fig. 13**);

Model	Study name	Event rate	Lower limit	Upper limit	Z-Value	p-Value	Total
	2013 Bonneau	0,217	0,093	0,428	-2,534	0,011	5 / 23
	2019 Ludovisi	0,021	0,008	0,053	-7,652	0,000	4 / 195
	2021 Chiappa	0,050	0,007	0,282	-2,870	0,004	1 / 20
Fixed		0,068	0,036	0,124	-7,747	0,000	
Random		0,064	0,011	0,302	-2,855	0,004	

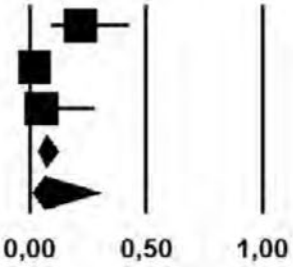

▶ **Fig. 13** Forest plots of individual studies and pooled for presence of ascites.

- 21.2 % (95 %CI: 2.1–76.8 %; I^2:0 %) for the presence of an intracavitary process (▶ **Fig. 14**);

Model	Study name	Statistics for each study					
		Event rate	Lower limit	Upper limit	Z-Value	p-Value	Total
	2013 Bonneau	0,391	0,218	0,598	-1,034	0,301	9 / 23
	2016 Park	0,600	0,297	0,842	0,628	0,530	6 / 10
	2019 Ludovisi	0,021	0,008	0,053	-7,652	0,000	4 / 195
Fixed		0,197	0,122	0,302	-4,831	0,000	
Random		0,212	0,021	0,768	-1,026	0,305	

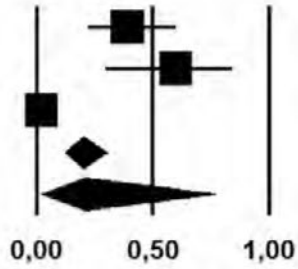

▶ **Fig. 14** Forest plots of individual studies and pooled for presence of an intracavitary process.

- 81.5 % (95 %CI: 56.1–93.8 %; I^2:0 %) for the presence of a singular lesion (▶ **Fig. 15**)

Model	Study name	Statistics for each study					
		Event rate	Lower limit	Upper limit	Z-Value	p-Value	Total
	2007 Exacoustos	0,944	0,495	0,997	1,947	0,052	8 / 8
	2013 Bonneau	0,783	0,572	0,907	2,534	0,011	18 / 23
	2016 Park	0,955	0,552	0,997	2,103	0,035	10 / 10
	2019 Kim	0,492	0,369	0,615	-0,128	0,898	30 / 61
	2021 Chiappa	0,900	0,676	0,975	2,948	0,003	18 / 20
Fixed		0,626	0,524	0,718	2,405	0,016	
Random		0,815	0,561	0,938	2,346	0,019	

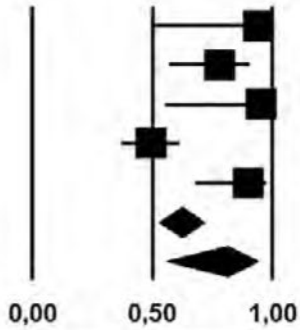

▶ **Fig. 15** Forest plots of individual studies and pooled for presence of a singular lesion.

Discussion

This study shows that the presence of a solid component, irregular walls of cystic areas, and singular lesions are sonographic signs with very high prevalence in uterine sarcomas, while inhomogeneous echogenicity of a solid component, anechoic cystic areas, and the absence of calcifications are signs with high prevalence. On the other hand, the presence of cystic areas (not exclusively anechoic), the absence of shadowing, a color score of 3 or 4, irregular tumor borders, lack of visualization of the endometrial cavity, the presence of fluid in the pouch of Douglas, the presence of ascites, and the presence of an intracavitary process are less common signs in malignant myometrial lesions.

Several tools have been described in the literature for the preoperative differentiation of uterine sarcomas from leiomyomas [3, 4, 25, 7, 27]. Among these, ultrasound is the first-line diagnostic tool as it is easy to perform, is cheap, and requires no patient preparation of preliminary exams.

In our study, the presence of a solid component, irregular walls of cystic areas, and singular lesions were the sonographic signs with the highest prevalence in uterine sarcomas, while other signs with high prevalence (although lower than the previous ones) were inhomogeneous echogenicity of a solid component, anechoic cystic areas, and the absence of calcifications.

The high prevalence of a solid component with inhomogeneous echogenicity may be explained by the increase of cellularity (generally exceeding 15 mitotic figures per 10 high-power fields [3]) caused by uncontrolled proliferation of neoplastic cells in uterine sarcomas. On ultrasound, "solid component" means the presence of high echogenicity [26].

On the other hand, the high prevalence of cystic areas would be the sonographic appearance of focal coagulative necrosis and degeneration of neoplastic tissue [28], while the irregularity of the walls of cystic areas would be due to a rapid and chaotic growth of malignant cells, reflecting the end-state of accumulation of multiple genetic defects in uterine sarcomas [3]. Degeneration and coagulative necrosis of neoplastic tissue in sarcomas would also explain the lack of calcifications inside the tumor.

In contrast, in our study, we found that the presence of cystic areas (not exclusively anechoic), the absence of shadowing, a color score of 3 or 4, irregular tumor borders, lack of visualization of the endometrial cavity, the presence of fluid in the pouch of Douglas, the presence of ascites, and the presence of an intracavitary process were less common signs in uterine sarcomas. Among these, it is a noteworthy finding that a color score of 3 or 4 had a low pooled prevalence (48.7 %). In fact, irregular and intense vascularity is typically known as a sign of malignant lesions due to neoangiogenesis related to the tumoral microenvironment [4, 16]. In addition, this sonographic sign could be considered even less relevant in uterine sarcoma diagnosis as uterine leiomyomas are usually sparsely vascularized, too [29].

To our knowledge, this study may be the first study to calculate the pooled prevalence of each sonographic sign in women with uterine sarcoma. On the one hand, it may provide physicians with some sonographic "red flags" in the diagnosis of uterine lesions, and, on the other hand, it may highlight sonographic signs rarely associated with malignant lesions.

However, some limitations may affect our findings: First, the impossibility of evaluating a combination of sonographic signs (the presence of two or more signs with a high prevalence in uterine sarcomas on ultrasound might actually increase the specificity of this examination and should be evaluated in future studies); second, the retrospective design of the included studies (however, given the rarity of uterine sarcomas, prospective studies do not seem feasible); lastly, the inability to calculate the accuracy of the considered sonographic signs since the data were not sufficient for this analysis.

Conclusion

On ultrasound of women with uterine sarcoma, a solid component, irregular walls of cystic areas, and singular lesions are signs with very high prevalence, while inhomogeneous echogenicity of a solid component, anechoic cystic areas, and the absence of calcifications are signs with high prevalence. In contrast, the presence of cystic areas (not exclusively anechoic), the absence of shadowing, a color score of 3 or 4, irregular tumor borders, a lack of visualization of the endometrial cavity, the presence of fluid in the pouch of Douglas, the presence of ascites, and the presence of an intracavitary process appear to be less common signs.

Our findings might help build a standardized approach for the ultrasound diagnosis of uterine sarcomas. The presence or absence of the described ultrasound signs may represent a useful item to help physicians in the differential diagnosis between benign and malignant uterine mesenchymal lesions.

Conflict of Interest

The authors declare that they have no conflict of interest.

References

[1] Tropé CG, Abeler VM, Kristensen GB. "Diagnosis and treatment of sarcoma of the uterus. A review,". Acta Oncologica 2012; 51 (6). doi:10.3109/0284186X.2012.689111.

[2] Nagai T et al. "Novel uterine sarcoma preoperative diagnosis score predicts the need for surgery in patients presenting with a uterine mass,". Springerplus 2014; 3 (1). doi:10.1186/2193-1801-3-678.

[3] D'Angelo E, Prat J. "Uterine sarcomas: A review,". Gynecologic Oncology 2010; 116 (1). doi:10.1016/j.ygyno.2009.09.023.

[4] Van Den Bosch T et al. "Terms, definitions and measurements to describe sonographic features of myometrium and uterine masses: A consensus opinion from the Morphological Uterus Sonographic Assessment (MUSA) group,". Ultrasound Obstet. Gynecol 2015; 46 (3). doi:10.1002/uog.14806.

[5] Amant F, Coosemans A, Debiec-Rychter M et al. "Clinical management of uterine sarcomas,". The Lancet Oncology 2009; 10 (12). doi:10.1016/S1470-2045(09)70226-8.

[6] Moher D et al. "Preferred reporting items for systematic review and meta-analysis protocols (PRISMA-P) 2015 statement,". Rev. Esp. Nutr. Humana y Diet 2016; 20 (2). doi:10.1186/2046-4053-4-1.

[7] Chiappa V et al. "Using rADioMIcs and machine learning with ultrasonography for the differential diagnosis of myometRiAL tumors (the ADMIRAL pilot study). Radiomics and differential diagnosis of myometrial tumors,". Gynecol. Oncol 2021; 161 (3). doi:10.1016/j.ygyno.2021.04.004.

[8] Bonneau C, Thomassin-Naggara I, Dechoux S et al. “Value of ultrasonography and magnetic resonance imaging for the characterization of uterine mesenchymal tumors,”. Acta Obstet. Gynecol. Scand 2014; 93 (3). doi:10.1111/aogs.12325.

[9] Slim K, Nini E, Forestier D et al. “Methodological index for non-randomized studies (Minors): Development and validation of a new instrument,”. ANZ J. Surg 2003; 73 (9). doi:10.1046/j.1445-2197.2003.02748.x.

[10] Raffone A et al. “Diabetes Mellitus Is Associated with Occult Cancer in Endometrial Hyperplasia,”. Pathology and Oncology Research 2020; 26 (3). doi:10.1007/s12253-019-00684-3.

[11] Travaglino A et al. “Congruence between 1994 WHO classification of endometrial hyperplasia and endometrial intraepithelial neoplasia system,”. Am. J. Clin. Pathol 2020; 153 (1). doi:10.1093/ajcp/aqz132.

[12] Travaglino A et al. “Significant risk of occult cancer in complex non-atypical endometrial hyperplasia,”. Archives of Gynecology and Obstetrics 2019; 300 (5). doi:10.1007/s00404-019-05299-2

[13] Raffone A, Raimondo D, Travaglino A et al. “Diagnostic accuracy of ultrasound in the differential diagnosis between uterine leiomyomas and sarcomas: a systematic review and meta-analysis,”. Manuscr. Submitt. Publ. 2022

[14] Aviram R et al. “Uterine sarcomas versus leiomyomas: Gray-scale and Doppler sonographic findings,”. J. Clin. Ultrasound 2005; 33 (1). doi:10.1002/jcu.20075.

[15] Chen I, Firth B, Hopkins L et al. “Clinical characteristics differentiating uterine sarcoma and fibroids,”. J. Soc. Laparoendosc. Surg 2018; 22 (1). doi:10.4293/JSLS.2017.00066.

[16] Hata K, Hata T, Maruyama R et al. “Uterine sarcoma: Can it be differentiated from uterine leiomyoma with Doppler ultrasonography? A preliminary report,”. Ultrasound Obstet. Gynecol 1997; 9 (2). doi:10.1046/j.1469-0705.1997.09020101.x.

[17] Zhao F, Xu Y, Zhang H et al. “Ultrasonographic findings of uterine carcinosarcoma,”. Gynecol. Obstet. Invest 2019; 84 (3): 277–282. doi:10.1159/000481885.

[18] Exacoustos C et al. “Can gray-scale and color Doppler sonography differentiate between uterine leiomyosarcoma and leiomyoma?,”. J. Clin. Ultrasound 2007; 35 (8). doi:10.1002/jcu.20386.

[19] Kim JH et al. “Sonographic and Clinical Characteristics of Uterine Sarcoma Initially Misdiagnosed as Uterine Fibroid in Women in the Late Reproductive Age,”. J. Menopausal Med 2019; 25 (3). doi:10.6118/jmm.19007.

[20] Ludovisi M et al. “Imaging in gynecological disease (15): clinical and ultrasound characteristics of uterine sarcoma,”. Ultrasound Obstet. Gynecol 2019; 54 (5). doi:10.1002/uog.20270.

[21] Park GE, Rha SE, Oh SN et al. “Ultrasonographic findings of low-grade endometrial Stromal sarcoma of the uterus with a focus on cystic degeneration,”. Ultrasonography 2016; 35 (2). doi:10.14366/usg.15045.

[22] Li D et al. “A real-world study on diagnosis and treatment of uterine sarcoma in Western China,”. Int. J. Biol. Sci 2020; 16 (3). doi:10.7150/ijbs.39773.

[23] Skorstad M, Kent A, Lieng M. “Preoperative evaluation in women with uterine leiomyosarcoma. A nationwide cohort study,”. Acta Obstet. Gynecol. Scand 2016; 95 (11). doi:10.1111/aogs.13008.

[24] Köhler G et al. “Benign uterine mass – discrimination from leiomyosarcoma by a preoperative risk score: a multicenter cohort study,”. Arch. Gynecol. Obstet 2019; 300 (6). doi:10.1007/s00404-019-05344-0.

[25] Najibi S, Gilani MM, Zamani F et al. “Comparison of the diagnostic accuracy of contrast-enhanced/DWI MRI and ultrasonography in the differentiation between benign and malignant myometrial tumors,”. Ann. Med. Surg 2021; 70. doi:10.1016/j.amsu.2021.102813.

[26] Timmerman D, Valentin L, Bourne TH et al. “Terms, definitions and measurements to describe the sonographic features of adnexal tumors: A consensus opinion from the International Ovarian Tumor Analysis (IOTA) group,”. Ultrasound in Obstetrics and Gynecology 2000; 16 (5). doi:10.1046/j.1469-0705.2000.00287.x.

[27] Di Cello A et al. “A more accurate method to interpret lactate dehydrogenase (LDH) isoenzymes’ results in patients with uterine masses,”. Eur. J. Obstet. Gynecol. Reprod. Biol 2019; 236. doi:10.1016/j.ejogrb.2019.03.017.

[28] Prat J. “FIGO staging for uterine sarcomas,”. International Journal of Gynecology and Obstetrics 2009; 104 (3). doi:10.1016/j.ijgo.2008.12.008.

[29] Wojtowicz K et al. “Uterine myomas and sarcomas – clinical and ultrasound characteristics and differential diagnosis using pulsed and color Doppler techniques,”. J. Ultrason 2022; 22 (89): e100–e108. doi:10.15557/JoU.2022.0017.