

Caesarean Scar Pregnancy: Single Dose of Intrasac Ultrasound-Guided Methotrexate Injection Seems to be a Safe Option for Treatment



Authors

Angeliki Rouvalis¹, Panagiotis Vlastarakos¹ , Georgios Daskalakis¹, Abraham Pouliakis², Sofoklis Stavrou³, Maria Tsiriva³, Maria Giourga³ , Angeliki Gereide⁴, Kalliopi Pappa³, Themis Gregoriadis³, Dimitrios-Efthymios Vlachos³, Alexandros Rodolakis³, Ekaterini Domali³

Affiliations

- 1 Obstetrics and Gynecology, National and Kapodistrian University of Athens – 1st Obstetrics and Gynecology Clinic, Athens, Greece
- 2 2nd Department of Pathology, National and Kapodistrian University of Athens School of Medicine, Athens, Greece
- 3 First Department of Obstetrics and Gynecology, University of Athens, Greece, National and Kapodistrian University of Athens – 1st Obstetrics and Gynecology Clinic, Athens, Greece
- 4 Department of Obstetrics and Gynecology, Democritus University of Thrace, Alexandroupolis, Greece

Key words

ectopic pregnancy, cesarean scar pregnancy, transvaginal ultrasound, methotrexate, gynecology

received 04.10.2022

accepted after revision 15.03.2023

published online 2023

Bibliography

Ultrasound Int Open 2023; 9: E18–E25

DOI 10.1055/a-2137-8318

ISSN 2199-7152

© 2023. The Author(s).

This is an open access article published by Thieme under the terms of the Creative Commons Attribution-NonDerivative-NonCommercial-License, permitting copying and reproduction so long as the original work is given appropriate credit. Contents may not be used for commercial purposes, or adapted, remixed, transformed or built upon. (<https://creativecommons.org/licenses/by-nc-nd/4.0/>)

Georg Thieme Verlag KG, Rüdigerstraße 14,
70469 Stuttgart, Germany

Correspondence

Dr. Panagiotis Vlastarakos
National and Kapodistrian University of Athens – 1st
Obstetrics and Gynecology Clinic
Obstetrics and Gynecology, Lourou 2-4
11528 Athens
Greece
Tel.: 00306978076788
pan.vlastarakos@gmail.com

ABSTRACT

Objective The purpose of the study was to assess the efficacy of local ultrasound-guided methotrexate injection in patients with caesarean section scar pregnancy, to chart the course of beta-human chorionic gonadotropin levels (HCG) after treatment, and to see if HCG levels are correlated with clinical presentation.

Methods Between May 2018 and January 2021, data were collected retrospectively from the Early Pregnancy Unit of a tertiary hospital.

Results Our clinic assessed 20 patients; one disputed terminating the pregnancy and was not included in the research. The remaining 19 patients, with a median age of 34 years, received intragestational sac methotrexate injection under ultrasound guidance. 7w3d was the median gestational age. These women had one to four previous caesarean sections, with a mean of 1.60 ± 9. Patients with caesarean scar pregnancy most typically presented with spotting (42.1%), whereas 26.3% were asymptomatic. Except in cases of pain, the symptomatic women's HCG levels were lower than in the non-symptomatic women. The level of HCG in patients with pain was approximately double that of non-pain patients ($p = 0.2557$). In our series, intragestational sac methotrexate injection was effective in 17/19 women, or 89.5% (95%CI: 75.7-100%). HCG levels were undetectable in 97.6 ± 30 days on average (minimum: 42 days, maximum: 147 days).

Conclusion Caesarean scar pregnancy is a rare possibly fatal condition with no consensus on the optimal treatment. An experienced Early Pregnancy Unit member performing local methotrexate injections under ultrasound guidance is a feasible and successful strategy in clinically stable patients.

Introduction

Caesarean scar pregnancy is a rare type of ectopic pregnancy that results from the implantation of a pregnancy on a previous caesarean section scar. It was first described in 1978 by Larsen and Solomon [1] and is now regarded as a severe “late complication” following a caesarean section birth.

The reported cases of caesarean scar pregnancy have increased over the last years in a parallel manner to a worldwide increase in the prevalence of caesarean section deliveries [2] and the widespread use of transvaginal ultrasound. The technical expertise acquired by clinicians and sonographers as well as the establishment of Early Pregnancy Units within Obstetric Healthcare systems has undoubtedly enhanced the awareness of this condition. Early recognition of this *subtype of ectopic* pregnancy is crucial and nowadays feasible, allowing termination of pregnancy on time and minimizing hazardous consequences such as uterine rupture with severe life-threatening bleeding.

Despite the above amelioration regarding the diagnosis of a caesarean scar pregnancy case, there is no agreement concerning the optimal treatment. This could be explained by the extremely low and sporadic incidence of these cases as well as the lack of randomized and controlled trials to compare the available treatment modalities [3]. To date, medical and surgical options, or a combination of both, have been proposed. All the suggested methods aim to eliminate catastrophic complications associated with caesarean scar pregnancy in order to preserve fertility and to avoid major hemorrhage, which may lead to hysterectomy.

In this study, we aim to assess the efficacy of intra-gestational methotrexate injection under ultrasound guidance as a method of choice to treat women with caesarean scar pregnancy.

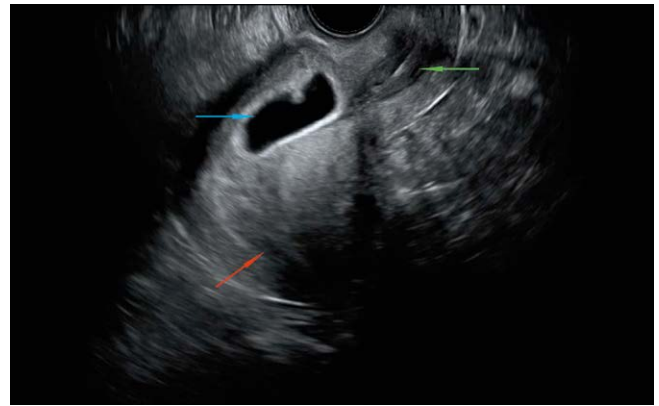
Materials and Methods

Statistical analysis

In this single-center, retrospective study conducted between May 2018 and January 2021, we examined the efficacy of local ultrasound-guided intra-gestational methotrexate injection to treat caesarean scar pregnancies. Diagnosis of a caesarean scar pregnancy was established in our Early Pregnancy Unit by transvaginal ultrasound using the following imaging criteria [4, 5] (► Fig. 1):

- an empty uterine cavity and endocervical canal, without contact with the sac,
- the presence of a gestational sac with or without a fetal pole (with or without fetal cardiac activity) implanted in the lower anterior uterine segment at the site of a previous caesarean section scar,
- thin or absent myometrium between the bladder and the sac,
- negative “sliding organ sign”,
- evidence of increased peritrophoblastic or periplacental vascularity on color Doppler examination.

Alternatively, Timor-Tritsch et al. [6], proposed an easy approach to estimate the risk of underlying caesarean scar pregnancy in three simple steps. First, based on the sagittal image of the uterus, they connect the external cervical os to uterine fundus via a longitudinal line. Second, they draw a line vertical to the first dividing it into



► Fig. 1 Caesarean scar pregnancy. The red arrow indicates the empty endometrial cavity; the green arrow shows the closed cervical canal; the blue arrow signifies the gestational sac implanted in the Caesarean scar.

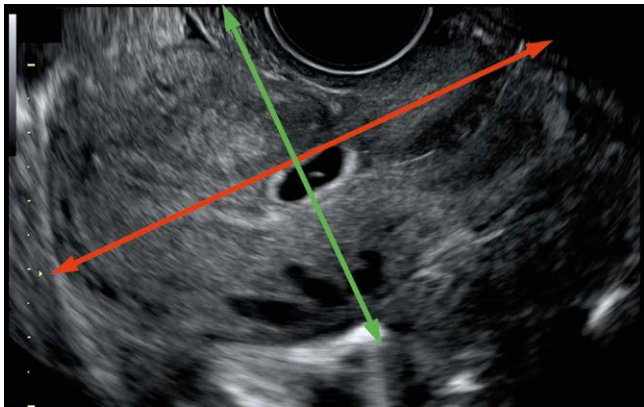
two equal parts. The cross section of the two lines is the area of interest that could define the risk of caesarean scar pregnancy. If the gestational sac is located towards the uterine fundus, then it is suggestive of intrauterine pregnancy, whereas if it is located on the crossline area or towards the cervix, it is a caesarean scar pregnancy ► Fig. 2.

Following diagnosis, patients were counselled and offered to terminate the ectopic pregnancy with ultrasound-guided methotrexate injection at the site of the implantation.

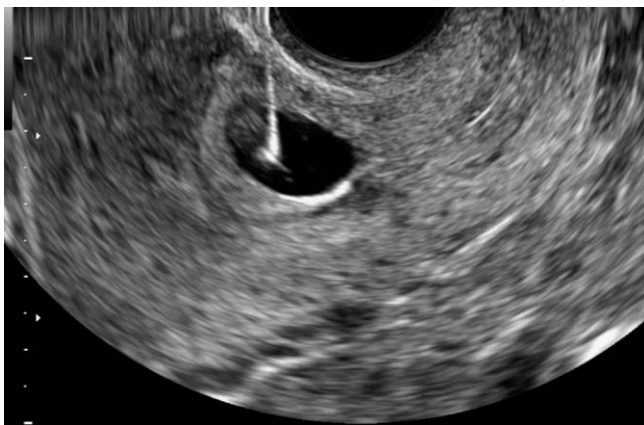The procedure was performed in main operating rooms by an experienced member of the Early Pregnancy Unit team. Patients were placed in lithotomy position and general anesthesia was administered. Local disinfection of the vagina followed by catheterization of the bladder using a nelaton catheter was the first step of the procedure. Then a punctured needle, attached to the ultrasound probe, was inserted into the gestational sac transvaginally. The fluid in the gestational sac was aspirated and 50 mg/m² of methotrexate was injected intracavitary ► Fig. 3. Finally, a thorough check for any signs of active bleeding was performed. The patients recovered in the operating room and remained in the hospital for at least 24 hours.

During follow-up, HCG levels were used to assess the therapeutic effect of the methotrexate injection. A first HCG level check was performed on day four and then on day seven (on average) after the procedure along with transvaginal ultrasound. We carried out weekly blood tests until HCG concentrations returned to undetectable levels.

Data were collected in Microsoft Excel spreadsheets from the Early Pregnancy Unit records and then were imported into SAS for Windows 9.4 software platform (SAS Institute Inc., NC, U.S.A.) for statistical analysis. Descriptive values are expressed as median and 1st-3rd quartile range (Q1–Q3) and in some cases the mean ± standard deviation (SD) is reported to allow for possible future comparisons and meta-analyses. For the categorical data the frequency and the relevant percentages are reported. Comparison of the HCG levels during diagnosis and methotrexate injection was performed using the Wilcoxon ranked sum test since a paired test was required



► **Fig. 2** Timor-Tritch et al., approach for the diagnosis of a Cesarean scar pregnancy. The red line connects the external cervical os to the uterine fundus. The green line separates the red one into two equal parts. The position of the gestational sac in the cross-sectional area indicates the risk of CSP.



► **Fig. 3** Methotrexate injection in the gestational sac.

and data normality was not ensured (via the Kolmogorov – Smirnov test). Comparisons for the qualitative parameters were made using the Fisher exact test, and for the continuous parameters as normality was ensured, we applied the Mann-Whitney U test. The significance level for the study was set to $p < 0.05$ and all tests were two-sided.

Results

Twenty patients with caesarean scar pregnancy were treated in our clinic. One of them refused to terminate her pregnancy and therefore is not included in the subsequent analysis. The remaining 19 patients ranged in age from 18 to 39 years (median age = 34 years, Q1–Q3: 30–38 years). These women had a history of one to four previous caesarean sections (mean number of caesarean sections before diagnosis = 1.6 ± 0.9 , 63.2%: one caesarean section, 21.1%: two caesarean sections, 10.5%: three caesarean sections, and one woman had four caesarean sections). On average, the participating women had 3.6 ± 1.7 gestations (min: 1, max: 7.00, median: 3

Q1–Q3: 2–4.00) and the resulted parities were 1.7 ± 1.0 (min: 1, max: 4, median: 1 Q1 – Q3: 1 – 2), leading to a success percentage of $47\% \pm 10\%$.

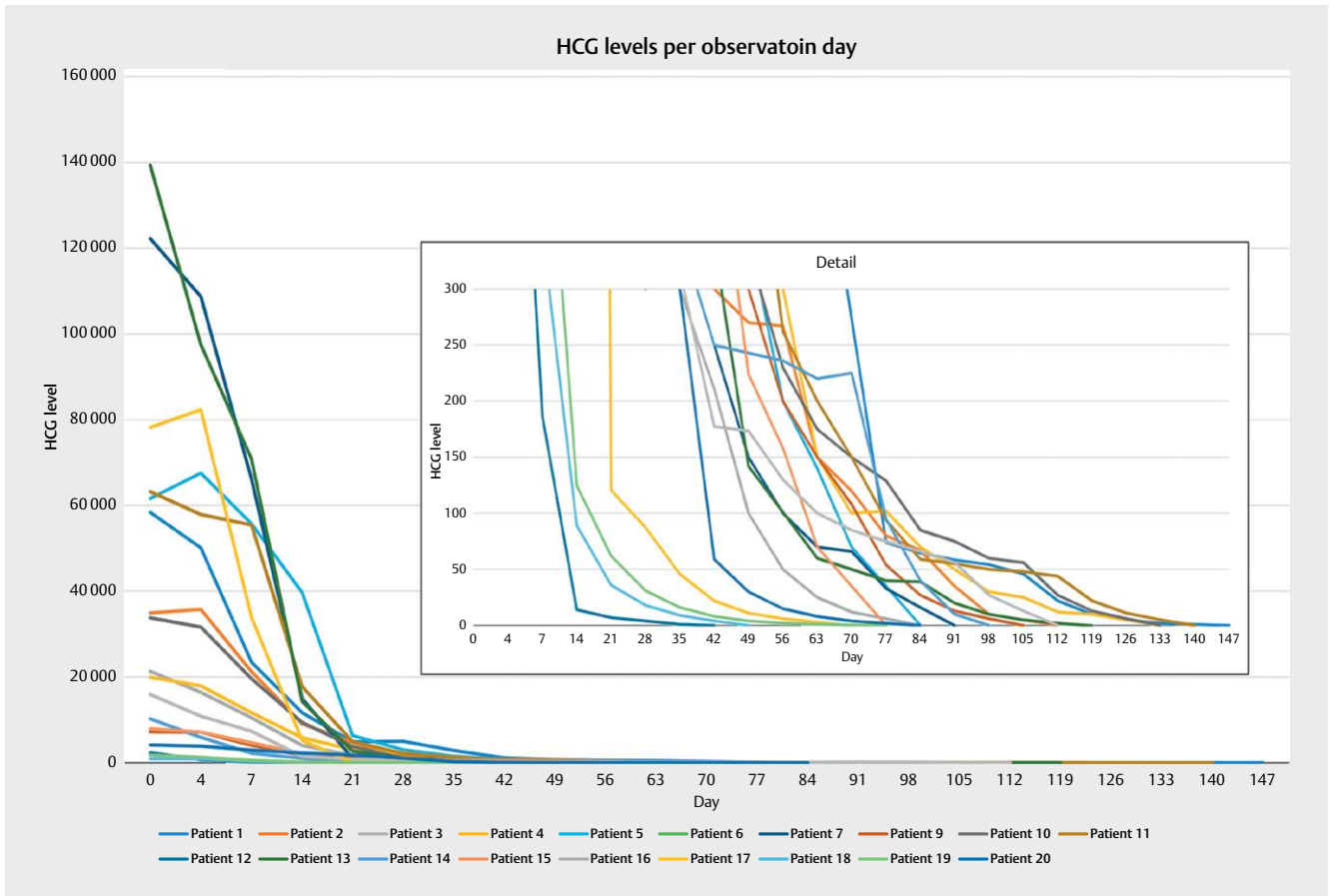
In 5 out of 19 caesarean scar pregnancy incidences (26.3%), the patients did not report any symptoms at the time of diagnosis. From the remaining 14 symptomatic patients, 8 (42.1% of all patients) reported spotting, 4 (21.1%) had bleeding, and 3 (15.8%) experienced pain (only one patient reported both spotting and pain).

The median gestational age at diagnosis was 7w3d (Q1–Q3: 6w1d – 8w5d). On the day of diagnosis, the median HCG level was 22365 mIU/ml (Q1–Q3: 5554–61645 mIU/ml) and on the day of the methotrexate injection, the median HCG level was 21,307 mIU/ml (Q1–Q3: 7217–63224 mIU/ml) ► **Fig. 4**. No difference in the HCG levels between the day of diagnosis and the day of methotrexate injection was observed ($p = 0.1094$). Note that in 12 cases diagnosis and methotrexate injection occurred on the same day.

For two women (10.5%) a complimentary intervention was required [the first: intramuscular (IM) additional methotrexate injection ($50 \text{ mg/kg}^2 \text{ IM}$) and the second: laparotomy]. ► **Table 1** shows the characteristics of the patients with caesarean scar pregnancy identified in our records. Note that one woman did not receive a methotrexate injection. This woman was consequently excluded from subsequent analysis. In one case the time for HCG standardization was not retrieved. Therefore, the data for this woman was only partially analyzed.

During the follow-up period, HCG levels dropped. On average, the time required for HCG levels to drop to undetectable levels was 97.6 ± 30.0 days (minimum: 42 days, maximum: 147 days, median: 94.5 Q1–Q3: 77–119 days). On average the drop rate was 375 ± 427 mIU/day (min: 18.5 mIU/day, max: 1343.7 mIU/day, median: 201.7 Q1–Q3: 68.7–451.6 mIU/day). However, note that HCG levels do not follow a linear drop pattern, since the drop rate is higher in the initial days and becomes lower in the following days. During the first month, HCG levels did not drop to zero for any woman. Within two months two women had HCG levels of zero. Levels normalized within three months in nine women (about 50%) and within four months in 14 (75%) women. It took more than four months for HCG to be undetectable in five women (about 25%). In terms of efficacy, the method led to successful treatment in all cases. However, two women required additional interventions. Thus the method efficacy is $17/19 = 89.5\%$ (95% CI: 75.7%–100%).

Subsequently and despite the fact that there is a rather limited set of data, we examined the data for a relationship between HCG levels and the various symptoms (► **Fig. 5**). Actually, no statistically important difference in HCG (at methotrexate injection) was able to be confirmed among the patients grouped according to their symptoms. However, there is strong evidence that HCG levels may differ between individual groups. ► **Table 2** shows the descriptive statistics of HCG levels during the injection of methotrexate in relation to the symptoms. Notably, in all cases with the exception of pain, HCG levels in patients with symptoms were lower compared to the group of women without symptoms. In women experiencing pain, the HCG level was almost double (72325.33 ± 62433 mIU/ml) compared to the women who did not experience pain (35506.63 ± 38358 mIU/ml) ($p = 0.2557$).



► **Fig. 4** Evolution of HCG for the study population and detail of the HCG levels near zero.

Discussion

Caesarean scar pregnancy is a rare form of ectopic pregnancy and even though a recent national cohort study from the United Kingdom (UK) reports an incidence of approximately 1.5 in 10,000 deliveries [3], other retrospective studies with a small number of cases from tertiary referral centers estimated that the prevalence of caesarean scar pregnancy may vary from 1:1800 to 1:2216 [7, 8]. Our hospital is a tertiary referral center with an Early Pregnancy Unit where many patients are referred from all over the country for diagnosis and further management. This paper presents our experience in 19 patients with caesarean scar pregnancy treated by injecting local methotrexate directly into the gestational sac between May 2018 and January 2021.

Early diagnosis of a scar ectopic pregnancy offers a wider range of management options with a higher success rate of conservative treatment options and chance of preserving fertility [9, 10]. It must be noted that ultrasound is the gold-standard imaging test for the diagnosis of caesarean scar pregnancy with a sensitivity of 86.4% [11]. Missed or delayed diagnosis of caesarean scar pregnancy could have detrimental consequences for the pregnancy and the patient [12]. All caesarean scar pregnancies presented in this report were diagnosed by transvaginal ultrasound and the median gestational age at diagnosis was 7w3d.

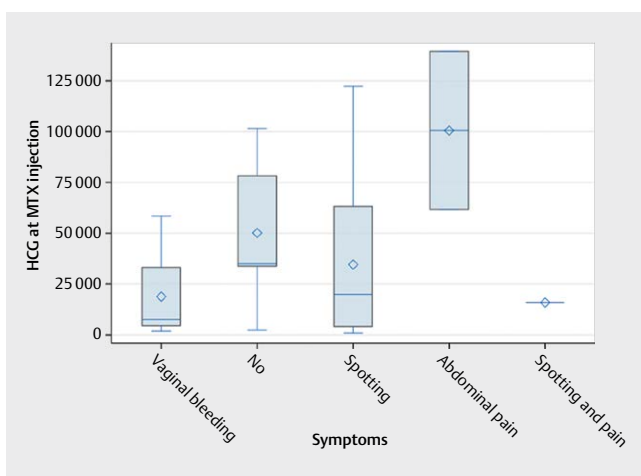
Consistent with existing data, most women in our caesarean scar pregnancy series presented with painless spotting or painless vaginal bleeding [11]. Although this is a rather limited set of data, there is evidence that HCG levels were almost double in women that experienced pain compared to the women that did not. However, vaginal bleeding and abdominal pain is very common in early pregnancy and is not specific. According to our findings, women with a history of prior caesarean delivery who present with these symptoms in early pregnancy should be evaluated with clinical vigilance for caesarean scar pregnancy.

Advanced maternal age, multigravidity, induced abortions, short pregnancy interval from previous caesarean section, induced abortions after caesarean section, and retroverted uterus have all been described as possible predisposing factors for caesarean scar pregnancy [13]. However, little is known about the pathogenesis of this condition; the most accepted theory for the caesarean scar pregnancy is that delayed wound healing caused by prior trauma and poor vascularization in the lower uterine segment forms a microscopic dehiscence myometrial defect through which the blastocyst inserts into the myometrium [14]. These defects have been described as 'niche' and usually occur in women with a history of multiple caesarean sections [15]. In our series, 63.2% had only one previous caesarean section, 21.1% had two previous caesarean sections, 10.5% had three previous caesarean sections, and one

► **Table 1** Summary table of patients with scar pregnancy.

Patient	Age (years)	GP	Number of CS	HCG at presentation	GA at diagnosis	Time of HCG standardization (days)	Complications/interventions
Patient 1	29	G3P1	1	25679	7w 1d	147	IM MTX
Patient 2	35	G3P1	1	34907	7w 4d	112	No
Patient 3	38	G3P1	1	16000	6w 3d	84	No
Patient 4	35	G3P1	1	22365	8w 3d	133	No
Patient 5	31	G4P2	2	61645	7w 6d	84	No
Patient 6	36	G4P2	1	101542	12w 5d	NA	Laparotomy
Patient 7	38	G4P2	2	122277	9w 0d	91	No
Patient 8 *	32	G3P2	2		16w 6d		Delivery + hysterectomy
Patient 9	24	G2P1	1	5554	5w 2d	105	No
Patient 10	35	G5P3	3	33777	11w 5d	133	No
Patient 11	30	G3P1	1	26526	7w 4d	140	No
Patient 12	39	G3P1	1	2074	8w 5d	42	No
Patient 13	34	G2P1	1	139410	7w 0d	119	No
Patient 14	25	G7P3	2	10254	7w 3d	98	No
Patient 15	18	G2P1	1	7910	5w 5d	77	No
Patient 16	34	G2P1	1	15921	6w 1d	112	No
Patient 17	34	G3P2	2	78202	8w 5d	70	No
Patient 18	38	G2P1	1	507	5w 0d	49	No
Patient 19	31	G7P4	4	1811	5w 5d	77	No
Patient 20	39	G7P4	3	4138	6w 4d	84	No

GP: Gestations/Parities, CS: Caesarean Section, GA: Gestational Age, HCG: Human Chorionic Gonadotropin, NA: Not Available. *This woman was not included in data analysis because she has chosen to continue the pregnancy.



► **Fig. 5** Box and whisker plots of HCG levels during MTX injection and the various symptoms. Box limits show the Q1 and Q3 values, the line within the boxes indicates the median values, the diamond symbol corresponds to the mean values, and the whisker limits to the minimum and maximum values.

woman had four caesarean sections. Nonetheless, due to the small number of patients in our investigation, we could not detect a strong correlation between the number of previous caesarean sections and the probability of caesarean scar pregnancy.

It has also been suggested that caesarean scar pregnancy and morbidly adherent placenta spectrum disorders share the same microscopic features, thus the former is considered by many authors as the precursor to morbidly adherent placenta if the pregnancy progresses to the late 2nd or 3rd trimester [16]. The crossover sign (COS) has been suggested as a useful sonographic marker to ascertain the evolution of a caesarean scar pregnancy. It seems that when the ectopic sac is implanted within the previous caesarean section scar and more than two thirds above the endometrial line towards the anterior uterine wall (COS 1 group), the risk of placenta percreta is significantly higher compared to other locations of caesarean scar pregnancy [17]. Patient 8 in our case series opted to continue with the pregnancy due to personal beliefs. She was able to complete 34 weeks of pregnancy and presented with contractions and spotting. Total abdominal hysterectomy was performed because of placenta accrete. Post-operatively, she remained in intensive care unit (ICU) for five days and was transfused

▶ **Table 2** ▶ HCG levels during MTX injection in relation to symptoms.

Symptom	Positive for symptom				Negative for symptom				P
	N	Mean±SD	Minimum-maximum	Median (Q1 - Q3)	N	Mean±SD	Minimum-maximum	Median (Q1 - Q3)	
Any	14	38167 ± 45188	906–139410	17923 (7217–61645)	5	50148 ± 39424	2313–101542	34907 (33777–78202)	0.4416
Spotting	8	32244 ± 41160	906–122277	17923 (7196–42265.5)	11	47921 ± 45049	1811–139410	34907 (7217–78202)	0.5435
Vaginal bleeding	4	18834 ± 26516	1811–58396	7563.5 (4514–33153)	15	47317 ± 45214	906–139410	33777 (10254–78202)	0.1937
Pain	3	72325 ± 62433	15921–139410	61645 (15921–139410)	16	35507 ± 38358	906–122277	20616 (5677.5–60810)	0.2557

N: number of women in each group.

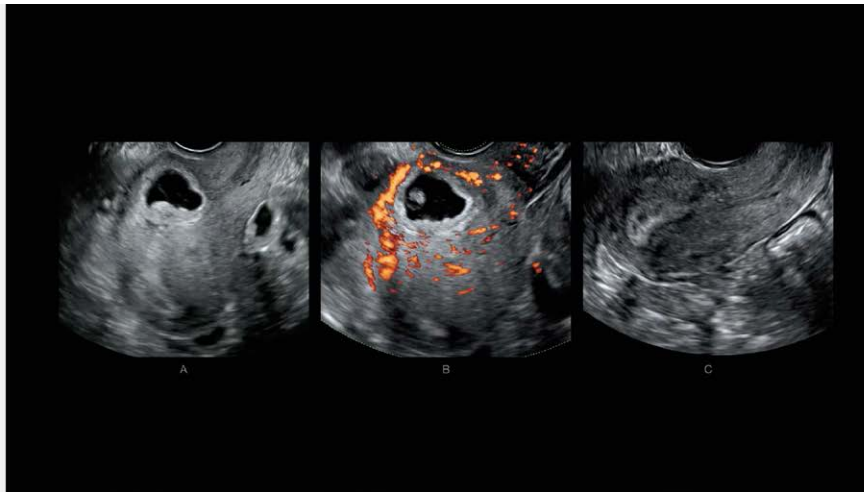
with six units of red blood cells (RBCs) and six units of fresh frozen plasma (FFPs). She recovered well and was discharged after 15 days.

The current evidence regarding the optimal management and proper counselling for caesarean scar pregnancies is sparse and derived from small retrospective series reflecting the need for further research in this field. Various treatment modalities for caesarean scar pregnancy have been described in the literature such as systemic or local methotrexate, intralesional potassium chloride injection, surgical resection, dilatation and curettage with or without hysteroscopy, uterine artery embolization and hysterectomy, bilateral uterine artery chemoembolization combined with dilation and curettage [18, 19]. Since this condition affects women of reproductive age, the treatment of choice should be tailored to preserve fertility. Expectant management is not usually recommended due to the risk of severe complications [7, 19, 20]. Methotrexate is the most widely used treatment modality. Ko et al. [21] reported an 80% success rate with the use of intralesional methotrexate with or without potassium chloride in their series. In the present study, 19 cases were treated with intragestational methotrexate and the efficacy of the method was 89.5%. Only 2 out of 19 patients required complimentary intervention. Of note, none of them experienced side effects associated with methotrexate administration.

Patient 1 received additional intramuscular methotrexate due to HCG levels reaching a plateau on day 21 and on day 28 (4857 mIU/ml and 4971 mIU/ml, respectively). It should be taken into account that she was the first patient treated with intragestational methotrexate in our department and the administration of intramuscular methotrexate could be explained by the lack of experience at the time regarding these cases.

Based on the allocation in our pool of data, patient 6 underwent laparotomy because of massive bleeding during the intrasac injection of methotrexate under ultrasound guidance. Neither bimanual pressure of the uterus nor uterine artery ligation managed to control the bleeding. Therefore, laparotomy was urgently performed, during which uterine rupture was observed at the site of the ectopic implantation on the previous caesarean section scar. The area was repaired with intermittent sutures. The patient was admitted to the ICU for 48 hours and was transfused with three units of RBCs. She remained at the hospital for three more days and then was discharged. Late referral to our unit due to delayed diagnosis of caesarean scar pregnancy (12w5d) as well as high levels of C-reactive protein preoperatively (67 mg/L) that were underestimated could possibly explain the massive bleeding that occurred during the intrasac methotrexate injection.

Overall, our data suggest that intragestational methotrexate under ultrasound guidance is a safe and effective approach for hemodynamically stable patients with caesarean scar pregnancy that wish to maintain their fertility. We observed very low complication rates with this procedure. However, it needs to be performed by an experienced gynecologist in a controlled environment suitable to deal with hemorrhagic complications. Women with caesarean scar pregnancy that undergo this procedure should be counselled about complications such as the risk of bleeding as well as the slow resolution of the pregnancy and the need for contraception until then. On day four following the procedure, HCG levels increased in three patients (16%) on average by 5.8%. For the remaining 16 (84%) women, a decrease in HCG levels was observed, on average by



► **Fig. 6 (a–c):** Patient 2. (a) CSP at 7w4d of gestation; (b) Evidence of peritrophoblastic vascularity on color Doppler; (c) Ultrasonographic appearance of the uterus four months after procedure.

19.9% (min: 1.1%, max: 69.3%). Undetectable HCG levels were observed within an average of 97.6 days following the methotrexate injection, which is consistent with other study findings [21, 22], although the disappearance of the “gestational sac” may occur later

► **Fig. 6 (a–c).**

Conclusion

Our study showed that the most prevalent symptom in caesarean scar pregnancy is vaginal bleeding but often patients are asymptomatic. Transvaginal ultrasound is crucial for timely diagnosis. Although to date, there is no universal agreement regarding the preferred method of choice for managing this rare form of ectopic pregnancy, we suggest that medical management using intragesational methotrexate under transvaginal ultrasound guidance appears to be an effective and safe approach in clinically stable women when performed by an experienced member of an Early Pregnancy Unit. However, this conclusion may be limited due to the retrospective nature of our study involving a small number of patients as well as the individual and often unpredictable progression of this condition.

Conflict of Interest

The authors declare that they have no conflict of interest.

References

- [1] Larsen JV, Solomon MH. Pregnancy in a uterine scar sacculus – an unusual cause of postabortal haemorrhage. *S Afr Med J* 1978; 53: 142–143
- [2] WHO H. WHO statement on caesarean section rates 2015 [Available from: https://www.who.int/reproductivehealth/publications/maternal_perinatal_health/cs-statement/en/]
- [3] Harb HM, Knight M, Bottomley C, Overton C, Tobias A, Gallos ID et al. Caesarean scar pregnancy in the UK: a national cohort study. *Bjog*. 2018; 125: 1663–70.
- [4] Osborn DA, Williams TR, Craig BM. Caesarean scar pregnancy: sonographic and magnetic resonance imaging findings, complications, and treatment. *J Ultrasound Med* 2012; 31: 1449–1456
- [5] Jurkovic D, Jauniaux E, Kurjak A, Hustin J, Campbell S, Nicolaidis KH. Transvaginal color Doppler assessment of the uteroplacental circulation in early pregnancy. *Obstet Gynecol* 1991; 77: 365–369
- [6] Timor-Tritsch IE, Monteagudo A, Cali G, El Refaey H, Kaelin Agten A, Arslan AA. Easy sonographic differential diagnosis between intrauterine pregnancy and cesarean delivery scar pregnancy in the early first trimester. *Am J Obstet Gynecol* 2016; 215: 225.e1–7
- [7] Jurkovic D, Hillaby K, Woelfer B, Lawrence A, Salim R, Elson CJ. First-trimester diagnosis and management of pregnancies implanted into the lower uterine segment Cesarean section scar. *Ultrasound Obstet Gynecol* 2003; 21: 220–227
- [8] Seow KM, Huang LW, Lin YH, Lin MY, Tsai YL, Hwang JL. Caesarean scar pregnancy: issues in management. *Ultrasound Obstet Gynecol* 2004; 23: 247–253
- [9] Yu XL, Zhang N, Zuo WL. [Caesarean scar pregnancy: an analysis of 100 cases]. *Zhonghua Yi Xue Za Zhi* 2011; 91: 3186–3189
- [10] Liang F, He J. Methotrexate-based bilateral uterine arterial chemoembolization for treatment of cesarean scar pregnancy. *Acta Obstet Gynecol Scand* 2010; 89: 1592–1594
- [11] Ash A, Smith A, Maxwell D. Caesarean scar pregnancy. *Bjog* 2007; 114: 253–263
- [12] Collins K, Kothari A. Catastrophic consequences of a caesarean scar pregnancy missed on ultrasound. *Australas J Ultrasound Med* 2015; 18: 150–156
- [13] Zhou X, Li H, Fu X. Identifying possible risk factors for cesarean scar pregnancy based on a retrospective study of 291 cases. *J Obstet Gynaecol Res* 2020; 46: 272–278
- [14] Godin PA, Bassil S, Donnez J. An ectopic pregnancy developing in a previous caesarian section scar. *Fertil Steril* 1997; 67: 398–400
- [15] Monteagudo A, Carreno C, Timor-Tritsch IE. Saline infusion sonohysterography in nonpregnant women with previous cesarean delivery: the “niche” in the scar. *J Ultrasound Med* 2001; 20: 1105–1115

- [16] Timor-Tritsch IE, Monteagudo A, Cali G, Palacios-Jaraquemada JM, Maymon R, Arslan AA et al. Cesarean scar pregnancy and early placenta accreta share common histology. *Ultrasound Obstet Gynecol* 2014; 43: 383–395
- [17] Cali G, Forlani F, Timor-Tritsch IE, Palacios-Jaraquemada J, Minneci G, D'Antonio F. Natural history of Cesarean scar pregnancy on prenatal ultrasound: the crossover sign. *Ultrasound Obstet Gynecol* 2017; 50: 100–104
- [18] Sadeghi H, Rutherford T, Rackow BW, Campbell KH, Duzyj CM, Guess MK et al. Cesarean scar ectopic pregnancy: case series and review of the literature. *Am J Perinatol* 2010; 27: 111–120
- [19] Lan W, Hu D, Li Z, Wang L, Yang W, Hu S. Bilateral uterine artery chemoembolization combined with dilation and curettage for treatment of cesarean scar pregnancy: A method for preserving the uterus. *J Obstet Gynaecol Res* 2013; 39: 1153–1158
- [20] Maymon R, Halperin R, Mendlovic S, Schneider D, Vaknin Z, Herman A et al. Ectopic pregnancies in Caesarean section scars: the 8 year experience of one medical centre. *Hum Reprod* 2004; 19: 278–284
- [21] Ko JK, Li RH, Cheung VY. Cesarean scar pregnancy: a 10-year experience. *Aust N Z J Obstet Gynaecol* 2015; 55: 64–69
- [22] Gerday A, Lourtie A, Pirard C, Laurent P, Wyna C, Jadoul P et al. Experience With Medical Treatment of Cesarean Scar Ectopic Pregnancy (CSEP) With Local Ultrasound-Guided Injection of Methotrexate. *Front Med (Lausanne)* 2020; 7: 564764