



Use of Sodium Channel Blockers in the Thr226Met Pathologic Variant of *SCN1A*: A Case Report

Brenda Carolina Nájera-Chávez¹ Lea Seeber¹ Klaus Goldhahn¹ Axel Panzer¹ 

¹Epilepsy Center - Neuropediatrics, DRK Kliniken Berlin, Westend, Germany

Address for correspondence Axel Panzer, MD, Department of Neuropediatrics, Epilepsy Center, DRK Kliniken Berlin, Spandauer Damm 130, 14050 Berlin, Charlottenburg, Germany (e-mail: a.panzer@drk-kliniken-berlin.de).

Neuropediatrics 2023;54:417–421.

Abstract

The Thr226Met pathologic variant of the *SCN1A* gene has been associated with the clinical development of an early infantile developmental and epileptic encephalopathy (EIDEE) different from Dravet's syndrome. The electrophysiological mechanisms of the mutated channel lead to a paradoxical gain and loss of function. The use of sodium channel blockers (SCB) that counteract this gain of function has been described in previous studies and they can be safely administered to patients carrying mutations in other sodium channel subtypes without causing a worsening of seizures. We report the use of SCB in a child harboring the Thr226Met pathologic variant of *SCN1A* with early-onset pharmaco-resistant migrating seizures, as well as developmental delay. Lacosamide led to a dramatic reduction in seizure frequency; however, only a mild improvement in the epileptic activity depicted by electroencephalography (EEG) was achieved. The introduction of carbamazepine as an add-on therapy led to a notable reduction in epileptic activity via EEG and to an improvement in sensorimotor development. Despite the overall clinical improvement, the patient developed febrile seizures and a non-epileptic jerking of the right hand. In this case of EIDEE with the Thr226Met variant, we demonstrate a beneficial pharmacological intervention of SCB in contrast to findings described in current literature. Our report encourages the cautious use of SCB at early stages of the disease in patients carrying this pathologic variant.

Keywords

- ▶ *SCN1A*
- ▶ Thr226Met
- ▶ early infantile developmental and epileptic encephalopathy
- ▶ sodium channel blocker
- ▶ gain and loss of function
- ▶ voltage gated sodium channel

Introduction

SCN1A variants associated with loss of function in voltage-gated sodium channel (VGSC) NaV1.1 have been widely described and are correlated with a spectrum of epilepsy syndromes extending from the self-limited generalized epilepsy with febrile seizures plus (GEFS+) to Dravet's syndrome (DS).^{1–3} Impaired or mutated NaV1.1 channels, mainly expressed in axons and somata of parvalbumin-positive interneurons (PV), induce excitatory activity. Lower levels of functional NaV1.1 impair the local inhibitory circuits and networks driven by these interneurons.⁴ Truncat-

ing *SCN1A* mutations cause premature truncation of the sodium channel protein, leading to haploinsufficiency. Missense variants that cause mutations in the pore region are associated with loss of function similar to the result of haploinsufficiency. However, missense mutations located in the voltage sensor region results in gain of function (GOF) and loss of function (LOF) of the channel.²

Recently, a Thr226Met missense mutation in the *SCN1A* gene was described and associated with a paradoxical GOF and LOF in sodium channel function, which correlates clinically with a more severe early infantile developmental and epileptic

received

December 4, 2022

accepted after revision

March 9, 2023

accepted manuscript online

July 19, 2023

article published online

September 18, 2023

DOI <https://doi.org/>

10.1055/a-2133-5343.

ISSN 0174-304X.

© 2023. The Author(s).

This is an open access article published by Thieme under the terms of the Creative Commons Attribution-NonDerivative-NonCommercial-License, permitting copying and reproduction so long as the original work is given appropriate credit. Contents may not be used for commercial purposes, or adapted, remixed, transformed or built upon. (<https://creativecommons.org/licenses/by-nc-nd/4.0/>)

Georg Thieme Verlag KG, Rüdigerstraße 14, 70469 Stuttgart, Germany

encephalopathy (EIDEE).^{1,5,6} The electrophysiological mechanisms derived from this variant are multifactorial: the GOF is driven by a hyperpolarizing shift in voltage dependence of activation, which leads to enhanced action potential firing. On the other hand, the LOF is driven by an early excitation that leads to early depolarization block resulting in loss of excitability.⁵ Clinically this correlates with multifocal epileptic discharges driven by depolarization blocks.^{5,7}

The electrophysiological characteristics of this *SCN1A* variant has led us to investigate the possible benefits of sodium channel blockers (SCB) as maintaining therapy, since these could reduce the availability of channels and lessen the sensitivity to depolarization block, counteracting with the GOF properties.⁵ Nevertheless, a potential aggravation of seizures introducing SCB in patients with LOF mutations has been previously reported.⁸ Brunklaus et al¹ described a cohort of GOF *SCN1A* patients who showed seizure reduction after the administration of SCB; however, patients with the p. Thr226Met variant were refractory to SCB use.

Case Report

A 12-week-old infant was referred to our hospital with early-onset migrating focal, tonic, and clonic, afebrile seizures. The pregnancy, perinatal, and familial medical histories were unremarkable. The developmental milestones up to that age were accordingly achieved.

Seizures began approximately at 9 weeks of age showing tonic flexion of one or both legs immediately after waking up followed by erratic myoclonic jerks of the arms and crying (up to 1.5 minutes). When the symptoms exacerbated and were identified as pathologic, the child was admitted to the clinic.

Neurometabolic and imaging evaluations were unremarkable. The first electroencephalography (EEG) performed at

the age of 10 weeks did not show any epileptic activity. At the age of 12 weeks, this patient was transferred to our clinic and parietal discharges with alternating side appeared in the EEG (►Fig. 1). Medication with levetiracetam 60 mg/kg/d was introduced.

Clinical stability was achieved for only 1 week followed by alternating clonic seizures involving the hands, legs, facial musculature, rapid eye blinking, and unilateral atonic posture. Levetiracetam (90 mg/kg/d), pyridoxine (300 mg/kg/d), pyridoxal 5'-phosphate (30 mg/kg/d), folate (3 mg/kg/d), and sultthiame (17 mg/kg/d) were given without any improvement. Ketogenic diet (KET) and phenobarbital (PB) showed a temporary effect on seizure frequency and alertness. At the age of 7 months, we introduced clobazam (0.5 mg/kg/d) due to clinical and EEG worsening (►Fig. 2A). Nevertheless, our patient was never free from alternating hemiclonic seizures and myoclonus of the right hand (3–6 episodes per day). The EEG showed a gaining proportion of high amplitude and hypersynchronous activity (►Fig. 2B). When the results of the multigene panel testing (next-generation sequencing with Nextera DNA Flex Pre-Enrichment Library Prep), which confirmed a heterozygote pathogenic variant c.677C > T, p. (Thr226Met) in the *SCN1A* gene, were available, we introduced a therapy with the SCB lacosamide (LCM) 8 mg/kg/d (blood level: 5.39 mg/L; therapeutic level: 1–10 mg/L).

This led to a massive reduction in the frequency and intensity of seizures up to complete seizure remission, but the nonepileptic jerking of the right hand remained. The EEG showed only little improvement; therefore, carbamazepine (CBZ) up to 12.6 mg/kg/d was added at the age of 11 months (blood level: 9.3 mg/L; therapeutic level: 8–12 mg/L). The follow-up EEG after 2 weeks showed a reduction of epileptic discharges (►Fig. 2C), and an improvement in the sensorimotor development was observed. Since the introduction of SCB, only three febrile seizures were seen (hemiclonic and

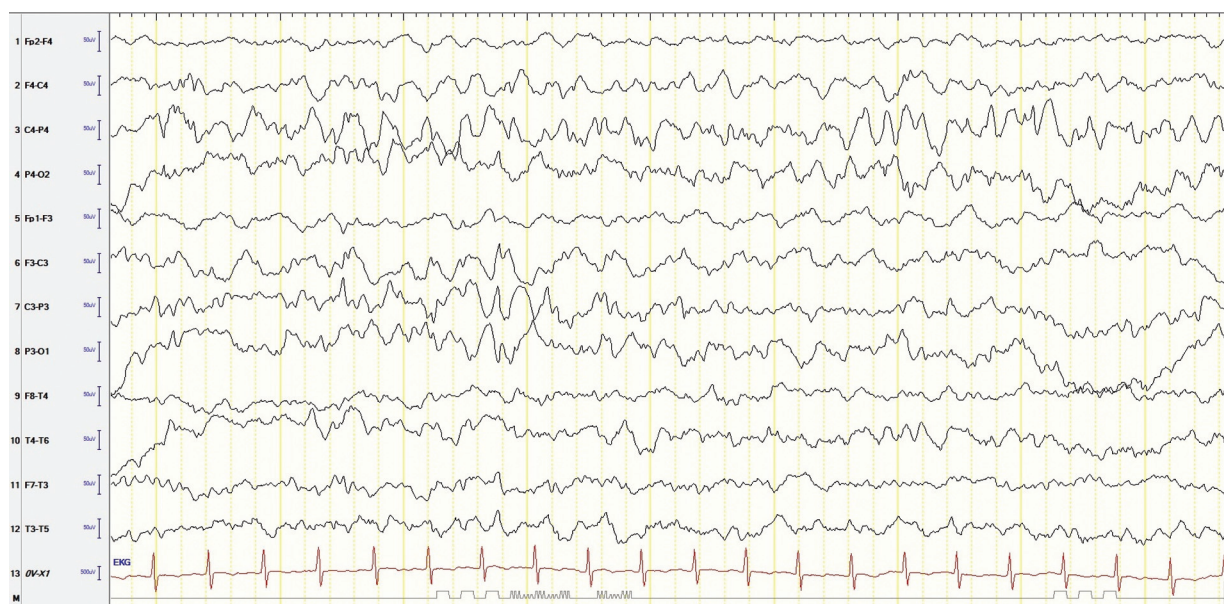


Fig. 1 Electroencephalographic (EEG) recording at the age of 13 weeks. SI 10–20 longitudinal montage, 7 µV/m, HF 35 Hz, LF 0.1 seconds. First pathologic EEG showing multifocal sharp waves. SI, spike index; HF, high frequency; LF, low frequency.

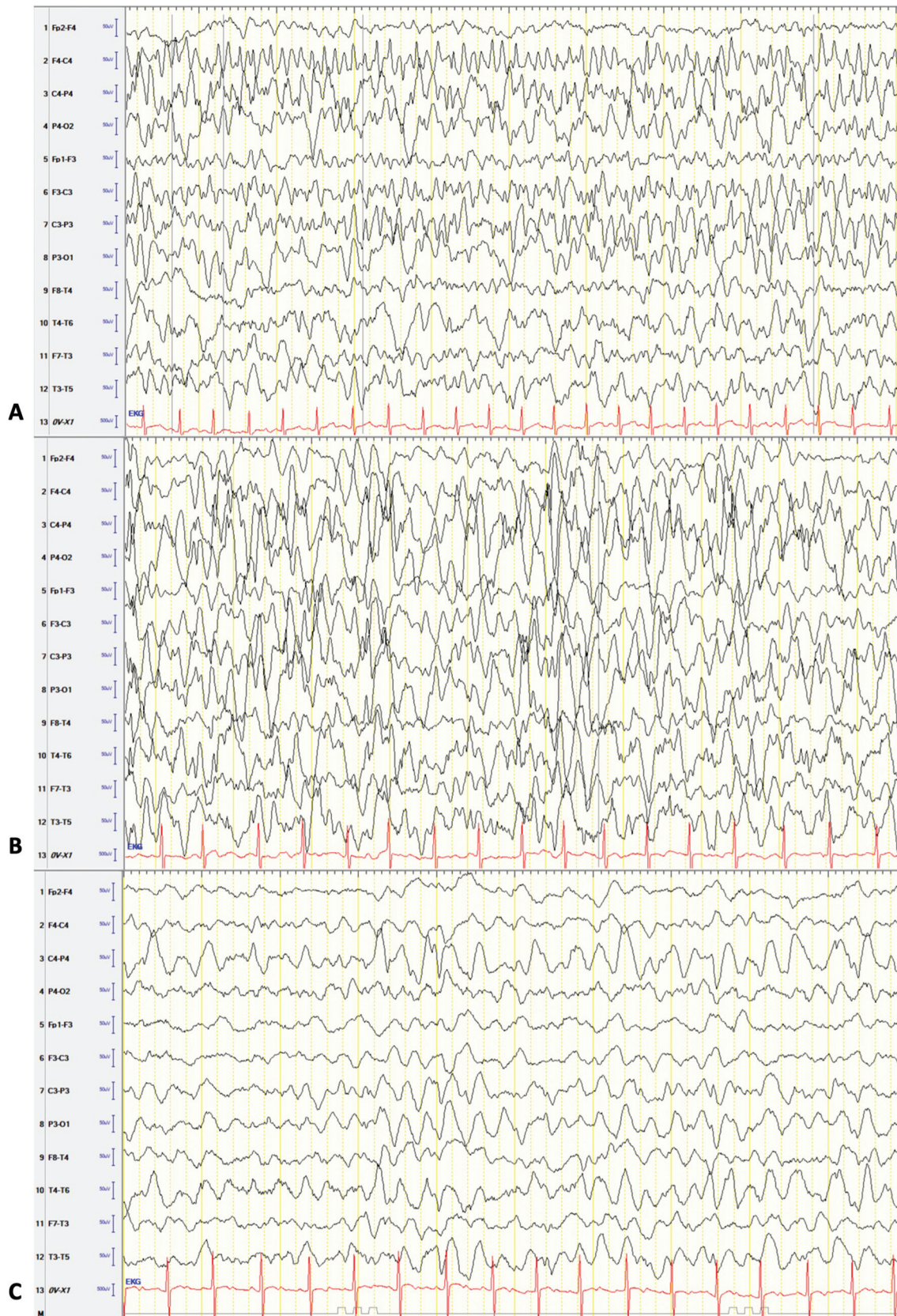


Fig. 2 Electroencephalographic (EEG) recordings SI 10–20 longitudinal montage, 7 $\mu\text{V}/\text{m}$, HF 35 Hz, and LF 0.1 seconds. (A) EEG at the age of 7 months. Seizures were present while recording, clinically the child was staring with open deviated eyes, arms in abduction, and legs in flexion. Spikes in the posterior and central brain regions were observed on both sides. (B) EEG at the age of 9 months shows hypersynchronous activity with sharp waves and spikes bilateral with secondary generalization. (C) EEG at the age of 11 months shows an improvement in the background activity as well as isolated sharp waves.

generalized tonic-clonic); therefore, valproate (35 mg/kg/d) was introduced (blood level: 36 mg/L; therapeutic level: 50–100 mg/L).

At the age of 5 months, developmental delay with generalized hypertonia became noticeable for the first time, which progressed up to the age of 12 months. In the meantime, after the introduction of SCB, the infant began to interact actively and grasp objects, but there was still a massive hypotonia (stable sitting remained difficult). At the age of 17 months, the child remains free from seizures without any epileptic discharges or encephalopathic pattern in the EEG.

Discussion

This report describes the efficacy of the use of SCB in an infant carrying the Thr226Met pathogenic variant of the *SCN1A* gene associated with a mix of GOF and LOF.

Sadleir et al⁶ speculated a possible GOF of the channel in the Thr226Met pathogenic variant as seen in other subtypes of the VGSC (e.g., *SCN2A* and *SCN8A*). Berecki et al⁵ demonstrated a paradoxical GOF and LOF in VGSC using electrophysiological studies. A key factor responsible for this hyperexcitation is a missense mutation in a conserved threonine residue in the S4 segment of domain I, which accounts for most of the gating charge.^{3,9}

The use of SCB to reduce the availability of channels and lessen the sensitivity to depolarization block has already been speculated and tested on patients by Brunklaus et al.¹ That study evaluated different GOF *SCN1A* cohorts and reported seizure reduction in the majority of patients except in the group carrying the p.Thr226Met variant (10 patients). Two of these patients belonged to their study group and the other eight were a part of the cohort studied by Sadleir et al.⁶ Brunklaus et al¹ did not report the use of any SCB for one of these two patients (patient 22). In the second patient (patient 23), the use of oxcarbazepine and carbamazepine is described as having “no effect.” However, they also did not report worsening of the condition under this treatment. A direct clinical comparison of these two patients with our case cannot be achieved, given the lack of use of LCM. Sadleir et al⁶ did not report the use of LCM in any of their patients either. Additionally, none of these studies report the age of introduction of SCB. Consequently, we speculate that the combination of drugs that selectively enhances slow and also fast inactivation of VGSC¹⁰ led to the described improvement in our case. Furthermore, early introduction of SCB might have an impact on the clinical improvement as well. This would be consistent with the findings of Wang et al,¹¹ who reported a peak distribution of Nav1.1 at 7 to 9 months of age, which then decreased and stabilized during childhood and adulthood. Therefore, an early introduction of SCB might be crucial in achieving effective treatment.

The antiepileptic mechanism of SCB such as CBZ relies on the enhanced fast inactivation of VGSC mediated by an intracellular peptide loop located between domains III and IV, whereas one for LCM has been associated with enhanced slow inactivation and is thought to be involved with the rearrangement of the inner pore structure.¹²

The development of febrile seizures after the introduction of SCB is susceptible to speculations. Several studies have investigated the effect of high temperatures in the development of seizures in models of DS, which account for the LOF properties of the channel.^{13,14} It has been described that at 40°C the mutant DIII voltage-sensing domain is altered by a shift in hyperpolarization and slows the action of the intracellular peptide loop, leading to fast inactivation. Therefore, at higher temperatures, the fast inactivation properties of the channel are enhanced leading to LOF.¹³

Volkers et al¹⁴ also found that the stability of the inactivation gates of the Nav1.1 channels is highly temperature dependent. At 40°C, the DS mutated variant showed fever-induced gating defects in combination with biophysical ion channel alterations that also led to LOF.¹⁴

Overall, we speculate that late development of febrile seizures in our patient is due to the use of SCB that counteracts with the GOF properties of the mutated channel, leaving the LOF properties intact, which are highly susceptible to temperatures as described earlier. In other words, after the effective introduction of SCB, the clinical features of our patient shifted to a more DS-like phenotype.

We speculate that the remaining myoclonic jerks of the arm in our patient might be associated with a beginning movement disorder in terms of tremor or hyperkinesia and not as a result of epileptic activity.

Further research to investigate the electrochemical properties of the Nav1.1 mutated channel and to understand the mechanisms of the already described development of motor disorders as well as the association with fever are warranted. More standardized clinical studies with the use of SCB for this particular mutation may improve the clinical state and quality of life of children carrying the Thr226Met pathologic variant of *SCN1A*.

Conclusion

The Thr226Met pathologic variant of *SCN1A* has been associated with a paradoxical GOF and LOF in the Nav1.1 VGSC and with a more severe EIDEE. We report the implementation of SCB treatment in a patient harboring a variant that led to clinical improvement in terms of reduction in seizure frequency and sensorimotor development, as well as reduction of epileptic activity demonstrated by EEG. Further long-term observational and larger studies are required to understand the clinical and pharmaceutical dynamics of these drugs in this cohort of patients.

Conflict of Interest

None declared.

References

- 1 Brunklaus A, Brünger T, Feng T, et al. The gain of function *SCN1A* disorder spectrum: novel epilepsy phenotypes and therapeutic implications. *Brain* 2022;145(11):3816–3831
- 2 Meng H, Xu HQ, Yu L, et al. The *SCN1A* mutation database: updating information and analysis of the relationships among

- genotype, functional alteration, and phenotype. *Hum Mutat* 2015;36(06):573–580
- 3 Zuberi SM, Brunklaus A, Birch R, Reavey E, Duncan J, Forbes GH. Genotype-phenotype associations in *SCN1A*-related epilepsies. *Neurology* 2011;76(07):594–600
 - 4 Ogiwara I, Miyamoto H, Morita N, et al. Nav1.1 localizes to axons of parvalbumin-positive inhibitory interneurons: a circuit basis for epileptic seizures in mice carrying an *Scn1a* gene mutation. *J Neurosci* 2007;27(22):5903–5914
 - 5 Berecki G, Bryson A, Terhag J, et al. *SCN1A* gain of function in early infantile encephalopathy. *Ann Neurol* 2019;85(04):514–525
 - 6 Sadleir LG, Mountier EI, Gill D, et al; DDD Study. Not all *SCN1A* epileptic encephalopathies are Dravet syndrome: early profound Thr226Met phenotype. *Neurology* 2017;89(10):1035–1042
 - 7 Bikson M, Hahn PJ, Fox JE, Jefferys JGR. Depolarization block of neurons during maintenance of electrographic seizures. *J Neurophysiol* 2003;90(04):2402–2408
 - 8 Liao WP, Shi YW, Long YS, et al. Partial epilepsy with antecedent febrile seizures and seizure aggravation by antiepileptic drugs: Associated with loss of function of Nav1.1: PEFS+ and Loss of Function of Nav1.1. *Epilepsia* 2010;51(09):1669–1678
 - 9 Catterall WA. From ionic currents to molecular mechanisms: the structure and function of voltage-gated sodium channels. *Neuron* 2000;26(01):13–25
 - 10 Kellinghaus C. Lacosamide as treatment for partial epilepsy: mechanisms of action, pharmacology, effects, and safety. *Ther Clin Risk Manag* 2009;5:757–766
 - 11 Wang W, Takashima S, Segawa Y, et al. The developmental changes of Na(v)1.1 and Na(v)1.2 expression in the human hippocampus and temporal lobe. *Brain Res* 2011;1389:61–70
 - 12 Rogawski MA, Tofighty A, White HS, Matagne A, Wolff C. Current understanding of the mechanism of action of the antiepileptic drug lacosamide. *Epilepsy Res* 2015;110:189–205
 - 13 Peters C, Rosch RE, Hughes E, Ruben PC. Temperature-dependent changes in neuronal dynamics in a patient with an *SCN1A* mutation and hyperthermia induced seizures. *Sci Rep* 2016;6(01):31879
 - 14 Volkens L, Kahlig KM, Das JHG, et al. Febrile temperatures unmask biophysical defects in Nav1.1 epilepsy mutations supportive of seizure initiation. *J Gen Physiol* 2013;142(06):641–653