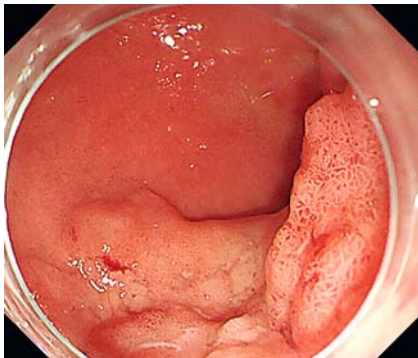
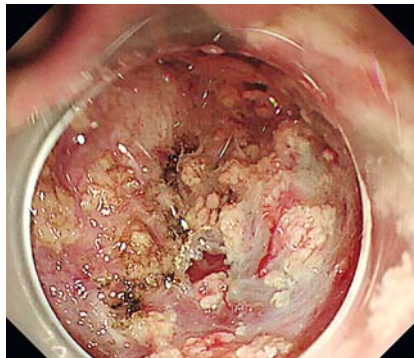


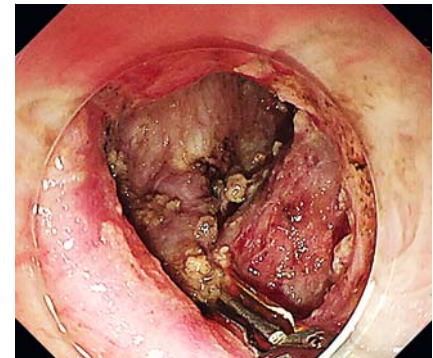
## Complete sealing of a duodenal perforation during endoscopic submucosal dissection using a novel through-the-scope twin clip



► **Fig. 1** Endoscopic view of a sessile lesion with uneven surface situated in the duodenal bulb, histologically confirmed as villous tubular adenoma.



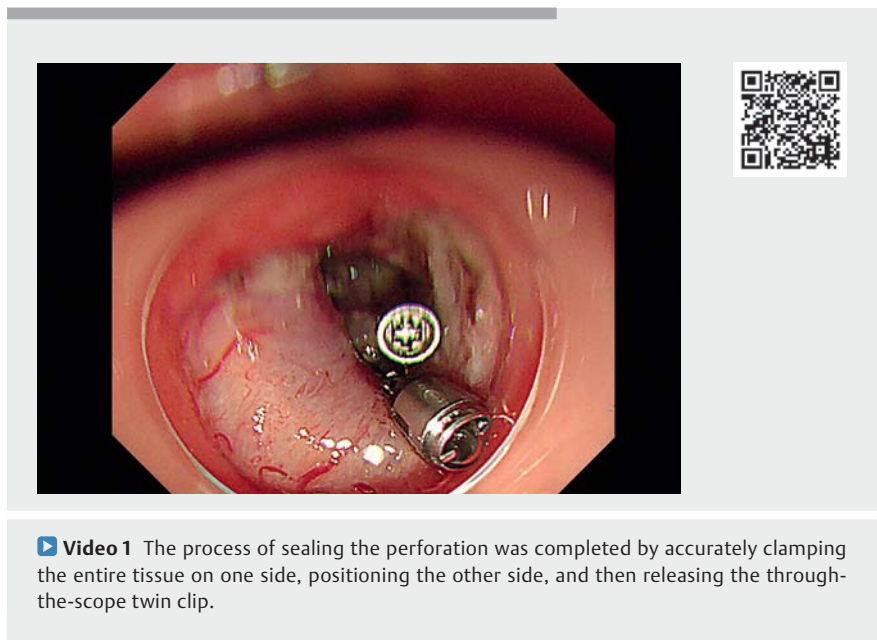
► **Fig. 2** Perforation occurred during endoscopic submucosal dissection.



► **Fig. 3** Perforation sealed with a through-the-scope twin clip.

Intraprocedure and postprocedure perforation are serious complications that limit the clinical application of endoscopic submucosal dissection (ESD) for duodenal neoplasia; thus, how to seal a perforation of the duodenum during ESD efficiently and safely is an important topic. Current sealing instruments include conventional through-the-scope (TTS) clips with or without nylon purse-string sutures, over-the-scope (OTS) clips, and high-end suture devices; however, these are time-consuming, high-cost, and difficult to use for sealing large perforations [1, 2]. We report the successful application of a novel TTS twin clip (TTS-TC), which is expected to achieve efficient closure of large perforations in difficult locations, in sealing a duodenal perforation that occurred during ESD [1, 3–5].

A 54-year-old man who was diagnosed with a villous tubular adenoma in the duodenal bulb at a local hospital 5 months ago was referred to our hospital to undergo endoscopic resection. The esophagogastroduodenoscopy (EGD) showed the presence in the bulb of a sessile lesion with an uneven surface and an estimated size of 6×4 cm (► **Fig. 1**). The nonlifting sign was positive after initial submucosal injection with sodium hyaluronate solution. ESD with clip-line trac-



► **Video 1** The process of sealing the perforation was completed by accurately clamping the entire tissue on one side, positioning the other side, and then releasing the through-the-scope twin clip.

tion was performed to remove the lesion, during which obvious submucosal fibrosis and Brunner's gland hyperplasia were observed. The lesion was successfully removed but the removal was complicated by a 3-mm perforation (► **Fig. 2**). The perforation was closed by inserting a TTS-TC (► **Fig. 3**) through the biopsy channel of the endoscope, accurately clamping one side of the entire duodenal wall layer near the perforation, positioning the other side, and then releasing the

TTS-TC (► **Video 1**). The patient fasted for 3 days and was discharged after 7 days with no postoperative complications and no residue or recurrence observed by EGD performed 3 months later. The TTS-TC is an accurate, efficient, and safe instrument for sealing duodenal perforation occurring during ESD, with excellent clamping and closing force.

Endoscopy\_UCTN\_Code\_CCL\_1AD\_2AG

## Funding

Development of portable multi-purpose medical electronic endoscope system for field operation  
012016018300812203

## Competing interests

The authors declare that they have no conflict of interest.

## The authors

**Xianzong Ma<sup>1,2\*</sup>, Lang Yang<sup>2,3\*</sup>, Dongliang Yu<sup>2</sup>, Jie Zhang<sup>2</sup>, Zilin Kang<sup>2</sup>, Peng Jin<sup>2,3,1</sup>**

- 1 Medical School of Chinese PLA, Beijing, P. R. China
- 2 Department of Gastroenterology, The Seventh Medical Center of Chinese PLA General Hospital, Beijing, P. R. China
- 3 Senior Department of Gastroenterology, The First Medical Center of Chinese PLA General Hospital, Beijing, P. R. China

## Corresponding author

### **Peng Jin, MD, PhD**

Senior Department of Gastroenterology, The First Medical Center of Chinese PLA General Hospital, No.28 Fuxing Road, Haidian District, Beijing, 100853, P. R. China  
dr\_pengjin@qq.com

## References

- [1] Zhang Q, Jin HY, Shen ZH et al. Novel through-the-scope twin clip for the closure of GI wounds: the first experimental survival study in pigs (with videos). *Gastrointest Endosc* 2021; 94: 850–858.e2
- [2] Modi RM, Shami VM. Making endoscopic submucosal dissection in the duodenum safer: is it possible? *Gastrointest Endosc* 2021; 93: 950–951
- [3] Zhang Q, Wang Z, Liu S. Gastric bypass was performed with a novel through-the-scope twin clip under endoscopy. *Endoscopy* 2022; 54: E962–E963
- [4] Zhang Q. A novel through-the-scope twin clip traction-assisted endoscopic submucosal dissection in an in vitro pig stomach model. *Endoscopy* 2021; 53: E259–E260
- [5] Zhang Q, Wang Z, Bai Y. A novel through-the-scope twin endoclip for a large mucosal closure in a live pig model. *Endoscopy* 2019; 51: E372–E373

## Citation Format

*Endoscopy* 2023; 55: E505–E506.  
doi: 10.1055/a-2037-5002.

## Bibliography

*Endoscopy* 2023; 55: 776–777  
DOI 10.1055/a-2108-0098  
ISSN 0013-726X

© 2023. The Author(s).

This is an open access article published by Thieme under the terms of the Creative Commons Attribution-NonDerivative-NonCommercial License, permitting copying and reproduction so long as the original work is given appropriate credit. Contents may not be used for commercial purposes, or adapted, remixed, transformed or built upon. (<https://creativecommons.org/licenses/by-nc-nd/4.0/>)

Georg Thieme Verlag KG, Rüdigerstraße 14, 70469 Stuttgart, Germany



### ENDOSCOPY E-VIDEOS

<https://eref.thieme.de/e-videos>



*Endoscopy E-Videos* is an open access online section, reporting on interesting cases

and new techniques in gastroenterological endoscopy. All papers include a high quality video and all contributions are freely accessible online. Processing charges apply, discounts and waivers acc. to HINARI are available.

This section has its own submission website at

<https://mc.manuscriptcentral.com/e-videos>

\* X. Ma and L. Yang are co-first authors and contributed equally to this work.