



# Unilateral Lung Agenesis: A Case Series and Review of Literature

Jennifer Weber, DO<sup>1</sup> Sunil Kumar Sati, MBBS<sup>2</sup> Vijender Rao Karody, MD<sup>2</sup>

<sup>1</sup>Department of Pediatrics, Medical College of Wisconsin, Milwaukee, Wisconsin

<sup>2</sup>Division of Neonatology, Department of Pediatrics, Medical College of Wisconsin, Milwaukee, Wisconsin

**Address for correspondence** Jennifer Weber, DO, Department of Pediatrics, Medical College of Wisconsin, 8915 W Connell Ct, Milwaukee, WI 53226 (e-mail: jennifer.weber719@gmail.com).

AJP Rep 2023;13:e40–e43.

## Abstract

### Keywords

- unilateral lung agenesis
- congenital abnormality
- neonate
- respiratory distress after birth

Unilateral lung agenesis is a rare congenital abnormality that typically presents with respiratory distress after birth. Prognostic factors include the side of the lung affected along with the presence or absence of other congenital abnormalities. Prenatal imaging can make the diagnosis that can assist the healthcare team in preparing to care for the neonate, as well as set expectations for the family. In this case series, we describe three cases of unilateral lung agenesis, two infants with right lung agenesis, and one with the left. We describe their presentation, provide a brief clinical course, and discuss outcomes.

Lung agenesis is a rare congenital abnormality that is defined as the absence of lung tissue along with the absence of bronchi. It is a rare phenomenon with the incidence from one report from North England of 1.22 cases per 100,000 live births.<sup>1</sup> It can be unilateral or bilateral, with bilateral lung agenesis being uniformly fatal soon after birth. Unilateral lung agenesis can affect the right or the left side, but right lung agenesis has been found to have a worse prognosis than the left.<sup>2</sup> The presentation can vary from prenatal diagnosis with ultrasound (US) or magnetic resonance imaging (MRI) to a symptomatic infant with severe respiratory failure postnatally. Rarely, unilateral lung agenesis is diagnosed in later life on routine chest imaging. The diagnosis is usually confirmed with a computed tomography (CT) scan that shows an absence of lung parenchyma, mediastinal shift to the affected side, and ipsilateral bronchus remnants.<sup>3</sup> Associated anomalies are common with lung agenesis and dictate prognosis. Here, we describe three neonates from our institute with unilateral lung agenesis with a brief review of the literature.

## Description of Cases

**Case 1:** Term infant with prenatal diagnosis of (TOF) and intrauterine growth restriction (IUGR) who was diagnosed with left lung agenesis after birth.

A term male born at 37 weeks with prenatally diagnosed TOF and IUGR. He presented with respiratory distress at birth and was intubated soon after. Chest X-ray showed apparent collapse of the left lung (► **Fig. 1**). A computed tomography angiogram (CTA) was obtained on the second day of life that showed left lung agenesis with volume loss and compensatory expansion of the other lung with mediastinal shift, in addition to TOF, and absent left pulmonary artery (► **Fig. 2**). The neonatal intensive care unit course was complicated by significant respiratory distress needing invasive respiratory support followed by noninvasive support via continuous positive pressure ventilation and high flow nasal cannula. Due to his TOF with significant right ventricular outflow tract (RVOT) obstruction and significant oxygen needs, he received prostaglandin treatment initially to keep his duct

received

April 18, 2023

accepted after revision

May 23, 2023

accepted manuscript online

June 7, 2023

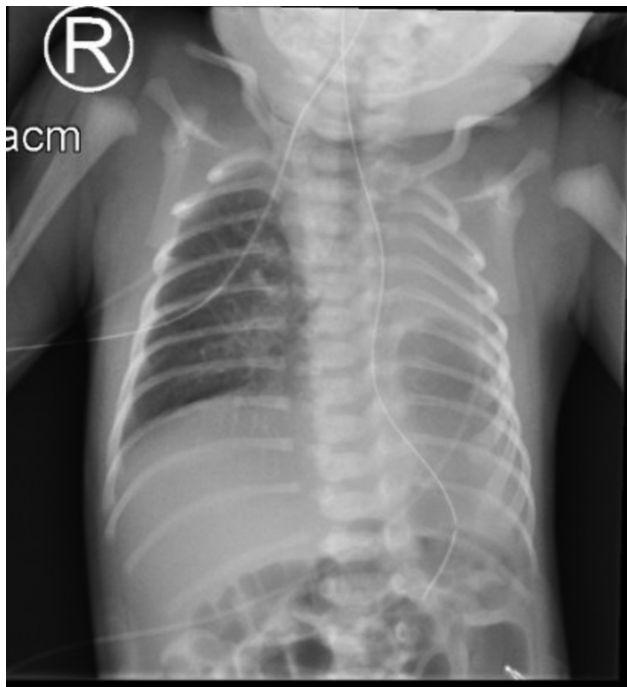
DOI <https://doi.org/10.1055/a-2107-0651>.

ISSN 2157-6998.

© 2023. The Author(s).

This is an open access article published by Thieme under the terms of the Creative Commons Attribution-NonDerivative-NonCommercial-License, permitting copying and reproduction so long as the original work is given appropriate credit. Contents may not be used for commercial purposes, or adapted, remixed, transformed or built upon. (<https://creativecommons.org/licenses/by-nc-nd/4.0/>)

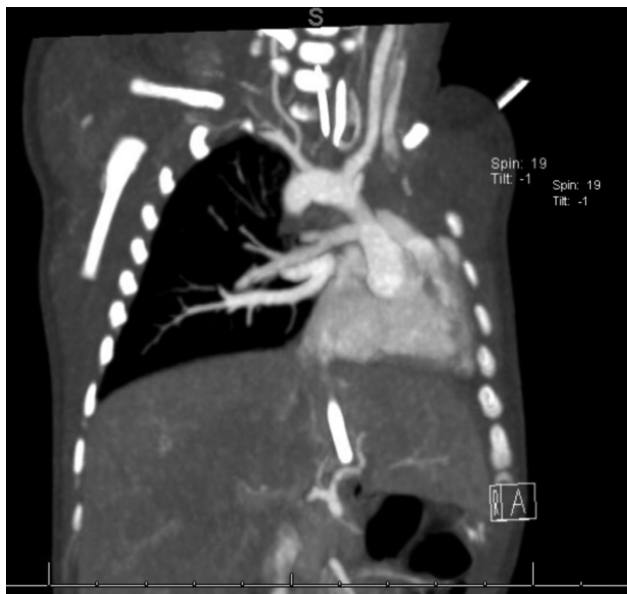Thieme Medical Publishers, Inc., 333 Seventh Avenue, 18th Floor, New York, NY 10001, USA



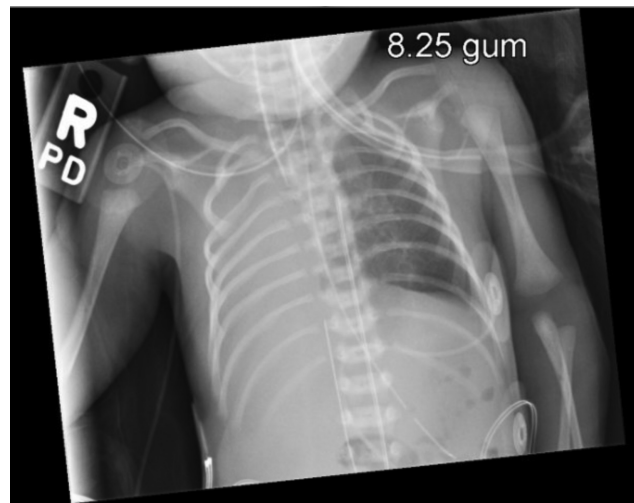**Fig. 1** Chest X-ray of first case showing opacification of left hemithorax.

open to augment his pulmonary blood flow, which was discontinued after he underwent RVOT stent placement. Airway evaluation with flexible bronchoscopy during third week of life revealed absent left mainstem bronchus, no tracheal rings, and no airway malacia. He was discharged home around 1 month of life on home oxygen. Since discharge, he had a successful repair of TOF and remains on home oxygen.

**Case 2:** Preterm infant with prenatal diagnosis of ventriculomegaly, dextrocardia, left renal agenesis, and right lung agenesis.



**Fig. 2** Computed tomographic angiogram of first case confirming absence of left lung and absent left pulmonary artery.

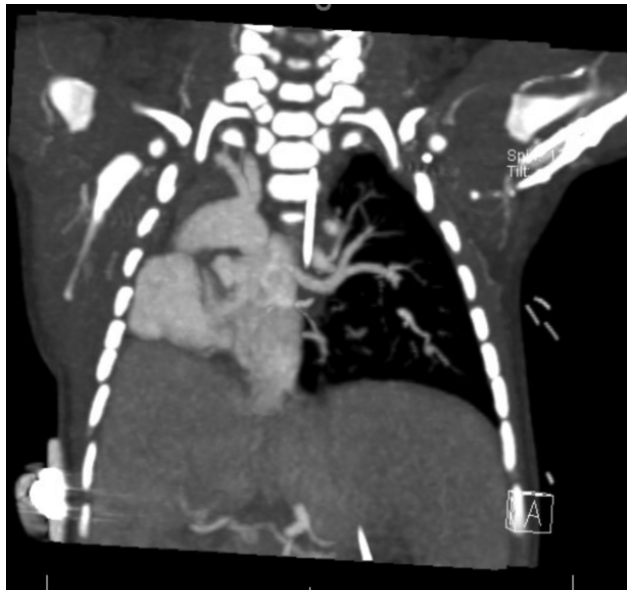

**Fig. 3** Chest X-ray of second case showing total opacification of right lung.

A preterm male born at 32 weeks and 5 days with prenatal concerns of cerebral ventriculomegaly, dextrocardia, hypoplastic/aplastic right lung, single right pelvic kidney, left renal agenesis, and mild IUGR. He was intubated at birth for severe respiratory distress. Chest X-ray showed opacification of right hemithorax with a rightward shift of mediastinum (► **Fig. 3**). CTA revealed an absent right lung, right mainstem bronchus, right pulmonary artery, and right pulmonary veins. Flexible bronchoscopy performed while on ventilator showed complete tracheal rings and ongoing collapse. He underwent a sliding tracheoplasty, left pulmonary vein repair, and left pulmonary artery plasty on cardiopulmonary bypass. The postoperative period was complicated by the need for venoarterial extracorporeal membrane oxygenation due to severe pulmonary hypertension and the inability to ventilate. He remained critically ill with refractory shock needing multiple inotropes and hydrocortisone. With continued clinical deterioration, he developed anasarca refractory to fluid restriction and diuretics. Due to his worsening condition, the family made a loving decision to withdraw extraordinary measures at 38 days of life and declined an autopsy.

**Case 3:** Preterm infant with prenatal diagnosis of heterotaxy syndrome, atrioventricular (AV) canal defect, pulmonary atresia, duodenal atresia, and was found to have right lung agenesis postnatally.

A preterm male born at 34 weeks with prenatally diagnosed heterotaxy, AV canal defect, pulmonary atresia, and duodenal atresia. This case was recently published by our institution with reference below.<sup>4</sup> He developed respiratory distress soon after birth needing intubation and mechanical ventilation. Chest X-ray showed diffuse opacity over the right lung field. CT chest obtained showed systemic veins and pulmonary veins returning to the left atrium, aorta arising from the right ventricle, large ventricular and atrial septal defects, complete pulmonary atresia, hypoplastic lower lobe and left lung supplied by collateral arteries from descending thoracic aorta, and complete AV canal with double outlet right ventricle (► **Fig. 4**). His single ventricle physiology along



**Fig. 4** Computed tomographic angiogram of third case confirming absence of right lung, along with aorta arising from right ventricle and left lung supplied from collaterals from descending thoracic aorta.

with the right lung agenesis was deemed inoperable by cardiology and cardiothoracic surgeons. After discussions with the family, his goals of care were changed to palliative care, and he was extubated to noninvasive ventilation on the fourth day of life. His clinical condition continued to deteriorate, and he died at 25 days of life. An autopsy was performed and confirmed the diagnosis of right lung agenesis, duodenal atresia, as well as multiple cardiac findings including dextrocardia, complete AV septal defect, aorta arising from right ventricle, anomalous pulmonary venous return, and single major left-sided aortopulmonary collateral artery branching from mid-descending aorta to the left lung hilum.

## Discussion

Ever since De Pozze described the first case of lung agenesis in 1673 in an autopsy, a few hundred cases have been described in the literature with an estimated incidence of 1 in 10,000 to 1 in 15,000 autopsies.<sup>5</sup> Possible etiologies include an embryologic defect of the lung, vascular tissues, or from an in utero vascular event.<sup>3</sup> Lung agenesis is a rare respiratory tract malformation that represents a failure of the primitive foregut branches, or lung buds, to develop very early on in the first trimester between weeks 3 and 7 of the

gestation. Developmental arrest at later stage results in aplasia or hypoplasia of the lung.<sup>6</sup> Lung agenesis is classified into three different groups as shown in **Table 2**.

Lung agenesis can present in a variety of ways. With more sophisticated prenatal US and MRI imaging widely available, more cases are diagnosed prenatally. Ito et al in 2013 summarized 19 reported cases of pulmonary hypoplasia or agenesis prenatally evaluated by US and/or MRI.<sup>7</sup> In 13 out of 19 cases described, the diagnosis of lung agenesis was made by US alone, while MRI was needed in the other 6 cases. Prenatal diagnosis with the US can be challenging with isolated lung agenesis and the absence of other fetal anomalies. While the prenatal US can still detect most thoracic abnormalities, MRI is more accurate and correlates better with postnatal diagnosis.<sup>8</sup> Often the first clue of lung agenesis in prenatal US is a cardio mediastinal shift but a fetal cardio mediastinal shift is seen more often with congenital diaphragmatic hernia or cystic lung malformation. Zhang et al described the role of the invisible ipsilateral pulmonary artery in the diagnosis of unilateral lung agenesis.<sup>9</sup> Our three cases did not have a prenatal MRI that might be the reason why the diagnosis of lung agenesis specifically was not suspected prenatally. Accurate prenatal diagnosis not only helps with better multidisciplinary management of the neonate but also creates a better understanding and expectations for the family.

The clinical presentation of unilateral lung agenesis can be variable with most patients being diagnosed postnatally. Fukuoka et al in 2022 published a systematic review of 259 published cases of lung agenesis.<sup>10</sup> In their review, 137 cases were diagnosed in the neonatal period and 40 cases (29%) had a suspicion based on prenatal US and/or MRI. Symptomatic neonates have varying degrees of respiratory distress and severity depends on other associated anomalies. A wide variety of congenital anomalies have been described with lung agenesis, but cardiovascular anomalies were the most common, seen in 40% of patients in Fukuoka et al's review. It was followed by skeletal anomalies (30%), gastrointestinal (GI; 20%), tracheal stenosis (20%), and genitourinary (14%) anomalies. All three patients in our series had cardiovascular abnormalities as shown in **Table 1**. Patient 3 had a GI anomaly (duodenal atresia) and patient 2 had left renal agenesis. Some patients remain asymptomatic and are missed during the neonatal period. They are usually diagnosed during a workup for recurrent lung infections. Many times, children with undiagnosed lung agenesis are initially misdiagnosed as foreign body inhalation.<sup>11,12</sup> Imaging studies play a very important role in the diagnosis of lung

**Table 1** Associated congenital anomalies in our patients with unilateral lung agenesis

Other congenital anomaly	Case 1	Case 2	Case 3
Cardiac	TOF	Ventriculomegaly, dextrocardia	AV canal defect
Gastrointestinal			Duodenal atresia
Renal		Left renal agenesis	

Abbreviations: AV, atrioventricular; TOF, tetralogy of Fallot

**Table 2** Anatomical types of lung agenesis

Types of lung agenesis	Anatomical defect
Type 1 (agenesis)	Complete absence of the lung parenchyma, its vasculature, and the bronchus
Type 2 (aplasia)	Rudimentary bronchus with complete absence of pulmonary parenchyma
Type 3 (hypoplasia)	Presence of variable amounts of pulmonary parenchyma, bronchus, and vasculature

agenesis in the neonates. Chest X-ray usually shows complete opacity of the affected side with hyperinflation and herniation of contralateral lung to the affected side. CT scan with three-dimensional reconstruction can confirm the type of lung agenesis in most cases by better delineation of the lung parenchyma and bronchial tree anatomy. A CT scan can also detect other associated thoracic anomalies as was shown in all three cases from our institution.

Treatment of lung agenesis is symptomatic with surgical correction of associated cardiac, or GI anomalies. Unlike bilateral lung agenesis, which is uniformly fatal soon after birth, the prognosis of unilateral lung agenesis has improved in the past few decades owing to prenatal diagnosis and better neonatal care. Overall reported mortality in unilateral lung agenesis is around 30% with higher mortality in right compared with left lung agenesis.<sup>10</sup> We saw a similar trend in our patients with both of our right-sided lung agenesis patients succumbing to their condition. Survival in unilateral lung agenesis depends on associated anomalies. Fukuoka et al reported higher mortality in patients with associated tracheal stenosis, and cardiac or GI anomalies.<sup>10</sup>

## Conclusion

In this article, we reviewed three cases of unilateral lung agenesis, two with right lung agenesis, and one with the left. Our findings were consistent with the literature of worse prognosis in patients with right lung agenesis compared with left, as well as the presence of other congenital abnormalities. Prenatal US can provide a high suspicion for the diagnosis and MRI is the most accurate imaging method. Making the diagnosis in the prenatal period can assist the healthcare team in preparing how to best care for the patient along with providing expectations for the family.

## Conflict of Interest

None declared.

## References

- Robertson N, Miller N, Rankin J, McKean M, Brodlie M, Thomas M. Congenital lung agenesis: incidence and outcome in the north of England. *Birth Defects Res* 2017;109(11):857–859
- Schaffer AJ, Rider RV. A note on the prognosis of pulmonary agenesis and hypoplasia according to the side affected. *J Thorac Surg* 1957;33(03):379–382
- Iyer VH, Charki S, Ramachandra KS. Aplasia of the lung in a neonate—the myth is explored. *BMJ Case Rep* 2015. Doi: 10.1136/bcr-2015-212508
- Berlin K, Cabacungan E, Hopp A, Jarzembowski J, Karody V. Post-intubation respiratory failure in an infant with multiple congenital anomalies. *Neoreviews* 2022;23(08):e589–e594
- Brereton RJ, Rickwood AM. Esophageal atresia with pulmonary agenesis. *J Pediatr Surg* 1983;18(05):618–620
- Sun X. Normal and abnormal structural development of lung. In Richard J Martin, Avroy A. Fanaroff, Michele C. Walsh, eds. *Fanaroff and Martin's Neonatal and Perinatal Medicine Disease of the Fetus and Infant*. 11th ed. Elsevier 2020:585–599
- Ito Y, Tanemoto T, Kato A, et al. Usefulness of ultrasonography and MRI for diagnosis of fetal pulmonary agenesis: case report and review of the literature. *J Med Ultrason* 2013;40(02):157–162
- Levine D, Barnewolt CE, Mehta TS, Trop I, Estroff J, Wong G. Fetal thoracic abnormalities: MR imaging. *Radiology* 2003;228(02):379–388
- Zhang Y, Fan M, Ren WD, et al. Prenatal diagnosis of fetal unilateral lung agenesis complicated with cardiac malposition. *BMC Pregnancy Childbirth* 2013;13:79
- Fukuoka S, Yamamura K, Nagata H, et al. Clinical outcomes of pulmonary agenesis: a systematic review of the literature. *Pediatr Pulmonol* 2022;57(12):3060–3068
- Xie L, Zhao J, Shen J. Clinical diagnostic approach to congenital agenesis of right lung with dextrocardia: a case report with review of literature. *Clin Respir J* 2016;10(06):805–808
- Kumar B, Kandpal DK, Sharma C, Sinha DD. Right lung agenesis. *Afr J Paediatr Surg* 2008;5(02):102–104