

The role of ultrasound in first-trimester screening after the introduction of NIPT as a service of public health insurance – a consensus statement of the Fetal Medicine Foundation (FMF) Germany

Die Rolle des Ersttrimester-Screenings nach Einführung von NIPT als Kassenleistung. Ein Konsensus-Statement der Fetal Medicine Foundation (FMF) Deutschland

Authors

Eberhard Merz¹, Bernd Eiben², Christian Thode³, Bernhard-Joachim Hackelöer⁴, Renaldo Faber⁵, Sevgi Tercanli⁶, Rudolf Alkier⁷

Affiliations

- 1 Obstetrics & Gynecology, Centre for Ultrasound and Prenatal Medicine, Frankfurt, Germany
- 2 Institut für Klinische Genetik Nordrhein, Labor Eiben Glaubitz, Essen, Germany
- 3 Laboratoriumsmedizin, MVZ wagnerstibbe für Laboratoriumsmedizin und Pathologie GmbH, Göttingen, Germany
- 4 Gynecology and Prenatal Medicine, Pränatale-Gynäkologie-Mammasonografie Hamburg, Praxis, Hamburg, Germany
- 5 Leipzig, Center of Prenatal Medicine, Leipzig, Germany
- 6 Praxis, Universitätsspital Basel, Basel, Switzerland
- 7 Clinical Chemistry, Labor Enders Prof Dr med Gisela Enders and Colleagues MVZ GbR, Stuttgart, Germany

Key words

Combined first-trimester screening, contingent screening, cell-free fetal DNA, prenatal ultrasound, chromosome anomalies

received 29.01.2023

accepted after revision 22.05.2023

published online 01.08.2023

Bibliography

Ultraschall in Med 2023; 44: 600–605

DOI 10.1055/a-2104-2689

ISSN 0172-4614

© 2023, Thieme. All rights reserved.

Georg Thieme Verlag KG, Rüdigerstraße 14, 70469 Stuttgart, Germany

Correspondence

Prof. Eberhard Merz

Obstetrics & Gynecology, Centre for Ultrasound and Prenatal Medicine, Ebersheimstr. 5, 60320 Frankfurt, Germany
merz.eberhard@web.de

ABSTRACT

Combined first-trimester screening (FTS) and noninvasive prenatal testing (NIPT) have been proven to be reliable noninvasive procedures to detect the most common chromosomal abnormalities (trisomies 21, 18, 13) in the first trimester. The aim of this paper is to demonstrate the strengths and limitations of these two procedures and to give a consensus statement of the Fetal Medicine Foundation (FMF) Germany on how to use the two techniques in the first trimester after the introduction of NIPT as a service of the statutory health insurance companies in Germany.

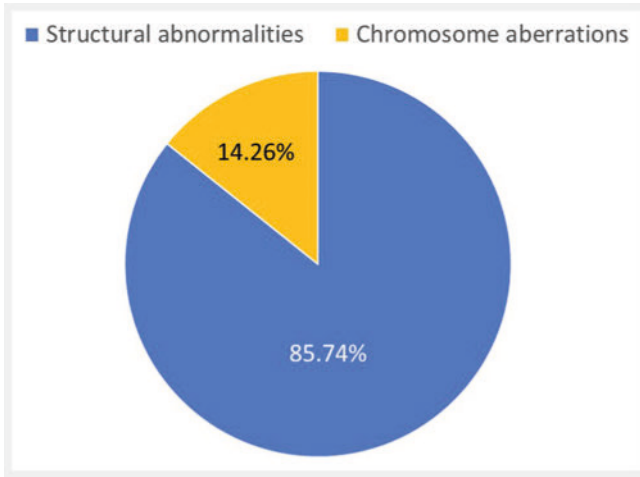
ZUSAMMENFASSUNG

Das kombinierte Ersttrimester-Screening und der nichtinvasive DNA-Test (NIPT) haben sich als verlässliche nichtinvasive Verfahren zur Diagnostik der häufigsten Chromosomen-Anomalien (Trisomie 21, 18, 13) im 1. Trimenon gezeigt. Das Ziel dieser Publikation ist es, die Stärken, wie auch die Limitierungen, beider Verfahren aufzuzeigen und ein Konsensus-Statement der Fetal Medicine Foundation (FMF) Deutschland abzugeben, wie beide Techniken im 1. Trimenon eingesetzt werden sollen, nachdem NIPT als Kassenleistung in Deutschland eingeführt wurde.

Introduction

For two decades, combined first-trimester screening (FTS), including data on maternal age, ultrasound markers, and biochem-

ical parameters, had been the most reliable noninvasive procedure to calculate the risk of chromosomal abnormalities between 11 + 0 and 13 + 6 weeks of gestation [1, 2, 3, 4, 5]. The introduction of noninvasive prenatal tests by sequencing cell-free placen-



► **Fig. 1** Incidence of structural and chromosomal abnormalities (based on Eurocat [11]).

tal DNA from maternal blood has changed the spectrum of prenatal screening rapidly due to a higher detection rate of trisomy 21, 18, 13, sex chromosomal abnormalities, and a few deletions [6, 7, 8, 9, 10]. However, chromosomal abnormalities (37.28/10,000) account for only 14.26% of the total spectrum of all malformations (261.41/10,000 including live births, stillbirths, and termination of pregnancy) (EUROCAT 2013–2019 [11]). Most of the fetal malformations are structural defects (► **Fig. 1**) which can usually be detected by a qualified ultrasound examination.

NIPT requires only withdrawal of blood from the mother and transfer of the sample to the laboratory to gain a reliable estimation of the risk of common chromosomal anomalies without any need for an ultrasound examination. First-trimester screening, however, includes a detailed ultrasound examination that must be performed by a qualified operator.

The introduction of NIPT as a service of the statutory health insurance companies in Germany on July 1, 2022 has increased the chance to offer NIPT to pregnant women as a first-line procedure without any qualified ultrasound examination. Consequently, structural malformations and other genetic anomalies may remain undetected in the first trimester.

The aim of this paper is to compare combined FTS and NIPT, to give an overview of the advantages and limitations of the two procedures and give recommendations on how to apply both techniques in daily practice.

Strengths and limitations of FTS and NIPT

The strengths of combined first-trimester screening and NIPT, and the limitations of the two techniques are listed in ► **Table 1**, ► **Table 2**, ► **Table 3**, ► **Table 4**, ► **Table 5**.

Discussion

The main goal of early prenatal screening is to provide the parents-to-be with accurate information about their fetus. Undoubt-

► **Table 1** Advantages of combined first-trimester screening.

Ultrasound allows early detection of abnormal fetal growth.
Ultrasound allows detection of normal and abnormal multiples.
Ultrasound allows early detection of many structural fetal defects [12, 13, 14, 15, 16] (see ► Table 3).
Ultrasound allows detection of an abnormal placental structure.
Transvaginal ultrasound allows good assessment of fetal anatomy in obese women.
First-trimester screening based on MA, NT, NB, TV flow, DV flow shows a detection rate of trisomy 21 of 94.5% when using a cut-off value of 1: 500 [17].
First-trimester screening based on MA, NT, NB, TV flow, DV flow in combination with a detailed anomaly scan allows the detection of 95.6% of fetuses with trisomies 18 and 13, triploidy and Turner syndrome in combination with an anomaly scan [18].
Serum biomarkers have potential value in the detection of atypical genetic anomalies [19, 20, 21].
Women can be informed of the result of their risk assessment within one day.
Combination with early preeclampsia screening [22, 23].
The number of invasive procedures can be reduced.
Detection of a structural fetal defect enables targeted invasive procedures and further genetic analysis if necessary.
MA = maternal age, NT = fetal nuchal translucency, NB = nasal bone, TV = tricuspid valve, DV = Ductus venosus

► **Table 2** Limitations of combined first-trimester screening.

Early detection of fetal malformations requires expert knowledge and high-quality ultrasound equipment.
Tight gestational age range (11 + 0 – 13 + 6 weeks of gestation).
Several structural fetal malformations cannot be detected before the second or third trimester (see ► Table 3).
First-trimester screening has a lower detection rate of trisomies 21, 13 and 18 than NIPT.
First-trimester risk calculation including ultrasound criteria and biochemistry from maternal blood does not allow the precise detection of rare chromosomal abnormalities.
Combined first-trimester screening has a false-positive result of 3.51 in the trisomy 21 group and 2.07 in the trisomy 13/18 group [24].

edly, cell-free fetal DNA screening in maternal blood (NIPT) is currently the best noninvasive screening test for assessing the risk of trisomies 21, 18, 13 and sex chromosomal abnormalities [26], and it also has some value in assessing the risk of 22q11.2 deletion syndrome [28, 29]. However, NIPT is still an advanced screening test and not a diagnostic test. It may be limited by its moderate to low positive predictive value, especially for conditions with low prevalence in the tested population. Furthermore, the test has several limitations (see ► **Table 5**) and requires qualified genetic

► **Table 3** Structural fetal defects detectable and not detectable with 3D ultrasound in the first trimester [25].

Structural defects detectable with 3D ultrasound in the first trimester	Structural defects not detectable with 3D ultrasound in the first trimester
Yolk sac abnormalities	Microcephaly
Umbilical cysts	Macrocephaly
Exencephaly/anencephaly	Ventriculomegaly
Encephalocele	Agenesis of corpus callosum
Holoprosencephaly	Subtle cardiac defects
Facial clefts/absent nasal bone/retrognathia	Lung abnormalities
Low set ears	Bowel obstruction
Spina bifida	Hydronephrosis
Severe cardiac defects	Bladder exstrophy
Abdominal wall defects	Achondroplasia
Hydrops	Pena-Shokeir syndrome
Megacystis	
Achondrogenesis	
Limb defects, polydactyly	
Body stalk anomaly	
Kartagener syndrome	
Severe amniotic band syndrome	
Conjoined twins	
Single umbilical artery	

► **Table 4** Advantages of NIPT (cell-free DNA analysis).

NIPT can be performed reliably from 10 weeks of gestation and does not have an upper gestational limit such as FTS.

Simplicity of the procedure, no special training required. However, qualified pre- and post-test counseling is necessary.

High detection rate of trisomy 21 (99.7%), trisomy 18 (97.9%), and trisomy 13 (99.0%) and sex chromosome aneuploidies (SCA) (monosomy X 95.8%, SCA other than monosomy X (100%) [26] and a few individual deletions such as 22q11.2 [27, 28, 29] or 13q31.1 [30].

The number of invasive procedures can be reduced.

counseling prior to the test and after the test result is available (German Gene Diagnostics Act [37]).

The implementation of NIPT in public-health-based programs allows two different application models: 1. NIPT as a first-line screening tool (effectively replacing conventional serum and NT screening) [38, 39] or 2. NIPT as a second screening step (contingent screening model) in the case of an abnormal FTS result [38, 40]. The advantages of NIPT for first-line screening are the simplicity of the procedure and the fact that there is no need for specialized training besides qualifications in prenatal counseling.

► **Table 5** Limitations of NIPT.

NIPT is an advanced screening test for trisomies 21, 18, and 13 and sex chromosome aberrations [31, 32], but has currently no value in the detection of many other chromosomal abnormalities.

NIPT has limited value in the detection of deletions [28, 29].

NIPT may produce false-positive results: trisomy 21 (0.04%), trisomy 18 (0.04%), trisomy 13 (0.04%) and sex chromosome aneuploidies (SCA) (monosomy X 0.14%, SCA other than monosomy X (0.004%) [26], and false-negative results [33].

NIPT does not allow the detection of structural defects of the fetus.

NIPT is limited to singleton and twin pregnancies.

NIPT is contraindicated in higher degree multiples.

NIPT is contraindicated in vanishing twin.

The time until the result is available is longer than with first-trimester screening.

Low fetal cfDNA fraction <4% in maternal blood is seen in about 2–5% of the cases [34] and results with low fetal fractions are of limited value or fail to provide a result after one blood drawing.

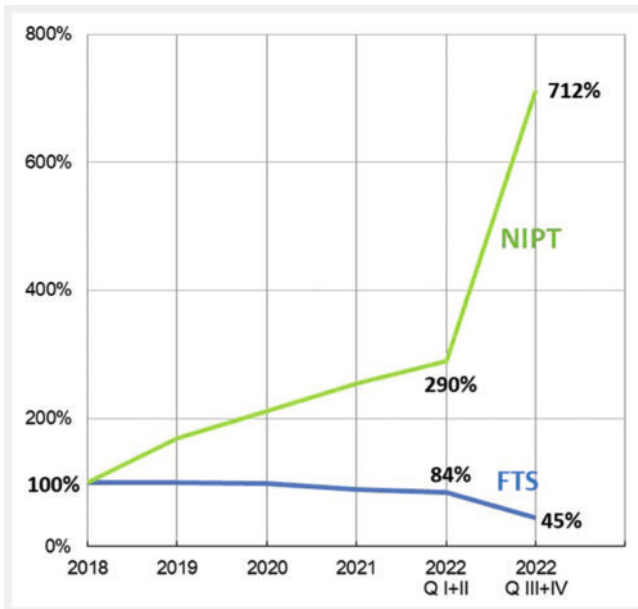
In obese pregnant women the risk of a low fetal cfDNA fraction in maternal blood is increased [35].

In pregnancies with failed cfDNA test, fetal chromosomal abnormalities are over-represented [34, 36].

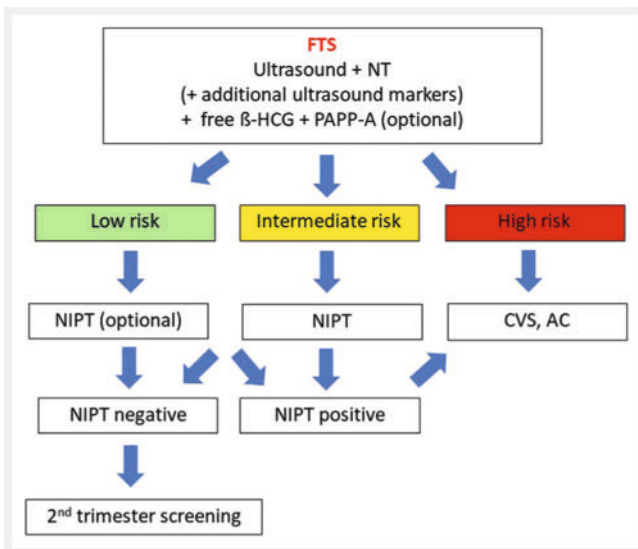
However, it is only a test for trisomies 21, 18, 13 and sex chromosomal abnormalities and, if performed without any ultrasound examination, no structural abnormalities or other genetic anomalies can be detected. Contingent screening using FTS with a qualified fetal anatomy scan first allows exclusion or detection of structural defects and – after risk assessment – differentiation between high-risk, intermediate-risk and low-risk groups [5, 41]. If there is normal sonoanatomy and the risk assessment shows a result in the intermediate or low-risk group, NIPT can be performed as soon as the FTS risk assessment is available or, alternatively, NIPT can be performed directly after the FTS anatomy scan has shown no structural abnormality. For cases with detected fetal abnormalities (suspicious ultrasound marker or structural abnormality), NIPT is not recommended, and invasive testing should be performed instead. However, the enactment of a contingent model requires an already well-established national screening program based on combined first-trimester screening including NT measurement and serum biochemistry [38]. In all countries where a qualified and standardized ultrasound examination and a qualified FTS AUDIT are guaranteed (such as with FMF UK or FMF Germany) [5, 41], a contingent screening [40, 42, 43] seems to be the preferred approach.

With the introduction of NIPT as a service covered by the statutory health insurance companies in Germany – while FTS is still a service for self-payers – a tremendous increase in NIPT and a decrease in FTS could be observed [44] (► Fig. 2).

NIPT, performed as first-line screening without any prior ultrasound examination, does not allow the detection of any fetal structural malformations, early fetal growth restriction, twin abnormalities, or abnormal placental structure. In contrast, qualified combined first-trimester screening with a detailed ultrasound ex-



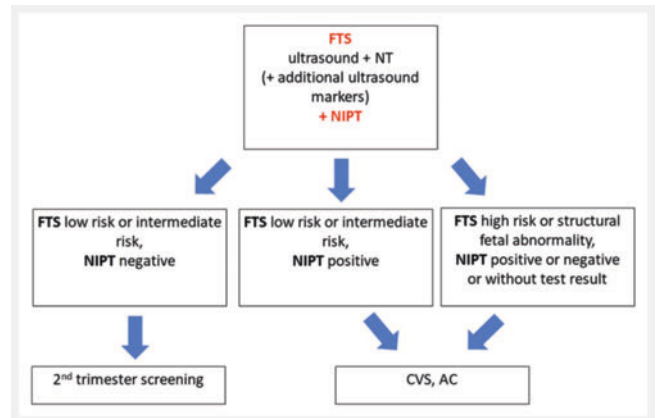
► **Fig. 2** Percentage of first-trimester screening and NIPT before and after the introduction of NIPT as a service of the statutory health insurance companies in Germany on July 1, 2022. The data from 2019 to 2022 are related to the data from 2018 (100%). (Data according to Eiben et al. 2023) [44]. Q = Quarter.



► **Fig. 3** Recommended first-trimester screening (contingent procedure): FTS first and NIPT as a second step.

amination allows the detection of the most common trisomies, triploidy, and the demonstration or exclusion of various structural defects (► **Table 3**). As early prenatal screening provides more than just risk assessment of trisomies 21, 18 and 13, every pregnant woman should receive comprehensive information about current noninvasive and invasive procedures and early pre-eclampsia screening [22, 23, 46, 47].

There is broad consensus in several ultrasound societies and publications that a detailed first-trimester ultrasound examina-



► **Fig. 4** Recommended first-trimester screening (combined procedure): FTS and NIPT together (however, ultrasound should be done first!).

tion should always be performed prior to an NIPT procedure [40, 47, 48, 49, 50, 51, 52].

Since NIPT has been covered by statutory health insurance since July 1, 2022, NIPT will become more popular and FTS biochemical screening, which is subject to a fee, will continue to decline. The hormone parameters free β -HCG and PAPP-A will no longer have the importance they had in pre-NIPT times, but they may continue to be offered as an option, or in situations where NIPT is not recommended (e.g., vanishing twin) or in cases with very low fetal DNA fractions. On the other hand, PAPP-A is a biomarker that is also used in pre-eclampsia screening in the first trimester [23].

As a result, FMF Germany recommends performing NIPT as a contingent procedure, either once the FTS results are available (► **Fig. 3**) or directly after the FTS ultrasound examination has shown no structural fetal malformation and normal NT (► **Fig. 4**).

Conclusion

While NIPT is currently focusing on screening for trisomy 21, 18, 13 and sex chromosomal abnormalities only, combined first-trimester screening with a detailed ultrasound check of the fetal anatomy is of major importance for the early detection of structural defects. Consequently, NIPT should not replace combined first-trimester screening with a detailed check of the fetal morphology. Therefore, the optimal first-trimester screening approach would be to first perform a detailed ultrasound examination and a risk calculation with the basic parameters of maternal age, crown-rump length, and nuchal translucency thickness, and – for experienced operators – with the additional ultrasound parameters absence/ presence of nasal bone, ductus venosus flow, and tricuspid regurgitation. If no structural abnormality is found and the risk assessment shows a result in the low-risk or intermediate-risk group, NIPT can be performed for advanced screening for trisomies 21, 18, 13 and sex chromosome aneuploidies. If a structural abnormality is detected during the ultrasound examination, NIPT is no longer advisable and instead, CVS or an amniocentesis should be performed for karyotyping (► **Fig. 3**)

► **Table 6** Recommendations for early prenatal screening [after Merz [50]].

1. NIPT should never be performed in the first trimester without a prior ultrasound examination.
2. NIPT is currently limited to the detection of trisomy 21, 18, 13, aberrations of sex chromosomes, and individual deletions.
3. First-trimester screening between gestational weeks 11 + 0 and 13 + 6 continues to be valid since ultrasound examination makes it possible to detect not only chromosomal but also structural abnormalities.
4. In the case of sonographic detection of a fetal abnormality, direct diagnosis via invasive testing without NIPT should be performed.
5. In Germany, both NIPT and first-trimester screening are subject to the Genetic Diagnosis Act, i. e., patients must be counseled prior to the examination as well as once the results are available.
6. A normal ultrasound examination in the first trimester does not necessarily rule out fetal anomalies. Therefore, second-trimester screening between gestational weeks 18 + 0 and 21 + 6 continues to be a standard part of prenatal testing.

as well as microarray [53] and genome sequencing [54, 55] if required.

Finally, the key statements for early prenatal screening are listed in ► **Table 6**.

Conflict of Interest

The authors declare that they have no conflict of interest.

References

- [1] Nicolaides KH, Azar G, Byrne D et al. Fetal nuchal translucency: ultrasound screening for chromosomal defects in first trimester of pregnancy. *BMJ* 1992; 304: 867–869. doi:10.1136/bmj.304.6831.867
- [2] Nicolaides KH, Brizot ML, Sniijders RJ. Fetal nuchal translucency: ultrasound screening for fetal trisomy in the first trimester of pregnancy. *Br J Obstet Gynaecol* 1994; 101 (9): 782–786. doi:10.1111/j.1471-0528.1994.tb11946.x
- [3] Sniijders RJ, Noble P, Sebire N et al. UK multicentre project on assessment of risk of trisomy 21 by maternal age and fetal nuchal-translucency thickness at 10–14 weeks of gestation. *Fetal Medicine Foundation First Trimester Screening Group. Lancet* 1998; 352: 343–346. doi:10.1016/s0140-6736(97)11280-6
- [4] Merz E, Thode C, Alkier A et al. A new approach to calculating the risk of chromosomal abnormalities with first-trimester screening data. *Ultraschall Med* 2008; 29 (6): 639–645. doi:10.1055/s-2008-1027958
- [5] Merz E, Thode C, Hackelöer BJ et al. The Fetal Medicine Foundation (FMF) Germany after 20 Years – Quality Assurance of Ultrasound Examinations during First Trimester Screening. *Ultraschall Med* 2022; 43 (2): 115–119. doi:10.1055/a-1745-6879
- [6] Lo YM, Chan KC, Sun H et al. Maternal plasma DNA sequencing reveals the genome-wide genetic and mutational profile of the fetus. *Sci Transl Med* 2010; 2 (61): 61ra91. doi:10.1126/scitranslmed.3001720
- [7] Bianchi DW, Parker RL, Wentworth J et al. DNA sequencing versus standard prenatal aneuploidy screening. *N Engl J Med* 2014; 370 (9): 799–808. doi:10.1056/NEJMoa1311037
- [8] Taylor-Phillips S, Freeman K, Geppert J et al. Accuracy of non-invasive prenatal testing using cell-free DNA for detection of Down, Edwards and Patau syndromes: a systematic review and meta-analysis. *BMJ Open* 2016; 6 (1): e010002. doi:10.1136/bmjopen-2015-010002
- [9] Borth H, Teubert A, Glaubitz R et al. Analysis of cell-free DNA in a consecutive series of 13,607 routine cases for the detection of fetal chromosomal aneuploidies in a single center in Germany. *Arch Gynecol Obstet* 2021; 303 (6): 1407–1414. doi:10.1007/s00404-020-05856-0
- [10] Eiben B, Borth H, Kutur N et al. Clinical experience with noninvasive prenatal testing in Germany: Analysis of over 500 high-risk cases for trisomy 21, 18, 13 and monosomy X. *Obstet Gynecol Rep* 2021; 5: 1–7 <https://www.oatext.com/pdf/OGR-5-157.pdf>
- [11] Interactive EUROCAT prevalence charts. https://eu-rd-platform.jrc.ec.europa.eu/eurocat/eurocat-data/prevalence_en
- [12] Syngelaki A, Chelemen T, Dagklis T et al. Challenges in the diagnosis of fetal non-chromosomal abnormalities at 11–13 weeks. *Prenat Diagn* 2011; 31 (1): 90–102. doi:10.1002/pd.2642
- [13] Karim JN, Roberts NW, Salomon LJ et al. Systematic review of first-trimester ultrasound screening for detection of fetal structural anomalies and factors that affect screening performance. *Ultrasound Obstet Gynecol* 2017; 50 (4): 429–441. doi:10.1002/uog.17246
- [14] Syngelaki A, Hammami A, Bower S et al. Diagnosis of fetal non-chromosomal abnormalities on routine ultrasound examination at 11–13 weeks' gestation. *Ultrasound Obstet Gynecol* 2019; 54 (4): 468–476. doi:10.1002/uog.20844
- [15] Yoshizato T, Kozuma Y, Horinouchi T et al. Diagnosis of Fetal Abnormalities during the First Trimester. *Kurume Med J* 2021; 66 (2): 85–92. doi:10.2739/kurumemedj.MS662002
- [16] Kenkhuis MJA, Bakker M, Bardi F et al. Effectiveness of 12–13-week scan for early diagnosis of fetal congenital anomalies in the cell-free DNA era. *Ultrasound Obstet Gynecol* 2018; 51 (4): 463–469. doi:10.1002/uog.17487
- [17] Merz E, Thode C, Eiben B et al. Prenatal Risk Calculation (PRC) 3.0: An Extended DoE-Based First-Trimester Screening Algorithm Allowing for Early Blood Sampling. *Ultrasound Int Open* 2016; 2 (1): E19–26. doi:10.1055/s-0035-1569403
- [18] Wagner P, Sonek J, Hoopmann M et al. First-trimester screening for trisomies 18 and 13, triploidy and Turner syndrome by detailed early anomaly scan. *Ultrasound Obstet Gynecol* 2016; 48 (4): 446–451. doi:10.1002/uog.15829
- [19] Tørring N, Petersen OB, Becher N et al. First trimester screening for other trisomies than trisomy 21, 18, and 13. *Prenat Diagn* 2015; 35 (6): 612–619. doi:10.1002/pd.4584
- [20] Lindquist A, Poulton A, Halliday J et al. Prenatal diagnostic testing and atypical chromosome abnormalities following combined first-trimester screening: implications for contingent models of non-invasive prenatal testing. *Ultrasound Obstet Gynecol* 2018; 51 (4): 487–492. doi:10.1002/uog.18979
- [21] Vogel I, Petersen OB. Prenatal screening for atypical chromosomal abnormalities: past or future? *Ultrasound Obstet Gynecol* 2018; 51 (4): 434–435. doi:10.1002/uog.19030
- [22] Chaemsaitong P, Sahota DS, Poon LC. First trimester preeclampsia screening and prediction. *Am J Obstet Gynecol* 2022; 226 (Suppl. 2): S1071–S1097.e2. doi:10.1016/j.ajog.2020.07.020
- [23] Mazer Zumaeta A, Wright A, Syngelaki A et al. Screening for preeclampsia at 11–13 weeks' gestation: use of pregnancy-associated plasma protein-A, placental growth factor or both. *Ultrasound Obstet Gynecol* 2020; 56 (3): 400–407. doi:10.1002/uog.22093
- [24] Merz E, Thode C, Eiben B et al. Individualized correction for maternal weight in calculating the risk of chromosomal abnormalities with first-trimester screening data. *Ultraschall Med* 2011; 32 (1): 33–39. doi:10.1055/s-0029-1246001
- [25] Merz E, Pashaj S. Embryonic and early fetal abnormalities diagnosed with three-dimensional ultrasound in the 1st trimester. In: Kurjak A,

- Chervenak F, (eds.) Embryo as a person and as a patient. New Delhi – London – Panama: Jaypee Brothers Medical Publishers; 2020: 51–64
- [26] Gil MM, Accurti V, Santacruz B et al. Analysis of cell-free DNA in maternal blood in screening for aneuploidies: updated meta-analysis. *Ultrasound Obstet Gynecol* 2017; 50 (3): 302–314. doi:10.1002/uog.17484
- [27] Gross SJ, Stosic M, McDonald-McGinn DM et al. Clinical experience with single-nucleotide polymorphism-based non-invasive prenatal screening for 22q11.2 deletion syndrome. *Ultrasound Obstet Gynecol* 2016; 47 (2): 177–183. doi:10.1002/uog.15754
- [28] Bevilacqua E, Jani JC, Chaoui R et al. Performance of a targeted cell-free DNA prenatal test for 22q11.2 deletion in a large clinical cohort. *Ultrasound Obstet Gynecol* 2021; 58 (4): 597–602. doi:10.1002/uog.23699
- [29] Kagan KO, Hoopmann M, Pfaff T et al. First Trimester Screening for Common Trisomies and Microdeletion 22q11.2 Syndrome Using Cell-Free DNA: A Prospective Clinical Study. *Fetal Diagn Ther* 2020; 47 (11): 841–852. doi:10.1159/000510069
- [30] Jia Y, Zhao H, Shi D et al. Genetic effects of a 13q31.1 microdeletion detected by noninvasive prenatal testing (NIPT). *Int J Clin Exp Pathol* 2014; 7 (10): 7003–7011
- [31] Bianchi DW, Wilkins-Haug L. Integration of noninvasive DNA testing for aneuploidy into prenatal care: what has happened since the rubber met the road? *Clin Chem* 2014; 60 (1): 78–87. doi:10.1373/clinchem.2013.202663
- [32] Suci I, Galeva S, Abdel Azim S et al. First-trimester screening-biomarkers and cell-free DNA. *J Matern Fetal Neonatal Med* 2021; 34 (23): 3983–3989. doi:10.1080/14767058.2019.1698031
- [33] Van Opstal D, Srebnik MI, Polak J et al. False Negative NIPT Results: Risk Figures for Chromosomes 13, 18 and 21 Based on Chorionic Villi Results in 5967 Cases and Literature Review. *PLoS One* 2016; 11 (1): e0146794. doi:10.1371/journal.pone.0146794
- [34] Revello R, Sarno L, Ispas A et al. Screening for trisomies by cell-free DNA testing of maternal blood: consequences of a failed result. *Ultrasound Obstet Gynecol* 2016; 47 (6): 698–704. doi:10.1002/uog.15851
- [35] Hopkins MK, Koelper N, Caldwell S et al. Obesity and no call results: optimal timing of cell-free DNA testing and redraw. *Am J Obstet Gynecol* 2021; 225 (4): 417.e1–417.e10. doi:10.1016/j.ajog.2021.04.212
- [36] Pergament E, Cuckle H, Zimmermann B et al. Single-nucleotide polymorphism-based noninvasive prenatal screening in a high-risk and low-risk cohort. *Obstet Gynecol* 2014; 124: 210–218. doi:10.1097/AOG.0000000000000363
- [37] Robiński J. The new law on gene diagnostics in Germany – an overview about the main principles. *Rev Derecho Genoma Hum* 2010; 32: 47–68
- [38] Oepkes D, Bartha JL, Schmid M et al. Benefits of contingent screening vs primary screening by cell-free DNA testing: think again. *Ultrasound Obstet Gynecol* 2016; 47 (5): 542–545. doi:10.1002/uog.15758
- [39] van der Meij KRM, Siermans EA et al. TRIDENT-2: National Implementation of Genome-wide Non-invasive Prenatal Testing as a First-Tier Screening Test in the Netherlands. *Am J Hum Genet* 2019; 105 (6): 1091–1101. doi:10.1016/j.ajhg.2019.10.005
- [40] Kagan KO, Sonek J, Kozłowski P. Antenatal screening for chromosomal abnormalities. *Arch Gynecol Obstet* 2022; 305 (4): 825–835. doi:10.1007/s00404-022-06477-5
- [41] Nicolaidis KH. First-trimester screening for chromosomal abnormalities. *Semin Perinatol* 2005; 29 (4): 190–194. doi:10.1053/j.semperi.2005.06.001
- [42] Gil MM, Revello R, Poon LC et al. Clinical implementation of routine screening for fetal trisomies in the UK NHS: cell-free DNA test contingent on results from first-trimester combined test. *Ultrasound Obstet Gynecol* 2016; 47 (1): 45–52. doi:10.1002/uog.15783
- [43] Galeva S, Konstantinidou L, Gil MM et al. Routine first-trimester screening for fetal trisomies in twin pregnancy: cell-free DNA test contingent on results from combined test. *Ultrasound Obstet Gynecol* 2019; 53 (2): 208–213. doi:10.1002/uog.20160
- [44] Eiben B, Glaubitz R, Winkler T et al. First-trimester screening in Germany after the introduction of NIPT as a general health insurance benefit. *Ultraschall Med* 2023. doi:10.1055/a-2028-8108
- [45] Poon LC, Shennan A, Hyett JA et al. The International Federation of Gynecology and Obstetrics (FIGO) initiative on pre-eclampsia: A pragmatic guide for first-trimester screening and prevention. *Int J Gynaecol Obstet* 2019; 145 (Suppl. 1): 1–33. doi:10.1002/ijgo.12802
- [46] Rolnik DL, Selvaratnam RJ, Wertaschnigg D et al. Routine first trimester combined screening for preterm preeclampsia in Australia: A multicenter clinical implementation cohort study. *Int J Gynaecol Obstet* 2022; 158 (3): 634–642. doi:10.1002/ijgo.14049
- [47] Salomon LJ, Alfrevic Z, Audibert F et al. ISUOG consensus statement on the impact of non-invasive prenatal testing (NIPT) on prenatal ultrasound practice. *Z Geburtshilfe Neonatol* 2014; 218 (6): 242–243. doi:10.1055/s-0034-1395670
- [48] Kagan KO, Hoopmann M, Hammer R et al. Screening for chromosomal abnormalities by first trimester combined screening and noninvasive prenatal testing. *Ultraschall Med* 2015; 36 (1): 40–46. doi:10.1055/s-0034-1385059
- [49] Schmid M, Klaritsch P, Arzt W et al. Cell-Free DNA Testing for Fetal Chromosomal Anomalies in clinical practice: Austrian-German-Swiss Recommendations for non-invasive prenatal tests (NIPT). *Ultraschall Med* 2015; 36 (5): 507–510. doi:10.1055/s-0035-1553804
- [50] Merz E. Can Prenatal Testing in the First Trimester be Performed without Ultrasound? *Ultraschall Med* 2017; 38 (2): 126–128. doi:10.1055/s-0043-102832
- [51] Kozłowski P, Burkhardt T, Gembruch U et al. DEGUM, ÖGUM, SGUM and FMF Germany recommendations for the implementation of first-trimester screening, detailed ultrasound, cell-free DNA screening and diagnostic procedures. *Ultraschall Med* 2019; 40 (2): 176–193. doi:10.1055/a-0631-8898
- [52] Kagan KO, Tercanli S, Hoopmann M. Ten reasons why we should not abandon a detailed first trimester anomaly scan. *Ultraschall Med* 2021; 42 (5): 451–459. doi:10.1055/a-1528-1118
- [53] Wapner RJ, Martin CL, Levy B et al. Chromosomal microarray versus karyotyping for prenatal diagnosis. *N Engl J Med* 2012; 367 (23): 2175–2184. doi:10.1056/NEJMoa1203382
- [54] Lord J, McMullan DJ, Eberhardt RY et al. Prenatal exome sequencing analysis in fetal structural anomalies detected by ultrasonography (PAGE): a cohort study. *Lancet* 2019; 393: 747–757. doi:10.1016/S0140-6736(18)31940-8
- [55] Diderich KEM, Romijn K, Joosten M et al. The potential diagnostic yield of whole exome sequencing in pregnancies complicated by fetal ultrasound anomalies. *Acta Obstet Gynecol Scand* 2021; 100 (6): 1106–1115. doi:10.1111/aogs.14053