

# Modern Lung Scintigraphy Techniques for Optimizing the Diagnosis of Pulmonary Embolism: Great Expectations Still Awaiting to Be Met

Stavros Konstantinides<sup>1,2</sup> 

<sup>1</sup> Center for Thrombosis and Hemostasis, University Medical Center of the Johannes Gutenberg University, Mainz, Germany

<sup>2</sup> Department of Cardiology, Democritus University of Thrace, Alexandroupolis, Greece

Address for correspondence Stavros V. Konstantinides, MD, FESC, Centre for Thrombosis and Haemostasis, University Medical Centre Mainz, Langenbeckstrasse 1, Building 403, 55131 Mainz, Germany (e-mail: stavros.konstantinides@unimedizin-mainz.de).

Thromb Haemost 2023;123:663–665.

In the present issue of the journal,<sup>1</sup> Drs. Squizzato and colleagues report on the diagnostic accuracy of ventilation/perfusion (V/Q) and perfusion-only (Q) single-photon emission computed tomography (SPECT) combined with low-dose CT (SPECT/CT) in patients with clinically suspected acute pulmonary embolism (PE). By systematically reviewing the literature and meta-analyzing eight studies with a total of 1,086 included patients having a 27% mean prevalence of PE, the authors found a bivariate weighted mean diagnostic sensitivity of 96% (95% confidence interval [CI]: 93–98%) and a weighted mean specificity of 95% (95% CI: 90–97%) for SPECT/CT.

Squizzato et al are to be congratulated on a solid piece of work: the methodology for study selection and data extraction is clearly described, and the statistical analysis transparently explained. The bivariate random-effects regression model, chosen to account for any correlation between sensitivity and specificity among the studies, seems appropriate. A formal bias assessment was performed and a high risk of bias in the included studies was acknowledged. The authors cautiously (and appropriately) avoid any overinterpretation of their results and conclude that new nuclear imaging techniques might, as a minimum, replace the “traditional” planar V/Q scan.<sup>1</sup>

What might be the broader implications of these results for the future of acute PE diagnosis? Many physicians as well as members of guidelines task forces around the world consider that the question on the optimal diagnostic test—and diagnostic algorithm—for patients with suspected PE has been “definitively” answered. Following a series of well-designed management and quasi management studies more than 15 years ago,<sup>2,3</sup> the 2008 update of the European Society of Cardiology (ESC) guidelines on PE recommended to replace

V/Q scintigraphy, along with invasive pulmonary angiography, by computed tomography pulmonary angiography (CTPA) as the new central imaging test and diagnostic “gold standard.”<sup>4</sup> It was nevertheless postulated that the evolving SPECT technique might help “resuscitate” the V/Q scan by overcoming the problem of frequent nondiagnostic intermediate probability planar scans.<sup>5,6</sup> However, at the next update of the guidelines 6 years later,<sup>7</sup> no compelling new evidence could be presented to question the central position of CTPA, and the need for further validation of V/Q SPECT was reiterated.<sup>8</sup> Recommendations on PE diagnosis remained unchanged even in the most recent update of 2019, with the guidelines continuing to point out the variability of V/Q SPECT techniques and diagnostic criteria as well as the lack of validation of this method in prospective management studies.<sup>9</sup> Since that time, only one small prospective study comparing V/Q SPECT/CT with CTPA in 28 patients with suspected PE (but no independent diagnostic reference standard) was published<sup>10</sup> and could be included in the present meta-analysis.<sup>1</sup> Admittedly, this is not typical of a rapidly changing landscape.

Squizzato et al elegantly summarize in their article the potential advantages, but also the limitations and drawbacks of V/Q SPECT compared with the gold standard, CTPA, in the contemporary diagnostic workup of acute PE.<sup>1</sup> Of them, the reduced radiation exposure with V/Q SPECT cannot be overemphasized,<sup>9</sup> and the more precise localization of scintigraphic findings when combined with low-dose CT images helps overcome a repeatedly cited weakness of planar V/Q lung scans. The sensitivity of V/Q SPECT/CT also appears to be excellent,<sup>11</sup> even though this latter strength of the method may turn out to be a double-edged sword, reminding us of

received

March 14, 2023

accepted

March 14, 2023

accepted manuscript online

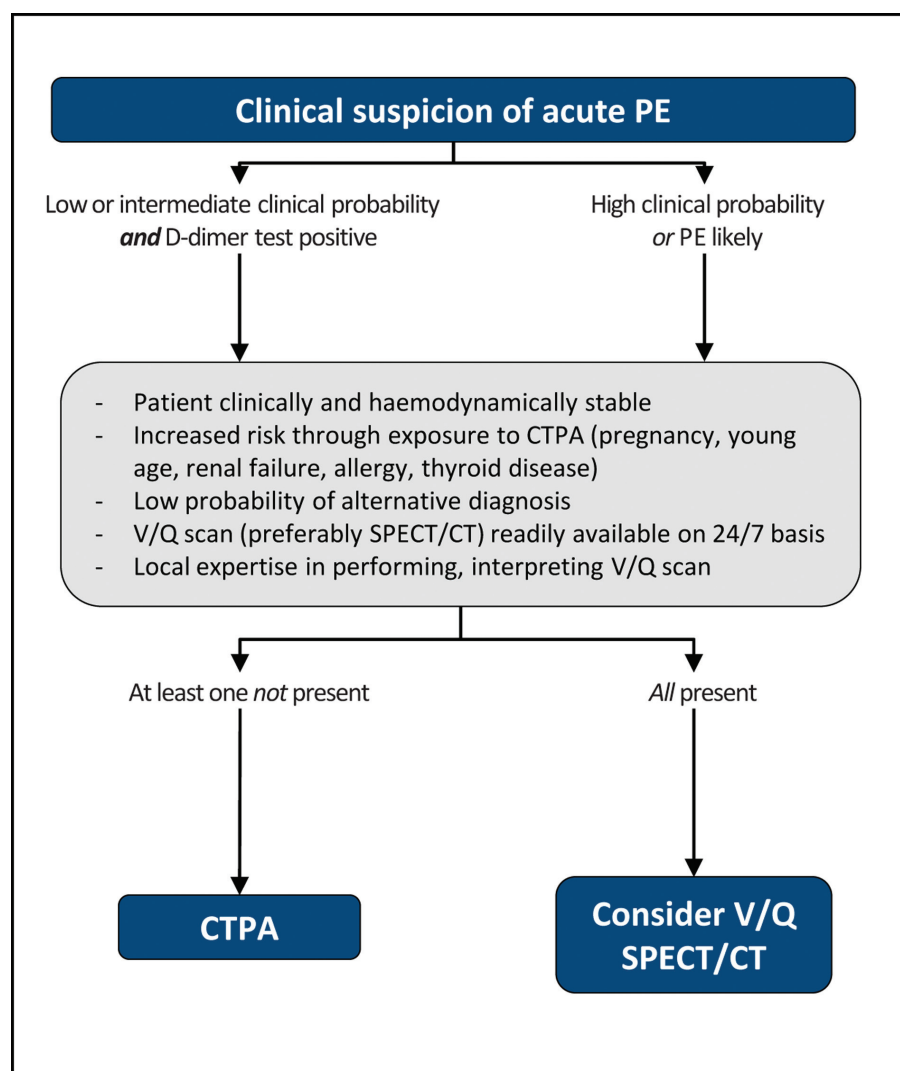
March 19, 2023

article published online

April 18, 2023

© 2023. Thieme. All rights reserved.  
Georg Thieme Verlag KG,  
Rüdigerstraße 14,  
70469 Stuttgart, Germany

DOI <https://doi.org/10.1055/a-2057-8672>.  
ISSN 0340-6245.



**Fig. 1** Proposed diagnostic work-up for clinically suspected acute pulmonary embolism. CTPA, computed tomography pulmonary angiography; PE, pulmonary embolism; SPECT/CT, single-photon emission computed tomography combined with low-dose computed tomography; V/Q scan, ventilation/perfusion scintigraphy.

the problem of PE overdiagnosis which we are already facing in the CTPA era.<sup>12,13</sup>

On the other hand, and apart from the limited body of evidence mentioned earlier, practical problems associated with the lack of “24/7” availability in most hospitals, and limitations or concerns specifically affecting ventilation scintigraphy, also including its nonfeasibility in critically ill patients with high-risk or intermediate high-risk PE, cannot be left out of the equation. Last but not least, a decisive strength of CTPA lies in its ability to provide an alternative diagnosis for the patient’s symptoms if acute PE is ruled out, and this remains a major driver of the use (and overuse) in the method around the world.

So, what are the chances that V/Q SPECT/CT might challenge the diagnostic gold standard CTPA and reshape PE diagnostic algorithms in the foreseeable future? Quite poor, I am afraid. Notwithstanding the limitations and risks associated with radiation and contrast medium exposure, and the repeated warnings concerning its overuse (and occasional misuse) in hospitals and the implications thereof, CTPA will remain invulnerable and uncontested in the years to come in

view if its omnipresence and overwhelming popularity. Guidelines will continue to find no scientific arguments that can be so convincing as to change the status quo. PE is an acute, potentially life-threatening situation, and nothing can be more dangerous for the patient than delaying its confirmation or exclusion by hours or even days until the imaging test can be performed, or by using a test that has not been formally and broadly validated. In the meantime, V/Q scintigraphy, preferably with the new SPECT/CT technology, may continue to be the preferred diagnostic method in institutions that can ensure its uninterrupted availability and expertise in its interpretation, also provided that the patient’s clinical condition is stable enough to permit it. Always ensuring that these latter conditions are met at a given institution, V/Q SPECT/CT may even gain higher priority in specific populations, including pregnant women with clinically suspected PE and a low probability of an alternative acute cardiovascular syndrome or pulmonary disease<sup>14,15</sup> (►Fig. 1). Such a strategy would be in line with the algorithm proposed by the current European guidelines, in which

(perfusion) scintigraphy assumed a more visible position as an alternative to CTPA in pregnancy.<sup>9</sup>

Taking care of patients with PE continues to evolve, and the focus of interest is no longer confined to diagnosing and treating the acute event alone. In fact, current guidelines underline the need for patient follow-up and early detection of late sequelae, namely chronic thromboembolic pulmonary disease with or without pulmonary hypertension.<sup>9,16</sup> Improving prognostication has always been high on the agenda, and the identification of clinical risk factors associated with prognosis,<sup>17–19</sup> as well as novel approaches such as machine learning to predict outcomes,<sup>20</sup> has been promoted.

Recently, evidence has begun to emerge that signs of preexisting chronic PE and chronic thromboembolic pulmonary hypertension may be detectable upon diagnosis of the (presumably) “first” episode of acute PE.<sup>21–23</sup> If an interdisciplinary consensus on the most relevant of these imaging parameters can be obtained so that they can be routinely assessed and provided to the treating physicians in clinical practice, this additional information may have a substantial impact on shaping post-PE follow-up programs in the future.<sup>9</sup> Again, it is CTPA that claims this growing potential for itself thanks to the anatomical details that it provides; nevertheless, I believe that V/Q (or even Q alone) SPECT/CT should not miss the chance of undergoing prospective testing as a possibly valuable “low radiation” imaging tool in the follow-up of carefully selected survivors of acute PE, notably those with signs of chronicity at baseline and/or an otherwise elevated risk of chronic thromboembolic disease.

**Conflict of Interest**  
None declared.

## References

- Squizzato A, Venturini A, Pelitti V, et al. Diagnostic accuracy of V/Q and Q SPECT/CT in patients with suspected acute pulmonary embolism: a systematic review and meta-analysis. *Thromb Haemost* 2023;123(07):700–713
- Perrier A, Roy PM, Sanchez O, et al. Multidetector-row computed tomography in suspected pulmonary embolism. *N Engl J Med* 2005;352(17):1760–1768
- van Belle A, Büller HR, Huisman MV, et al; Christopher Study Investigators. Effectiveness of managing suspected pulmonary embolism using an algorithm combining clinical probability, D-dimer testing, and computed tomography. *JAMA* 2006;295(02):172–179
- Torbicki A, Perrier A, Konstantinides S, et al; ESC Committee for Practice Guidelines (CPG). Guidelines on the diagnosis and management of acute pulmonary embolism: the task force for the diagnosis and management of acute pulmonary embolism of the European Society of Cardiology (ESC). *Eur Heart J* 2008;29(18):2276–2315
- Reinartz P, Kaiser HJ, Wildberger JE, Gordji C, Nowak B, Buell U. SPECT imaging in the diagnosis of pulmonary embolism: automated detection of match and mismatch defects by means of image-processing techniques. *J Nucl Med* 2006;47(06):968–973
- Reinartz P, Wildberger JE, Schaefer W, Nowak B, Mahnken AH, Buell U. Tomographic imaging in the diagnosis of pulmonary embolism: a comparison between V/Q lung scintigraphy in SPECT technique and multislice spiral CT. *J Nucl Med* 2004;45(09):1501–1508
- Konstantinides SV, Torbicki A, Agnelli G, et al; Task Force for the Diagnosis and Management of Acute Pulmonary Embolism of the European Society of Cardiology (ESC) 2014 ESC guidelines on the diagnosis and management of acute pulmonary embolism. *Eur Heart J* 2014;35(43):3033–3069, 3069a–3069k
- Schulman S, Agno W, Konstantinides SV. Venous thromboembolism: past, present and future. *Thromb Haemost* 2017;117(07):1219–1229
- Konstantinides SV, Meyer G, Becattini C, et al; ESC Scientific Document Group. 2019 ESC Guidelines for the diagnosis and management of acute pulmonary embolism developed in collaboration with the European Respiratory Society (ERS). *Eur Heart J* 2020;41(04):543–603
- Martins GH, Contardi EB, Lopes DM, et al. Head-to-head comparison of ventilation/perfusion single photon emission computed tomography/computed tomography and multidetector computed tomography angiography for the detection of acute pulmonary embolism in clinical practice. *Perfusion* 2023;38(03):637–644
- Le Roux PY, Robin P, Tromeur C, et al. Ventilation/perfusion SPECT for the diagnosis of pulmonary embolism: a systematic review. *J Thromb Haemost* 2020;18(11):2910–2920
- Konstantinides SV. Trends in incidence versus case fatality rates of pulmonary embolism: Good news or bad news? *Thromb Haemost* 2016;115(02):233–235
- Dentali F, Agno W, Pomero F, Fenoglio L, Squizzato A, Bonzini M. Time trends and case fatality rate of in-hospital treated pulmonary embolism during 11 years of observation in Northwestern Italy. *Thromb Haemost* 2016;115(02):399–405
- Hansen SL, de Nijs R, Mortensen J, Berg RMG. Ventilation-perfusion SPECT versus CTPA in young adult females with suspected pulmonary embolism. *Eur Respir J* 2020;55(06):2000448
- Konstantinides SV. The optimal imaging test for diagnosis of acute pulmonary embolism: a second chance for lung scintigraphy? *Eur Respir J* 2020;55(06):2001426
- Humbert M, Kovacs G, Hoepfer MM, et al; ESC/ERS Scientific Document Group. 2022 ESC/ERS Guidelines for the diagnosis and treatment of pulmonary hypertension. *Eur Heart J* 2022;43(38):3618–3731
- Orione C, Tromeur C, Le Mao R, et al. The impact of pulmonary vascular obstruction on the risk of recurrence of pulmonary embolism: a French prospective cohort. *Thromb Haemost* 2021;121(07):955–963
- Le Mao R, Jiménez D, Bikdeli B, et al; RIETE Investigators. Prognostic impact of obstructive sleep apnea in patients presenting with acute symptomatic pulmonary embolism. *Thromb Haemost* 2021;121(06):808–815
- Wang D, Fan G, Liu X, Wu S, Zhai Z. Renal insufficiency and short-term outcomes of acute pulmonary embolism: a systemic review and meta-analysis. *Thromb Haemost* 2020;120(07):1025–1034
- Mora D, Nieto JA, Mateo J, et al; RIETE Investigators. Machine learning to predict outcomes in patients with acute pulmonary embolism who prematurely discontinued anticoagulant therapy. *Thromb Haemost* 2022;122(04):570–577
- Barco S, Mavromanolis AC, Kreitner KF, et al. Preexisting chronic thromboembolic pulmonary hypertension in acute pulmonary embolism. *Chest* 2023;S0012-3692(23)00013-2
- Boon GJAM, Ende-Verhaar YM, Beenen LFM, et al. Prediction of chronic thromboembolic pulmonary hypertension with standardised evaluation of initial computed tomography pulmonary angiography performed for suspected acute pulmonary embolism. *Eur Radiol* 2022;32(04):2178–2187
- Ruggiero A, Screaton NJ. Imaging of acute and chronic thromboembolic disease: state of the art. *Clin Radiol* 2017;72(05):375–388