

Multicenter prospective evaluation of an overtube endoluminal interventional platform for colorectal polypectomy




Authors

Mohamed O. Othman¹ , David L. Diehl² , Harshit S. Khara² , Salman Jawaid¹, Dennis Yang³, Peter V. Draganov³

Institutions

- 1 Division of Gastroenterology Baylor St. Luke's Medical Center Houston, Texas, United States
- 2 Division of Gastroenterology Geisinger Health System Danville, Pennsylvania, United States
- 3 Division of Gastroenterology University Florida Gainesville, Florida, United States

submitted 1.8.2022

accepted after revision 10.2.2023

published online 17.3.2023

Bibliography

Endosc Int Open 2023; 11: E519–E526

DOI 10.1055/a-2057-4286

ISSN 2364-3722

© 2023. The Author(s).

This is an open access article published by Thieme under the terms of the Creative Commons Attribution-NonDerivative-NonCommercial License, permitting copying and reproduction so long as the original work is given appropriate credit. Contents may not be used for commercial purposes, or adapted, remixed, transformed or built upon. (<https://creativecommons.org/licenses/by-nc-nd/4.0/>)

Georg Thieme Verlag KG, Rüdigerstraße 14,
70469 Stuttgart, Germany

Corresponding author

Mohamed O. Othman, MD, Chief, Gastroenterology Section, BSLMC, William T. Butler Endowed Chair for Distinguished Faculty, Professor of Medicine – Gastroenterology and Hepatology Section, Baylor College of Medicine, 7200 Cambridge Street, Suite 8C, Houston, Texas 77030, United States

Fax: +1-713-798-0951

mohamed.othman@bcm.edu

ABSTRACT

Background and study aims Endoscopic removal of complex colorectal polyps (≥ 2 cm) can be technically challenging. A dual balloon endoluminal overtube platform (DBEP) was developed to facilitate colonoscopic polypectomy. The study purpose was to evaluate clinical outcomes with the DBEP for complex polypectomy.

Patients and methods This was an observational, prospective, multicenter Institutional Review Board-approved study. Between January 2018 and December 2020, safety and performance data were collected intra-procedurally and at 1 month post-procedure in patients undergoing intervention with the DBEP at three US centers. The primary endpoint was device safety and technical success of the procedure. Secondary endpoints included navigation time, total procedure time, and user feedback assessment post-procedure.

Results A total of 162 patients underwent colonoscopy with the DBEP. Of these, 144 (89%) underwent 156 interventions successfully with DBEP (44.5% endoscopic mucosal resection, 53.2% hybrid endoscopic submucosal dissection (ESD)/ESD, 1.3% other). In 13 patients (8%), device challenges contributed to unsuccessful intervention. One mild device-related adverse event (AE) occurred. Procedural AE rate was 8.3%. Median lesion size was 2.6 cm [range 0.5–12]. The investigators felt that navigating the device was easy/somewhat easy in 78.5% of successful cases. Median total procedure time was 69 minutes [range, 19–213], median navigation time to lesion was 8 minutes [range, 1–80], And median polypectomy time was 33.5 minutes [range, 2–143].

Conclusions Endoscopic colon polyp resection with the DBEP was safe with a high technical success rate. The DBEP has the potential to provide enhanced scope stability and visualization, traction, and a conduit for scope exchange. Further prospective randomized studies are warranted.

Introduction

The incidence of colon polyps and colorectal cancer (CRC) are increasing in the United States, with a particular increase in CRC in young adults [1, 2]. Colonoscopy and resection of colo-

nic polyps has been proven to decrease mortality from CRC [3]. Unfortunately, the use of surgery for benign colon polyps has risen between 2000 and 2014 [4], despite the fact that an endoscopic approach to therapy results in significant cost sav-

ings, lower morbidity and mortality, quicker recovery, and better quality of life versus a surgical approach [5–8].

Most benign colon adenomas can be removed by standard polypectomy techniques; however, removal of complex colonic polyps (>2 cm, difficult locations, recurrent polyps) can be challenging [9]. Management of such polyps may require advanced endoscopic resection techniques such as endoscopic mucosal resection (EMR) and endoscopic submucosal dissection (ESD). EMR and ESD are technically demanding procedures and some of the most common challenges are lack of scope stability and poor lesion access and exposure.

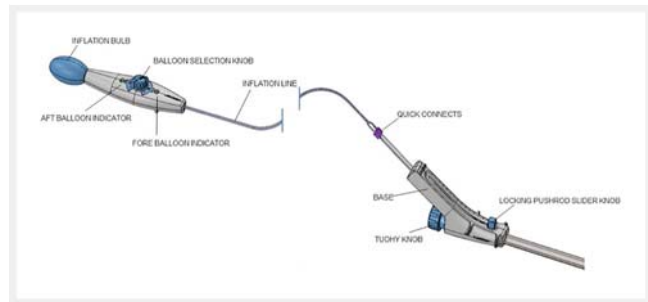
To address this problem, a dual balloon endoluminal platform (DBEP), DiLumen (Lumendi, Westport, Connecticut, United States), with an overtube-like sheath was introduced to facilitate endoscopic resection of complex colon polyps by assisting with scope visualization, stabilization, navigation, and tissue manipulation, while providing a conduit for scope exchange. The purpose of the study was to prospectively evaluate safety and performance outcomes using the DBEP for endoscopic resection of complex colon polyps.

Patients and methods

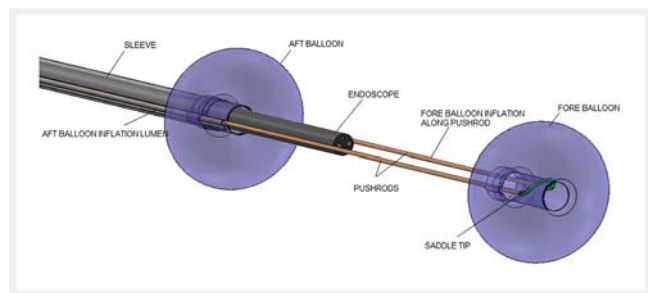
Study design and patient population

This was a prospective, multicenter cohort registry study. IRB approval was obtained at each site prior to the enrollment of subjects (NCT03942965). The study was conducted at three major academic centers between January 2018 and December 2020. Recruitment to the study was temporary halted for 3 months during COVID pandemic. All devices were purchased by the respective academic institutions and the procedures were done as part of routine patient care. IRB costs, institutional research fees, database collection/management, and statistical support were funded by the device manufacturer. Device manufacturer had access to the registry data but were not included in formulating of the results or drafting this manuscript. Since this was a feasibility study, no sample size calculation was performed but we estimated that sample size of 150 to 200 patients will be sufficient to detect any safety concern of the device.

Our inclusion criteria were all adult patients who were referred for EMR or ESD procedures during the study time frame. Specific criteria for colonic polyps included in this study was polyps equal to or larger than 2 cm with no prior endoscopic interventions for polyps resection or polyps smaller than 2 cm with a history of prior failed endoscopic resection. Exclusion criteria included history of open or laparoscopic colorectal surgery, history of inflammatory bowel disease, or a contraindication to colonoscopy with the device due to colon anatomy (e. g. known stricture). Diverticulosis was not an exclusion criterion in this study. Enrollment was planned for up to total of 200 subjects at all sites. Enrollment was halted in December 2020 after recruiting 176 patients due to the difficulty in conducting clinical trials or elective procedures during COVID pandemic. Patients were followed up at 1 month by phone call or office visit.



► Fig. 1 Device components.



► Fig. 2 Relationship between aft balloon and fore balloon of the device.

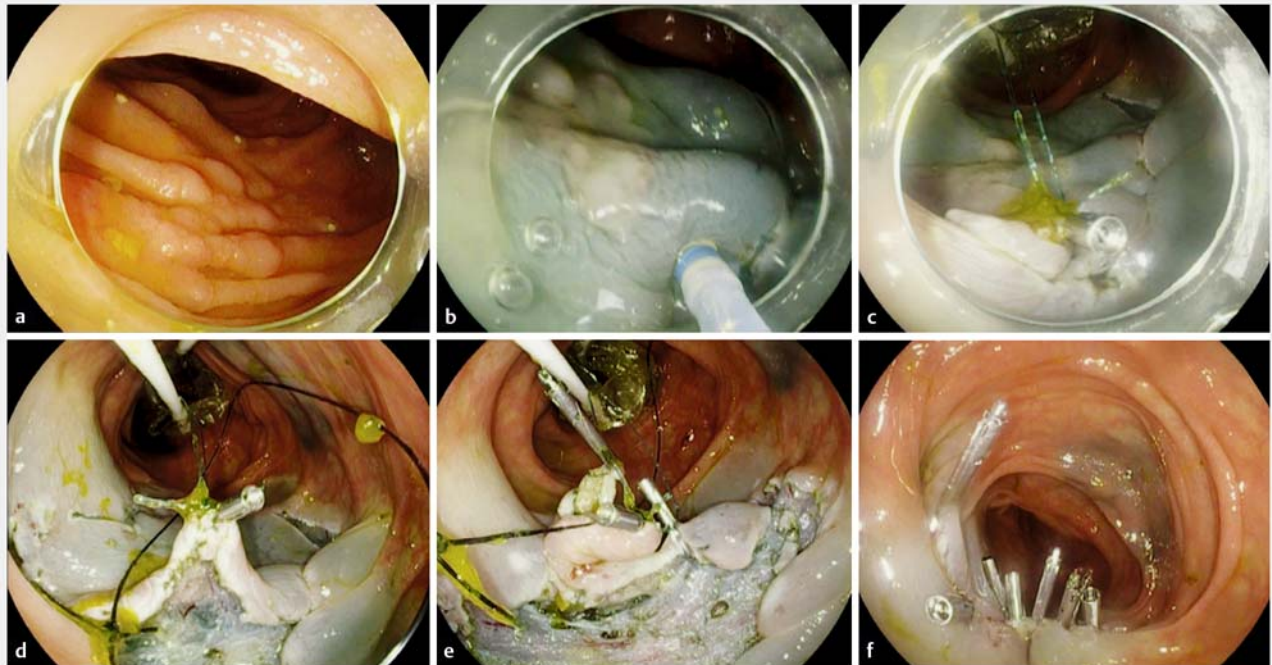
Study device

The DBEP is a non-sterile, single-use, close-fitting sleeve (overtube) that fits over a colonoscope. The overtube stabilizes endoscope position in the large intestine and facilitates optical visualization for the treatment of polyps. It can be used with any standard endoscope with a distal tip outer diameter of 12.5 to 14.3 mm and the overtube comes in 103-cm and 130-cm lengths. This device received initial 510(k) clearance on December 6, 2016.

The device consists of six major components that form its primary mechanical structure: 1) fore balloon; 2) aft balloon; 3) sleeve; 4) base; 5) push rods; and 6) inflation system (► Fig. 1 and ► Fig. 2).

Procedure

All procedures were performed using colonoscopes with water jet function, Pentax EC38-i10L (Pentax America, Montvale, New Jersey, United States) or Olympus CF-HQ190L or PCF-HQ190L (Olympus America, Center Valley, Pennsylvania, United States) depending on the institution. The technique of performing EMR or ESD has been described elsewhere [4]. All procedures were performed by five advanced endoscopists in three tertiary referral centers. in the United States. The technique of using the endoscopic accessory is described as follows: The platform utilizes two balloons (“fore” and “aft”) to position and stabilize the endoscope within a patient’s large intestine. After the device is installed over the colonoscope, both are navigated together to the target zone with the balloons deflated. If needed, the aft balloon can be inflated/deflated sequentially to assist with navigation in a tortuous colon, in a technique very similar to bal-



► **Fig. 3** Step-by-step endoscopic submucosal dissection of granular lateral spreading colonic polyp with the aid of DBEP. **a** Three-centimeter granular lateral spreading polyp in the transverse colon. **b** Submucosal injection followed by circumferential incision. **c** The traction loops of the fore balloon are attached to the anal side of the lesion using a clip. **d** The fore balloon is extended slightly to create sufficient tension for rapid dissection. **e** Dynamic retraction of the fore balloon with almost complete dissection of the lesion. **f** Post-resection closure with clips.

loon-assisted small bowel enteroscopy [5]. Once the colonoscope is at the target site, the aft balloon is inflated until it contacts the intestinal wall near the proximal end of the bending section of the colonoscope. The fore balloon can be deployed at a variable distance in front of the colonoscope tip via two push rods. Once extended and inflated, the fore balloon contacts the patient's intestinal wall, and in combination with the aft balloon, creates an isolated therapeutic zone within the large intestine. Both balloons are inflated or deflated with air independently using an inflation device with a squeeze bulb. The balloons stabilize the endoscope distal tip, assisting with accessing and visualization of lesions behind folds and turns in the intestine. Required insufflation within the therapeutic zone is minimized compared to typical colorectal endoscopic procedures, because the balloons enclose only a small portion (approximately 20 cm) of the large intestine. The platform sheath can act as an overtube to remove and reinsert the endoscope efficiently, especially when working on the right side of colon. Two traction loops are attached to the fore balloon to facilitate traction in ESD procedures if needed. ► **Video 1** highlights traction-assisted ESD using DBEP. The decision of performing EMR, ESD or hybrid ESD technique (the combined use of ESD knife for initial incision followed by snare resection) was based on endoscopist's discretion. In case of DBEP failure, the device was removed and the procedure was performed in standard fashion. ► **Fig. 3** illustrates step-by-step ESD of granular lateral spreading colonic polyp with the aid of DBEP.

► VIDEO



► **Video 1** Traction-assisted ESD for sessile serrated adenoma using DBEP.

Data collection

After confirming eligibility, subjects signed a study consent prior to participation. Outcome data were collected utilizing a standardized collection form for later data analysis. Data collected included patient demographics, whether the intervention was successfully performed with the DBEP, time to reach the lesion, dissection/polypectomy time, defect closure time (if performed), and total procedure time. Histologic data were also collected. Data concerning adverse events (AEs) were collected

throughout the procedure and up to the one-month follow-up timepoint.

Study outcomes

The purpose of this study was to evaluate device safety and device outcomes when used for endoscopic therapy of colorectal polyps. The primary endpoint was whether the study device was successfully used for performing the entire procedure. Secondary endpoints included time needed to reach the lesion, time for lesion removal, time for defect closure, and overall case time. At procedure end, endoscopist was asked to answer two questions regarding the case: Was the device easy to navigate to the lesion (Easy/Somewhat Easy/Somewhat Difficult/Difficult) and whether the balloons were used to assist in navigation (Yes/No).

The primary safety endpoints of the study were to assess intraprocedure blood loss or mucosal trauma beyond what would be expected during a typical procedure during intervention, as well as perforation rate, and whether these were device- or procedure-related. Investigators assessed whether the AE was mild, moderate, or severe. Assessment of the severity of AEs was based on the American Society for Gastrointestinal Endoscopy lexicon. Follow-up to 1 month evaluated any delayed perforations or bleeding episodes. Safety data were summarized by relationship to device/procedure and whether the AE was anticipated, or serious. A serious AE was defined as life-threatening, resulting in permanent impairment, or requiring post-procedure intervention to avoid permanent damage to a body function. An unanticipated event was defined as any serious adverse effect on health or safety, or any life-threatening problem or death caused by, or associated with a device, if that effect, problem, or death was not previously identified in nature, severity, or degree of incidence in the investigational plan or application and one related to the device causing perforation or excessive bleeding requiring intervention.

Statistical analysis

Demographics (including age, gender, ethnicity) and baseline procedure characteristics were summarized with descriptive statistics. Summaries included mean and standard deviation for continuous variables and frequencies or percentages for categorical ones. A *P* value and confidence interval of independent means was reported to compare continuous data.

Results

Patient characteristics

A total of 176 patients were enrolled in this study. Fourteen patients were excluded post-consent or pre-procedure based on inclusion/exclusion criteria, with 162 undergoing interventions with the DBEP device. Of these, 144 of 162 (89%) had successful completion of the procedure with the DBEP device. Mean age in included cases was 66.3 years, females constituted 43.1%, and 75.7% of patients were White. One participant was lost to follow-up; 143 completed the 1-month follow-up period. A total of 156 polyps were endoscopically removed using the DBEP device. ► **Table 1** lists reasons for unsuccessful com-

► **Table 1** Breakout of patients undergoing interventions with DBEP.

N = 162	N (%)
Successfully completed with DBEP	144 (89%)
Unsuccessfully completed with DBEP	18 (11%)
Possibly device-related	13 (8%)
Colon anatomy (stricture, tortuosity) impairing navigation	6
Could not reach polyp	3
Difficult to advance scope	3
Device twisting	1
Unrelated to device	5 (3%)
No polyp found	3
Converted to surgery for suspected cancer	2
DBEP, dual balloon endoluminal overtube platform.	

pletion with the DBEP device (N=18). A single polyp was removed in 135 patients while nine patients had multiple polyps removed (total of 21 polyps removed in the nine procedures). ► **Table 2** shows demographic and pertinent medical history of the patients who underwent successful procedure(s) with the DBEP.

Of 156 polyps included in the study (► **Table 3**), the majority of included polyps were Paris classification Is (62, 39.7%) or Paris classification IIa (60, 38.5%). The most common endoscopic resection method was EMR in 44.9% (N=71), ESD in 32% (N=50) and Hybrid ESD in 21.2% (N=33) of patients. The most common location of polyps was in the ascending colon (39.7%), with 63.4% (N=99) in the right colon.

Study outcomes

During navigation to the lesion, balloons were used to assist with colon shortening in 63% of cases. The traction loops were utilized in expediting ESD in 11 cases (7.6%). Mean total procedure time was 75.5 min ± 38.5 min minutes. The mean time to reach the lesion was 9.7 minutes ± 8.9 minutes. Mean time to remove the lesion was 43.0 minutes ± 31.4 minutes. Mean time needed for resection defect closure was 9.9 minutes ± 9.3 minutes (► **Table 4** and ► **Table 5**). The endoscopist felt that navigating the device was easy or somewhat easy in 78.5% of cases.

Comparison of EMR versus ESD technique

Subgroup analysis of 127 polyps ≥ 2 cm which were removed by EMR and ESD as single polyp cases was performed (► **Table 5**). The mean size of polyp removed by ESD was 4.0 cm ± 1.5 cm and EMR was 2.3 cm ± 1.1 cm. The en-bloc resection rate for EMR group was 70.4% (50/71 cases). As expected, time to remove colon polyps (intervention time) was significantly higher using ESD technique versus EMR technique (43 min vs 24.7 min, *P*=0.00001).

► **Table 2** Subject demographics who underwent successful polypectomy.

Parameter by subject	N = 144
Age (years)	
▪ Mean (SD)	66.3 (9.9)
Gender, [n (%)]	
▪ Male	82 (56.9)
▪ Female	62 (43.1)
Ethnicity, [n (%)]	
▪ African American/Black/not of Hispanic origin	17 (11.8)
▪ American Indian or Alaska Native	1 (0.7)
▪ Asian	1 (0.7)
▪ Caucasian/White/not of Hispanic origin	109 (75.7)
▪ Hispanic or Latino	14 (9.6)
▪ Other	1 (0.7)
▪ Unknown	1 (0.7)
Previous colon polyp, [n (%)]	88 (61.1)
History of diverticulosis, [n (%)]	104 (72.2)
Hemorrhoids, [n (%)]	104 (72.2)
Other comorbidity, [n (%)]	35 (24.1)
ASA classification, [n (%)]	
▪ 1	0
▪ 2	33 (22.9)
▪ 3	104 (74.3)
▪ 4	2 (1.4)
▪ Not answered	2 (1.4)
Previous biopsy, [n (%)]	106 (73.6)

SD, standard deviation.

Adverse events

There was one device-related AE (1/144, 0.69%) and no unexpected AEs were reported in this study. A submucosal hematoma that formed from the contact of the device with the colonic wall was noted in one patient. One clip was placed over this superficial hematoma to prevent bleeding. This incident was considered resolved by the time the procedure concluded. Eleven AEs occurred that were considered procedure-related or possibly procedure-related (10 ESD-related [7.6%], one EMR-related [0.7%]). There were eight incidents of microperforation or perforation associated with hybrid ESD or ESD. All perforations were treated endoscopically with clipping or suturing. Seven of eight cases were considered mild AEs because perforations were managed during the procedure and were considered resolved after complete closure. One was considered a serious

► **Table 3** Polyp-specific information.

Polyp-specific parameter	N = 156 (polyps removed)
Polyp size	3.2 cm ± 1.7 cm (median 2.6 cm [range, 0.5–12])
Paris classification [n (%)]	
▪ Ila	60 (38.5)
▪ I Ib	1 (0.6)
▪ I Ia + I Ic	11 (7)
▪ I p	8 (5.1)
▪ I s	63 (40.3)
▪ I s + I Ia	1 (0.6)
▪ Not recorded	12 (7.7)
Intervention [n (%)]	
▪ EMR	71 (45.5)
▪ ESD	50 (32.0)
▪ Hybrid ESD	33 (21.2)
▪ FTRD	2 (1.3)
Location [n (%)]	
▪ Cecum	37 (23.7)
▪ Ascending colon	62 (39.7)
▪ Transverse colon	36 (23.1)
▪ Descending colon	11 (7.1)
▪ Rectosigmoid	10 (6.4)
Visually clean margins, [n (%)]	
▪ No	8 (5.2)
▪ Yes	142 (91.0)
▪ Not assessed	6 (3.8)

EMR, endoscopic mucosal resection; ESD, endoscopic submucosal dissection.

AE by the investigators as it led to a prolonged hospitalization. Another patient had post-polypectomy syndrome. This event was considered procedure-related and moderate. It resolved without incident but did possibly prolong the hospital stay. There was one incident of post-procedure bleeding that resolved without intervention and was considered possibly related to the procedure. Finally, there was one patient who had electrocardiogram changes intra-procedurally which required an overnight stay. The AEs that occurred during this study are summarized in ► **Table 6**.

Discussion

In this prospective registry, we found that DBEP was safe and enabled endoscopic resection of complex colon polyps using both an EMR and ESD technique. The device was successfully

► **Table 4** User evaluation of device used during successful procedures.

Parameter	N = 144
Balloons used in navigation [n (%)]	
▪ Yes	91 (63.2)
▪ No	45 (31.2)
▪ Not collected	8 (5.6)
Navigating with DiLumen to lesion [n (%)]	
▪ Easy	95 (66.0)
▪ Somewhat easy	18 (12.5)
▪ Somewhat difficult	16 (11.1)
▪ Difficult	4 (2.8)
▪ Not collected	11 (7.6)

navigated to the target site in 92% of the cases. The mean time for polyp resection using ESD in our trial was 43 minutes with median size of 4 cm for the included polyps indicating that the

device possibly expedited the dissection process. The mean entire ESD procedure time was a mean of 83 minutes. The stability of the device balloons and the overtube sheath allowed for efficient EMR and provided a conduit for piecemeal specimen removal and scope reinsertion which can translate to shorter procedure time.

It is notable that there were no AEs related to the device reported in the study. All AEs were procedure-related and 92% of them (11/12) were related to ESD, not EMR.

In spite of documented cost-effectiveness of EMR and ESD in managing complex colon polyps [6], many of the patients with these complex polyps are still referred for laparoscopic or open surgery due to the challenges of an endoscopic approach. There is a need for a pipeline of better devices which can facilitate endoscopic resection of complex colon polyps as well as an increase of referral to advanced endoscopic interventionists before referral for surgery.

Endoscopic resection of complex colon polyps may require many endoscopic devices. However, technical challenges remain, including suboptimal visualization, scope stabilization, traction (for ESD), navigation to the right side in a tortuous colon, and secure closure of the lesion defect. Previous overtube-

► **Table 5** Efficacy endpoint data collected per polyp/patient.

Endpoints (all polyps)	No. polyps N = 156	Mean ± SD (median)
Polyp size	156	3.2 cm ± 1.7 cm (2.6 cm [range, 0.5–12])
Time to reach lesion	138 ¹	9.7 min ± 8.9 min (median 8 min [range, 1–80])
Time to remove lesion	142 ¹	39.5 min ± 31.1 min (median 33.5 min [range, 2–143])
Time to close defect	125 ²	9.8 min ± 9.2 min (median 7 min [range, 0.8–59])
Polyps ≥ 2 cm (single polyp)		
▪ Polyp Size		Mean ± SD
▪ ESD	77	4.0 cm ± 1.5 cm
▪ EMR	50	2.3 cm ± 1.1 cm
▪ P value		.00001
Time to remove lesion		
▪ ESD	76 ¹	43.0 min ± 31.4 min
▪ EMR	47 ¹	24.7 min ± 25.7 min
▪ P value		.00001
Total case time		
▪ ESD	76 ¹	85.0 min ± 39.8 min
▪ EMR	49 ¹	62.1 min ± 30.1 min
▪ P value		.000178
	No. patients (N = 144)	Mean ± SD (median)
Total case time (all patients)	143 ³	75.5 min ± 38.5 min (median 69 min [range, 19–213])

SD, standard deviation; ESD, endoscopic submucosal dissection; EMR, endoscopic mucosal resection.

¹ Not all data points were recorded

² The defect was not closed or the defect closure time was not captured in 31 polyps.

³ Total case time was not collected in one case.

► **Table 6** Number of device- or procedure-related events by subject for all procedures.

Type of event (N = 144)	No. events/ (%)	Investigator-determined severity (N)		
		Mild	Moderate	Severe
Device-related events	1 (0%)	1	0	0
Procedure-related or possibly procedure-related events	11 (8.3%)	9	2	0
EMR	1 (0.70%)			
EKG changes	1 (0.70%)	1		
ESD/hybrid ESD	11 (7.6%)			
Mucosal trauma	1 (0.70%)	1		
Microperforation/perforation	8 (5.6%)	7		1
Post-polypectomy syndrome	1 (0.70%)		1	
Delayed bleeding	1 (0.70%)	1		
Total events	12 (8.3%)	10	2	0

EMR, endoscopic mucosal resection; EKG, electrocardiogram; ESD, endoscopic submucosal dissection.

related devices have been less ideal due to difficulty in reaching the target lesion or inducing mucosal wall trauma. The DBEP seems to address these challenges, but until now there have been no published data on both its safety and feasibility.

The double balloon platform was designed to address several of these issues. The DBEP enables the creation of a stable therapeutic zone for endoscopic resection, and it can stabilize the colon, allowing the endoscopist to optimize the position of the scope in the lumen by minimizing looping during navigation and assisting visualization during polypectomy. In this study, the balloons were used in most cases to assist with colon shortening and limiting this looping. In addition, two traction loops attached to the fore balloon allowed for creation of dynamic push or pull traction by using an endoscopic clip attaching the traction loop to the tissue flap and then extending or retracting the fore balloon slider to expedite ESD.

Post-procedure bleeding or perforation at the site of the lesion defect can occur, especially with ESD. Closure devices such as specialized through-the-scope or over-the-scope clips in addition to suturing devices have enabled complete closure of the defect, which can decrease post-polypectomy bleeding or perforation [7, 8]. The conduit function of the device allows for a switch from the colonoscope to a double channel gastroscope to reach the right side of the colon quickly for sutured closure of the defects after ESD. It is worth mentioning that the perforation rate in our cohort was 5.6%. Intraprocedure perforation during ESD could be due to several factors including operator experience, excessive cautery use or severe fibrosis from prior tattoo. In the United States, a significant portion of patients referred to ESD had prior endoscopic resection or ink was used for marking under the lesion. This may lead to severe fibrosis with subsequent higher rates of microperforations or perforations. In addition, all perforations in this study were treated endoscopically with clipping or suturing and they resolved by the end of the procedure in seven of eight patients.

For EMR, the device was beneficial in providing the stability and visualization needed to expedite the procedure. Another benefit during piecemeal EMR was the ability to withdraw the colonoscope along with the resected large pieces through the device followed by rapid reinsertion of the colonoscope to the EMR location. This maneuver facilitates piecemeal EMR by maintaining a clean field for resection with minimal time needed for scope reinsertion. In addition, the device facilitates clip closure by providing the stability needed to approximate the resection margins. Intervention on the right side of the colon utilizing an EMR or ESD approach is more challenging due to less scope stability, and the DBEP was able to provide this. In our study, 63.4% (99/156) of the lesions were on the right side of the colon.

One of the drawbacks of this device is the inability to successfully navigate it to the cecum in case of severe diverticulosis or fixed sigmoid colon anatomy. Occasionally, manual pressure is needed to assist the advancement of the endoscope, which may prolong the procedure time. The company introduced a change in design to make the platform easier to navigate in late 2020, after this registry was closed. The inside sheath was made hydrophilic, which shortened device preparation time and also made it easier for the endoscope to slide within the sheath. In the previous version, there was occasional “stickiness” between the scope and the sheath, which sometimes impaired endoscope advancement within the sheath; that may explain some of the unsuccessful cases in this registry.

The strength of our study is its prospective nature, the ability to include lesions resected by different techniques, the involvement of different endoscopists at various institutions, and the rigorous follow-up for any AEs. However, our study was performed by experienced endoscopists, and it is possible that our outcomes may not be generalizable to the broader endoscopic community. Another limitation of our study is that it was not designed to calculate R0, curative resection rates, or

recurrence rates because it included both EMR and ESD data and follow-up colonoscopy was not a part of this registry. We utilized Paris classification exclusively for polyp morphology classification in this study, which hindered the utilization of other classifications such as lateral spreading polyp status. Finally, there was no comparative arm in the study, so we were unable to quantify any significant time or cost savings versus conventional complex polypectomy. Having established the safety and feasibility of the device, the company has supported a prospective, comparative study with and without DBEP for colorectal ESD (NCT #03846609).

Conclusions

In conclusion, we found that the double balloon platform is safe and facilitated endoscopic resection of complex colon polyps by providing stability, good visualization and mucosal flap traction, which has the potential to decrease endoscopic resection time. Comparative studies with cost- and time-effectiveness analyses are needed to further determine how to incorporate the device into our routine endoscopic resection armamentarium.

Competing interests

Dr. Othman is a consultant for Olympus, Lumendi, Boston Scientific, AbbVie, ConMed, Covidian, Apollo Medical, Creo Medical and Neptun Medical and receives research support from Conmed, Lucid Diagnostics, Boston Scientific, AbbVie, Nestle and US Biotest. Dr. Diehl is a consultant for Boston Scientific, Olympus Corporation of America, Lumendi, Pentax, and Cook Medical. Dr. Khara is a consultant for Olympus. Dr. Yang is a consultant for Olympus, Microtech, Fujifilm, Apollo Endosurgery, and Medtronic and receives research support from Microtech and 3D Matrix. Dr. Jawaid is a consultant for Conmed, Creo, and Lumendi. Dr. Draganov is a consultant for Boston Scientific, Olympus Corporation of America, Lumendi, FujiFilm Medical, and Microtech.

Funding

Dilumen

Clinical trial

ClinicalTrials.gov (<http://www.clinicaltrials.gov/>)
NCT03942965

TRIAL REGISTRATION: Prospective study NCT03942965 at ClinicalTrials.gov (<http://www.clinicaltrials.gov/>)

References

- [1] Siegel RL, Fedewa SA, Anderson WF et al. Colorectal cancer incidence patterns in the United States, 1974-2013. *J Natl Cancer Inst* 2017; 109: doi:10.1093/jnci/djw322
- [2] Nfonsam VN, Jecius H, Chen D et al. Increasing incidence of colon cancer in the young: assessing the tumor biology. *J Am Coll Surg* 2019; 229: 79–903
- [3] Zauber AG, Winawer SJ, O'Brien MJ et al. Colonoscopic polypectomy and long-term prevention of colorectal-cancer deaths. *N Engl J Med* 2012; 366: 687–6964
- [4] Ismail MS, Bahdi F, Mercado MO et al. ESD with double-balloon endoluminal intervention platform versus standard ESD for management of colon polyps. *Endosc Int Open* 2020; 8: E1273–E1279
- [5] Riff BP, DiMaio CJ. Exploring the small bowel: update on deep enteroscopy. *Curr Gastroenterol Rep* 2016; 18: 28
- [6] Swan MP, Bourke MJ, Alexander S et al. Large refractory colonic polyps: is it time to change our practice? A prospective study of the clinical and economic impact of a tertiary referral colonic mucosal resection and polypectomy service (with videos). *Gastrointest Endosc* 2009; 70: 1128–1136
- [7] Pohl H, Grimm IS, Moyer MT et al. Clip closure prevents bleeding after endoscopic resection of large colon polyps in a randomized trial. *Gastroenterology* 2019; 157: 977–984 e973
- [8] Kantsevov SV, Bitner M, Hajiyeva G et al. Endoscopic management of colonic perforations: clips versus suturing closure (with videos). *Gastrointest Endosc* 2016; 84: 487–493
- [9] Othman MO, Jawaid SA, Rungta M et al. Double-balloon endoluminal intervention platform with flexible grasper to expedite colonic endoscopic submucosal dissection. *VideoGIE* 2021; 6: 144–146