



Complete Resolution of Nonimmune Hydrops Fetalis Secondary to Maternal Syphilis Infection

Andreea Dinicu, MPH¹ Patrick Penalosa, MD² Brian A. Crosland, MD, MPH² Jonathan Steller, MD²

¹University of California, Irvine, School of Medicine, Irvine, Orange, California

²Department of Obstetrics and Gynecology, University of California, Irvine, Orange, California

Address for correspondence Andreea Dinicu, MPH, 3800 West Chapman Ave, Suite 3400, Orange, CA 92868 (e-mail: adinicu@hs.uci.edu).

AJP Rep 2023;13:e21–e24.

Abstract

Maternal syphilis infection is a common infectious cause of nonimmune hydrops fetalis. Generally, hydrops fetalis is equated with poor prognoses in affected pregnancies. A 38-year-old G5P2114 presented at 28^{5/7} weeks' gestation with newly diagnosed primary syphilis infection, sonographic findings of hydrops fetalis, and elevated middle cerebral artery Dopplers concerning for fetal anemia. Following treatment with intramuscular penicillin, the symptoms of hydrops fetalis were resolved and our patient delivered a healthy male neonate with no signs of congenital syphilis at the time of delivery. Routine and early testing for syphilis is an important component of prenatal care. Though not previously documented, the secondary findings of suspected fetal syphilis may be able to completely resolve in utero with penicillin treatment.

Keywords

- ▶ fetal syphilis
- ▶ maternal syphilis
- ▶ hydrops fetalis
- ▶ penicillin
- ▶ early testing

Syphilis remains the most common congenital infection in the world.^{1,2} In pregnancy, syphilis is associated with numerous findings, including placentomegaly, hepatomegaly, polyhydramnios, fetal anemia, and hydrops fetalis. Typically, hepatomegaly and placentomegaly precede signs of hydrops fetalis on ultrasound.² Abnormal ultrasound findings are associated with poor outcomes and higher risk of neonatal treatment failure.² In severe cases, syphilis infection in pregnancy leads to prematurity, low birth weight, and stillbirth.^{2,3}

Nonimmune fetal hydrops (NIFH) is defined as two or more abnormal fetal fluid collections without red blood cell alloimmunization.⁴ These include generalized skin edema (thickness > 5 mm), pleural effusions, pericardial effusion, or ascites. Concomitant sonographic findings include polyhydramnios and placental thickening of at least 4 or 6 cm in diameter at the second and third trimesters, respectively. This condition is an uncommon but serious sequelae of various infectious processes, including advanced stages of

neonatal syphilis.^{5,6} NIFH accounts for up to 90% of all fetal hydrops cases and presents a poor prognosis.⁷ Rarely, NIFH may resolve after delivery, including one instance of syphilis-induced NIFH.^{8–11} The signs of neonatal syphilis, including hepatic and bone dysfunction, improved with penicillin.¹⁰

To our knowledge, there is no prior documentation of in utero resolution of syphilis-related NIFH during pregnancy. Herein, this report presents one such case following treatment with penicillin.

Case

Our patient, a 38-year-old gravida 5 para 3, presented at 28^{5/7} weeks' gestation as a transfer from an outside hospital for newly diagnosed maternal syphilis and concern for fetal hydrops. Her pregnancy was otherwise complicated by chronic hypertension, history of preeclampsia, history of gestational diabetes mellitus, four prior cesarean sections, and an elevated second trimester α -fetoprotein in the setting

received

August 7, 2022

accepted after revision

January 2, 2023

accepted manuscript online

February 6, 2023

DOI <https://doi.org/>

10.1055/a-2028-7727.

ISSN 2157-6998.

© 2023. The Author(s).

This is an open access article published by Thieme under the terms of the Creative Commons Attribution-NonDerivative-NonCommercial-License, permitting copying and reproduction so long as the original work is given appropriate credit. Contents may not be used for commercial purposes, or adapted, remixed, transformed or built upon. (<https://creativecommons.org/licenses/by-nc-nd/4.0/>)

Thieme Medical Publishers, Inc., 333 Seventh Avenue, 18th Floor, New York, NY 10001, USA

of a normal anatomy scan and reassuring noninvasive prenatal testing (declined amniocentesis).

The patient was diagnosed with syphilis following a rapid plasma regain (RPR) titer result of 1:16 at a routine prenatal care visit at 27^{5/7} weeks and confirmed with a treponemal test. First trimester syphilis screening results were ultimately never found. However, the patient reported normal syphilis screens with her prior four pregnancies, the last of which was 10 years prior. She denied symptoms concerning for syphilis infection, including genital chancre or rash on her hands and feet. She returned for initiation of penicillin and follow-up ultrasound at 28^{5/7} weeks (3 weeks after her last ultrasound which had revealed normal growth and anatomy) which then demonstrated fetal ascites, mild ventriculomegaly, and an elevated middle cerebral artery (MCA) Doppler at 1.41 multiple of the median (MoM). She was admitted to an outside hospital for further monitoring and administration of betamethasone and penicillin. A few hours following the first dose of penicillin, her unremarkable fetal monitoring changed to minimal variability and intermittent late decelerations. She was transferred to our center for higher level of care.

On arrival, fetal monitoring redemonstrated intermittent late decelerations every 60 minutes, without active concern for fetal acidemia. Standard maternal resuscitation measures were initiated. When the fetal status was reassuring, an ultrasound was performed revealing a singleton intrauterine pregnancy in cephalic presentation, fetal pleural effusions, ascites, and ventriculomegaly (► **Fig. 1**). MCA Dopplers were 1.49 MoM. Estimated fetal weight was in the 86th percentile by Hadlock, and the placental diameter was 4.84 cm.

Over the next 4 days, continuous fetal monitoring remained reactive without further decelerations and was de-escalated to twice daily 1-hour nonstress tests. A repeat ultrasound on hospital day (HD) 6 showed resolution of the pleural effusion, ascites, and ventriculomegaly. A third ultrasound on HD 8 again redemonstrated the above and normalized MCA Dopplers at 1.23 to 1.34 MoM. A complete NIFH workup, including other infectious etiologies of parvovirus and cytomegalovirus serologies, was negative. Amniocentesis was declined in favor of formal testing for a possible fetal syphilis infection for the following reasons: normal anatomic survey at 25^{3/7} weeks' gestation, no alternate sources for NIFH and resolution of the NIFH following treatment, and high suspicion for a successful treatment of a fetal syphilis infection. The patient received three total doses of intramuscular penicillin and was discharged home in stable condition on HD 9.

Twice weekly outpatient nonstress tests were reassuring. Weekly "hydrops check" ultrasounds were performed and never again demonstrated any signs of fetal hydrops. A follow-up fetal growth scan revealed appropriate growth. Genetic workup of the resolved ventriculomegaly was declined, and no evidence of structural anomalies including aqueductal stenosis, neural tube defects, agenesis of the corpus callosum, or a Dandy-Walker malformation was observed. At 36^{4/7} weeks, she ultimately was diagnosed with preeclampsia with severe features and underwent a

repeat cesarean section. She delivered a healthy male neonate with Apgar scores of 8 and 8 at 1 and 5 minutes, respectively.

There were no signs of congenital syphilis, neonatal anemia, or anatomic abnormalities following a thorough evaluation from our neonatology team. Laboratory testing was notable for hemoglobin 18.2 g/dL and a platelet count of 241,000. The syphilis screen for the neonate was notable for a reactive treponema pallidum antibody with an RPR screen positive and an RPR titer of 1:8. Prior to discharge, the neonate received a single dose of benzathine penicillin.¹² The neonate had continued close outpatient follow-up with no further laboratory testing performed.

Discussion

NIFH can present a severe risk to overall fetal well-being and has multiple infectious etiologies.^{9,10,13} In the setting of confirmed syphilis infection and negative workup for hydrops fetalis, the patient's course was likely secondary to fetal syphilis infection. Infections such as syphilis can cause fetal anemia. When untreated, this leads to fetal heart failure, an increase in central venous pressure, and fluid accumulation in the interstitium, leading to NIFH.¹³ Although hepatomegaly and placentomegaly are the first and most common signs of fetal syphilis infection, our patient's presentation indicated that these findings do not necessarily precede NIFH and fetal anemia in cases of fetal syphilis.² Percutaneous umbilical blood sampling for fetal anemia was considered, but not performed as MCA Dopplers remained less than 1.5 and improved. Given hydropic findings, including pleural effusion and fetal ascites, a robust response to penicillin was not expected.³

Decreased fetal movement, uterine contractions, and transient late decelerations were initially observed after the first dose of penicillin but not the second. These findings may represent a fetal Jarisch–Herxheimer reaction (JHR). In the adult patient, JHR presents after receipt of penicillin with patients experiencing shaking chills, a rise in temperature, and intensified skin rash.¹⁴ JHR also occurs in up to 40% of pregnant patients being treated for syphilis. Transient late fetal heart rate decelerations, decreased fetal movement, and uterine contractions following penicillin administration have been previously reported in a fetus with hydrops.^{15,16} The authors suggest these findings indicate a fetal JHR, which is consistent with this case.^{15,16}

Although the patient developed preeclampsia, no significant relationship has been described between maternal syphilis infection and preeclampsia.¹⁷ Given the patient's history of chronic hypertension and preeclampsia in a prior pregnancy, this instance likely represents a disease process independent of maternal syphilis infection.

Conclusion

This case underscores the importance of routine maternal syphilis screening as per Centers for Disease Control and Prevention recommendation is imperative.¹⁻³ Repeat third

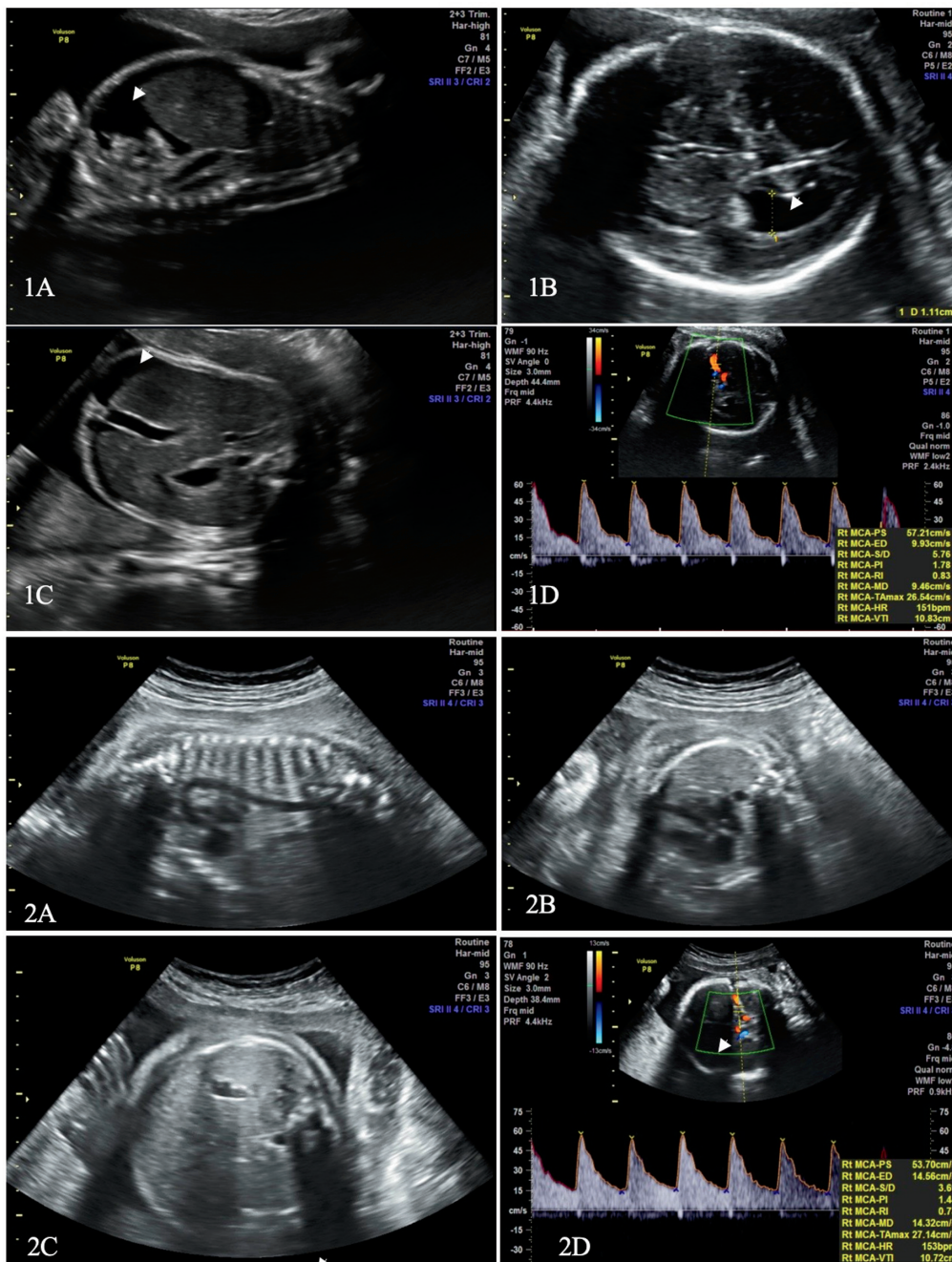


Fig. 1 Initial presentation on hospital day (HD)1 with pleural effusion (A, arrow), ventriculomegaly (B, arrow), enlarging fetal ascites (C), and elevated middle cerebral artery (MCA) Dopplers (D), compared with resolution of pleural effusion (A), ventriculomegaly (B), fetal ascites (C), and normalized MCA (D) Dopplers on HD8.

trimester syphilis screening may have saved the life of this fetus because the first trimester screen had not resulted when the decision to send this follow-up screen was made.¹⁸ Furthermore, this case supports the idea of a fetal JHR in the setting of fetal heart rate tracing abnormalities after penicillin administration. Additionally, this case lends support to the idea that complete in utero recovery from fetal syphilis infection and prevention of congenital syphilis are possible with penicillin treatment.

Informed Consent

Patient consent was obtained prior to writing this report.

Conflict of Interest

None declared.

References

- 1 National Overview of STDs. 2019. Center for Disease Control and Prevention. Updated April 13, 2021. Accessed February 18, 2022, at: <https://www.cdc.gov/std/statistics/2019/overview.htm#CongenitalSyphilis>
- 2 Rac MW, Revell PA, Eppes CS. Syphilis during pregnancy: a preventable threat to maternal-fetal health. *Am J Obstet Gynecol* 2017;216(04):352-363
- 3 Gomez GB, Kamb ML, Newman LM, Mark J, Broutet N, Hawkes SJ. Untreated maternal syphilis and adverse outcomes of pregnancy:

- a systematic review and meta-analysis. *Bull World Health Organ* 2013;91(03):217–226
- 4 Norton ME, Chauhan SP, Dashe JS. Society for Maternal-Fetal Medicine (SMFM) Society for Maternal-Fetal Medicine (SMFM) clinical guideline #7: nonimmune hydrops fetal. *Am J Obstet Gynecol* 2015;212(02):127–139
 - 5 Adhikari EH. Syphilis in pregnancy. *Obstet Gynecol* 2020;135(05):1121–1135
 - 6 Duby J, Bitnun A, Shah V, Shannon P, Shinar S, Whyte H. Non-immune hydrops fetal. *Front Pediatr* 2019;7:508
 - 7 Derderian SC, Jeanty C, Fleck SR, et al. The many faces of hydrops. *J Pediatr Surg* 2015;50(01):50–54, discussion 54
 - 8 Narayanan M, Dhuka S, Alapati S, Kauffman RP. Complete resolution of arrhythmia-induced hydrops fetal. *BMJ Case Rep* 2020;13(10):e235827
 - 9 Garcia-Manau P, Garcia-Ruiz I, Rodo C, et al. Fetal transient skin edema in two pregnant women with coronavirus disease 2019 (COVID-19). *Obstet Gynecol* 2020;136(05):1016–1020
 - 10 Chen I, Chandra S, Singh A, Kumar M, Jain V, Turnell R. Successful outcome with intrauterine transfusion in non-immune hydrops fetal. *J Obstet Gynaecol Can* 2010;32(09):861–865
 - 11 Rac MW, Bryant SN, McIntire DD, et al. Progression of ultrasound findings of fetal syphilis after maternal treatment. *Am J Obstet Gynecol* 2014;211(04):426.e1–426.e6
 - 12 Workowski KA, Bachmann LH, Chan PA, et al. Sexually transmitted infections treatment guidelines, 2021. *MMWR Recomm Rep* 2021;70(04):1–187
 - 13 Bellini C, Hennekam RC. Non-immune hydrops fetal: a short review of etiology and pathophysiology. *Am J Med Genet A* 2012;158A(03):597–605
 - 14 Butler T. The Jarisch-Herxheimer reaction after antibiotic treatment of spirochetal infections: a review of recent cases and our understanding of pathogenesis. *Am J Trop Med Hyg* 2017;96(01):46–52
 - 15 Klein VR, Cox SM, Mitchell MD, Wendel GD Jr. The Jarisch-Herxheimer reaction complicating syphilotherapy in pregnancy. *Obstet Gynecol* 1990;75(3 Pt 1):375–380
 - 16 Myles TD, Elam G, Park-Hwang E, Nguyen T. The Jarisch-Herxheimer reaction and fetal monitoring changes in pregnant women treated for syphilis. *Obstet Gynecol* 1998;92(05):859–864
 - 17 Schlueter A, Doshi U, Garg B, Hersh AR, Caughey AB. Adverse pregnancy outcomes associated with maternal syphilis infection. *J Matern Fetal Neonatal Med* 2022;35(25):5828–5833
 - 18 Third Trimester Screening. Accessed on February 18, 2002, at: http://www.ncsddc.org/wp-content/uploads/2017/07/ncs_366_third_trimester_screening_brochure_page_by_page_mechanical_12-28-16.pdf