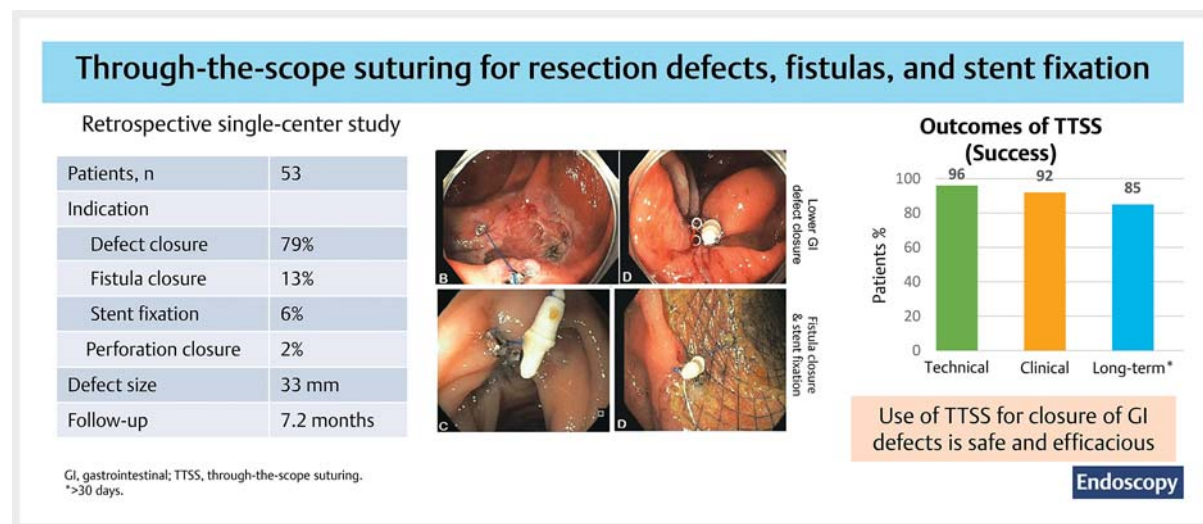


Endoscopic management of gastrointestinal wall defects, fistula closure, and stent fixation using through-the-scope tack and suture system ▶

GRAPHICAL ABSTRACT



Authors

Arunkumar Krishnan¹ , Sardar M. Shah-Khan¹ , Yousaf Hadi¹, Neel Patel¹, Shyam Thakkar¹, Shailendra Singh¹ 

Institution

1 Section of Gastroenterology and Hepatology, West Virginia University School of Medicine, Morgantown, West Virginia, United States

submitted 25.10.2022

accepted after revision 24.1.2023

accepted manuscript online 24.1.2023

published online 13.3.2023

Bibliography

Endoscopy 2023; 55: 766–772

DOI 10.1055/a-2019-3652

ISSN 0013-726X

© 2023. Thieme. All rights reserved.

Georg Thieme Verlag KG, Rüdigerstraße 14, 70469 Stuttgart, Germany

 Scan this QR-Code for the author commentary.



 Fig. 1 s

Supplementary material is available under <https://doi.org/10.1055/a-2019-3652>

Corresponding author

Shailendra Singh, MD, Section of Gastroenterology and Hepatology, West Virginia University School of Medicine, PO Box 9161, 5th Floor HSC, Room 5500, Morgantown, WV 26506, United States

Shail121@gmail.com

ABSTRACT

Background Multiple devices are available for tissue approximation. A new through-the-scope suturing (TTSS) device has recently been introduced; however, data on its scope of use and clinical effectiveness are limited. We aimed to assess the clinical course and effectiveness of this TTSS device.

Methods A retrospective review was performed for consecutive patients who underwent TTSS application. Primary outcomes were technical and clinical success, and secondary outcomes included adverse events and long-term clinical success.

Results 53 patients (mean age 67.8 years; 69.8% females) were included, with a mean defect size of 32.6 mm (SD 11.9). Technical success was achieved in 51 patients (96.2%). Clinical success was achieved in 49 patients (92.4%). Two patients (3.8%) experienced failed fistula closure after technical success. Long-term follow-up (>30 days) was available for 45 patients (84.9%), with a mean

follow-up of 7.2 months. One patient (1.9%) had self-reported bleeding that did not require further intervention.

Conclusions TTSS was an effective and safe method for the closure of large gastrointestinal defects and could be used for fistula closure and stent fixation, making it a valuable addition to the armamentarium of endoscopic closure devices.

Introduction

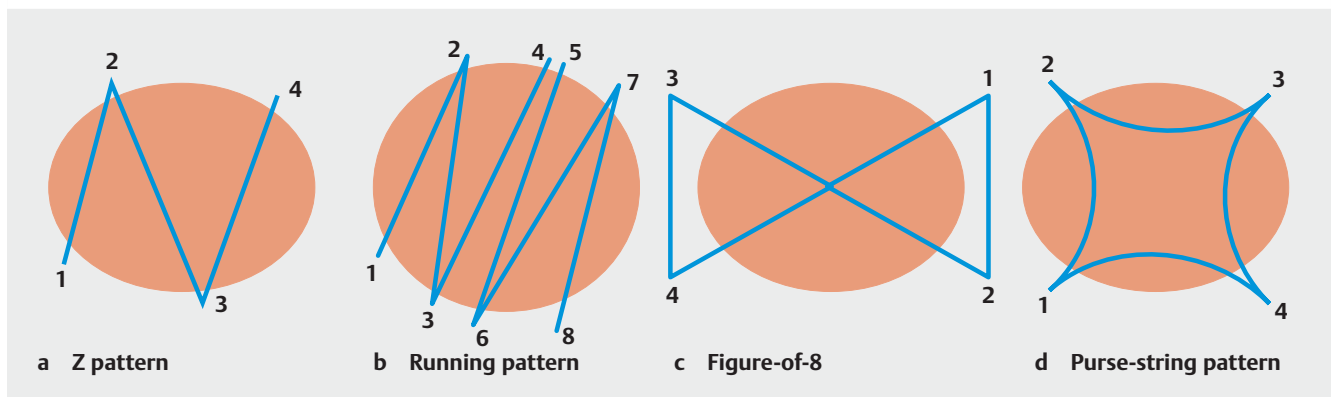
Endoscopic mucosal resection (EMR) and endoscopic submucosal dissection (ESD) result in mucosal defects of various sizes with exposure to muscularis and submucosal vessels; these defects can result in immediate or delayed adverse events, including bleeding and perforation. These risks can be decreased by defect closure [1, 2]. Multiple devices are available for mucosal closure, including through-the-scope (TTS) clips, over-the-scope (OTS) clips, and endoscopic suturing. However, each device has benefits and limitations, including the need for withdrawal of the endoscope (OTS clips and suturing devices), and some defects may not be amenable to closure by TTS clips owing to the size or shape of the defect. A novel endoscopic tack-and-suture device was developed to overcome some of these limitations. The through-the-scope suture (TTSS) system was approved for the endoscopic approximation of soft tissue. It can be used for the closure of EMR or ESD defects, fistulas, leaks, or perforation. TTSS eliminates the need to withdraw the endoscope from the patient before applying therapy and can be used with both gastroscopes and colonoscopes for challenging locations. A recent study demonstrated the successful use of the TTSS to close gastrointestinal (GI) defects [3]; however, the study involved a relatively short follow-up duration, and data on the use of TTSS still needs to be provided. We aimed to assess the clinical course and effectiveness of TTSS across multiple indications, including mucosal defect closure, fistulas, and stent fixation.

Methods

We performed a retrospective review of patients who underwent TTSS application for achieving endoscopic mucosal defect apposition at our tertiary care center from April 2021 to September 2022. Institutional Review Board (IRB: 2205571128) approval was obtained, and informed consent was obtained from patients as per the standard of care. Data were collected on demographic and clinical variables, procedural details, clinical course, and follow-up.

Endoscopic deployment procedure:

The X-Tack Endoscopic-HeliX System (Apollo Endosurgery, Austin, Texas, USA) comprises four 5-mm-long surgical steel helical tacks preloaded on a 3-0 polypropylene suture that runs through an eyelet on each tack. Each tack is deployed sequentially using a catheter through the 2.8-mm working channel of the endoscope. Tacks penetrate into tissue adjacent to mucosal defects (or stents) and are then approximated by suture tension and placement of a suture cinch to achieve mucosal closure. The tacks are designed to reach into but not through the muscularis propria, in contrast to the over-the-scope suturing (OTSS) system, which offers full-thickness sutures. We closed linear defects using four tacks in a “Z” pattern; a second device was used, if needed, in a “running” pattern (two Z patterns) for larger or irregular defects. A “figure-of-8” pattern for irregular and a “purse-string” pattern for circular defects were also used (► Fig. 1).



► **Fig. 1** Steps of tack placement in different suture patterns. **a** Z pattern for linear defects. **b** Running pattern (two Z patterns) for larger or irregular defects. **c** Figure-of-8 pattern for irregular or circular defects. **d** Purse-string pattern for circular defects.

All procedures were performed by a single endoscopist experienced in endoscopic suturing, with the patient under conscious sedation. Lesions were resected using previously described EMR [4], ESD [5], or hybrid ESD [6–8] techniques. Patients were discharged on the same day. Follow-up was performed to ascertain clinical success (over the phone in 2 weeks to discuss adverse events or biopsy results) and long-term success (>30 days' follow-up), adverse events, further endoscopic/surgical intervention, and complications.

Study outcomes

Study outcomes included technical success (defined as adequate TTSS placement in intended location/orientation based on immediate endoscopic examination, with complete closure of defect/stent fixation), clinical success (maintenance of defect closure or stent fixation based on clinical/endoscopic follow-up), and adverse event rate. Adverse events were categorized based on the American Society for Gastrointestinal Endoscopy lexicon [9]. Mild adverse events were defined as symptoms requiring postprocedural medical attention, and moderate adverse events were defined as those that needed repeat endoscopy.

Concomitant treatment was defined as any additional treatment applied during the same session as TTSS application. Long-term success was based on a follow-up of at least 30 days. Rescue treatment was defined as using other closure devices to close the defect in order to attain clinical success after a prior failed closure attempt(s).

Statistical analysis:

Results were described as means (SD) or proportions where appropriate. The 95% CIs for study outcomes were calculated using the Agresti–Coull method. All statistical analyses were conducted with Stata version SE16 (StataCorp, College Station, Texas, USA).

Results

Baseline characteristics:

A total of 53 patients (mean age 67.8 years [SD 10.8 years]; 69.8% females) who underwent TTSS application were included. ► **Table 1** summarizes the baseline characteristics of the patients.

Location and indication for TTSS

The most common indications for TTSS use were defect closure after lesion resection (n = 42, 79.2%), followed by fistula closure (n = 7, 13.2%) and stent fixation (n = 3, 5.7%). The most common site of use was the colon (n = 37, 69.8%), followed by the stomach (n = 9, 17.0%), duodenum (n = 4, 7.5%), and esophagus (n = 3, 5.7%) (► **Table 1**). Overall, 26 patients (49.0%) underwent EMR, 13 (24.5%) underwent ESD, and 3 (5.7%) underwent hybrid ESD. The mean defect size was 32.61 mm (SD 11.9 mm). Most patients required one device, but two devices were used in 11 patients (20.7%) (► **Table 2**). Mean follow-up was 7.2 months (SD 3.3 months).

► **Table 1** Baseline characteristics of the study patients (n = 53).

Age, mean (SD), years	67.8 (10.8)
Female sex, n (%)	37 (69.8)
Lesion site, n (%)	
Upper GI	
▪ Esophagus	3 (5.7)
▪ Stomach	9 (17.0)
▪ Duodenum	4 (7.5)
Lower GI	
▪ Cecum	3 (5.7)
▪ Ascending colon	11 (20.7)
▪ Transverse colon	9 (17.0)
▪ Descending colon	3 (5.7)
▪ Sigmoid colon	7 (13.2)
▪ Rectum	4 (7.5)
Procedure, n (%)	
▪ ESD	13 (24.5)
▪ EMR	26 (49.0)
▪ Hybrid ESD ¹	3 (5.7)
▪ Fistula closure	7 (13.2)
▪ Stent fixation	3 (5.7)
▪ Perforation	1 (1.9)
Macroscopic type, n (%)	
Upper GI lesions	
▪ Submucosal lesions	4 (7.5)
▪ Sessile polyp with high grade dysplasia	3 (5.7)
▪ Intestinal type, well-differentiated adenocarcinoma	1 (1.9)
▪ Hyperplastic polyp with high grade focal dysplasia	2 (3.8)
Lower GI lesions	
▪ Tubular adenoma	15 (28.3)
▪ Tubulovillous adenoma	9 (17.0)
▪ Tubular/tubulovillous adenoma	1 (1.9)
▪ Serrated	4 (7.5)
▪ Hyperplastic	2 (3.8)
▪ Invasive colonic adenocarcinoma	1 (1.9)
Overall defect size, mean (SD), mm, (n = 42)	32.6 (11.9)
GI, gastrointestinal; ESD, endoscopic submucosal dissection; EMR, endoscopic mucosal resection.	
¹ Hybrid ESD is defined as the use of a snare EMR at the final stage of the ESD procedure.	

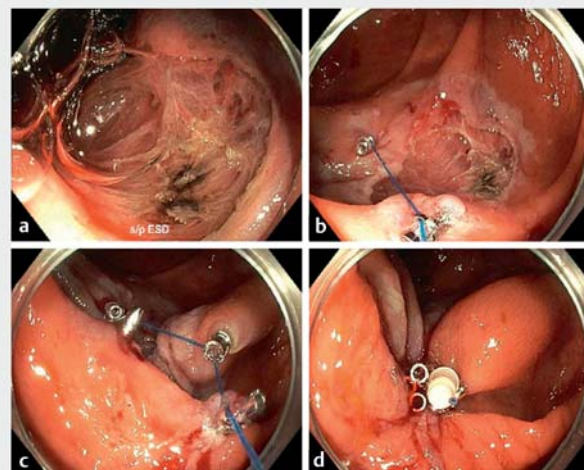
► **Table 2** Primary and secondary outcomes of the study (n=53).

Primary outcomes	
Overall technical success, n (%)	
▪ Yes	51 (96.2)
▪ No	2 (3.8)
Overall clinical success ¹ , n (%)	
▪ Attained	49 (92.4)
▪ Failed	2 (3.8)
Rescue treatment, n (%)	2 (3.8)
Device that achieved defect closure, n (%)	
▪ Endoscopic suturing system ²	1 (1.9)
▪ Septal-occluder device ³	1 (1.9)
Concomitant treatment, n (%)	3 (5.7)
Supplemental closure (hybrid approach)	
▪ Total no. of TTS clips used, n (%)	3 (5.7)
▪ 1 clip	1 (1.9)
▪ 2 clips	1 (1.9)
Technical success of defect closure ⁴ (stratified by defect size), n (%)	
▪ <20 mm	6 (11.3)
▪ 20–30 mm	14 (26.4)
▪ 30–40 mm	14 (26.4)
▪ >40 mm	8 (15.1)
Secondary outcomes	
Long-term follow-up available ⁵	45
Follow-up, mean (SD), months	7.2 (3.3)
Adverse events, n (%)	1 (1.9)
No. of tack and suture devices used, n (%)	
▪ 1	42 (79.2)
▪ 2	11 (20.7)

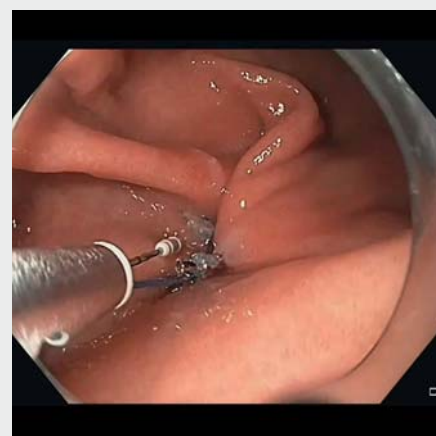TTS, through-the-scope.
¹ We included only patients with technical success.
² OverStitch (Apollo Endosurgery Inc., Austin, Texas, USA).
³ Amplatzer PFO Occluder; Abbott Laboratories, Abbott Park, Illinois, USA)
⁴ Defect closure after either EMR, ESD, or hybrid ESD.
⁵ Patients with more than 30 days' follow-up.

Lower GI defect closure

The most common colonic site of application was the ascending colon (n=11, 20.7%), followed by the transverse colon (n=9, 17.0%), sigmoid colon (n=7, 13.2%), rectum (n=4, 7.5%), cecum (n=3, 5.7%), and descending colon (n=3, 5.7%) (► **Table 1**). ► **Fig. 2** and ► **Video 1** demonstrate colonic TTSS application. ► **Table 1** describes the lesion site, indication, and histology.



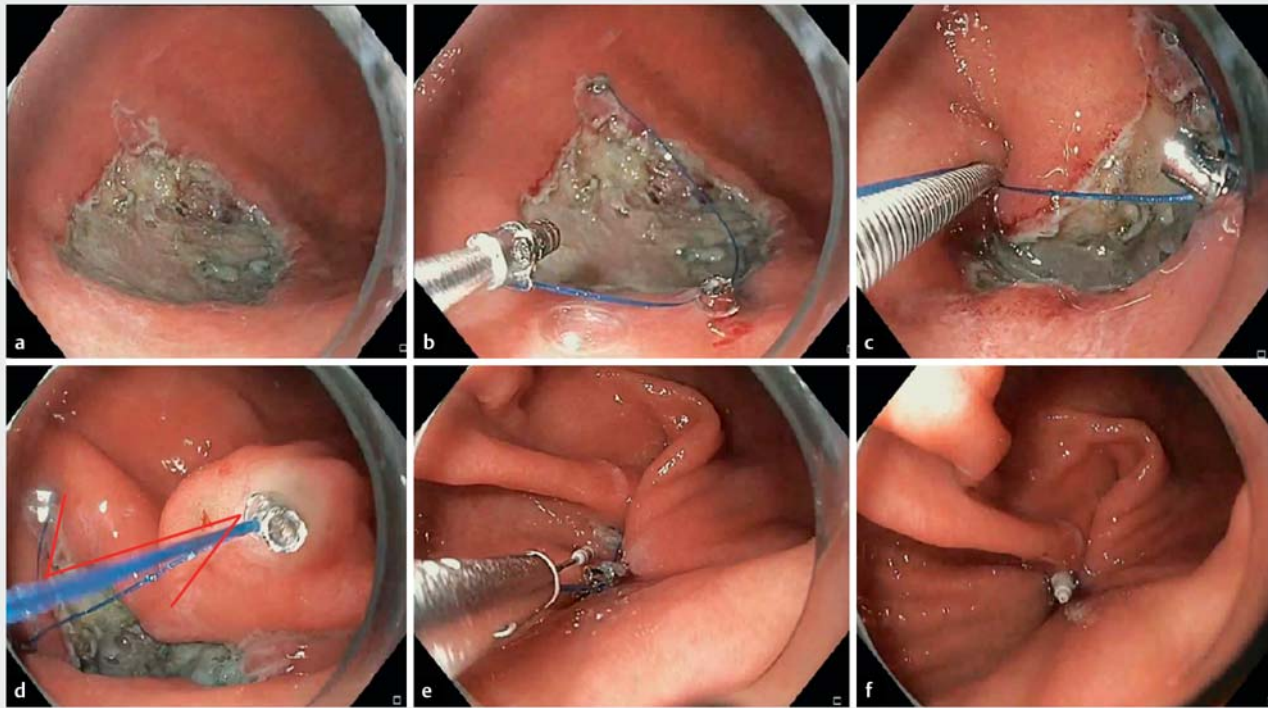
► **Fig. 2** Endoscopy images. **a** The lesion was removed en bloc with endoscopic submucosal dissection. **b** Two tacks were placed directly opposite each other. **c** Each tack was placed sequentially. **d** Coaxial suture was tightened and cinched to close the defect.



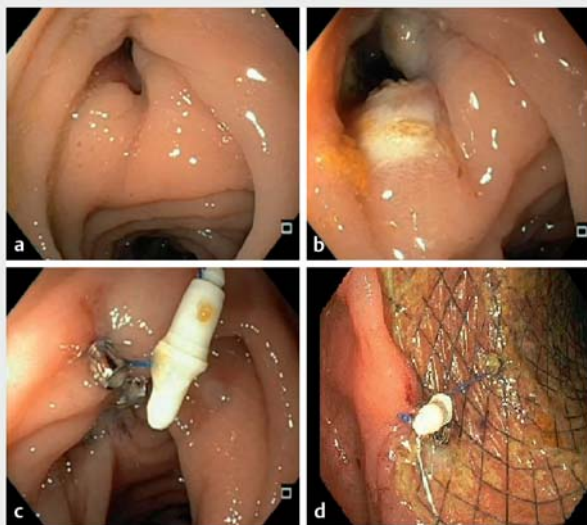
► **Video 1** Application of the endoscopic through-the-scope suturing device for mucosal defect closure and stent fixation. Online content viewable at: <https://doi.org/10.1055/a-2019-3652>

Upper GI tract defect closure

► **Fig. 3**, ► **Fig. 4**, and ► **Video 1** demonstrate the application of the TTSS device for mucosal defect closure and stent fixation. Histological assessment showed that, of the 10 upper GI lesions, there were 4 submucosal lesions (7.5%), 3 sessile adenomatous polyps with high grade dysplasia (5.7%), 2 hyperplastic polyps with high grade dysplasia (3.8%), and 1 intestinal-type well-differentiated adenocarcinoma (1.9%) (► **Table 2**).



► **Fig. 3** Endoscopy images. **a** Endoscopic submucosal dissection defect in the upper gastrointestinal tract (stomach). **b, c** Tacks were placed sequentially. **d** A Z pattern was used for the defect closure. **e, f** The defect was completely closed after approximation of tacks and cinching of the suture.



► **Fig. 4** Endoscopy images. **a** Pancreatocolonic fistula. **b** Argon plasma coagulation was used on the fistulous tract to promote re-epithelialization and tissue apposition. **c** The fistulous tract was entirely closed with the through-the-scope suture system. **d** A fully covered self-expandable metal stent was anchored by the tack and suture device.

Technical and clinical success

Technical success (successful placement of TTSS) was achieved in 51/53 patients (96.2%; 95%CI 0.87–0.99). One instance of technical failure was due to suture breakage during the closure of a large cecal polyp resection site. Another technical failure occurred during fistula closure below the gastroesophageal junction and was due to friable tissue that could not hold the tacks after penetration.

Clinical success with TTSS was attained in 49/53 patients from the total cohort (92.4%, 95%CI 81.64–97.52). Two patients (3.8%) experienced failure of fistula closure after initial technical success and required rescue treatment. Thus, the overall clinical success for fistula closure was 57.1% (4/7). Clinical success for patients requiring defect closure or perforation closure was 97.7% (42/43). In three patients (5.7%), TTS clips were deployed along with the TTSS (one clip in two patients and two clips in one patient). Clinical success for stent fixation was 100% (3/3).

Long-term follow-up (>30 days) was available for 45 patients (84.9%) with a mean follow-up of 7.2 months (SD 3.3 months). Long-term clinical success was observed in all these patients. One patient (1.9%) had self-reported bleeding that did not require further intervention. However, there were no moderate or severe adverse events associated with TTSS use. Repeat endoscopic evaluation at our center was performed in 23 of these 45 patients (>3 months) and revealed sustained closure of defects in all cases, and the helical tacks were retained in 19

patients during follow-up (see **Fig. 1 s** in the online-only Supplementary material).

Use of alternative devices

Rescue treatment was required for two patients (3.8%) in whom fistula closure failed after TTSS. In one patient, closure failed in the distal esophagus and the defect was subsequently successfully closed with the OverStitch endoscopic suturing system (Apollo Endosurgery, Inc.). For another patient with a fistula at a colopelvic anastomosis, TTSS was initially used; however, follow-up sigmoidoscopy demonstrated a persistent fistulous tract for which argon plasma coagulation and OTS clip system (Ovesco Endoscopy GmbH, Tübingen, Germany) was used for closure. The fistula persisted, and we opted to finally close it using a septal-occluder device (Amplatzer PFO Occluder; Abbott Laboratories, Abbott Park, Illinois, USA). At 3.5 months' follow-up, both patients remained well and asymptomatic.

Discussion

Our experience with TTSS demonstrated high technical and clinical effectiveness. Technical and clinical success rates were 96.2% and 92.5%, respectively, and we demonstrated the wide-ranging applicability of the device in various GI tract locations. There were no serious device-related adverse events during follow-up. For patients who underwent defect closure, TTSS showed excellent outcomes regardless of defect size. Currently, there are no published long-term data for outcomes after TTSS. We observed long-term clinical success in 84.9% of cases at a mean follow-up of 7.2 months.

Mahmoud et al. reported outcomes of TTSS in their retrospective study [3] and noted a technical success rate of 89.2% and supplemental closure with another device of 24.7%. Two cases of pain and minor bleeding were reported [3]. We encountered two instances (3.8%) of technical failure. In the first instance, the suture broke when tension was applied while cinching. The suture in the TTSS is thinner than that in OTSS devices and thus can only withstand lower tensile forces. Care must be taken to avoid over-tension while ensuring adequate apposition of margins. The second instance involved the closure of a fistula with friable margins; in such cases, the tacks should ideally be placed in healthy tissue about 5–10 mm adjacent to the defect, as friable tissue may not hold the tacks under tension.

TTSS achieved high clinical success in closing large irregular defects in difficult locations that are otherwise challenging to close using other available devices. TTS clips, OTS clips, and OTSS systems are other devices available for defect closure. Closure of large and irregular defects with TTS clips can sometimes be difficult due to the restricted opening distance between the clip jaws and relatively superficial closure limited to the mucosa. Thus, closure may be incomplete in 33% of cases of large defects (>2 cm) [10]. OTS clips provide more durable closure and have wider area capture; however, scope withdrawal and reinsertion are needed for deployment. The clip jaws allow adequate capture in defect sizes up to 20 mm [11]. While the OTSS system is not limited by defect size and allows durabil-

ity, deep closure, scope withdrawal, and reinsertion are still required and involve a steep learning curve. TTSS can thus be advantageous for the closure of large defects with irregular margins, and it can be cost effective compared with the use of multiple TTS clips for the closure of large, irregular defects [3]. TTSS is also suitable for challenging locations, such as the right colon, avoiding the need for scope withdrawal and reinsertion (needed by OTS clips and other endoscopic suturing devices). Prior data also suggest that when closing large defects, TTSS is associated with lower user workload and stress, as assessed by the National Aeronautics and Space Administration Task Load Index, compared with TTS clips [12].

We experienced two clinical failures (3.8%) in cases of fistula closure. Fistula closure was eventually achieved with an alternative endoscopic suturing system (OverStitch) and a septal-occluder device (Amplatzer PFO Occluder). The helical tacks are not designed to anchor within the muscularis propria; thus, only mucosa-to-mucosa apposition is reliably ensured. As fistulous tracts are transmural, fistula closure may fail when only mucosal apposition can be achieved with the tack apparatus. Despite these two unsuccessful attempts at fistula closure, our results demonstrated overall high success and favorable outcomes with TTSS, especially for the closure of large defects after EMR or ESD. We used different suture patterns preferentially depending on the defect shape, which could have contributed to the success rate; however, the standard closure pattern has yet to be studied and should be addressed in future studies.

In most cases we used one TTSS device, but two were needed in 20.7% of patients for the closure of large defects. In three cases, we used a TTS clip as a concomitant treatment. The defect could have been closed by the placement of a second TTSS device (this was not a “technical failure”); however, due to the small residual area after using one device, we completed closure with one or two clips. The TTSS system (\$695/device) achieves cost parity with approximately four TTS clips (US \$150–250/clip) [3]. This hybrid TTSS+TTS clip approach can be used to reduce costs in cases where one TTSS device attains near-complete closure. TTSS can reduce the defect size, making complete closure achievable by 1–2 clips when the original defects may be too large or cumbersome for primary clip closure.

The main limitations of our study are its retrospective nature and single-center design. Our study involved only a single arm, and a follow-up endoscopy was available in 23 of 45 patients. It is difficult to conclude whether natural healing or the suturing device itself was responsible for sustained defect closure; however, the lack of adverse events and the presence of the TTSS system on surveillance examinations suggest that it may be reasonable to expect that once successfully deployed, the TTSS system can provide durable closure during the healing process to prevent complications. Despite these limitations, this is the first study to show TTSS outcomes across various indications with a relatively long follow-up.

In conclusion, using the TTSS helical tack system for the closure of colonic and upper GI defects was safe and efficacious, and the system could be a valuable addition to the armamentarium of endoscopic closure devices.

Competing interests

S. Singh is a consultant for Apollo Endosurgery. A. Krishnan, S.M. Shah-Khan, Y. Hadi, N. Patel, and S. Thakkar declare that they have no conflict of interest.

References

- [1] Ahmed Y, Othman M. EMR/ESD: techniques, complications, and evidence. *Curr Gastroenterol Rep* 2020; 22: 39
- [2] Oka S, Tanaka S, Kanao H et al. Current status in the occurrence of postoperative bleeding, perforation and residual/local recurrence during colonoscopic treatment in Japan. *Dig Endosc* 2010; 22: 376–380
- [3] Mahmoud T, Wong Kee Song LM, Stavropoulos SN et al. Initial multi-center experience using a novel endoscopic tack and suture system for challenging GI defect closure and stent fixation (with video). *Gastrointest Endosc* 2022; 95: 373–382
- [4] Yokota T, Sugihara K, Yoshida S. Endoscopic mucosal resection for colorectal neoplastic lesions. *Dis Colon Rectum* 1994; 37: 1108–1111
- [5] Fujishiro M, Yahagi N, Nakamura M et al. Successful outcomes of a novel endoscopic treatment for GI tumors: endoscopic submucosal dissection with a mixture of high-molecular-weight hyaluronic acid, glycerin, and sugar. *Gastrointest Endosc* 2006; 63: 243–249
- [6] Toyonaga T, Man-I M, Morita Y et al. Endoscopic submucosal dissection (ESD) versus simplified/hybrid ESD. *Gastrointest Endosc Clin N Am* 2014; 24: 191–199
- [7] Toyonaga T, Man-I M, Morita Y et al. The new resources of treatment for early stage colorectal tumors: EMR with small incision and simplified endoscopic submucosal dissection. *Dig Endosc* 2009; 21: (Suppl. 01): S31–37
- [8] Byeon JS, Yang DH, Kim KJ et al. Endoscopic submucosal dissection with or without snaring for colorectal neoplasms. *Gastrointest Endosc* 2011; 74: 1075–1083
- [9] Cotton PB, Eisen GM, Aabakken L et al. A lexicon for endoscopic adverse events: report of an ASGE workshop. *Gastrointest Endosc* 2010; 71: 446–454
- [10] Albéniz E, Álvarez MA, Espinós JC et al. Clip closure after resection of large colorectal lesions with substantial risk of bleeding. *Gastroenterology* 2019; 157: 1213–1221
- [11] Zhang LY, Bejjani M, Ghandour B et al. Endoscopic through-the-scope suturing. *VideoGIE* 2021; 7: 46–51
- [12] Hernandez A, Marya NB, Sawas T et al. Gastrointestinal defect closure using a novel through-the-scope helix tack and suture device compared to endoscopic clips in a survival porcine model (with video). *Endosc Int Open* 2021; 9: E572–E577 Erratum in: *Endosc Int Open* 2022; 9: C12