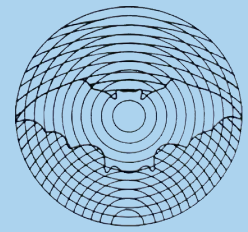


# Dansk Ultralyddiagnostisk Selskab

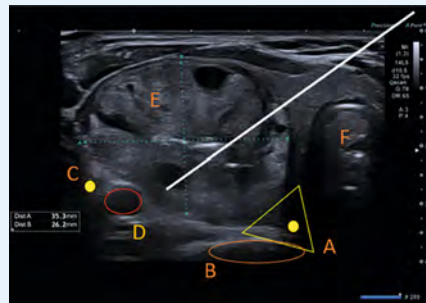


## Treatment of thyroid nodules with radiofrequency ablation

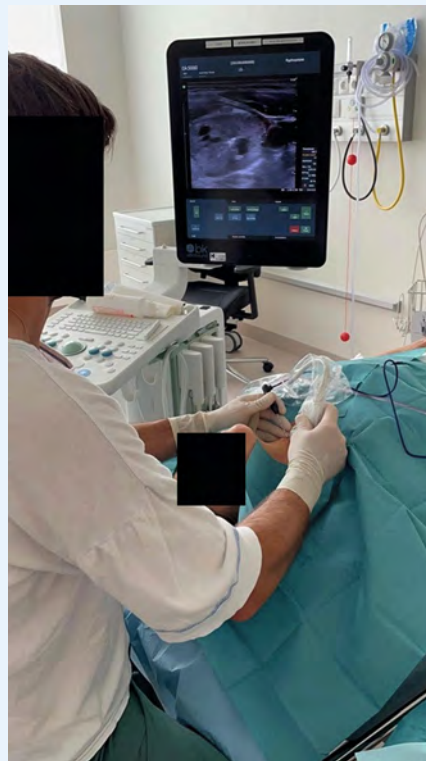Thyroid Adenomas is a very common cause of pressure symptoms, swallowing difficulties and cosmetic symptoms. However, the majority of thyroid adenomas are benign, and do not need treatment if they are asymptomatic. When treatment is required, the standard treatment in most centers is surgery, typically in the form of a lobectomy (removal of a thyroid lobe). In order to avoid the risks associated with surgery: bleeding, infection, recurrent laryngeal nerve damage and postoperative hypothyroidism [1, 2], radiofrequency ablation has been introduced as a minimally invasive treatment option. Radiofrequency ablation (or RFA) is a technique in which radiofrequency energy (an electric current) is used to generate heat that destroys the cells and causes the adenoma to shrink.

Candidates for treatment with radiofrequency ablation are patients with a symptomatic benign solitary hypofunctioning (cold) thyroid nodule, with a volume between 2 and 20 ml. Prior to treatment, two benign fine needle aspiration cytology samples must be present, in order to be as sure as possible that the nodule to be treated is benign. The expected average volume reduction of the treated adenoma is around 70% after one year [3], as well as improvement of discomfort from the adenoma can be expected [4].

The treatment takes place in an outpatient clinic setting. It is done under local anesthesia and typically lasts 30 minutes. The technique is very similar to that used in ultrasound-guided fine needle aspiration. A “trans-isthmic” approach is used to avoid coming into contact with the recurrent laryngeal nerve. (► Fig. 1). A setup is typically used where the attending physician sits at the head end of the patient and thus has a good overview, and both hands are free to move (► Fig. 2).



► **Fig. 1** Trans-isthmic technique with RFA electrode **A**: Danger triangle with Recurrent Laryngeal Nerve; **B**: Oesophagus; **C**: Vagal Nerve; **D**: Carotid Artery; **E**: Adenoma; **F**: Trachea.



► **Fig. 2** Setup in RFA treatment. RFA is done as a sterile procedure, and the physician is at the head end, with the ultrasound in one hand and the RFA electrode in the other hand.

The radiofrequency ablation technique was developed in South Korea and has spread to several European countries in recent years, and is also recommended by the European Thyroid Society, ETA [5]. Copenhagen University Hospital – Rigshospitalet (CUH-RH) is the first center in the Nordic Countries to offer treatment of thyroid adenomas with radiofrequency ablation. Over the past two and a half years, more than 80 patients have been treated at the department of otolaryngology at CUH-RH. Patients are offered inclusion in a study of self-reported thyroid related quality of life using the THYPRO questionnaire. Measurements are done before treatment and 3 months and 1 year after the treatment.

For further information or a visit to see RFA treatment being carried out at our department, the authors can be contacted (mikkel.kaltoft.01@regionh.dk).

### Advantages of RFA

- Less invasive procedure than surgery.
- No need for full anesthesia.
- Performed in an outpatient setting.
- Shorter recovery time than after surgery.
- No surgical scar.
- Low rate of complications.
- Preservation of thyroid function and less risk of hypothyroidism.

### Disadvantages of RFA

- No histological diagnosis is made as in surgery.
- Serious complications are rare. The most frequent risks are pain, bleeding, burns to the skin and infection. Infection can be a delayed problem and manifest itself with swelling, pain and redness.
- Rare serious complications include damage to the oesophagus, tra-

chea and recurrent laryngeal nerve.  
The risk of permanent damage to  
the vocal cord nerve leading to a  
change in voice is less than 1 %.

**Mikkel Kaltoft, Tobias Todsén & Christoffer  
Holst Hahn**

Department of Otorhinolaryngology, Head  
and Neck Surgery & Audiology – Rigshospitalet,  
Copenhagen, Denmark

## References

- [1] Godballe C, Madsen AR, Sørensen CH et al. Risk factors for recurrent nerve palsy after thyroid surgery: a national study of patients treated at Danish departments of ENT Head and Neck Surgery. *Eur Arch Otorhinolaryngol* 2014; 271 (8): 2267–2276. doi:10.1007/s00405-013-2767-7
- [2] Verloop H, Louwerens M, Schoones JW et al. Risk of hypothyroidism following hemithyroidectomy: systematic review and meta-analysis of prognostic studies. *J ClinEndocrinolMetab* 2012; 97 (7): 2243–2255
- [3] Cho SJ, Baek JH, Chung SR et al. *Endocrinol Metab (Seoul)*. 2020 Jun 35 (2): 339–350
- [4] Valcavi R, Tsamatropoulos P. HEALTH-RELATED QUALITY OF LIFE AFTER PERCUTANEOUS RADIO-FREQUENCY ABLATION OF COLD, SOLID, BENIGN THYROID NODULES: A 2-YEAR FOLLOW-UP STUDY IN 40 PATIENTS. *Endocr Pract* 2015; 21 (8): 887–896
- [5] Papini E, Monpeyssen H, Frasoldati A et al. 2020 European Thyroid Association Clinical Practice Guideline for the Use of Image-Guided Ablation in Benign Thyroid Nodules. *Eur Thyroid J* 2020; 9 (4): 172–185