



# Forty-Eight Hour Ex Vivo Perfusion and Two-Hour Simulated Reperfusion after a Major Traumatic Upper Extremity Amputation

Viola Antonia Stögner, MD<sup>1</sup> Lavinia Neubert, MD<sup>2</sup> Alexander Kaltenborn, PD<sup>3</sup>  
Bettina Wiegmann, PD<sup>4</sup> Christian Krettek, MD<sup>5</sup> Peter Maria Vogt, MD<sup>1</sup> Nicco Krezdorn, PD<sup>1</sup>

<sup>1</sup> Department of Plastic, Aesthetic, Hand, and Reconstructive Surgery, Hannover Medical School, Hannover, Germany

<sup>2</sup> Institute of Pathology, Hannover Medical School, Hannover, Germany

<sup>3</sup> Department of Trauma and Orthopedic Surgery, Plastic, Hand, and Reconstructive Surgery, Armed Forces Hospital Westerstede, Westerstede, Germany

<sup>4</sup> Department for Cardiothoracic, Transplantation and Vascular Surgery, Hannover Medical School, Hannover, Germany

<sup>5</sup> Department of Traumatology, Hannover Medical School, Hannover, Germany

**Address for correspondence** Viola Antonia Stögner, MD, Department of Plastic, Aesthetic, Hand and Reconstructive Surgery, Hannover Medical School, Carl-Neuberg-Straße 1, 30625 Hannover, Germany (e-mail: stoegner.viola@mh-hannover.de).

J Reconstr Microsurg Open 2023;8:e28–e31.

## Abstract

**Background** Extremity replantation as well as allotransplantation aim to restore form and function of the amputated limb. Both approaches, however, are clearly limited by the ischemic time. Ex vivo perfusion (EVP), already well-established in the field of solid organ transplantation, represents a promising tool to overcome this restriction.

**Methods** We have currently established the technical requirements to provide EVP to severed limbs in a clinical hospital setting and hereby report of a 48-hour hypothermic EVP (EVP48) of an upper extremity amputated at the level of the proximal humerus, followed by a 2-hour simulated reperfusion (2SR) with donor blood.

**Results** Muscle biopsies revealed histopathologically well preserved, vital muscle tissue after EVP24, and partially grouped muscle fiber necrosis with predominantly vital muscle tissue after EVP48 and 2SR. Analyses of perfusate samples showed a marked decline of biochemical muscle damage markers during EVP48. Cytokine analysis disclosed an isolated increase of the proinflammatory cytokines, interleukine-6, monocyte chemoattractant protein-1, and interferon- $\gamma$ , during EVP and 2SR. Magnetic resonance imaging, performed after EVP48, indicated partial muscle necrosis of the intrinsic hand muscles only, while no signs for infection or inflammation were present.

**Conclusion** Our single case experience shows the general feasibility of an amputated limb ex vivo salvage perfusion setting to allow for delayed replantation up to 24 hours. Nevertheless, an accurate prior planning is crucial to ensure successful implementation of EVP in the acute clinical setting.

## Keywords

- ▶ ex vivo perfusion
- ▶ extremity
- ▶ amputation
- ▶ replantation

received  
June 6, 2022  
accepted after revision  
October 31, 2022  
accepted manuscript online  
December 28, 2022

DOI <https://doi.org/10.1055/a-2004-0041>.  
ISSN 2377-0813.

© 2023. The Author(s).

This is an open access article published by Thieme under the terms of the Creative Commons Attribution-NonDerivative-NonCommercial-License, permitting copying and reproduction so long as the original work is given appropriate credit. Contents may not be used for commercial purposes, or adapted, remixed, transformed or built upon. (<https://creativecommons.org/licenses/by-nc-nd/4.0/>)

Thieme Medical Publishers, Inc., 333 Seventh Avenue, 18th Floor, New York, NY 10001, USA

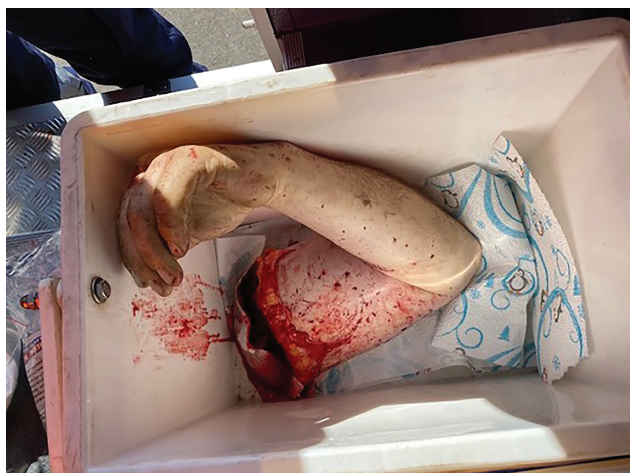Extremity replantation, as well as allotransplantation aim to restore form and function of the amputated limb. Both approaches, however, are clearly limited by the ischemic time.<sup>1</sup> Logistic circumstances or an impaired clinical constitution of the amputee are factors, which often lead to exceedance of the tolerable cold ischemic time of up to 6 hours.<sup>1,2</sup> In cases, where there is no option for replantation, delayed vascularized composite allotransplantation could provide a functional human limb. Ex vivo perfusion (EVP), already well-established in the field of solid organ transplantation, represents a promising tool to overcome this restriction. Recent studies not only proofed the feasibility of extremity EVP in humans, but also showed a significant extension of swine limb survival of up to 24 hours by use of EVP.<sup>2-5</sup> Based on these findings we currently have established the technical requirements to provide EVP to severed limbs in a clinical hospital setting. We hereby report of an EVP of an amputated upper extremity for a period of 48 hours (EVP48) followed by 2-hour simulated reperfusion (2SR).

### Epicrisis

A 44-year-old male patient with a traumatic major avulsion amputation injury of the upper extremity at the subcapital level was presented to our emergency department. The limb had been caught in a farming machinery with a comminution avulsion at the proximal humerus and severe contamination (► Fig. 1). Apart from a closed and slightly displaced radial shaft fracture, however, the rest of the amputated limb was in good condition. After initial surgical debridement the severely polytraumatized patient was not in the physical condition for an immediate replantation. To preserve the amputated limb and maintain the option of a delayed replantation, an EVP system was used.

### Methods

EVP comprised a conventional extracorporeal membrane oxygenation device (Maquet GmbH) and the low-potassium preservation solution histidine-tryptophan-ketoglutarate (Custodiol Dr. Franz Köhler Chemie GmbH, 5-liter bag), sup-



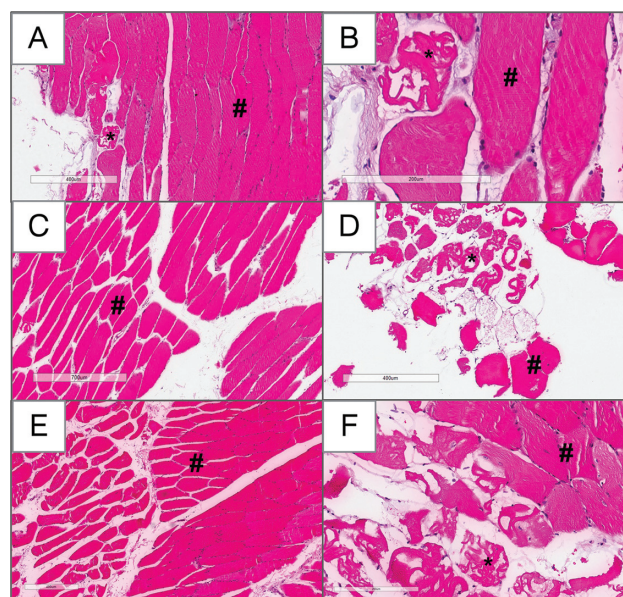
**Fig. 1** Securing of the amputated limb at the accident site.

plemented with antibiotics (piperacillin/tazobactam), antimycotics (voriconazol), and methylprednisolone. The solution was renewed every 6 hours. Initial microbiological swabs were taken and a debridement as well as fasciotomy of the amputated limb performed before the EVP was started. Perfusate samples and muscle biopsies were taken regularly, while the peripheral oxygen saturation was measured continuously by use of transmissive pulse oximetry. The targeted perfusate temperature was 10°C. The patient's medical constitution was monitored continuously in an intensive care unit in order to closely reevaluate the feasibility of replantation. Facing a still critically unstable patient after 24 hours of EVP (EVP24), the indication for replantation was ultimately discarded. The patient received a definite plastic stump formation later on. Muscle biopsies of the perfused limb, however, revealed vital and well-preserved tissue at this point. For this reason we decided to continue the EVP for another 24 hours. A magnetic resonance imaging (MRI) of the amputated limb was performed subsequently, followed by a 2SR with a total of six human erythrocyte concentrates and 500 IE heparin. During 2SR perfusate samples were gained for cytokine level analysis using the MILLIPLEX MAP Rat Cytokine/Chemokine Magnetic Bead Panel (Merck Millipore, Schwalbach, Germany) and Luminex 100/200 analyzer (LuminexCorp., TX).

### Results

#### Ex Vivo Perfusion

The mean perfusate temperature was 10.9°C during EVP and 19°C during SR. The mean perfusion flow was 0.27 L/min



**Fig. 2** Histopathology of *M. flexor digitorum superficialis* after 24 hours of ex vivo perfusion (EVP24) (A, B), EVP48 (C, D), and reperfusion (E, F). Vital muscle tissue (#) with only single and patchy muscle fiber necrosis (\*) with focal intramuscular edema, lacking inflammatory cell infiltrations (A, B). Partially grouped muscle fiber necrosis (\*) with predominantly vital muscle tissue (#) (C, D). No changes in tissue quality were noted during reperfusion (E, F) in comparison to EVP48. Bars indicate 400  $\mu$ m (A, D, and E), 200  $\mu$ m (B and F), and 700  $\mu$ m (C).

during EVP and 0.37 L/min during SR. The mean peripheral oxygen saturation was 45.5% during EVP and 89% during 2SR.

**Pathology**

Histopathological examinations of the flexor digitorum superficialis and profundus muscle revealed vital muscle tissue with only single and patchy muscle fiber necrosis with focal intramuscular edema, lacking inflammatory cell infiltrations after EVP24. Biopsies, obtained after EVP48, showed partially grouped muscle fiber necrosis with predominantly vital muscle tissue. No histopathological changes were noted in the biopsies taken during SR compared to EVP48 (→ Fig. 2).

**Microbiology**

Initial microbiological swabs of the amputation stump exhibited a microflora consisting of Bacillus cereus, Enterococcus hirae, Pseudomonas stutzeri, and Acinetobacter lwoffii.

**Radiology**

A conventional MRI scan of the amputated limb after EVP48 showed diffuse, inter-, and intramuscular edema, but no

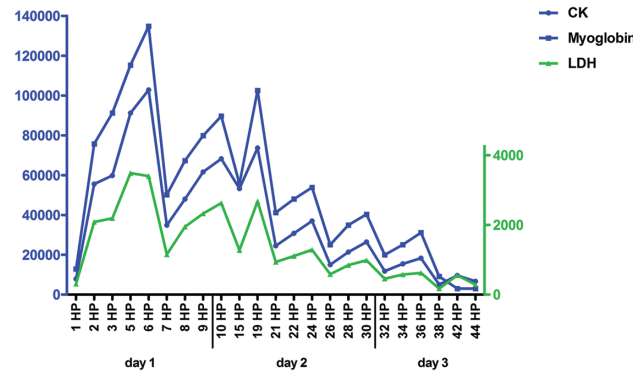
signs of infection or inflammation. Muscle morphology indicated predominantly vital muscle tissue, while the pennate structure of the muscle appeared to vanish in the intrinsic hand muscles only—suggesting muscle necrosis in this area.

**Biochemical Markers for Muscle Damage**

Creatinine kinase (CK), myoglobin, and lactate dehydrogenase (LDH) levels, measured in the amputates perfusate revealed an increase with a peak after EVP6 (CK 102,883 U/L, LDH 3,404 U/L, myoglobin 134,813 µg/L), followed by a steady decline (CK 6,656 U/L, LDH 386 U/L, myoglobin 3,000 µg/L) (→ Fig. 3).

**Cytokines**

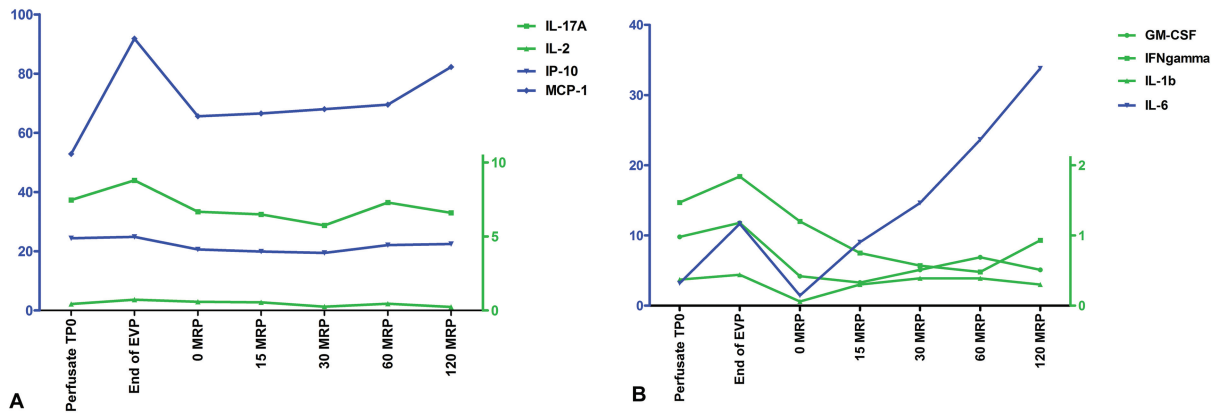
Cytokine level analysis revealed an isolated marked increase of the proinflammatory cytokines, interleukine-6 (IL-6) and monocyte chemotactic protein-1 (MCP-1), during the EVP. IL-6 further showed a steady and steep increase throughout the whole 2SR period, while MCP-1 and interferon-γ (IFN-γ) showed an increase from minute 60 to 120 of SR. Granulocyte macrophage-colony-stimulating factor (GM-CSF) levels slowly increased during the first hour and declined during the second hour of SR (→ Fig. 4A,B).



**Fig. 3** After an initial distinct increase, the biochemical markers for muscle damage, creatinine kinase (CK), myoglobin, and lactate dehydrogenase (LDH), measured in the amputates’ perfusate, showed a steady decline from 6 hours of ex vivo perfusion (EVP6) on.

**Discussion**

EVP is a highly promising salvage option for limb preservation and might significantly improve replantation surgery. While the existing data on extremity EVP mainly arises from animal studies, Werner et al reported successful EVP of five human upper extremities from brain-dead organ donors.<sup>6</sup> Taeger et al replanted two lower extremities after 16 and 12 hours of EVP, respectively.<sup>4</sup> Our histopathological investigation revealed preserved muscle tissue after EVP24, while tissue after EVP48 showed muscle fiber necrosis to a higher extent besides preserved muscle tissue. The radiological findings suggest that the small and distally located intrinsic hand muscles are more vulnerable to tissue damage during



**Fig. 4** Cytokine level analysis revealed an isolated marked increase of the proinflammatory cytokines monocyte chemotactic protein-1 (MCP-1) (A) and interleukin-6 (IL-6) (B) during ex vivo perfusion (EVP). IL-6 showed a steady and steep increase throughout the whole simulated reperfusion (SR) period. MCP-1 (A) and interferon-γ (IFN-γ) (B) showed an increase from minute 60 to 120 of reperfusion. Granulocyte macrophage-colony-stimulating factor (GM-CSF) levels slowly increased during the first hour and declined during the second hour of SR (B).

EVP. The markers for muscle damage increased early on as signs of the warm ischemic damage but clearly decreased during hypothermic EVP. In accordance to the literature we observed an upregulation of IL-6, as well as MCP-1, during EVP. Sadaria et al reported rising levels of IL-6, IL-8, GM-CSF, and MCP-1,<sup>7</sup> while Kueckelhaus et al noted an upregulation of the cytokine IL-6 during EVP.<sup>8</sup> SR with donor blood allowed to monitor cytokine behavior during a reperfusion process and showed an isolated, marked, and steady increase of IL-6 levels. MCP-1 and IFN- $\gamma$  increased during the last hour of 2SR. Nonetheless, no clinical or radiological signs for inflammation or infection, respectively, could be captured.

We performed an early fasciotomy, just before the EVP started. Due to a loss of tissue resistance and consecutive massive edema formation during EVP, however, we would rather consider fasciotomy in a delayed fashion upon reperfusion. Histidine-tryptophan-ketoglutarate (Custodiol) was the quickest available preservation solution and therefore used in our case. Although, other, dextran or albumin containing, solutions might effect even more tissue protection.<sup>5</sup>

To our knowledge, this is the first report imitating the actual reperfusion process after an EVP48 of an amputated human upper limb.

## Conclusion

Our single case experience shows the general feasibility of an amputated limb ex vivo salvage perfusion setting to allow for delayed replantation up to 24 hours. Nevertheless, an accurate prior planning is crucial to ensure successful implementation of EVP in the acute clinical setting. Risk and benefits for potential candidates have to be reevaluated continuously.

## Note

This paper was presented at the 59th Annual Conference of the Austrian Society of Plastic, Aesthetic and Reconstructive Surgery (ÖGPÄRC), on October 8, 2021.

## Conflict of Interest

None declared.

## References

- 1 Blaisdell FW. The pathophysiology of skeletal muscle ischemia and the reperfusion syndrome: a review. *Cardiovasc Surg* 2002;10(06):620–630
- 2 Krezdorn N, Macleod F, Tasigiorgos S, et al. Twenty-four-hour ex vivo perfusion with acellular solution enables successful replantation of porcine forelimbs. *Plast Reconstr Surg* 2019;144(04):608e–618e
- 3 Ozer K, Rojas-Pena A, Mendias CL, Bryner BS, Toomasian C, Bartlett RH. The effect of ex situ perfusion in a swine limb vascularized composite tissue allograft on survival up to 24 hours. *J Hand Surg Am* 2016;41(01):3–12
- 4 Taeger CD, Lamby P, Dolderer J, et al. Extracorporeal perfusion for salvage of major amputates. *Ann Surg* 2019;270(01):e5–e6
- 5 Haug V, Kollar B, Tasigiorgos S, et al. Hypothermic ex situ perfusion of human limbs with acellular solution for 24 hours. *Transplantation* 2020;104(09):e260–e270
- 6 Werner NL, Alghanem F, Rakestraw SL, et al. Perfusion of human limb ex situ allografts for 24 hours. *Transplantation* 2017;101(03):e68–e74
- 7 Sadaria MR, Smith PD, Fullerton DA, et al. Cytokine expression profile in human lungs undergoing normothermic ex-vivo lung perfusion. *Ann Thorac Surg* 2011;92(02):478–484
- 8 Kueckelhaus M, Dermietzel A, Alhefzi M, et al. Acellular hypothermic extracorporeal perfusion extends allowable ischemia time in a porcine whole limb replantation model. *Plast Reconstr Surg* 2017;139(04):922e–932e