

Immune-mediated Gastritis in a Patient with metastatic Lung Cancer due to Therapy with the immune Checkpoint Inhibitor Pembrolizumab – Differences and Similarities in Comparison to “endogenous” autoimmune Type A Gastritis and a review of literature

Immun-vermittelte Gastritis bei einem Patienten mit metastasiertem Bronchialkarzinom in Folge einer Therapie mit dem Immun Checkpoint Inhibitor Pembrolizumab – Unterschiede und Ähnlichkeiten im Vergleich zur „endogenen“ autoimmun-vermittelten Typ A Gastritis und eine Literaturübersicht



Authors

Miriam Eva Ecker¹ , Helgard Weckauf², Sandra Tebbe³, Frank Schuppert¹

Affiliations

- 1 Gastroenterology, Endocrinology, Diabetology and General Medicine, Klinikum Kassel GmbH, Kassel, Germany
- 2 Pathology, Klinikum Kassel GmbH, Kassel, Germany
- 3 Private Practice for Haematology and Oncology, Kassel, Germany

Key words

immune-mediated gastritis, autoimmune gastritis, type A gastritis, non-small cell lung cancer, immune checkpoint inhibitor, pembrolizumab

Schlüsselwörter

Immunvermittelte Gastritis, Autoimmungastritis, Typ A Gastritis, Nicht-kleinzelliges Bronchialkarzinom, Immuncheckpoint-Inhibitor, Pembrolizumab

received 07.11.2022

accepted 13.12.2022

published online 24.03.2023

Bibliography

Z Gastroenterol 2022; 60: 1385–1393

DOI 10.1055/a-2000-5705

ISSN 0044-2771

© 2022. The Author(s).

This is an open access article published by Thieme under the terms of the Creative Commons Attribution-NonDerivative-NonCommercial-License, permitting copying and reproduction so long as the original work is given appropriate credit. Contents may not be used for commercial purposes, or adapted, remixed, transformed or built upon. (<https://creativecommons.org/licenses/by-nc-nd/4.0/>).

Georg Thieme Verlag KG, Rüdigerstraße 14,
70469 Stuttgart, Germany

Correspondence

Miriam Eva Ecker

Gastroenterology, Endocrinology, Diabetology and General Medicine, Klinikum Kassel GmbH, Mönchebergstraße 41–43,
34125 Kassel, Germany
ecker-miriam@t-online.de

ABSTRACT

Immune checkpoint inhibitors are increasingly used in advanced malignant diseases and are well-known for their good results. With the blockade of immune checkpoints, the probability of immune-related adverse events is also increased.

We present a 54-year-old female patient with advanced NSCLC. She was treated with pembrolizumab and developed a stable disease under therapy. After six cycles, she presented with massive epigastric pain to our emergency department. Gastroscopy showed severe erosive-fibrinous pangastritis without the involvement of the esophagus, duodenum, or other immune-related adverse effects. Histology showed the complete destruction of the gastric mucosa. We concluded an immune-mediated gastritis by pembrolizumab, after the exclusion of other differential diagnoses.

Despite treatment with prednisolone and marked improvement of her symptoms, the mucosa was never fully reconstituted into a healthy mucosa.

Furthermore, we collected published reports of similar cases and conducted a comparison with features of a typical, endogenous type A gastritis to highlight similarities and differences.

ZUSAMMENFASSUNG

Immun-Checkpoint-Inhibitoren finden immer häufiger Anwendung in der Therapie von fortgeschrittenen Tumorleiden

und sind inzwischen bekannt für ihre Effektivität. Bedingt durch ihren Wirkmechanismus kommt es allerdings auch zu immunvermittelten Nebenwirkungen.

Wir präsentieren den Fall einer 54-jährigen Patientin, die bei fortgeschrittenem NSCLC mit Pembrolizumab behandelt wurde. Darunter wurde eine stable disease erreicht. Nach 6 Zyklen Pembrolizumab stellte sie sich mit stärksten epigastrischen Schmerzen in unserer Notaufnahme vor. In der Gastroskopie zeigte sich eine fibrinös-erosive Pangastritis, ohne jegliche Beteiligung von Ösophagus und Duodenum oder eines anderen Organsystems. Die histologische Untersuchung

des gastralen Gewebes zeigte eine vollständige Destruktion des Epithels. Nach Ausschluss einer klassischen Typ A-, B- oder C-Gastritis, schlussfolgerten wir eine immunvermittelte Gastritis durch Pembrolizumab.

Auch nach Therapie mit Prednisolon und trotz deutlicher klinischer Befundbesserung rekonstituierte sich die Mukosa auch nach 6 Monaten nicht mehr vollständig.

Des Weiteren führten wir eine Literaturrecherche zu publizierten Fällen ähnlicher Gastritiden unter Pembrolizumab durch und verglichen das Krankheitsbild mit der klassischen Typ A-Gastritis.

Introduction

In recent years, therapeutic options for cancer have markedly increased. The approval of immune checkpoint inhibitors (ICIs), such as pembrolizumab, marked a watershed. This monoclonal antibody blocks binding between programmed cell death-1 (PD-1) receptors on activated T-cells and programmed cell death-Ligand-1 (PD-L1) on the target tissue. This stimulates the secretion of interferon-gamma by activated T cells, resulting in higher cytotoxicity and increased secretion of pro-inflammatory cytokines [1]. Hereby tumor cells are cleared by the immune system.

For patients with advanced non-small cell lung cancer (NSCLC), it became first-line treatment if the tumor expresses more than 50% of PD-L1 on its surface [2].

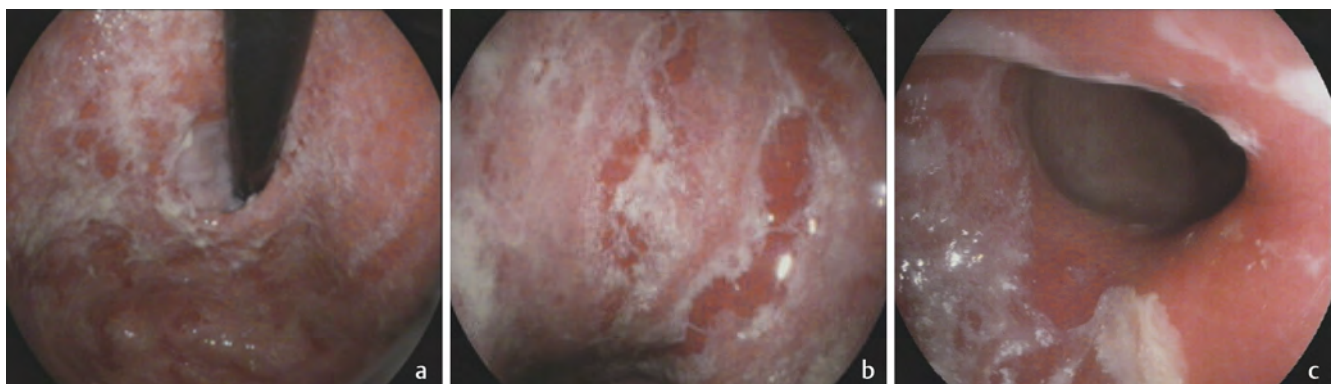
Well-known adverse events are immune-related adverse events (irAEs), particularly of barrier tissues [3] such as skin [4], of the gastrointestinal tract with immune-mediated colitis [5] and of the endocrine system such as autoimmune hypophysitis [6].

We present a case in which pembrolizumab-induced immune-mediated gastritis with the complete destruction of the gastric mucosa and definite sparing of the esophageal and duodenal mucosa. Furthermore, we discuss differences between “endogenous” autoimmune Type A gastritis and present a brief literature review of pembrolizumab-induced gastritis.

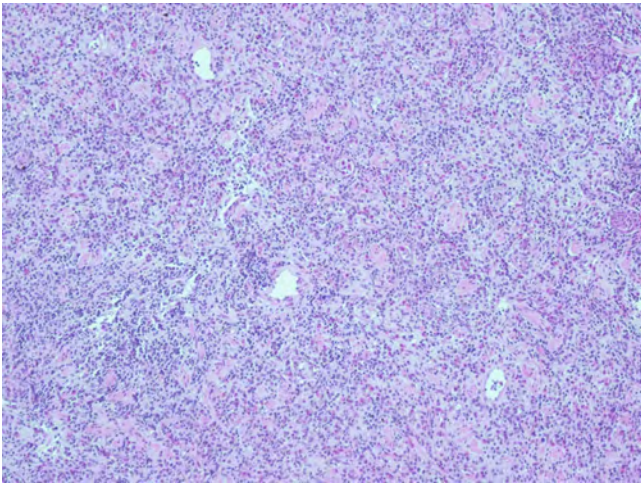
Case presentation

A 54-year-old female patient underwent treatment with carboplatin/pemetrexed/pembrolizumab for metastatic NSCLC, which is considered first-line treatment in this case [7]. The primary tumor was located in the right upper lobe and had metastasized to the adjacent lymph nodes, bones and, most likely, the brain. After the sixth treatment cycle, she presented to the emergency department of our tertiary care hospital with severe epigastric pain, nausea, vomiting and anorexia. She denied hematochezia, melena or hematemesis. Clinical examination revealed umbilical and epigastric pain on palpation. No further signs of an alteration of other organ systems could be detected. Her past medical history revealed uterine fibroids and hypertension. Cardiovascular risk factors included 30 pack years. Due to bone metastases, this patient suffered from severe back pain. Regular medication included opioids and intermittent use of low-dose NSAIDs. Initial blood work did not show a significant pathology.

A gastroscopy shortly after admission and 5 days later showed diffusely hyperemic gastric tissue throughout the stomach from the cardia to the antrum (► Fig. 1a, b, c). In addition, multiple fibrin-covered erosions were found (► Fig. 1a, b, c). Most importantly, the esophageal (► Fig. 1a) and duodenal mucosa (► Fig. 1c) looked unremarkable endoscopically.



► **Fig. 1** **a** Hyperemic gastric mucosa in the cardia and fundus with multiple fibrin-covered erosions and esophageal-gastric junction with normal esophageal mucosa. **b** Hyperemic gastric mucosa in the body with multiple fibrin-covered erosions. **c** Hyperemic antral gastric mucosa with multiple fibrin-covered erosions and gastric-duodenal junction with normal duodenal mucosa.



► **Fig. 2** Massive inflammation with complete destruction of the mucosa in the body with entirely absent vital epithelial glands including the complete absence of parietal cells (HE, × 100).

Histology found a completely destroyed mucosa in the cardia, fundus, body and antrum with entirely absent vital epithelial glands. Furthermore, parietal cells were completely absent in the gastric body. Since the picture was so uniform, only findings in the body are shown as a representative example (► **Fig. 2**). The massive destruction of cells was restricted to the mucosa. The muscularis mucosae and submucosa were found vital and intact. Overall, these findings showed massive erosive pangastritis with completely absent mucosa. The esophagus and duodenum revealed very mild infiltration of inflammatory cells only (figures not shown).

Helicobacter pylori, cytomegalovirus (CMV) antibodies, CMV DNA or Herpes simplex virus (HSV) DNA could not be detected within the tissue and in the serum, respectively, hence making a bacterial or viral etiology of our findings unlikely.

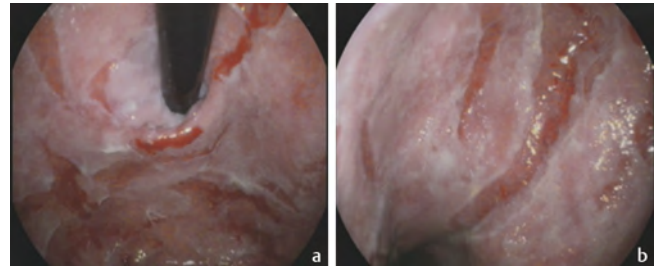
Gastrin levels were below detection, and, in addition, anti-parietal cell-antibodies and anti-intrinsic factor antibodies were not detected in the serum. Thus, these findings excluded an “endogenous” type A gastritis.

The patient did take low-dose NSAIDs intermittently, but a type C gastritis would present with histological hallmarks such as foveolar hyperplasia, mucin depletion in epithelial cells or smooth muscle hyperplasia [8].

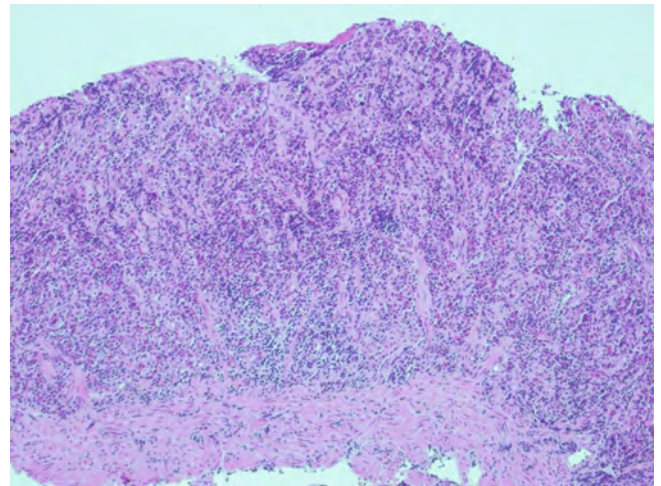
Treatment-wise, high-dose continuous application of intravenous proton-pump inhibitor (PPI) was given initially.

But since parietal cells in the body and fundus were histologically also found to be destroyed and anti-parietal cell-antibodies and anti-intrinsic factor-antibodies were not detected, another noxious agent – pembrolizumab – had to be the causing agent. Furthermore, in concordance with the histology results, the lack of measurable gastrin levels indicated the destruction of G-cells in the antrum.

It was only then that prednisolone at a dose of 100 mg was applied twice daily intravenously for seven days followed by an oral dose of 70 mg in the morning and 30 mg in the evening in order to treat this immune-mediated erosive-fibrinous pangastritis. The administration of prednisolone was in line with current treatment op-



► **Fig. 3 a** Incipient healing of the mucosa in the cardia and fundus after 8 days of high-dose iv prednisolone. **b** Incipient healing of the mucosa in the body after 8 days of high-dose iv prednisolone.



► **Fig. 4** Continued massive inflammation and complete destruction in the antrum with entirely absent vital epithelial glands leaving muscularis mucosae and submucosa intact (HE, × 100).

tions for complications caused by treatment with immune checkpoint inhibitors [5, 6, 7]. After 8 days of high-dose intravenous prednisolone, endoscopy showed incipient healing of the gastric mucosa in the gastric cardia and fundus (► **Fig. 3a**) and body (► **Fig. 3b**). But in the antrum, massive inflammation and complete destruction with entirely absent vital epithelial glands prevailed and the inflammation continued to be confined to the mucosa, leaving muscularis mucosae and submucosa intact (► **Fig. 4**).

After discharge, careful tapering with a prednisolone reduction of 5 mg per week until achieving a maintenance dose of 7.5 mg was recommended.

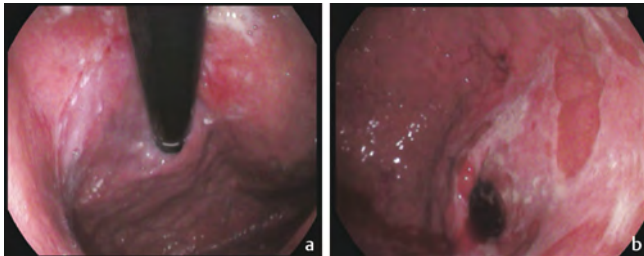
A follow-up gastroscopy was performed about 2, 4 and 6 months after discharge.

At about 2 months after discharge, the patient was adherent to prednisolone tapering and took 30 mg daily. On a numeric rating scale (NRS) up to 10, the patient reported her pain and discomfort level to be around 3 under therapy with 10 mg oxycodone three times per day. Esomeprazole was taken twice daily at a total dose of 40 mg.

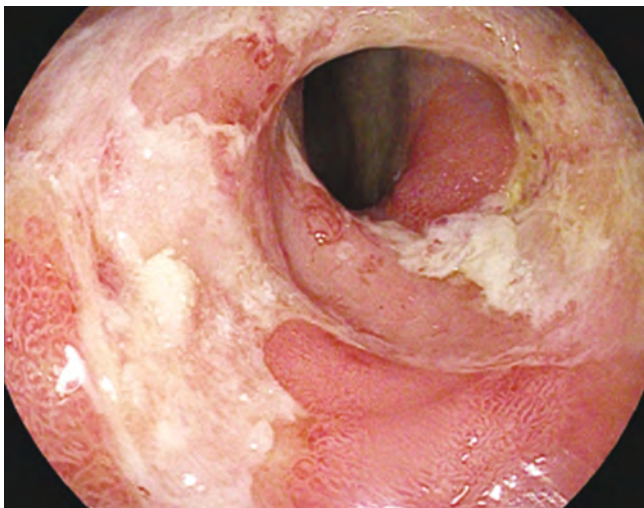
Gastroscopy showed healing of the gastric mucosa, although large areas of hemorrhagic gastritis were still visible. Healing was more pronounced in the fundus and body region of the stomach

(► Fig. 5a), whereas the antrum (► Fig. 5b) was still most affected by the inflammatory destruction.

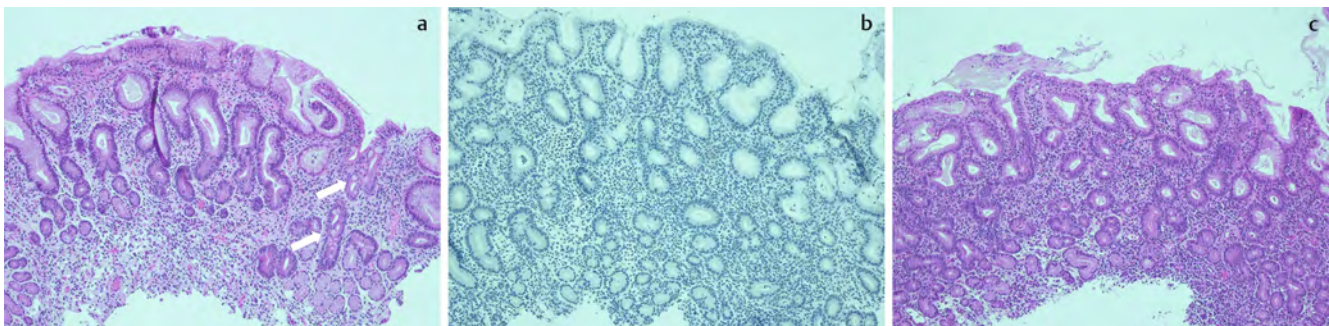
At about four months after discharge, gastroscopy showed progress of the healing in the fundus and body of the stomach; the findings resembled mucosal gastric tissue typically seen in type A gastritis. At this time also, the antral tissue had improved



► Fig. 5 a Continued endoscopic healing in the cardia, the fundus and body. b Wide areas of fibrin-covered erosions still seen macroscopically in the antrum.



► Fig. 6 Incipient healing in the antrum two months later.



► Fig. 7 a Receding inflammation in the antrum and healing commencing with vital epithelial glands and focal intestinal metaplasia (white arrows) (HE, $\times 100$). b Immunohistochemistry with gastrin antibodies showed complete absence of G-cells in the antrum; positive controls not shown ($\times 100$). c Newly formed mucosa in the fundus showed mucoïd glands without signs of regeneration of the site-specific glandular body (“antral metaplasia”) and with parietal cells still missing (HE, $\times 100$).

endoscopically (► Fig. 6) and histologically (► Fig. 7a). As expected, G-cells in the antrum were undetectable as demonstrated using immunohistochemistry with Gastrin antibodies (► Fig. 7b). Interestingly, histology revealed that the regenerated fundic mucosal tissue showed a picture normally seen in the antrum: mucoïd glands without signs of regeneration of the site-specific glandular body (“antral metaplasia”) and with parietal cells still missing (► Fig. 7c).

Her abdominal pain reduced to 1–2 on an NRS up to 10. On the other hand, her daily opioid dose was more than doubled because of bone pain. Due to progressing bone metastases, chemotherapy had to be re-initiated. Her prednisolone dose was further tapered to 4 mg per day and the dose of esomeprazole was unchanged.

Six months after discharge, another follow-up examination took place. By then, a PET-CT showed progress in the size of the primary NSCLC, and the patient had received one cycle of paclitaxel and one application of atezolizumab, another checkpoint inhibitor. Prednisolone had also been discontinued, but esomeprazole was still taken at a dose of 40 mg daily.

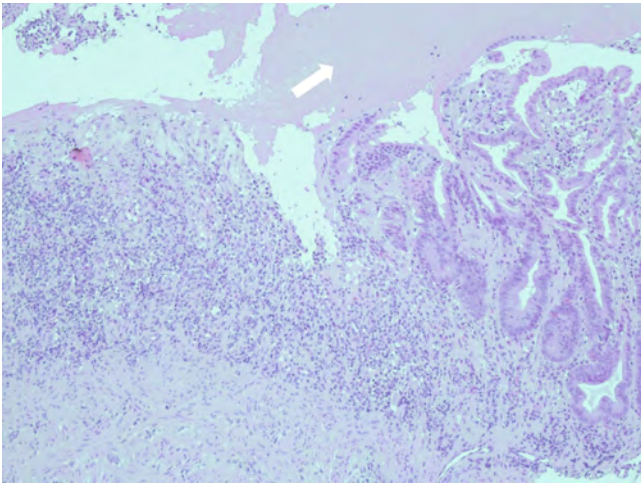
Gastroscopy revealed a further improvement macroscopically (pictures not shown), but mucosal tissue still displayed fibrin-covered mucosal tissue as demonstrated histologically in ► Fig. 8. Immunohistochemical studies with positive and negative controls confirmed the continued absence of antral G-cells (figures not shown).

► Table 1 summarizes our findings of immune checkpoint inhibitor-mediated gastritis, such as by pembrolizumab, and compares them to “endogenous” autoimmune type A gastritis.

Discussion

Our case illustrates that immune checkpoint inhibitors (ICIs) such as pembrolizumab can cause irAEs in the form of immune-mediated gastritis. This rare irAE has been described in a few case reports (compare ► Table 2). In contrast, immune-mediated, i. e., colitis and hypophysitis seem to be relatively more common and are well-known adverse events [1, 5, 6].

Formally speaking, a pre-existing type B or type C gastritis cannot be excluded with certainty, as the damage to the mucosa was too intense for the detection of *H. pylori*, and histological features



► **Fig. 8** The pyloric antrum with destroyed mucosal tissue toward the left and regenerating mucosal tissue toward the right, covered with fibrin (white arrow) (HE, × 100).

within the mucosa typical for adverse effects of NSAIDs could not be seen, simply because there was no mucosa left at all. Hence, we cannot prove or disprove pre-existing type B or C gastritis but, considering all findings and the patient’s history, a relevant type B or C gastritis seem unlikely, and the histological findings are like those in other published cases that are considered irAEs of pembrolizumab.

They are described in varying degrees of similarity with our case, but a small number of cases are extremely similar in their description of macroscopic and histological findings [15, 17, 18, 21]. The outstanding feature hereby is the complete destruction of the gastric epithelium with the absence of mucosal glands. Also unique is the definite sparing of histo-anatomical boundaries to the esophagus and duodenum (► **Fig. 1a** and 1c).

It is remarkable that most cases of immune-mediated gastritis caused by pembrolizumab seem to affect the gastric mucosa exclusively, strictly sparing the esophagus and duodenum.

In addition, two patients treated with pembrolizumab developed CMV-associated gastritis [19, 26]. The macroscopic appearance in those cases was described similarly to our case and other cases without CMV detection, but the treatment is significantly different, obviously.

Some cases mentioned a different anatomical distribution of the affected tissues without the gastric mucosa being the affected area only; in one case study, the transverse colon was affected by the irAE with diffuse erythema and oedema [16]. Another case is described with an affected duodenum leading to gastroduodenitis associated with pembrolizumab [27].

Other cases of pembrolizumab-induced gastritis have been described with histology distinctly different from the aforementioned cases of immune-mediated gastritis, including our own, thus leading the authors to label their cases lymphocytic rather than immune-mediated gastritis [24, 25].

One case mentioned histological similarities to ulcerative colitis [13].

► **Table 1** Typical findings in “endogenous” autoimmune type A gastritis versus immune checkpoint inhibitor-mediated gastritis such as pembrolizumab.

| | “ENDOGENOUS” AUTOIMMUNE TYPE A GASTRITIS | OUR CASE OF IMMUNE CHECKPOINT INHIBITOR MEDIATED GASTRITIS DUE TO PEMBROLIZUMAB |
|--|--|--|
| REGION AFFECTED | Entire stomach, but preferably body of stomach [9]; sparing esophagus and duodenum | Entire stomach, sparing esophagus and duodenum |
| ANTI-PARIETAL CELL ANTI-BODIES | Typically present [10] | Absent |
| INTRINSIC FACTOR ANTI-BODIES | Sometimes present [10] | Absent |
| PARIETAL CELLS | Absent/reduced in numbers [9] | Absent |
| G-CELLS | Hyperplasia [9] | Absent |
| GASTRIN LEVELS | Increased [9] | Low/below detection limits |
| SECONDARY VITAMIN B₁₂ DEFICIENCY | Present [9] | Possibly in development |
| TREATMENT | None [9, 11, 12] | Corticosteroids [7] |
| PRECANCEROUS STATE | Yes | Unknown |

So far, few case reports described the exact same histological pattern with the complete destruction of the glandular epithelium [15, 17, 18, 21].

In one case study, gastrin levels were measured, but contrary to our case, they were normal and hence proved the presence of G-cells [22].

Interestingly, Gaffuri et al. published a temporal process of a patient showing a potential development of the severity: this patient was asymptomatic at first, but PET scans and endoscopy showed a beginning mild inflammation. Histology showed findings resembling lymphocytic gastritis. As the patient was asymptomatic, pembrolizumab was continued. After a further seven cycles, they became symptomatic with epigastric pain, nausea and vomiting – just like our patient. By then, histology found erosions of the gastric mucosa with focal thinning of glandular epithelium, which could be a preliminary stage to the histological findings in our patient with the complete destruction of the glandular epithelium.

► **Table 2** summarizes published cases of immune-mediated gastritis with pembrolizumab.

As previously mentioned, classic type A, B and C gastritis could be excluded because of histology, laboratory findings and the patient’s past medical history. In contrast to “endogenous” autoimmune type A gastritis, anti-parietal cell-antibodies, as well as anti-intrinsic factor-antibodies, whose specificity for autoimmune gas-

► **Table 2** Summary of reported cases of immune-mediated gastritis (reports in languages other than English were excluded; PubMed and Medline were searched). Adapted from Hayama et al. [13].

| Ref | Age | Sex | Type of Tumor | Drug | Duration of Therapy | Symptoms | Endoscopic Findings | Histopathological Findings | CMV | H. pylori | HSV | Treatment |
|------|-----|-----|---------------|-------|---------------------|---|---|--|-----|-----------|-----|--|
| [14] | 71 | M | Lung adeno-Ca | Pemb. | 19 cycles | Epigastric pain before meals | Stomach: multiple erosions, erythema, solid white exudate | Inflammatory cell infiltration, thickening of muscularis mucosa and granulation tissue | n/a | – | n/a | Discontinuation of Pemb. |
| [15] | 61 | F | Ovarian-Ca | Pemb. | 4 Months | Epigastric pain, nausea, vomiting, weight loss | Stomach: complete sloughing of gastric mucosa, spontaneous bleeding | Inflammatory infiltrate, granulation tissue and complete absence of mucosal glands | – | – | n/a | IV steroids |
| [16] | 61 | F | Lung adeno-Ca | Pemb. | 13 cycles | Epigastric pain, diarrhea | Stomach: erythematous, edematous mucosa Colon: indistinct vascular pattern, edematous changes | Stomach: apoptotic bodies, mild inflammation Colon: cryptitis, foamy histiocytes | n/a | – | n/a | Prednisolone |
| [17] | 75 | M | Ureter cancer | Pemb. | 8 Months | Epigastric pain, nausea, anorexia | Stomach: erythematous and ulcerated mucosa | Erosion of mucosa with marked inflammatory cell infiltrate | – | – | n/a | Prednisolone |
| [18] | 67 | F | Melanoma | Pemb. | 5 Years | Abdominal pain, anorexia | Stomach: severe gastritis Esophagus, duodenum: normal appearance | Severe atrophy of glands | n/a | n/a | n/a | Methylprednisolone, PPI |
| [19] | 43 | F | Melanoma | Pemb. | 9 cycles | Epigastric pain, nausea, vomiting | Stomach: oozing, hemorrhagic, edematous, exfoliative mucosa Duodenum: erosions | Inflamed granulation tissue and necrotic detritus | + | n/a | n/a | First dexamethasone without improvement, followed by ganciclovir |
| [13] | 68 | F | Lung adeno-Ca | Pemb. | 25 cycles | Anorexia, nausea, vomiting | Stomach: erythema, oedema | Erosion of mucosa, inflammatory infiltrate, micro-abscesses in fundic gland mucosa | – | – | n/a | Prednisolone |
| [20] | 52 | M | Melanoma | Pemb. | 23 cycles | Abdominal pain, nausea, vomiting, diarrhea, melana, | Stomach: hemorrhagic gastritis | Inflammatory cell infiltration in lamina propria and crypt epithelium | – | – | n/a | Steroids, PPI |
| [21] | 60 | F | Melanoma | Pemb. | 9 cycles | Abdominal pain, nausea, vomiting, hematemesis | Stomach: erythematous, friable, ulcerated and hemorrhagic mucosa Esophagus, duodenum: normal appearance | Subtotal loss of glandular epithelium | – | – | – | Infliximab |

► **Table 2** (Continuation)

| Ref | Age | Sex | Type of Tumor | Drug | Duration of Therapy | Symptoms | Endoscopic Findings | Histopathological Findings | CMV | H. pylori | HSV | Treatment |
|------|-----|-----|-----------------------------------|-------------------------|------------------------|--|--|---|-----|-----------|-----|--|
| [22] | 49 | F | Squamous cell carcinoma of tongue | Pemb. | 7 cycles | Epigastric pain | Stomach: multiple ulcers, friable mucosa, exudate Duodenum: intact | Increased lymphocytes | n/a | – | n/a | Prednisolone, PPI |
| [23] | 41 | F | Melanoma | Pemb. | 10 cycles | Epigastric pain | Stomach: hemorrhagic gastritis | Neutrophilic infiltration in lamina propria and gastric glands, apoptotic bodies | – | – | n/a | Prednisolone |
| [24] | 75 | M | Melanoma | Pemb. | 12 cycles | Asymptomatic | Stomach: diffuse mucosal erythema | Lymphoplasmacytic and neutrophilic infiltration in lamina propria with cryptitis, crypt abscesses | – | – | n/a | Prednisolone (1 mg/kg/day, PPI (40 mg/day) |
| [25] | 44 | M | Melanoma | Pemb. | 1 month | Dyspepsia | Stomach: hiatal hernia | Erosion of gastric mucosa, focal thinning of glandular epithelium | – | – | n/a | Prednisolone (0.5 mg/kg/day), PPI (120 mg/day) |
| [26] | 66 | F | Colon cancer, bladder cancer | Atez. followed by Pemb. | 6 months, then 1 month | Epigastric pain, dysphagia, nausea, vomiting | Stomach: erythematous mucosa with bleeding on contact, ulcers in antrum Esophagus, duodenum: normal appearance | Lymphocytic gastritis Mononuclear inflammatory cell infiltration in lamina propria, crypt apoptosis, apoptotic abscesses | n/a | – | n/a | Ganciclovir |
| [27] | 44 | M | NSCLC | Pemb. | n/a | Dysphagia, bloating, vomiting, anorexia | Stomach: swollen, friable mucosa with exudate Duodenum: small patches of white exudate | Stomach, duodenum: inflammatory infiltrate in lamina propria, glandular distortion and ulceration | – | – | n/a | Prednisolone |

Abbreviations: Pemb.: pembrolizumab, Atez.: atezolizumab, n/a: not available, +: positive, -: negative

tritis is higher than those of anti-parietal cell antibodies [10], were not found. Also, unlike type A gastritis, gastrin levels were not measurable. Our macroscopic findings (► Fig. 1a, b, c) correspond to the histological findings, where we could show that not only parietal cells in the gastric body were completely destructed selectively (► Fig. 2), but also G-cells in the antrum were destructed (► Fig. 7b), revealing more widespread destruction of the gastric epithelium than seen in type A gastritis. Furthermore, gastrin levels in type A gastritis are typically elevated as a result of the achlorhydria following the destruction of parietal cells. In our case, as a result of the absence of G-cells, gastrin levels were below detection limits.

Furthermore, endogenous Type A gastritis is associated with gastric carcinoma and neuroendocrine tumors (NET) [11]; hence, it is seen as a precancerous state and patients are managed differently.

To our knowledge, in other case studies (except one [22]) reporting an irAE of gastritis, the histological samples have not been tested for the absence of parietal cells and G-cells or antibodies typically seen in type A gastritis. So, our case reports the most thorough analysis of a form of autoimmune gastritis induced by checkpoint inhibitors underlining that this type of gastritis is clearly distinct from “endogenous” type A gastritis.

However, similarities include the absence of parietal cells and the following lack of vitamin B₁₂, as intrinsic factor cannot be synthesized. Thus, vitamin B₁₂ cannot be resorbed in adequate quantities in the ileum. As our patient did not have pernicious anemia and vitamin B₁₂ levels were still within normal ranges, the destruction of parietal cells must have occurred recently. But serum levels of holo-transcobalamin were low, indicating an incipient deficiency in vitamin B₁₂. Bodily vitamin B₁₂ stores may last up to years, until a deficiency manifests [28]. Hence, we recommend screening those patients regularly to prevent a vitamin B₁₂ deficiency before symptoms manifest and to substitute B₁₂ subcutaneously.

Treatment and management of patients with irAE gastritis caused by ICIs include glucocorticoid administration to downregulate the immune system. In the published case studies, patients also received PPI. Our histological findings showed that parietal cells were absent, hence PPIs cannot exert their mode of action as the target cells are missing.

But it could be expected that under therapy with glucocorticoids, the mucosa and parietal cells begin to reconstitute and PPIs could be used in a preventative fashion. In our patient, parietal cells have not evolved even after 6 months. Mucosal tissue in the fundus and body did reconstitute but a typical site-specific glandular body with parietal cells could never be seen despite extensive and repeated sampling of the patients’ mucosa throughout the treatment. Instead, antral metaplasia developed in the healing process. Likewise, mucosal tissue in the antrum did recover as well, but gastrin-producing G-cells never re-occurred.

It remains unclear if this is unique to this case or might have occurred in other cases as well. To our knowledge, none of the published cases provided a follow-up as long as ours.

Other described treatment options for irAEs include immune modulatory agents, such as infliximab [22, 29]. This monoclonal antibody inhibits tumor necrosis factor α (TNF- α). We refrained from administering those, as the patient received atezolizumab to treat her progressing metastatic NSCLC and, most im-

portantly, she did respond to prednisolone and her discomfort levels were minor and no longer leading.

Conclusion

This case report describes an immune-mediated gastritis, a rare irAE of checkpoint inhibitors such as pembrolizumab. At first, it may resemble endogenous type A gastritis, but there are substantial differences, such as the absence of autoantibodies against parietal cells, the destruction of G-cells and, thus, the absence of gastrin. Remarkable is the strict sparing of the esophagus and duodenum. Most importantly, management of endogenous type A gastritis and immune-mediated gastritis differs critically. Immune-mediated gastritis caused by ICIs can be treated with corticosteroids or (if feasible) other immunomodulatory agents.

Contributors’ Statement

Miriam Ecker drafted the manuscript. Frank Schuppert treated the patient, and performed and made images of the endoscopies available. Sandra Tebbe treated the patient throughout the time as her oncologist. Helgard Weckauf processed the histological images and made them available for publication. Frank Schuppert, Helgard Weckauf and Sandra Tebbe revised the manuscript critically for intellectual argumentation. All authors gave their final approval of the version to be submitted.

Acknowledgement

The critical revision of the manuscript by Dr. U.W. Denzer, professor of medicine, chief of endoscopy, Marburg University Hospital, Baldingerstrasse, D-35043 Marburg, Germany, is gratefully acknowledged.

Conflict of Interest

The authors declare that they have no conflict of interest.

References

- [1] Dougan M, Luoma AM, Dougan SK et al. Understanding and treating the inflammatory adverse events of cancer immunotherapy. *Cell* 2021; 184 (6): 1575–1588. doi:10.1016/j.cell.2021.02.011
- [2] Reck M, Rodriguez-Abreu D, Robinson AG et al. Pembrolizumab versus Chemotherapy for PD-L1-Positive Non-Small-Cell Lung Cancer. *New England Journal of Medicine* 2016; 375 (19): 1823–1833. doi:10.1056/NEJMoa1606774
- [3] Dougan M, Dougan SK. Targeting Immunotherapy to the Tumor Microenvironment. *J Cell Biochem* 2017; 118 (10): 3049–3054. doi:10.1002/jcb.26005
- [4] Teufel A, Zhan T, Hartel N et al. Management of immune related adverse events induced by immune checkpoint inhibition. *Cancer Letters* 2019; 456: 80–87. doi:10.1016/j.canlet.2019.04.018
- [5] Paparoupa M, Stupperich S, Goerg-Reifenberg L et al. Successful Treatment of an Immune-Mediated Colitis Induced by Checkpoint Inhibitor Therapy in a Patient with Advanced Melanoma. *Case Rep Gastroenterol* 2020; 14 (3): 554–560
- [6] Hartmann A, Paparoupa M, Volkmer BG et al. Autoimmune hypophysitis secondary to therapy with immune checkpoint inhibitors: Four cases describing the clinical heterogeneity of central endocrine dysfunction. *J Oncol Pharm Pract* 2020; 26 (7): 1774–1779

- [7] Wills B, Brahmer JR, Naidoo J. Treatment of Complications from Immune Checkpoint Inhibition in Patients with Lung Cancer. *Cur Treat Options Oncol* 2018; 19 (9): 46
- [8] Steinbuss G, Kriegsmann K, Kriegsmann M. Identification of Gastritis Subtypes by Convolutional Neuronal Networks on Histological Images of Antrum and Corpus Biopsies. *Int J Mol Sci* 2020; 21 (18): 11. doi:10.3390/ijms21186652
- [9] Kamada T, Maruyama Y, Monobe Y et al. Endoscopic features and clinical importance of autoimmune gastritis. *Dig Endosc* 2022; 34 (4): 700–713. doi:10.1111/den.14175
- [10] Lahner E, Norman GL, Severi C et al. Reassessment of intrinsic factor and parietal cell autoantibodies in atrophic gastritis with respect to cobalamin deficiency. *Am J Gastroenterol* 2009; 104 (8): 2071–2079
- [11] Pimentel-Nunes P, Libânio D, Marcos-Pinto R et al. Management of epithelial precancerous conditions and lesions in the stomach (MAPS II): European Society of Gastrointestinal Endoscopy (ESGE), European Helicobacter and Microbiota Study Group (EHMSG), European Society of Pathology (ESP), and Sociedade Portuguesa de Endoscopia Digestiva (SPED) guideline update 2019. *Endoscopy* 2019; 51 (4): 365–388. doi:10.1055/a-0859-1883
- [12] Shah SC, Piazuelo MB, Kuipers EJ et al. AGA Clinical Practice Update on the Diagnosis and Management of Atrophic Gastritis: Expert Review. *Gastroenterology* 2021; 161 (4): 1325–1332.e7
- [13] Hayama N, Ihara H, Honma Y et al. Severe gastritis due to pembrolizumab treatment in a lung cancer patient *Respirol Case Rep*: © 2020 The Authors. *Respirology Case Reports* published by John Wiley & Sons Australia, Ltd on behalf of The Asian Pacific Society of Respirology. 2020: pe00636
- [14] Saito K, Ozono D, Nagumo H et al. Temporal observation of endoscopic and histological findings of gastritis after administration of an immune checkpoint inhibitor: a case report. *Clin J Gastroenterol* 2022; 15 (2): 368–373. doi:10.1007/s12328-021-01582-5
- [15] Nasser R, Fisher Y, Klein A. Gastrointestinal: Severe gastritis with complete gastric mucosal sloughing. *J Gastroenterol Hepatol* 2021; 36 (10): 2639. doi:10.1111/jgh.15427
- [16] Omotehara S, Nishida M, Yamanashi K et al. A case of immune checkpoint inhibitor-associated gastroenteritis detected by ultrasonography. *J Clin Ultrasound* 2021; 49 (6): 605–609. doi:10.1002/jcu.22975
- [17] Okubo Y, Hosotani K, Taniguchi Y et al. Gastrointestinal: Recurrence of pembrolizumab-induced severe gastritis after tapering steroid therapy. *J Gastroenterol Hepatol* 2021; 36 (3): 586. doi:10.1111/jgh.15248
- [18] Vandepapelière J, Siple J, Libbrecht L et al. Auto-immune gastritis induced by pembrolizumab, an anti-PD-1, in a melanoma patient. *Acta Gastroenterol Belg* 2020; 83 (3): 482–484
- [19] Kim H, Ha SY, Kim J et al. Severe cytomegalovirus gastritis after pembrolizumab in a patient with melanoma. *Curr Oncol* 2020; 27 (4): e436–e39
- [20] Elmasry M, Dong B, Rios C et al. Delayed hemorrhagic gastritis caused by immunotherapy in a patient With metastatic melanoma. *Am J Med Sci* 2022. doi:10.1016/j.amjms.2022.02.010
- [21] Cinnor B, Crossman H, Kaplan J et al. First Reported Case of Pembrolizumab-Induced Immune Mediated Hemorrhagic Gastritis. *Gastroenterology* 2017; 52 (5): S891
- [22] Liu WT, Li YF, Hsieh TY. Unusual severe gastritis and gastric ulcers caused by pembrolizumab. *Journal Postgrad Med* 2022; 68 (1): 38–40. doi:10.4103/jpgm.JPGM_1132_20
- [23] Rao BB, Robertson S, Philpott J. Checkpoint Inhibitor-Induced Hemorrhagic Gastritis with Pembrolizumab. *Am J Gastroenterol* 2019; 114 (2): 196. doi:10.1038/s41395-018-0366-3
- [24] Gaffuri P, Espeli V, Fulcini F et al. Immune-related acute and lymphocytic gastritis in a patient with metastatic melanoma treated with pembrolizumab immunotherapy. *Pathologica* 2019; 111 (3): 92–97
- [25] Yip RHL, Lee LH, Schaeffer DF et al. Lymphocytic gastritis induced by pembrolizumab in a patient with metastatic melanoma. *Melanoma Res* 2018; 28 (6): 645–647
- [26] Lu J, Firpi-Morell RJ, Dang LH et al. An Unusual Case of Gastritis in One Patient Receiving PD-1 Blocking Therapy: Coexisting Immune-Related Gastritis and Cytomegaloviral Infection. *Gastroenterol Res* 2018; 11 (5): 383–387. doi:10.14740/gr1068w
- [27] Mendo R, Figueiredo P, Mascarenhas L. Checkpoint Inhibitor-Induced Gastroduodenitis: An Unusual Manifestation. *GE Port J Gastroenterol* 2021: 150–152. doi:10.1159/000509196
- [28] Carmel R. Diagnosis and management of clinical and subclinical cobalamin deficiencies: why controversies persist in the age of sensitive metabolic testing. *Biochimie* 2013; 95 (5): 1047–1055. doi:10.1016/j.biochi.2013.02.008
- [29] Sawai Y, Katsuya Y, Shinozaki-Ushiku A et al. Rapid temporal improvement of pembrolizumab-induced pneumonitis using the anti-TNF-alpha antibody infliximab. *Drug Discov Ther* 2019; 13 (3): 164–167. doi:10.5582/ddt.2019.01032