

Revision of Failed Osteochondritis dissecans Surgical Treatment: Case Report

Revision einer fehlgeschlagenen chirurgischen Behandlung der Osteochondritis dissecans: Fallbericht



Authors

Marco Maiotti¹, Valentina Rossi¹, Daniele Armocida² 

Affiliations

- 1 Orthopedics, Shoulder Unit Villa Stuart Clinic (Rome), Rome, Italy
- 2 Human Neuroscience, University of Rome La Sapienza, Rome, Italy

Key words

knee, osteochondritis dissecans, arthroscopy, orthopedics, surgery

Schlüsselwörter

Knie, Osteochondritis dissecans, Arthroskopie, Orthopädie, Chirurgie

received 21.10.2022

accepted after revision 29.11.2022

published online 20.1.2023

Bibliography

Z Orthop Unfall 2024; 162: 310–315

DOI 10.1055/a-1994-0956

ISSN 1864-6697

© 2023. The Author(s).

This is an open access article published by Thieme under the terms of the Creative Commons Attribution-NonDerivative-NonCommercial-License, permitting copying and reproduction so long as the original work is given appropriate credit. Contents may not be used for commercial purposes, or adapted, remixed, transformed or built upon. (<https://creativecommons.org/licenses/by-nc-nd/4.0/>).

Georg Thieme Verlag KG, Rüdigerstraße 14,
70469 Stuttgart, Germany

Correspondence

Dr. Daniele Armocida

Human Neuroscience

University of Rome La Sapienza

Del Policlinico 155

00185 Rome, Italy

danielearmocida@yahoo.it

ABSTRACT

Background Osteochondritis dissecans (OD) is one of the most common cartilage lesions of the knee. Conservative treatment is recommended if the lesions are stable with no loose bodies or there are open physes. Surgical intervention is recommended as the primary treatment in symptomatic adults with unstable chondral lesions or with concomitant loose bodies. **Methods** We describe a case of a patient suffering from OD with a bone lesion in the weight-bearing area of medial femoral condyle. Arthroscopy was performed and an osteochondral fragment from the medial femoral condyle was observed and two articular loose bodies were removed. After months, the patient returned with pain and a locked knee. magnetic resonance imaging (MRI) presented a new unstable chondral flap at the posterior border of the previous lesion. Surgery was performed again, and at open examination, the previous OD lesions were covered by regenerative tissue, with a lesion of 3 cm² at the inferior medial part of the chondral flap. The peripheral margins were cleaned, and a subchondral crater was curetted. The subchondral lesion was debrided, and the flap was fixed with pins and a central bioresorbable screws. **Results** Revision surgery with fixation of the chondral flap using bioresorbable pins and screws led to satisfactory results. **Conclusion** Open revision surgery allowed us a more accurate assessment of the OD area to provide an effective fixation of the chondral flap and in this circumstance, this should have been done after seeing the first MRI.

ZUSAMMENFASSUNG

Hintergrund Die Osteochondritis dissecans (OD) ist eine der häufigsten Knorpelläsionen des Knies. Eine konservative Behandlung wird empfohlen, wenn die Läsionen stabil sind und keine Wackelkörper vorhanden sind oder es sich um offene Stellen handelt. Bei symptomatischen Erwachsenen mit instabilen chondralen Läsionen oder gleichzeitigen lockeren Körpern wird als erste Maßnahme ein chirurgischer Eingriff empfohlen. **Methoden** Wir beschreiben den Fall eines Patienten, der an einer OD mit einer Knochenläsion im lasttragenden Bereich des medialen Femurkondylus litt. Es wurde eine Arthroskopie durchgeführt, bei der ein osteochondrales Fragment des medialen Femurkondylus festgestellt und 2 Gelenklocke-

rungskörper entfernt wurden. Nach Monaten kehrte der Patient mit Schmerzen und blockiertem Knie zurück. Die MRT zeigte einen neuen instabilen Knorpellappen am hinteren Rand der früheren Läsion. Der Patient wurde operiert, und bei der offenen Untersuchung wurde die frühere OD-Läsion durch regeneratives Gewebe mit einer 3 cm² großen Läsion im unteren medialen Teil des Knorpellappens bedeckt. Die peripheren Ränder wurden gesäubert und der subchondrale Krater wurde kürettiert. Die subchondrale Läsion wurde debridiert, und der

Lappen wurde mit Stiften und einem zentralen bioresorbierbaren Skalpell fixiert. **Ergebnisse** Die Revisionsoperation mit Fixierung des chondralen Lappens mit bioresorbierbaren Stiften und Schrauben führte zu zufriedenstellenden Ergebnissen. **Schlussfolgerung** Die offene Revisionsoperation ermöglichte uns eine genauere Beurteilung des OD-Bereichs, um eine wirkungsvolle Fixierung des Knorpellappens vorzunehmen, was in diesem Fall nach der ersten MRT-Untersuchung hätte erfolgen sollen.

Abbreviations

LFC	lateral femoral condyle
MFC	medial femoral condyle
MRI	magnetic resonance imaging
OD	osteochondritis dissecans

Background

Osteochondritis dissecans (OD) is one of the most common cartilage lesions of the knee and in approximately 85% of cases, the weight-bearing surface of the medial femoral condyle (MFC) is involved [1]. Of the remaining patients, 13% experience lesions of the lateral femoral condyle (LFC) and only 2% exhibit defects in the trochlear notch [1]. These uncommon lesions of the LFC are frequently associated with an intact discoid meniscus. Sometimes the exact location of the OD lesion is strictly related to a complete or incomplete discoid meniscal tear.

The exact etiology of OD is still unclear and traumatic, genetic, and ischemic causes have all been proposed as possible causes. The onset of OD is often subtle, and its symptoms depend on both the patient's age and disease progression at presentation [2, 3]. Sometimes, asymptomatic OD can be accidentally discovered on plain radiographs taken for other reasons, while advanced stages can have a presentation pretty similar to other common knee injuries. Conservative treatment is recommended if the lesions are stable with no loose bodies or there are open physes. Physical therapy strategies include isometric quadriceps exercises in addition to stretching and soft tissue modalities. Return to physical and work activities are generally allowed after resolution of pain symptoms, a normal clinical examination, and if X-rays and magnetic resonance imaging (MRI) show signs of OD healing. Surgical intervention is currently recommended as the primary treatment in symptomatic adults with unstable chondral lesions or in case of concomitant loose bodies.

Is hypothesis [2] is that OD of the knee represents a separation of an accessory ossification nucleus of the distal femoral epiphysis, which is partially attached during maturation, but it may be completely separate if exposed to trauma. For this reason, the type of sport practiced by younger individuals can be an important risk factor. Other researchers have identified a mutation in the ACAN gene, which is important for cartilage function, as responsible for dominant familial OD [3]. This dominant inheritance is easily seen

in some cases, such as a family in which three out of four daughters developed bilateral OD [4].

Conversely, earlier studies such as that of Petrie [5] refute the idea that OD is a familial inherited disorder but rather suggest it is a “disorder produced by different etiologies”. Interestingly, the aforementioned studies provide a peculiar juxtaposition of the genetic component of OD. It has been also proposed that the repetitive microtrauma may cause OD.

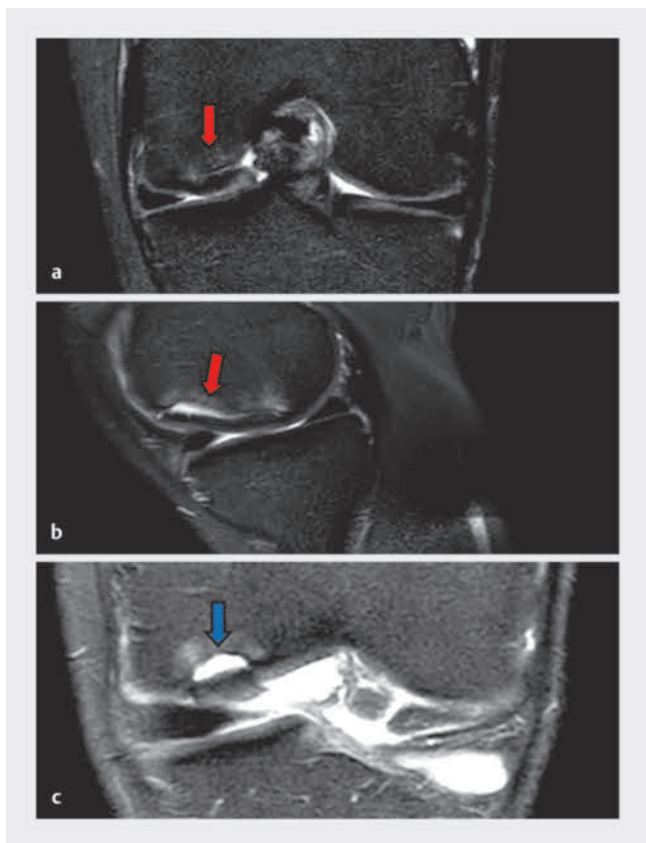
OD is subdivided into juvenile and adult forms. It is classified based on its anatomical location, surgical appearance, MRI findings, and patient age. The juvenile form has a better prognosis than the adult form [1, 6]. The clinical presentation of this pathological condition is unspecific. The majority of patients present a stable chondral lesion and pain in the anterior portion of the knee, which is frequently correlated with physical activity. Sometimes patients may complain about knee instability and may present antalgic gait [7]. With palpation, it is generally possible to detect an area of more intense pain in the lateral part of the medial femoral condyle, although Wilson's sign is not always present. Patients generally present edema and crepitation in the knee [8]. Imaging studies have the aim of characterizing the lesion, monitoring its healing, and determining the prognosis for conservative treatment [9]. MRI is extremely useful for determining the size of the lesion, status of the cartilage, and viability of the subchondral bone. The best treatment for OD of the knee is still debated.

Case Description

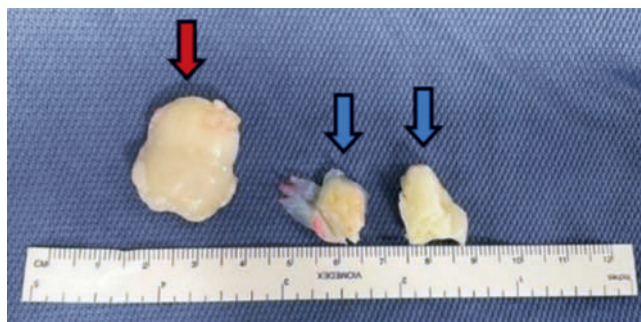
A 21-year-old male complained of pain at the right knee with a catching sensation during active joint motion. Physical examination revealed moderate swelling and a locked right knee at 15° of flexion without any abnormality in the leg's alignment.

MRI showed an area of OD with a bone lesion of 34 × 20 mm in the center of the weight-bearing area of the medial femoral condyle (► Fig. 1 a,b) with bone marrow edema. In addition, two loose bodies were seen (► Fig. 1 c). After talking with the family, we decided to proceed with an arthroscopic treatment.

The arthroscopic examination revealed a 2.8-cm by 2.5-cm displaced osteochondral fragment from the medial femoral condyle and two articular loose bodies: the first one the size of 21 mm length located between the patella and the medial femoral condyle, the second one the size of 10 mm length anterior to the ventral part of the medial femoral condyle. The OD defect was 0.7 cm in depth and contained poor quality scar tissue. It was considered



► **Fig. 1** a OD bone lesion in the MRI T2W fat sat coronal plane (red arrow). b OD bone lesion in the MRI T2W fat sat sagittal plane (red arrow). c One of two loose bodies in the MRI T2W fat sat coronal plane (blue arrow).

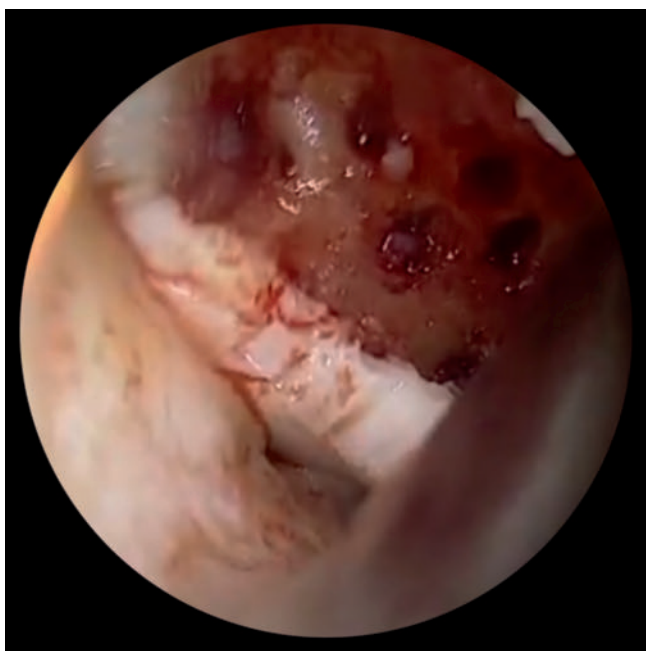

► **Fig. 2** One displaced fragment (red arrow) and two cartilage loose bodies (blue arrows).

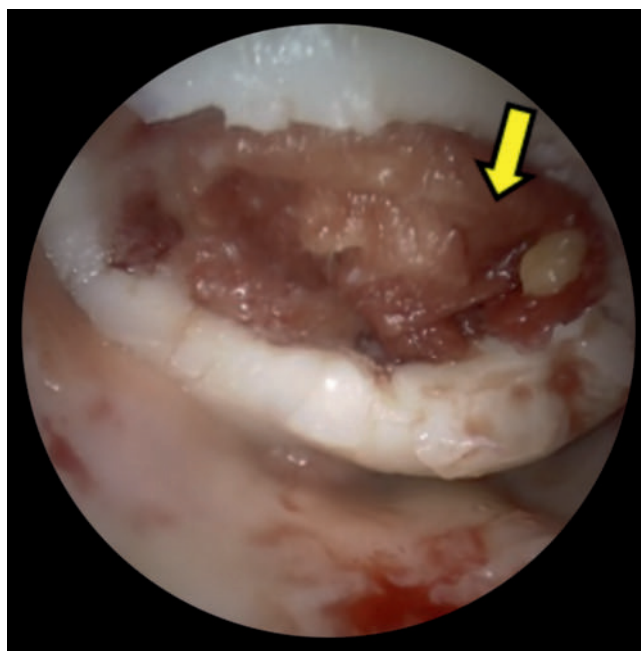that the osteochondral flap had lower potential for healing, so the fragment was simply removed with the two concomitant loose bodies (► **Fig. 2**). A decision was thus made to proceed with repairing the chondral lesion with a microfracture procedure (► **Fig. 3**) and implantation of a 3D hyaluronan-based scaffold (Hyalofast) (► **Fig. 4**).

Weight-bearing was not allowed for 6 weeks and passive and active range of motion exercises were performed during this period. Full weight-bearing was allowed at 2 months.

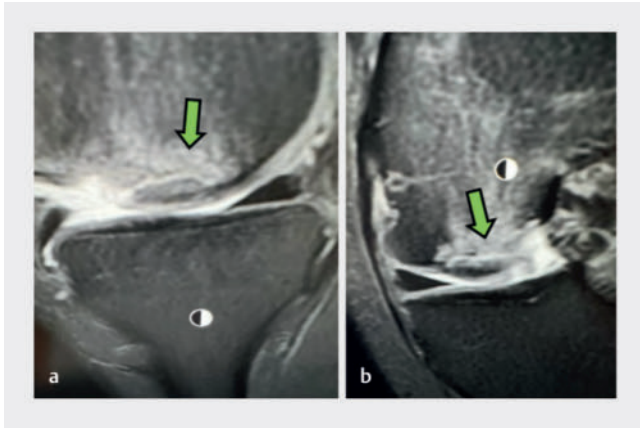
After 3 months from the previous arthroscopic surgery, the same patient returned with painful swelling of his right knee and a locked knee at 20° of flexion lasting for 1 day. A new MRI examination showed a new wide unstable chondral flap originating from the posterior border of the previous OD lesion with a 20-mm transverse diameter × 26-mm anteroposterior diameter (► **Fig. 5**). After a discussion with the patient and his family, we decided to



► **Fig. 3** Subchondral socket of the medial condyle treated with microfractures.



► **Fig. 4** Implantation of a 3D hyaluronic scaffold (yellow arrow).



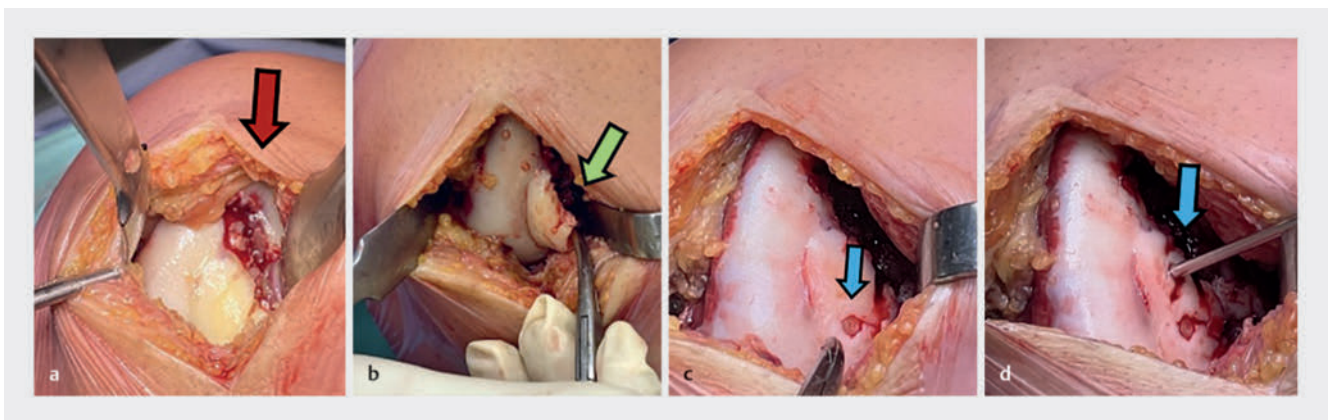
► **Fig. 5** Large cartilage flap near the treated lesion. **a** MRI T2W fat sat sagittal plane (green arrow). **b** MRI T2W fat sat coronal plane (green arrow).

proceed with an open surgery in order to stabilize the large osteochondral fragment.

During the open examination, the previous OD lesion was carefully inspected and seemed to be completely covered by good quality regenerative tissue (► **Fig. 6a**) at the inferior medial part of the healing lesion. A 3 cm² chondral flap, 0.5 cm in depth, detached from the medial femoral condyle was seen (► **Fig. 6b**).

The peripheral margins of the flap were cleaned, and a subchondral crater was curetted to remove fibrous tissue and improve vascularity on the femoral side. After performing this step, in order to restore the bony defect, the cured flap was fixed using bioabsorbable pins (PLLA Chondral Dart, Munich, Germany), three chondral darts, size 18 × 1.3 mm (► **Fig. 6c,d**), and one central bio-compression screw, size 3.0 × 20 mm (Arthrex, Naples, FL, USA).

At the end of surgical procedure, the stability of the fragment fixation was checked both in flexion and extension.



► **Fig. 6** **a** Regenerated tissue healed the cartilage damage (red arrow). **b** Osteochondral flap (green arrow). **c** 1st PLLP pin fixed (light blue arrow). **d** Preparing fixation of 2nd PLLP pin (light blue arrow).

Outcome and Follow-up

The patient was advised non-weight-bearing for 4 weeks, and exercises for range of motion were started the day after surgery. At the 3-month follow-up after the second surgery, the patient presented an excellent functional recovery of the left knee without limitations of range of motion.

The MRI showed early signs of osteointegration and a reduction of the chondral flap, with evidence of the bioabsorbable chondral dart pin still on site, both in the axial coronal plane (► **Fig. 7a,b**) and in the sagittal plane, where the bio-compression screw was also visualized in a good position (► **Fig. 8a,b**). In addition, a reduced reactive synovitis and intra-articular effusion of the knee were found.

Discussion

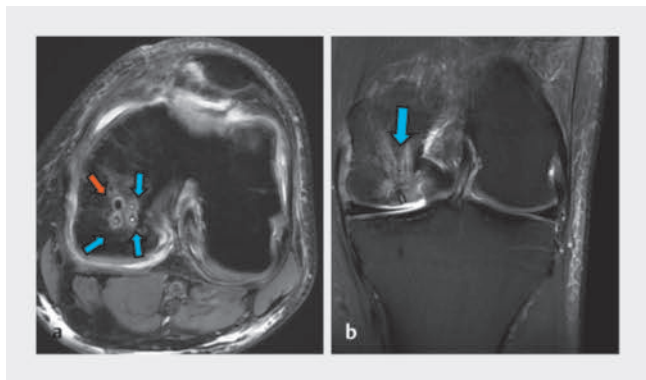
The best treatment for OD of the knee is still debated. Several procedures have been proposed to treat OD lesions, but the gold standard technique remains controversial.

The lack of a standard operative treatment is principally due to a large number of different shapes, sizes, or locations of focal chondral or osteochondral knee lesions from a scientific or routine clinical care point of view. The currently available clinical options complement each other in terms of their indication and have recently been differentiated into those with reparative or restorative properties [10, 11].

Reparative methods (such as bone marrow-stimulating techniques with and without biomaterial augmentation) are characterized by the formation of fibrous cartilage [12, 13, 14, 15], whereas restorative methods such as autologous (OAT) or allogeneic osteochondral transfer (OCA) and autologous chondrocyte implantation (ACI) form cartilage with hyaline properties.

There is increasing evidence from various studies with longer follow-up periods that restorative procedures have better long-term results with lower failure rates [16, 17, 18, 19].

If the preservation of the fragment is not possible, there is a general consensus that the large cartilage defect should be filled with osteochondral autografts or allograft plugs.



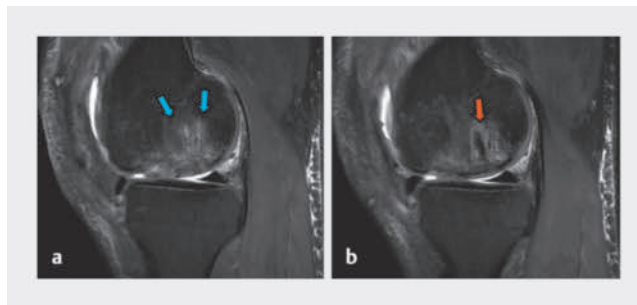
► **Fig. 7** Three chondral dart pins (light blue arrows) and a bio-compression screw (orange arrow) in place in medial femoral condyle flap. **a** MRI T2 W fat sat axial plane. **b** MRI T2 W fat sat coronal plane.

The cell-free hyaluronic acid-based scaffold (HYALOFAST, Bedford, MA, USA) is a bioscaffold that stimulates new cartilage growth and is considered a valid option in treating OD. Hyalofast is a non-woven biodegradable hyaluronic acid-based scaffold for hyaline-like cartilage regeneration. It captures mesenchymal stem cells (MSCs) to heal both chondral and OCL in the knee and ankle. The MSCs secrete paracrine factors, which modulate the immune response of the host, facilitate angiogenesis, improve cell migration and survival, and prevent fibrosis. Once instilled, it keeps supporting MSC attachment, proliferation, and differentiation that will plug the lesion with new cartilage. Studies demonstrated that the treatment of OD with Hyalofast in combination with microfractures showed significant improvement in VAS and AOFAS scores for lesions deeper than 7 mm with no postoperative complications. Further, it was demonstrated that, comparing the arthroscopic treatment of OD with nanofracture alone with the use of Hyalofast, the cartilage quality, clinical, and radiological outcomes were better in the patient treated with the bioscaffold [15, 16].

Regarding the approach, various methods have been used for internal fixation [10, 11, 12] of displaced chondral fragments. Operative treatment includes a variety of techniques, such as the following: arthroscopic drilling, mosaicplasty, arthroplasty through abrasion, microfracture, osteochondral grafts, autologous implantation of chondrocytes, and fixation of fragments [13, 14].

An arthroscopic approach represents the best surgical option in symptomatic individuals with failed conservative treatment or in skeletally immature patients. If the OD lesion was proven to be stable during arthroscopy, the patient may undergo subchondral drilling, which stimulates the formation of fibrocartilage tissue. However, there are some difficulties to assess the real extension of an OD lesion by arthroscopy and sometimes the unstable margins of the lesion may be left untreated.

Although the procedure performed arthroscopically can reduce the risk of persistent ligamentous laxity and reduce open surgery-related morbidity, it has as its main limitation the poor visualization of the more peripheral and hidden margins of the chondral lesion. OD results in tissue alteration through a potentially slow-growing expansive process, therefore MRI images may not document areas that, in reality, are already undergoing pathologic al-



► **Fig. 8** MRI T2 W fat sat sagittal plane. **a** Chondral dart pins in place (light blue arrows). **b** Bio-compression screw in place (orange arrow).

teration. We believe that supra-marginal resection and curettage should be warranted even in the young subject and if this may not be warranted, then the option of open surgery should be considered.

Lesions to the medial femoral condyle could be associated with varus alignment, while lesions to the lateral femoral condyle are seen in patients with valgus malalignment. Common risk factors for failed fixation of OD lesions include unstable lesions to the lateral femoral condyle, screw breakage, older age, and closed physes. Knee realignment defects can be avoided with the proper use of reabsorbable pins; this procedure is made easier and more precise precisely by using an open approach.

In our experience, we preferred to proceed to microfractures and arthroscopic OD repair with a 3 D hyaluronic scaffold at first because we were not able to assess the presence of unstable margins in the remaining portion of medial femoral condyle.

However, in situations where functional recovery does not occur adequately or when areas of osteochondritis are still present due to visualization problems during the first procedure, a revision by open surgery should, in our opinion, be considered.

Open revision surgery allowed us a more accurate assessment of the OD area to provide an effective fixation of the chondral flap and in this case, this should have been done after seeing the first MRI. Finally, the use of a bio-compression screw system (Arthrex, Naples, FL, USA) was effective and resolute for the large flap fixation. In our opinion, the procedure described here should always be performed together in a one-step surgical session to treat large OD lesions, which are too demanding to address arthroscopically.

Conclusion

In treating ODs with unclear margins and the presence of loose bodies through an arthroscopic approach, a 3 D hyaluronic scaffold is the most suitable choice, as the surgical operator is often not able to assess the presence of unstable margins in the remaining portion of medial femoral condyle.

In situations where functional recovery does not occur adequately or areas of osteochondritis are still present due to visualization problems during the first procedure, a revision by open surgery should, in our opinion, be considered. In selected patients with large and unstable chondral lesions, the combination of open fixation and implantation of a hyaluronan-based scaffold may

represent a valid alternative to autologous grafting and should be performed directly with an open surgery approach.

LEARNING POINTS

1. In younger patients with OD, the combination of open fixation and implantation of a hyaluronan-based scaffold may represent a valid alternative to autologous grafting.
2. OD is a common cartilage lesion of the knee with subtle clinical onset.
3. Conservative treatment of OD is recommended if the lesions are stable with no loose bodies or there are open physes. Surgical intervention is currently recommended as the primary treatment in symptomatic adults with unstable chondral lesions or in cases of concomitant loose bodies.

Contributors' Statement

Supervised by MM. Patient was under the care of MM. Report was written by RN, AQ and CT.

Conflict of Interest

The authors declare that they have no conflict of interest.

References

- [1] Aichroth P. Osteochondritis dissecans of the knee: a clinical survey. *J Bone Joint Surg Br* 1971; 53: 440–447. doi:10.1302/0301-620X.53B3.440
- [2] Ribbing S. The hereditary multiple epiphyseal disturbance and its consequences for the aetiology of local malacias: particularly the osteochondrosis dissecans. *Acta Orthop Scand* 1955; 24: 286–299. doi:10.3109/17453675408988571
- [3] Stattin EL, Wiklund F, Lindblom K et al. A missense mutation in the aggreCAN C-type lectin domain disrupts extracellular matrix interactions and causes dominant familial osteochondritis dissecans. *Am J Hum Genet* 2010; 86: 126–137. doi:10.1016/j.ajhg.2009.12.018
- [4] Pick MP. Familial osteochondritis dissecans. *J Bone Joint Surg Br* 1955; 37: 142–145. doi:10.1302/0301-620X.37B1.142
- [5] Petrie PW. Aetiology of osteochondritis dissecans: failure to establish a familial background. *J Bone Joint Surg Br* 1977; 59: 366–367. doi:10.1302/0301-620X.59B3.893517
- [6] Aglietti P, Buzzi R, Bassi PB et al. Arthroscopic drilling in juvenile osteochondritis dissecans of the medial femoral condyle. *Arthroscopy* 1994; 10: 286–291. doi:10.1016/s0749-8063(05)80113-6
- [7] Koch S, Kampen WU, Laprell H. Cartilage and bone morphology in osteochondritis dissecans. *Knee Surg Sports Traumatol Arthrosc* 1997; 5: 42–45. doi:10.1007/s001670050023
- [8] Mubarak SJ, Carroll NC. Familial osteochondritis dissecans of the knee. *Clin Orthop Relat Res* 1979(140): 131–136
- [9] Bohndorf K. Osteochondritis (osteochondrosis) dissecans: a review and new MRI classification. *Eur Radiol* 1998; 8: 103–112. doi:10.1007/s003300050348
- [10] Johnson LL, Uitvlugt G, Austin MD et al. Osteochondritis dissecans of the knee: arthroscopic compression screw fixation. *Arthroscopy* 1990; 6: 179–189. doi:10.1016/0749-8063(90)90073-m
- [11] Lindholm S, Pylkkänen P, Osterman K. Fixation of osteochondral fragments in the knee joint: a clinical survey. *Clin Orthop Relat Res* 1977(126): 256–260
- [12] Marcacci M, Kon E, Zaffagnini S et al. Use of autologous grafts for reconstruction of osteochondral defects of the knee. *Orthopedics* 1999; 22: 595–600. doi:10.3928/0147-7447-19990601-09
- [13] Hinckel BB, Thomas D, Vellios EE et al. Algorithm for Treatment of Focal Cartilage Defects of the Knee: Classic and New Procedures. *Cartilage* 2021; 13 (Suppl 1): 473S–495S. doi:10.1177/1947603521993219
- [14] Richter DL, Schenck RC, jr., Wascher DC et al. Knee Articular Cartilage Repair and Restoration Techniques: A Review of the Literature. *Sports Health* 2016; 8: 153–160. doi:10.1177/1941738115611350
- [15] Tahta M, Akkaya M, Gursoy S et al. Arthroscopic treatment of osteochondral lesions of the talus: nanofracture versus hyaluronic acid-based cell-free scaffold with concentration of autologous bone marrow aspirate. *J Orthop Surg (Hong Kong)* 2017; 25: 2309499017717870. doi:10.1177/2309499017717870
- [16] Yontar NS, Aslan L, Can A et al. One step treatment of talus osteochondral lesions with microfracture and cell free hyaluronic acid based scaffold combination. *Acta Orthop Traumatol Turc* 2019; 53: 372–375. doi:10.1016/j.aott.2019.04.002
- [17] Macmull S, Parratt MT, Bentley G et al. Autologous chondrocyte implantation in the adolescent knee. *Am J Sports Med* 2011; 39: 1723–1730. doi:10.1177/0363546511404202
- [18] Saris DB, Vanlauwe J, Victor J et al. Characterized chondrocyte implantation results in better structural repair when treating symptomatic cartilage defects of the knee in a randomized controlled trial versus microfracture. *Am J Sports Med* 2008; 36: 235–246. doi:10.1177/0363546507311095
- [19] Ogura T, Bryant T, Minas T. Long-term outcomes of autologous chondrocyte implantation in adolescent patients. *Am J Sports Med* 2017; 45: 1066–1074. doi:10.1177/0363546516682492