



# Three-Point Vertical Mattress Suture: A Simple Technique for Mild Blepharoptosis Correction in Partial-Incision Double-Eyelid Surgery

Bo Chen, MD<sup>1</sup> Li Ma, MD<sup>1</sup> Jingyi Wang, MD<sup>2</sup>

<sup>1</sup>Plastic Surgery Department, China-Japan Friendship Hospital, Beijing, China

<sup>2</sup>MAGIC BeauCare Clinic, Beijing, China

Address for correspondence Bo Chen, MD, Plastic Surgery Department, China-Japan Friendship Hospital, NO. 2 Yinghuadong Street, Chaoyang District, Beijing, 100029, China (e-mail: fstf125@163.com).

Facial Plast Surg 2023;39:57–62.

## Abstract

The aim of this study was to introduce a simple technique for mild blepharoptosis correction using a three-point vertical mattress suture in partial-incision double-eyelid surgery. The medical records and preoperative and postoperative images of 57 patients who underwent simultaneous mild blepharoptosis correction and partial-incision double-eyelid surgery from January 2018 to July 2021 were retrospectively reviewed. The surgical procedure mainly involves three small incisions in the proper eyelid crease, levator aponeurosis exposure by conservative dissection, and three-point vertical mattress suture to plicate levator aponeurosis and fix the orbicularis muscle with the plicated levator aponeurosis. All patients underwent bilateral partial-incision double-eyelid surgery: 10 unilateral and 47 bilateral blepharoptosis corrective surgeries. The average age was  $25.3 \pm 7.4$  years. The mean operative and follow-up duration were 50 minutes and 13 months, respectively. The pre- and postoperative mean marginal reflex distance was  $3.04 \pm 0.27$  and  $3.75 \pm 0.35$  mm, respectively. The overall surgical success rate was 93%. Complications including undercorrection (5.3%), asymmetry (7.0%), and double-eyelid crease disappearance (5.3%) were reported. Three-point vertical mattress suture is considered an effective, safe, and simple technique for mild blepharoptosis correction in partial-incision double-eyelid surgery.

## Keywords

- ▶ blepharoptosis
- ▶ double-eyelid surgery
- ▶ partial incision
- ▶ vertical mattress suture
- ▶ marginal reflex distance

The partial-incision double-eyelid surgery has become a popular aesthetic surgical procedure among East Asians because of its advantages, such as creating a more durable fold, less visible scar, and shorter postoperative recovery time.<sup>1</sup> The incidence of blepharoptosis is much higher in East Asians than in other areas worldwide because of their distinctive eyelid anatomy. However, patients who want to undergo double-eyelid surgery frequently have mild blepharoptosis.<sup>2–4</sup>

Due to high clinical demands, some surgical techniques have been used to correct blepharoptosis and create double-eyelid creases simultaneously.<sup>4</sup> However, these techniques are somewhat complex and require a long learning curve, which is not conducive to clinical popularization. Here, we introduce a simple technique for mild blepharoptosis correction with a three-point vertical mattress suture in partial-incision double-eyelid surgery.

accepted manuscript online  
November 16, 2022

Issue Theme Lower Eyelid  
Blepharoplasty – Reducing  
Complications; Guest Editor:  
Callum Faris, MBBS

DOI <https://doi.org/10.1055/a-1980-8755>.  
ISSN 0736-6825.

© 2023. The Author(s).

This is an open access article published by Thieme under the terms of the Creative Commons Attribution-NonDerivative-NonCommercial-License, permitting copying and reproduction so long as the original work is given appropriate credit. Contents may not be used for commercial purposes, or adapted, remixed, transformed or built upon. (<https://creativecommons.org/licenses/by-nc-nd/4.0/>)

Thieme Medical Publishers, Inc., 333 Seventh Avenue, 18th Floor, New York, NY 10001, USA

## Materials and Methods

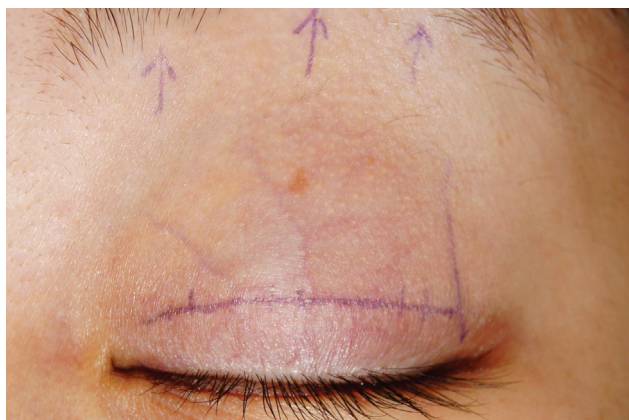The medical records and preoperative and postoperative images of 57 patients who underwent simultaneous mild blepharoptosis correction and partial-incision double-eyelid surgery from January 2018 to July 2021 in the Plastic Surgery Department of the China-Japan Friendship Hospital and MAG-IC BeauCare Clinic were retrospectively reviewed. All patients had mild blepharoptosis with good levator function ( $LF > 10$  mm). The procedures conformed to the ethical guidelines of the Declaration of Helsinki and clinical practice guidelines from the ethical committee of the hospital and clinic. All participants were fully informed about the treatment protocol and potential risks, and signed informed consent and photo release forms were obtained preoperatively.

All medical records were reviewed, and demographic data, including age and sex, examination findings, and measurements (including preoperative marginal reflex distance [MRD1]), were collected. Postoperative information such as postoperative MRD1, follow-up period, and complications was also collected. All pre- and postoperative images were obtained.

A paired *t*-test was used to analyze MRD1 changes pre- and postoperatively. A value of *p* less than 0.05 was considered to indicate a statistically significant difference.

Preoperatively, the patient was instructed to remain in an upright sitting position, and the upper lid was retracted upward until incipient eyelash eversion was observed. The proper lid crease was designed as the superior border of the tarsal plate, and a dot was placed at the central aspect of the proposed crease line. A line was marked at the supine position, and a typical height of approximately 8 to 10 mm was measured when the eyelid was retracted upward. Three small incisions corresponding to the pupil, the middle of the lateral limbus and outer canthus angle, and the middle of the medial limbus and inner canthus angle of approximately 2 mm in length were made and marked at the crease line (►Fig. 1). The lid creases and incisions were confirmed several times preoperatively to confirm bilateral symmetry.

Surgical procedures were performed under local anesthesia. A solution containing 1% lidocaine and 0.5% bupivacaine



**Fig. 1** A proper lid crease was designed as the superior border of the tarsal plate when the upper lid was retracted upward.

with 1:100,000 epinephrine was infiltrated subcutaneously below the marked incisions. Only 0.05 mL was used to minimize edema for each incision and ensure symmetrical evaluation of the crease height intraoperatively. A 10-minute duration was given to permit maximal hemostasis and anesthesia, and three skin incisions were created using a no. 11 blade. Through small incisions, the orbicularis muscle was dissected with small ophthalmic scissors in a spreading manner under the deep orbicularis muscle layer. Dissection was performed in an upward direction from the superior border of the tarsal plate, followed by preaponeurotic fat pad identification and levator aponeurosis exposure of approximately 5 mm higher than the superior border of the tarsal plate (not higher than the musculoaponeurotic junction level) (►Fig. 2). In patients with puffy eyelids, the orbital septum was locally opened, and the central preaponeurotic fat was selectively removed via the small incision in the temporal region (►Fig. 3).

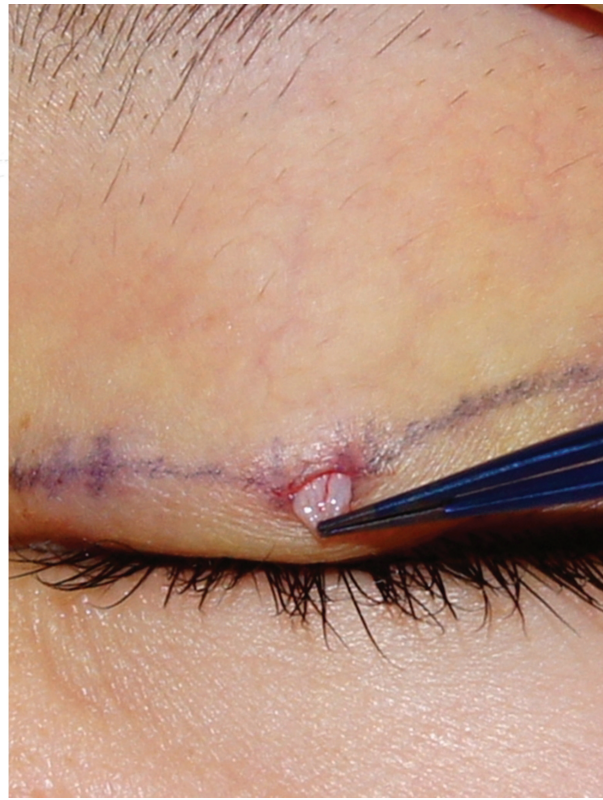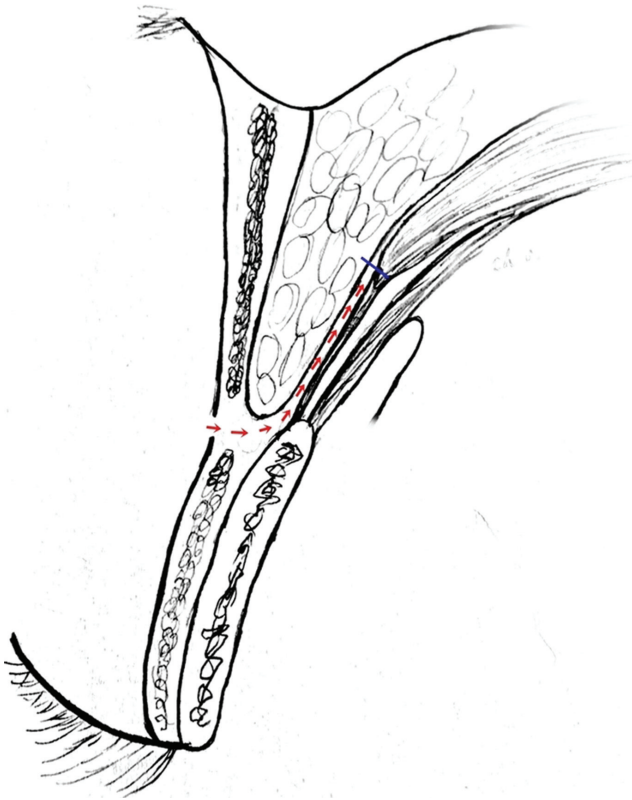
A three-point vertical mattress suture was then used with 7-0 nylon with three suture points, including the orbicularis muscle under the inferior skin edge, levator aponeurosis at the superior border of the tarsal plate, and levator aponeurosis at the proper height (~3–5 mm higher than the superior border of the tarsal plate) below the musculoaponeurotic junction at the center of the small incision (►Fig. 4). This three-point vertical mattress suture had several functions: first, the levator aponeurosis was pliated to correct mild blepharoptosis; second, the levator aponeurosis and orbicularis muscle were fixed to create a double-eyelid crease; and third, the eyelashes were everted to correct lash ptosis.

The suture was tied with a surgeon's knot, and a slip knot is placed over the surgeon's knot. Then, the patient was asked to sit up and open his or her eyes. The eyelid height and contour and the lid crease height were confirmed as favorable indicators before completely securing the suture with additional knots (►Fig. 4). If the eyelid height and contour and the lid crease height or symmetry remain unsatisfactory after suturing, repositioning the suture site was adjusted in the levator aponeurosis. After the suture was tied down, suture tails were trimmed, and the suture was buried beneath the skin. Small skin incisions involving levator aponeurosis were closed using 7-0 nylon sutures to strengthen the double-eyelid crease. These skin sutures were removed on postoperative day 7, and three-point vertical mattress sutures remained beneath the skin permanently.

## Results

A total of 57 patients underwent surgery from January 2018 to July 2021. All patients underwent bilateral partial-incision double-eyelid surgery: 10 unilateral and 47 bilateral blepharoptosis corrective surgeries. Patients' average age was  $25.3 \pm 7.4$  (range: 18–38) years. The mean operative and follow-up time was 50 (range: 36–71) minutes and 13 (range 3–35) months, respectively.

The pre- and postoperative mean MRD1s were  $3.04 \pm 0.27$  mm and  $3.75 \pm 0.35$  mm, respectively. A statistically significant improvement was observed between pre- and



**Fig. 2** Dissection was performed in an upward direction from the superior border of the tarsal plate, and the levator aponeurosis was exposed.

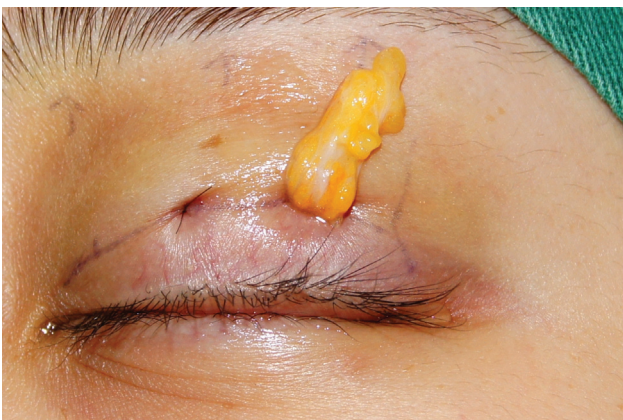postoperative MRD1 values ( $p < 0.01$ ). The overall surgical success rate was 93%. Undercorrection was noted in three patients (5.3%), asymmetry in four patients (7.0%), and double-eyelid crease disappearance in three patients (5.3%). The three patients with undercorrection (two also had double-eyelid crease disappearance) were corrected by widening the small incisions slightly and placing double same three-point vertical mattress suture in widened small incisions. One patient with double-eyelid crease disappearance was satisfied with the correction of blepharoptosis and did not undergo double-eyelid surgery again. No severe postoperative complications such as lid retraction, lagophthalmos, corneal keratopathy,

infection, hypertrophic scarring, or persistent edema were observed during the follow-up period (► **Fig. 5** and ► **Fig. 6**).

## Discussion

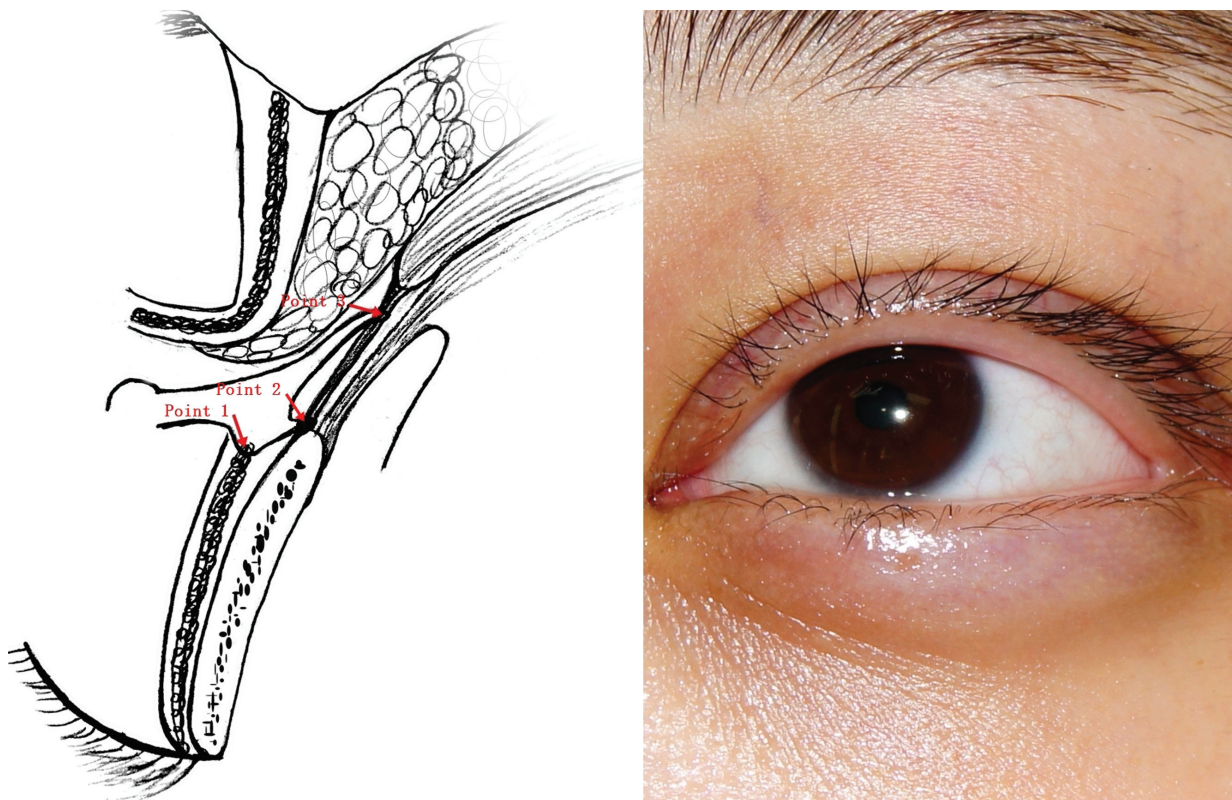
Small-incision blepharoptosis correction surgery became well known since its introduction by Lucarelli and Lemke.<sup>5</sup> Recently, a central minimal incision levator resection was used to correct blepharoptosis in two main areas: for reducing the incision size and for reducing the dissection and resection. The advantages of this technique include minimal tissue damage, bleeding, and edema, allowing a faster wound healing and recovery and more accurate intraoperative assessment of the eyelid position and a shorter operation time and less scarring, facilitating further dissection if reoperation was indicated in case of unsatisfactory results.<sup>6–11</sup>

The creation of a proper and persistent double-eyelid crease is considered the primary and important step during blepharoptosis surgery in East Asian patients.<sup>12</sup> For the central small incisional procedure, the fixation of the double-eyelid crease is limited toward the center, and the double-eyelid crease is not fully established in the medial and lateral parts of fuller East Asian upper eyelids, causing lateral eyelid hooding and double-eyelid crease asymmetry.<sup>13,14</sup> Lee et al<sup>4</sup> presented a surgical technique to correct mild or moderate blepharoptosis with levator aponeurosis–Müller muscle complex advancement through three partial incisions, the levator aponeurosis–Müller muscle complex, and the upper border of the tarsal plate, which were fixed using the horizontal mattress suture technique and double-

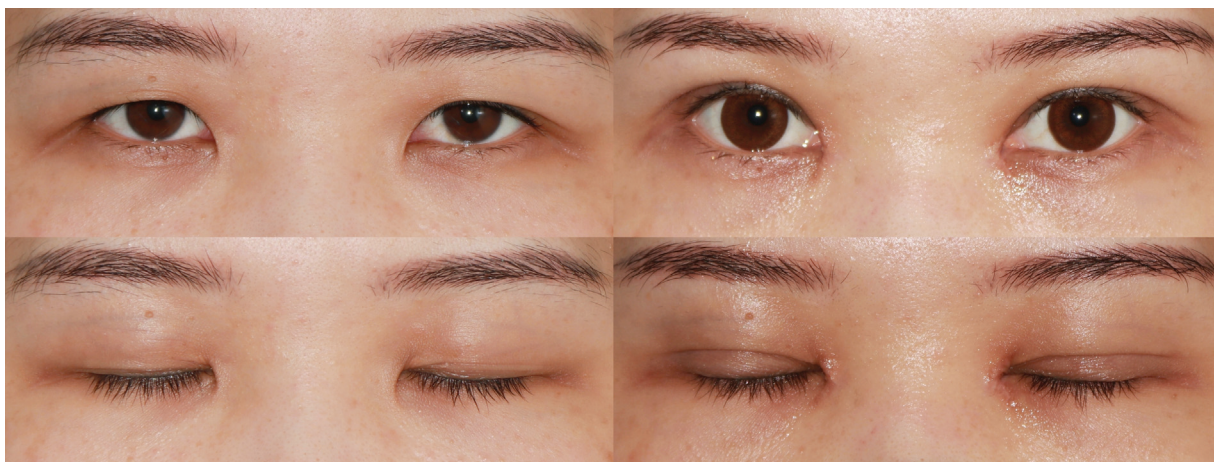

**Fig. 3** The central preaponeurotic fat was exposed and selectively removed through a small incision temporarily.





**Fig. 4** The plication fixation suture was implemented, and the eyelid height and contour, the lid crease height, and the eyelash eversion were confirmed.



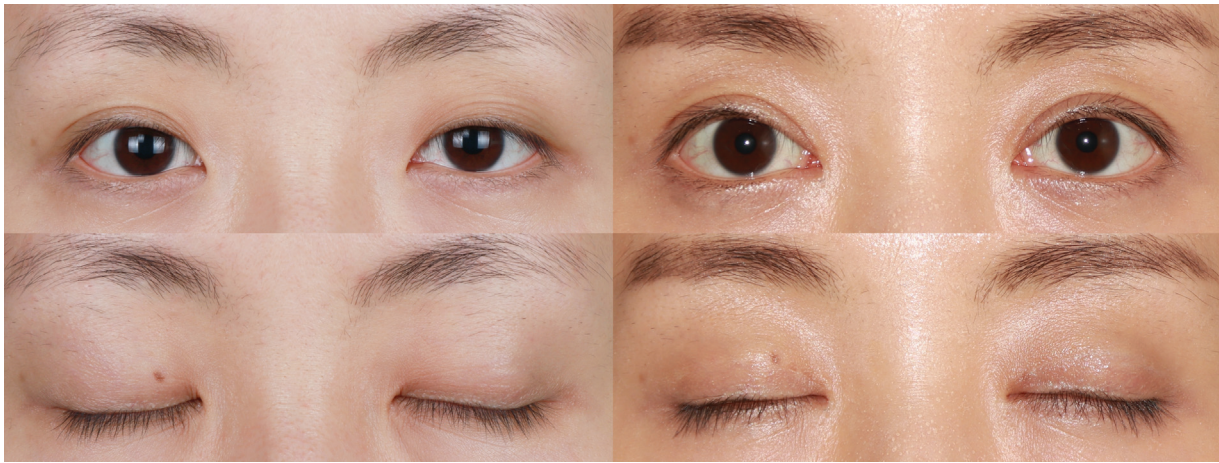
**Fig. 5** A 22-year-old woman underwent bilateral simultaneous blepharoptosis correction, partial-incision double-eyelid surgery, and medial epicanthoplasty, with a ptosis correction of 2 mm on both sides. Preoperative view of the opened and closed eyes. Postoperative view of opened and closed eyes at 2 months.

eyelid crease was performed with additional suturing of the orbicularis muscle. However, these techniques are somewhat complex and require a long learning curve, which is not conducive to clinical popularization.

In our study, three skin incisions were created the same as the traditional three small-incision double-eyelid blepharoplasties, and dissection of the levator aponeurosis was just a little larger than traditional three small-incision double-eyelid blepharoplasties and very easy to perform; the three-point vertical mattress suture was also very simple.

Due to the simplicity of our technique, our operative time was relatively short. Because of these characteristics, namely minimally invasive, easy to perform, and short operation time, our technology have certain comparative advantages.

The three points, namely the orbicularis muscle under the inferior skin edge, levator aponeurosis at the superior border of the tarsal plate, and levator aponeurosis at the proper height (~3–5 mm higher than the superior border of the tarsal plate), were fixed together using the vertical mattress suture in our surgery. This procedure not only can correct



**Fig. 6** A 26-year-old woman underwent bilateral simultaneous blepharoptosis correction and partial-incision double-eyelid surgery, with a ptosis correction of 2 mm on the left side and 1.5 mm on the right side. Preoperative view of opened and closed eyes. Postoperative view of opened and closed eyes at 6 months.

mild blepharoptosis but also can produce a persistent adhesion between the orbicularis muscle and levator aponeurosis to maintain a stable double-eyelid crease, and the disappearance or deformity of the double-eyelid crease after this technique was only observed in four patients, indicating that our technique is suitable for East Asian patients.

Ranno et al<sup>15</sup> have evaluated the outcomes of standard incision levator advancement with a small-incision technique, which showed success rates of 95.2% and 94.7% with standard and small incision methods in patients with good LF (>10 mm). The technique presented by Lee et al<sup>4</sup> shows excellent results in 83.8% and good results in 14.9% of patients. In our study, success rates were 93%, a finding slightly inferior to Ranno et al's and Lee et al's studies. We think the reason may be the small incision, insufficient dissection, and unresected hypertrophic fascial tissue in front of the levator aponeurosis and tarsal plate, resulting in aponeurosis not sufficiently and accurately plicated during suture. This deficiency can be addressed by slightly widening small incisions and placing double the same three-point vertical mattress suture in the widened small incisions.

Makeeva et al<sup>16</sup> found that a 4-mm advancement resulted in an average MRD1 increase of 2.26 mm and a 5-mm advancement resulted in an average MRD1 increase of 2.74 mm. Alkswani et al<sup>17</sup> found that a 4-mm average advancement led to an average of 2.2 mm increase in MRD1, whereas a 5-mm advancement led to an average increase of 2.9 mm. These studies suggested that a consistent relationship between the levator advancement distance and improvement in MRD1 measurement can be used to plan the amount of advancement required to elevate the eyelid. In our study, a successful operation was confirmed by the eyelid height and contour and lid crease height when the patient was in an upright sitting position rather than the levator advancement distance.

However, our technique has some disadvantages, i.e., the small incision, minimized surgical dissection, and limited exposure to the complete correction of blepharoptosis. Thus,

this technique is not considered suitable for severe blepharoptosis with poor LF.

Our study has several limitations. First, this study included a retrospective design, and thereby, prospective, randomized studies comparing our technique with the usual small incisional approaches and independent evaluation by blinded observers were considered better for assessing surgical success. Second, the small sample size allowed only a weak statistical power. Third, the overall follow-up period was short to confirm the effects in the long run. Finally, all measurements and evaluations were performed by one of the authors who is also the operator. Thus, recordings by an independent investigator should be conducted to reduce the risk of measurement bias.

In summary, we think that the three-point vertical mattress suture is an effective, safe, and simple technique for mild blepharoptosis correction in partial-incision double-eyelid surgery.

#### Conflict of Interest

None declared.

#### Acknowledgment

None.

#### References

- Zhang MY, Yang H, Li CY, Du FY, Huang XJ, Tan WQ. Removal of a large amount of pretarsal tissue through three mini incisions in the construction of a double eyelid. *Aesthetic Plast Surg* 2012;36(05):1039–1046
- Suhk JH, Kiranantawat K, Nguyen AH. Physical evaluation of the Asian blepharoplasty patient. *Semin Plast Surg* 2015;29(03):145–157
- Saonanon P. Update on Asian eyelid anatomy and clinical relevance. *Curr Opin Ophthalmol* 2014;25(05):436–442
- Lee JH, Nam SM, Kim YB. Blepharoptosis correction: levator aponeurosis-Müller muscle complex advancement with three partial incisions. *Plast Reconstr Surg* 2015;135(02):388–395
- Lucarelli MJ, Lemke BN. Small incision external levator repair: technique and early results. *Am J Ophthalmol* 1999;127(06):637–644

- 6 Frueh BR, Musch DC, McDonald HM. Efficacy and efficiency of a small-incision, minimal dissection procedure versus a traditional approach for correcting aponeurotic ptosis. *Ophthalmology* 2004;111(12):2158–2163
- 7 Baroody M, Holds JB, Sakamoto DK, Vick VL, Hartstein ME. Small incision transcutaneous levator aponeurotic repair for blepharoptosis. *Ann Plast Surg* 2004;52(06):558–561
- 8 Eshraghi B, Ghadimi H. Small-incision levator resection for correction of congenital ptosis: a prospective study. *Graefes Arch Clin Exp Ophthalmol* 2018;256(09):1747–1750
- 9 Ahuero AE, Winn BJ, Sires BS. Standardized suture placement for mini-invasive ptosis surgery. *Arch Facial Plast Surg* 2012;14(06):408–412
- 10 Bernardini FP, de Conciliis C, Devoto MH. Mini-invasive ptosis surgery. *Orbit* 2006;25(02):111–115
- 11 Elabjer BK, Busić M, Elabjer E, Bosnar D, Sekelj S, Krstonjević EK. Microincision aponeurotic ptosis surgery of upper lid. *Coll Antropol* 2009;33(03):915–918
- 12 Lee CK, Ahn ST, Kim N. Asian upper lid blepharoplasty surgery. *Clin Plast Surg* 2013;40(01):167–178
- 13 Bellinva G, Klinger F, Maione L, Bellinva P. Upper lid blepharoplasty, eyebrow ptosis, and lateral hooding. *Aesthet Surg J* 2013;33(01):24–30
- 14 Matsuda H, Shiba T, Takahashi Y, Tsuneoka H. Transcutaneous aponeurotic repair with small detachment of the levator aponeurosis for aponeurotic blepharoptosis in Japanese patients. *J Plast Reconstr Aesthet Surg* 2018;71(03):425–430
- 15 Ranno S, Sacchi M, Gonzalez MO, Ravula MT, Nucci P. Evaluation of levator function for efficacy of minimally invasive and standard techniques for involutional ptosis. *Am J Ophthalmol* 2014;157(01):209–213.e1
- 16 Makeeva V, Collawn SS, Pierce EN, et al. Numerical correlation of levator advancement in preoperative planning. *Ann Plast Surg* 2017;78(6S, Suppl 5):S279–S281
- 17 Alkeswani A, Hataway F, Westbrook B, Gulamani S, Collawn SS. Changes in lid crease measurements in levator advancement for ptosis. *Ann Plast Surg* 2020;84(6S, Suppl 5):S358–S360