

Comparison of Intraocular Tamponade in Patients with Peripheral Tear-Induced Retinal Detachment and Coexisting Macular Hole without High Myopia

Vergleich der intraokularen Tamponade bei Patienten mit peripheren Netzhautlöchern und Netzhautablösung mit gleichzeitig bestehendem Makulaforamen ohne hohe Myopie

Authors

Yücel Ozturk¹, Abdullah Ağın², Aysun Yücel Gencoglu¹, Mustafa Talan³, Muhammed Nurullah Bulut³

Affiliations

- 1 Ophthalmology, Haydarpaşa Numune Training and Research Hospital, Istanbul, Turkey
- 2 Ophthalmology, Haseki Education Research Hospital, Haseki Fatih, Istanbul, Turkey
- 3 Ophthalmology, Kartal City Hospital, Istanbul, Turkey

Key words

internal limiting membrane, rhegmatogenous retinal detachment, vitrectomy, macular hole

Schlüsselwörter

Vitrektomie, rhegmatogene Netzhautablösung, innere Grenzmembran, Makulaforamen

received 15. 8. 2022
accepted 27. 10. 2022
published online 12. 1. 2023

Bibliography

Klin Monatsbl Augenheilkd 2023; 240: 897–902

DOI 10.1055/a-1969-0310

ISSN 0023-2165

© 2023, Thieme. All rights reserved.

Georg Thieme Verlag KG, Rüdigerstraße 14,
70469 Stuttgart, Germany

Correspondence

Dr. Abdullah Ağın
Ophthalmology, Haseki Education Research Hospital
Adnan Adivar St, Haseki Fatih, 34265 Istanbul, Turkey
Phone: + 90 21 25 29 44 00, Fax: + 90 21 25 89 62 29
abdullahagin@gmail.com

ABSTRACT

Introduction To introduce the surgical results and examine the effect of intraocular tamponades on surgical outcomes in patients with coexisting macular hole (MH) and rhegmatogenous retinal detachment (RRD) without high myopia.

Methods This retrospective, cross-sectional, two-center study was carried out with 29 eyes of 29 patients. The patients were divided into two groups according to the intraocular tamponade used in surgery: silicone oil (Group 1) and C₃F₈ gas (Group 2). In all patients, the internal limiting membrane was peeled during surgery. Exclusion criteria were determined as RRD with MH due to high myopia (≥ 6 D) without peripheral retinal tears and traumatic MH.

Results In Group 1, the median preoperative best-corrected visual acuity (BCVA) was 3.0 (M \pm SD: 2.85 \pm 0.27) logMAR, while the median postoperative BCVA was 1.0 (M \pm SD: 1.39 \pm 0.83) logMAR ($p < 0.001$). In Group 2, the median preoperative BCVA was 3.0 (M \pm SD: 2.37 \pm 0.93) logMAR, while the median postoperative BCVA was 0.76 (M \pm SD: 1.06 \pm 0.86) logMAR ($p = 0.008$). The retinal attachment success rate was 15/17 (89.3%) in Group 1, and 11/12 (91.7%) in Group 2 ($p = 0.64$). The MH closure rate was 12/17 (71.6%) in Group 1, and 10/12 (78.1%) in Group 2 ($p = 0.52$). No difference was determined between the groups in terms of preoperative and postoperative BCVA, preoperative and postoperative intraocular pressure, and BCVA improvement.

Conclusions The study results showed no significant difference between using silicone oil or C₃F₈ gas as an intraocular tamponade after internal limiting membrane peeling in patients with RRD due to peripheral tear with coexisting MH.

ZUSAMMENFASSUNG

Einführung Vorstellung der Operationsergebnisse und Untersuchung der Wirkung von intraokularen Tamponaden auf die Operationsergebnisse bei Patienten mit Makulaforamen (MH) und rhegmatogener Netzhautablösung (RRD) ohne hohe Myopie.

Methoden Diese retrospektive Querschnittsstudie wurde an 2 Zentren mit 29 Augen von 29 Patienten durchgeführt. Die Patienten wurden entsprechend der bei der Operation verwendeten intraokularen Tamponade in 2 Gruppen eingeteilt: Silikonöl (Gruppe 1) und C₃F₈-Gas (Gruppe 2). Bei allen Patienten wurde die innere Grenzmembran während der Opera-

tion gepeelt. Ausschlusskriterien waren RRD aufgrund MH ohne periphere Netzhautrisse bei hoher Myopie (≥ 6 dpt) und traumatisches MH.

Ergebnisse In Gruppe 1 betrug der präoperative bestkorrigierte Visus (BCVA) 3,0 ($M \pm SD$: 2.85 ± 0.27) logMAR, während der postoperative BCVA 1,0 logMAR ($M \pm SD$: 1.39 ± 0.83) betrug ($p < 0.001$). In Gruppe 2 betrug die präoperative BCVA 3,0 ($M \pm SD$: 2.37 ± 0.93) logMAR, die postoperative BCVA betrug 0,76 ($M \pm SD$: 1.06 ± 0.86) logMAR ($p = 0.008$). Die Erfolgsrate der primären Nertzhautanlage lag bei 15/17 (89.3%) in Gruppe 1, 11/12 (91.7%) in Gruppe 2 ($p = 0.64$).

Die MH-Verschlussrate erreichte 12/17 (71.6%) in Gruppe 1, 10/12 (78.1%) in Gruppe 2 ($p = 0.52$). Es zeigte sich kein Unterschied in Bezug auf präoperative und postoperative BCVA, präoperativen und postoperativen Augeninnendruck, BCVA-Verbesserung zwischen den beiden Gruppen.

Schlussfolgerungen Unsere Ergebnisse zeigen keinen signifikanten Unterschied zwischen der Verwendung von Silikonöl oder C_3F_8 -Gas als intraokulare Tamponade nach einem Peeling der inneren Grenzmembran bei Patienten mit RRD aufgrund von peripherem Netzhautlöcher und gleichzeitig vorhandenem MH.

Introduction

A macular hole (MH) is an anatomical opening in the central fovea. It is a treatable cause of central vision loss, more common in older adults, and may occur secondary to myopia and trauma [1–5].

MH accompanying rhegmatogenous retinal detachment (MHRD) is a challenging condition, with a prevalence varying from 2 to 8% [6, 7]. Even though the pathogenesis of MH in MHRD is different from other common causes of MH such as pathological myopia and trauma, the formation mechanism of MH has not been fully elucidated in these cases. MHRD may result from posterior vitreous detachment, leading to peripheral tears. Another proposed hypothesis is related to tangential retraction of the macula, which occurs in conditions such as vitreoretinal interface abnormalities or proliferative vitreoretinopathy [6–9].

Pars plana vitrectomy (PPV) is one of the standard treatments for MHRD. Tamponade is necessary to reduce the fluid flow rate from open retinal tears that will cause recurrent rhegmatogenous retinal detachment (RRD). The main buffering agents currently available are various gases and silicone oils. Gases include air, sulfur hexafluoride (SF_6), hexafluoroethane (C_2F_6), and perfluoropropane (C_3F_8). The most significant advantage of gas tamponade is that the gas usually dissipates spontaneously within a few weeks. Especially in eyes with proliferative vitreoretinopathy, the permanent tamponade effect of silicone is a disadvantage for use [10].

However, in addition to the complexity of the formation mechanism of MHRD, surgical management is also a challenging process. Trials and debates are still ongoing regarding whether to perform internal limiting membrane (ILM) peeling, combining scleral buckling with PPV, and using an exogenous extraocular tissue such as the amniotic membrane lens capsular flap to close the hole [11, 12].

Although there are many different studies on this subject in the literature, the effect of tamponade has not been evaluated. The aim of this study was to report the surgical outcomes and observations of how intraocular tamponade affects the anatomic and functional results of these complex cases.

Materials and Methods

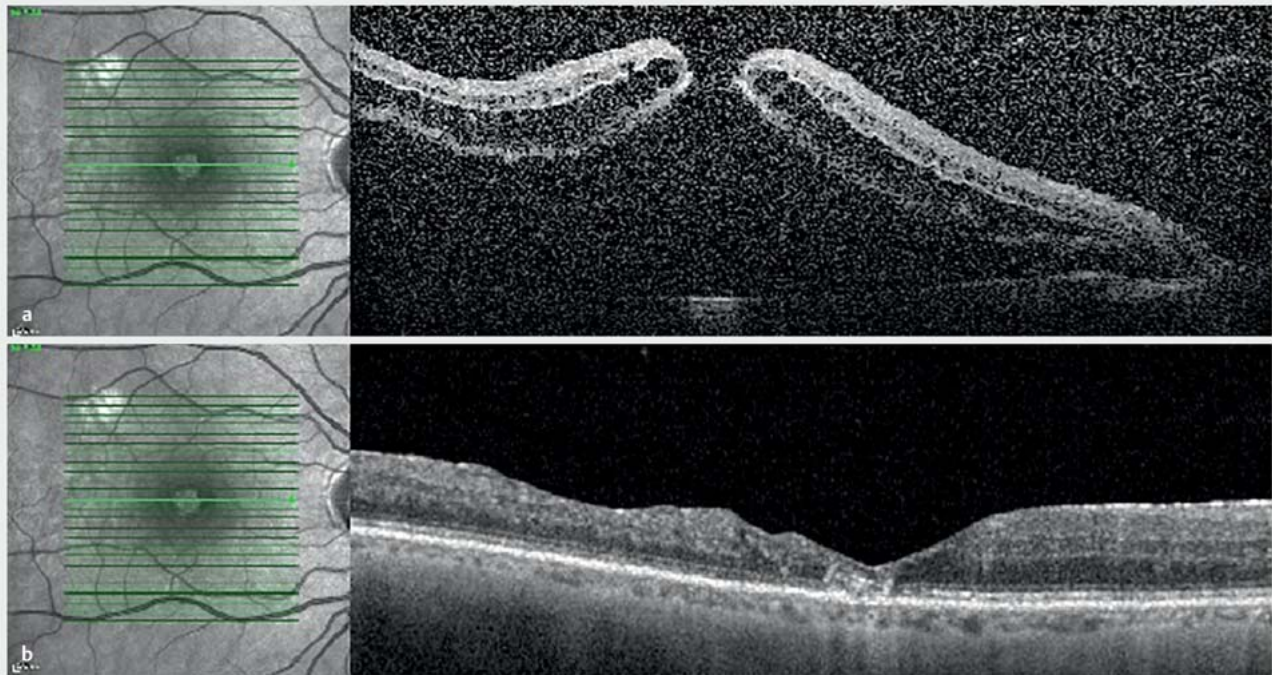
This retrospective, cross-sectional, two-center case study included 29 eyes of 29 patients with MHRD who underwent 23-gauge PPV in the eye clinics of two tertiary-level university

hospitals between 2016 and 2021. The patients included were those with an MH that was noted preoperatively, or which was detected during PPV to repair RRD. Some patients had prolapsed RRD or media issues that obstructed the preoperative view of the macula. Patients with at least one tear in the peripheral retina in addition to the MH were included. The study exclusion criteria were defined as patients with high myopic MHs with associated retinal detachment without peripheral retinal breakage, diabetic retinopathy, trauma, or underlying hereditary or systemic diseases. An example case is shown in ► **Fig. 1**. High myopia is defined as near-sightedness of ≥ -6.00 diopters or axial length > 26.5 mm.

Patients diagnosed with RRD underwent a detailed examination. If MH was detected preoperatively, it was noted. Relevant clinical and surgical history information was collected. Best-corrected visual acuity (BCVA), measured on the Snellen eye chart, was recorded before surgery and at the final follow-up visit and these values were converted to logarithms of minimum angle resolution (logMAR) acuities. All patients in the study underwent a comprehensive ophthalmological examination, including slit lamp biomicroscopy, dilated fundus examination, and spectral-domain optical coherence tomography (OCT) (Heidelberg Spectralis, Heidelberg Engineering, Dossenheim, Germany and OCT-SLO, Optos, Dunfermline, UK). The full thickness MH was defined using the OCT criteria in the International Vitreomacular Traction Study [13]. The study was approved by the Haydarpasa Numune Training and Research Hospital, Clinical Research Ethics Committee (2021/216–3405), and all procedures complied with the principles of the Declaration of Helsinki. Informed consent was waived due to the retrospective nature of this study.

After surgery, the patients were divided into two groups according to the type of tamponade used. Patients using silicone oil were classified as Group 1, and patients using C_3F_8 gas as Group 2. Retinal attachment was defined as complete absorption of the subretinal fluid and complete attachment of the neurosensory retina to the retinal pigment epithelium. Successful MH closure was defined as the absence of neurosensory defects over the fovea on OCT images (type 1 closure).

Data collected included preoperative BCVA, MH closure, intraocular tamponade, and postoperative BCVA. The anatomic condition of both the peripheral retina and the macula was documented postoperatively.



► **Fig. 1** Preoperative OCT image of a patient with retinal detachment and macular hole (a). OCT image of the same patient after silicone oil removal (b).

Surgery was performed using a standard 3-port, 23-gauge PPV by two surgeons (Y.O, M.N.B.). Combined phaco-PPV was performed in the presence of a cataract. The primary intent in all patients was to repair the RRD, but an attempt was also made to repair the MH. Trocar cannulas of 23 g were placed 3.5 mm behind the limbus. All patients underwent PPV and ILM peeling surgery. Intraoperatively, posterior hyaloid was completely separated from the retina after core vitrectomy. Liquid perfluorocarbon was injected to facilitate subretinal fluid drainage and safer peeling of the ILM. Brilliant blue injection was applied to visualize the ILM in the macular region, and it was then peeled off. PVR (proliferative vitreoretinopathy) membranes were also peeled if present. Vitreous base cleanup was carefully completed. Fluid-air exchange was performed, and then following retinal reattachment, endolaser was performed around the peripheral tears. The air in the vitreous cavity was replaced with 16% C₃F₈ or 1000 centistokes silicone oil. Patients were advised to stay prone for 1 week after the surgery. The decision of postoperative tamponade was made according to the clinical presentation of retinal detachment (RD). Silicone was preferred in patients with RD or a break in the inferior quadrants, or RD due to a giant retinal tear, and PVR gas was preferred if the break or RD area was localized superiorly, or the detachment was shallow.

The study data were analyzed using SPSS, version 22.0, software (SPSS, Inc., Chicago, IL, USA). Data distribution was analyzed with the Shapiro-Wilk test. Demographic variables are expressed as count and percentage, whereas continuous variables are expressed as a median value. In the comparisons of median values,

the Mann-Whitney U test was used. Changes in values from baseline to final follow-up were analyzed using the Wilcoxon signed-rank test. Differences between the groups were compared with Fisher's exact test. A value of $p < 0.05$ was considered statistically significant.

Results

Evaluation was made of 29 eyes of 29 patients with a median age of 61.6 years (range 33–80 years), in a male/female ratio of 18:11. The average follow-up was 9 months (range: 3–17 months). Silicone oil was used as a tamponade in 17 (58.6%) patients, and C₃F₈ was used in 12 (41.4%; ► **Table 1**). RRD surgery was successful in 26 (89.7%) eyes and unsuccessful in 3 (10.3%) eyes (► **Table 2**). The MH was closed in 22 (75.9%) eyes and not closed in 7 (24.1%) eyes. In the assessments of the groups, retinal attachment showed a success rate of 15/17 (89.3%) in Group 1, and 11/12 (91.7%) in Group 2 ($p = 0.64$). The MH closure rate was 12/17 (71.6%) in Group 1, and 10/12 (78.1%) in Group 2. The postoperative median BCVA increased from 3 to 1 logMAR in Group 1 and from 3 to 0.76 logMAR in Group 2 ($p < 0.001$, $p = 0.08$, respectively). Intraocular pressure (IOP) before and after surgery was similar in both groups ($p = 0.41$, $p = 0.82$, respectively; ► **Table 3**).

No significant difference was determined between the groups in respect to preoperative and postoperative BCVA, preoperative and postoperative IOP, and BCVA improvement ($p = 0.77$, $p = 0.16$, $p = 0.63$, $p = 0.54$, $p = 0.21$, respectively; ► **Table 4**).

► **Table 1** Patient demographics and characteristics.

Variable	Data
Gender (M/F)	18 (62.1%)/11 (37.9%)
Age (median)	61.6
Hole closure (yes/no)	22 (75.9%)/7 (24.1%)
Retinal attachment (yes/no)	26 (89.7%)/3 (10.3%)
Tamponade (silicone oil/C ₃ F ₈)	17 (58.6%)/12 (41.4%)

► **Table 2** Surgical success in patient groups.

	Group 1	Group 2	P*
Retinal attachment			
Yes	15 (89.3%)	11 (91.7%)	0.64
No	2 (11.7%)	1 (8.3%)	
Macular hole closure			
Yes	12 (71.6%)	10 (78.1%)	0.52
No	5 (29.4%)	2 (16.6%)	
Fisher's exact test, *p < 0.05			

Discussion

The complex process of the formation of MHRD and the two criteria (retinal attachment and MH closure) on which success is based create various difficulties in applying the optimal intervention and obtaining the intended anatomic and functional outcome in this patient group when faced with the problem of MH. The results of this study represent the surgical outcomes and the effects of two crucial postsurgical internal tamponades, silicone oil and C₃F₈ gas, on the visual and anatomic results. Surgery in patients with MHRD has two purposes. The first goal is to restore the retinal attachment, and the second is to close the MH. If only retinal attachment is achieved, postoperative vision will not improve to the desired level. Therefore, successful MH closure must be ensured to improve the subsequent visual acuity. In this series, retinal attachment was achieved in 89% of Group 1 and 91% of Group 2, and MH closure in 71% of Group 1 and 78% of Group 2.

ILM peeling is a cornerstone for MH closure by completely removing all contractile cells from the edge of the MH. Although the ILM does not have natural contractile properties, it serves as a scaffold for the contractile tissue to exert tangential traction on the umbo. The completeness of elimination of the overlying contractile tissue when the ILM is peeled provides greater surgical success and higher contrast sensitivity than in eyes without membrane peeling [14, 15]. In contrast, it was reported in a study by Shukla et al. that ILM peeling did not result in higher closure rates of MH than in cases without ILM peeling, which have better BCVA [16]. In that series, unlike the current study, Shukla et al. used

► **Table 3** Comparison of median BCVA and IOP values before and after surgery within the groups.

Variable	Preoperative BCVA (log-MAR; median [min-max])	Postoperative BCVA (log-MAR; median [min-max])	P value
Group 1	3 (0.7–3)	1 (0.2–3)	< 0.01*
Group 2	3 (2–3)	0.76 (0.3–3)	0.008*
	Preoperative IOP (mmHg; median [min-max])	Postoperative IOP (mmHg; median [min-max])	
Group 1	13 (10–19)	15 (12–16)	0.41
Group 2	15 (10–17)	14 (9–18)	0.82

Wilcoxon signed-rank test, *p < 0.05, BCVA = best-corrected visual acuity, IOP = intraocular pressure

► **Table 4** The median values of the groups were analyzed using the Mann-Whitney U test.

Variable	Group 1 (n = 17) (logMAR; median [min-max])	Group 2 (n = 12) (logMAR; median [min-max])	P value
Preoperative BCVA	3 (0.7–3)	3 (2–3)	0.77
Postoperative BCVA	1 (0.2–3)	0.76 (0.3–3)	0.16
BCVA increment	1.14 (0.18–2.48)	2 (0.4–2.7)	0.21
Preoperative IOP (mmHg)	13 (10–19)	15 (12–16)	0.63
Postoperative IOP (mmHg)	15 (10–17)	14 (9–18)	0.54

Mann-Whitney U test, *p < 0.05, BCVA = best-corrected visual acuity, IOP = intraocular pressure

silicon oil in 26 cases and C₃F₈ gas in 5 cases. In addition, a 100% retinal attachment rate was reported, and all patients underwent encircling scleral buckle, unlike the current series. This minor difference in terms of the two series may be related to the possible effect of the scleral buckle. Moreover, the authors advocated type 2 closure as a successful closure in that study, and 8 (57%) of the 14 closed holes in patients with ILM peeling had type 2 closure, whereas in patients without ILM peeling, 3 (23.1%) of 13 closed holes had type 2 closure. The current study classified only type 1 closure as an accurate and successful closure and achieved these rates.

Chen et al. [17] achieved 100% success in both retinal attachment and closure of the MH with a free retinal flap assisted by

liquid perfluorocarbon in their case series of 7 patients. This method can be used in failed MH closure, although not in the first surgery. A recent study conducted by Lyu et al. [18] compared the ILM flap and ILM insertion techniques on MH closure in 49 MHRD cases, and the ILM flap was shown to be superior to the ILM insertion technique to improve the postoperative BCVA. In that series, MH closure was observed in 95% of the ILM flap group and 73% of the ILM insertion group, although 40 (82%) patients were high myopic. In the current series, high myopic patients were excluded from the evaluation. MH closure was obtained in 75.9% of the patients in this series by performing only ILM peeling.

Ryan et al. [11] showed that ILM peeling increased the success of MH closure in MHRD cases and reported MH closure at the rate of 90.7% in these cases, and at a rate of 33.3% in cases where the ILM was not peeled (average 83.7%). Perfluorooctane was not used in those cases due to the concern of transmission to the sub-retinal region due to MH and possible toxicity of the dye. In the current study, brilliant blue and perfluorocarbon were used in all cases and no associated problems were encountered. In the previous study, SF₆ was shown to be superior to C₃F₈ in terms of success, but SF₆ was not used as a postoperative tamponade in any patient of the current series.

Although modern surgical techniques are very advanced, ILM peeling from the detached retina is challenging. Using liquid perfluorocarbon and dyes such as brilliant blue facilitates ILM peeling in these cases. Some authors have developed bimanual peeling techniques because of the concern that there may be transition from the hole to the back of the retina during the use of liquid perfluorocarbon. This technique risks serious complications such as macular trauma and paramacular breaks. Peeling the ILM under perfluorocarbon liquid eliminates the need for bimanual counter-pressure and reduces the risk of macular annealing. In the current study, liquid perfluorocarbon and brilliant blue dye were used when peeling the ILM in all cases [19–23].

To the best of our knowledge, although there is much information about MHRD secondary high myopia, there is no study in the literature as large as the current series that has evaluated patients with MHRD without high myopia. The efficacy of these intraocular tamponades on surgical success was investigated and the surgical results are presented. However, limitations of this study included the retrospective nature, and that preoperative OCT imaging could not be performed in all patients due to the nature of RRD. Furthermore, the diagnosis of an MH was made mostly during the operation. As the study was conducted in two centers, two different OCT devices were used, one of which did not have a segmentation function, so retinal layers, including the ganglion cell complex, could not be examined in detail. Thus, using two different OCT devices was a problem in terms of optimizing the values.

Conclusion

The results of this study demonstrated that there was no significant difference between silicone oil or C₃F₈ gas as an intraocular tamponade after ILM peeling in patients with MHRD. Silicone oil does not have a significant superiority over C₃F₈ in cases with MHRD. Considering the potential problems that the use of sili-

cone may cause in the future, C₃F₈ gas can be used in suitable cases as a postoperative tamponade in MHRD.

CONCLUSION BOX

Already known:

- There are no data about the surgical outcomes of patients with peripheral tear-induced retinal detachment with coexisting MH without high myopia in the literature.

Newly described:

- PPV plus ILM peeling is a very safe and effective method in MH coexisting secondary to retinal detachment without high myopia, which is quite complex and problematic.
- There is no significant difference between silicone oil or C₃F₈ gas as an intraocular tamponade after ILM peeling in patients with peripheral tear-induced retinal detachment with coexisting MH without high myopia.
- Silicone oil does not have a significant superiority over C₃F₈ in cases with peripheral tear-induced retinal detachment with coexisting MH without high myopia.

Funding

This study was funded by the authors and did not receive any grant from finance agencies in the public or commercial sectors.

Data Availability Statement

The data that support the findings of this study are available from the corresponding author upon reasonable request.

Contributors' Statement

Y.O. and M.N.B. performed the surgeries; A.Y.G. and M.T. were involved in drafting the article; Y.O. designed the concept of the study, A.A. revised it critically for important intellectual content, and all authors approved the final version to be published. All authors had full access to all of the data in the study and take responsibility for the integrity and the accuracy of the data.

Conflict of Interest

The authors declare that they have no conflict of interest.

References

- Parravano M, Giansanti F, Eandi CM et al. Vitrectomy for idiopathic macular hole. *Cochrane Database Syst Rev* 2015; (5): CD009080. doi:10.1002/14651858.CD009080.pub2
- Wang S, Xu L, Jonas JB. Prevalence of full-thickness macular holes in urban and rural adult Chinese: the Beijing Eye Study. *Am J Ophthalmol* 2006; 141: 589–591. doi:10.1016/j.ajo.2005.10.021
- Jackson TL, Donachie PHJ, Sparrow JM et al. United Kingdom National Ophthalmology Database study of vitreoretinal surgery: report 2, macular hole. *Ophthalmology* 2013; 120: 629–634. doi:10.1016/j.ophtha.2012.09.003

- [4] Budoff G, Bhagat N, Zarbin MA. Traumatic Macular Hole: Diagnosis, Natural History, and Management. *J Ophthalmol* 2019; 2019: 5837832. doi:10.1155/2019/5837832
- [5] Schumann RG, Wolf A, Hoerauf H et al. Vitrectomy for Persistent Macular Holes Following Ocriplasmin Injection: A Comparative Multicenter Study. *Retina* 2017; 37: 2295–2303. doi:10.1097/IAE.0000000000001473
- [6] Cunningham MA, Tarantola RM, Folk JC et al. Proliferative vitreoretinopathy may be a risk factor in combined macular hole retinal detachment cases. *Retina* 2013; 33: 579–585. doi:10.1097/IAE.0b013e31826b0c41
- [7] Najafi M, Brown JS, Rosenberg KI. Increased Reoperation Rate in Surgical Treatment of Rhegmatogenous Retinal Detachment with Coexistent Macular Hole. *Ophthalmol Retina* 2018; 2: 187–191. doi:10.1016/j.oret.2017.07.005
- [8] Oie Y, Emi K, Takaoka G et al. Effect of indocyanine green staining in peeling of internal limiting membrane for retinal detachment resulting from macular hole in myopic eyes. *Ophthalmology* 2007; 114: 303–306. doi:10.1016/j.ophtha.2006.07.052
- [9] Schumann RG, Langer J, Compera D et al. Assessment of intravitreal ocriplasmin treatment for vitreomacular traction in clinical practice. *Graefes Arch Clin Exp Ophthalmol* 2017; 255: 2081–2089. doi:10.1007/s00417-017-3747-1
- [10] Schwartz SG, Flynn HW jr., Wang X et al. Tamponade in surgery for retinal detachment associated with proliferative vitreoretinopathy. *Cochrane Database Syst Rev* 2020; 5: CD006126. doi:10.1002/14651858.CD006126.pub4
- [11] Ryan EH jr., Bramante CT, Mittra RA et al. Management of rhegmatogenous retinal detachment with coexistent macular hole in the era of internal limiting membrane peeling. *Am J Ophthalmol* 2011; 152: 815–819. e1. doi:10.1016/j.ajo.2011.04.026
- [12] Abouhusein MA, Elbaha SM, Aboushousha M. Human Amniotic Membrane Plug for Macular Holes Coexisting with Rhegmatogenous Retinal Detachment. *Clin Ophthalmol* 2020; 14: 2411–2416. doi:10.2147/OPHT.S272060
- [13] Duker JS, Kaiser PK, Binder S et al. The International Vitreomacular Traction Study Group classification of vitreomacular adhesion, traction, and macular hole. *Ophthalmology* 2013; 120: 2611–2619. doi:10.1016/j.ophtha.2013.07.042
- [14] Park DW, Lee JH, Min WK. The use of internal limiting membrane maculorrhexis in treatment of idiopathic macular holes. *Korean J Ophthalmol* 1998; 12: 92–97. doi:10.3341/kjo.1998.12.2.92
- [15] Brooks HL jr. Macular hole surgery with and without internal limiting membrane peeling. *Ophthalmology* 2000; 107: 1939–1948. doi:10.1016/s0161-6420(00)00331-6
- [16] Shukla D, Kalliath J, Srinivasan K et al. Management of rhegmatogenous retinal detachment with coexisting macular hole: a comparison of vitrectomy with and without internal limiting membrane peeling. *Retina* 2013; 33: 571–578. doi:10.1097/IAE.0b013e31826b6748
- [17] Chen SN, Yang CM. Perfluorocarbon Liquid-Assisted Neurosensory Retinal Free Flap for Complicated Macular Hole Coexisting with Retinal Detachment. *Ophthalmologica* 2019; 242: 222–233. doi:10.1159/000502443
- [18] Lyu J, Xia F, Zhao P. Intraoperative Perfluorocarbon Liquid Tamponade Technique for Treatment of Extensive Retinal Detachment Secondary to a Myopic Macular Hole. *Retina* 2022. doi:10.1097/IAE.00000000000003429
- [19] Ichibe M, Yoshizawa T, Murakami K et al. Surgical management of retinal detachment associated with myopic macular hole: anatomic and functional status of the macula. *Am J Ophthalmol* 2003; 136: 277–284. doi:10.1016/s0002-9394(03)00186-7
- [20] O'Driscoll AM, Goble RR, Kirkby GR. Vitrectomy for retinal detachments with both peripheral retinal breaks and macular holes. An assessment of outcome and the status of the macular hole. *Retina* 2001; 21: 221–225. doi:10.1097/00006982-200106000-00004
- [21] Nishimura A, Kita K, Segawa Y et al. Perfluorocarbon liquid assists in stripping the ILM to treat detached retina caused by macular hole. *Ophthalmic Surg Lasers* 2002; 33: 77–78
- [22] Uemoto R, Yamamoto S, Tsukahara I et al. Efficacy of internal limiting membrane removal for retinal detachments resulting from a myopic macular hole. *Retina* 2004; 24: 560–566. doi:10.1097/00006982-200408000-00009
- [23] Chen YP, Chen TL, Yang KR et al. Treatment of retinal detachment resulting from posterior staphyloma-associated macular hole in highly myopic eyes. *Retina* 2006; 26: 25–31. doi:10.1097/00006982-200601000-00005