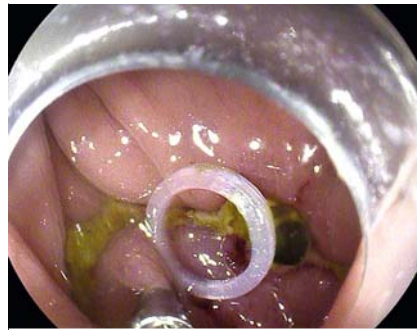


A novel elastic ring for suturing colonic anastomotic fistula by colonoscopy

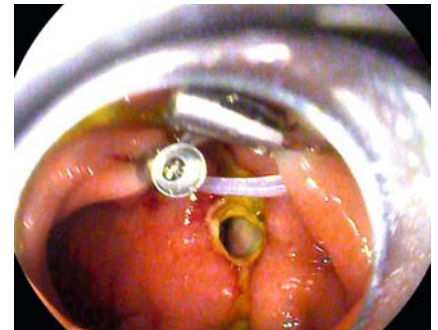
A 76-year-old man presented with abdominal pain and fever on the fourth day after laparoscopic radical resection of rectal cancer. Colonoscopy revealed an 0.8×0.8-cm colonic anastomotic fistula 8 cm from the anus.

Because of major tension from the surface of the fistula and pronounced swelling at the anastomosis, it was difficult to close the fistula with metal clips. Instead, we anchored one metal clip with an elastic ring on one side of the fistula (► Fig. 1). Then we pulled the elastic ring to the opposite side with another metal clip and anchored the clip. By means of the elastic force, the tension from the surface of the fistula was reduced and the fistula shrunk (► Fig. 2). Then we used two metal clips anchored around the fistula across the elastic ring (► Fig. 3). A nylon rope was used to gather the metal clips, and the fistula was nearly closed (► Fig. 4). The remaining small gap was closed directly using metal clips. Colonoscopy 3 months later revealed that the fistula had healed completely.

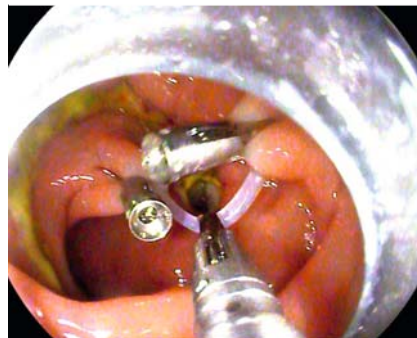
Colonic anastomotic fistulas are serious postoperative complications. Most cases are sutured during a second surgical operation, which causes considerable damage. Manta et al. reported that the over-the-scope clip has therapeutic effects on colonic anastomotic fistulas [1]. Our patient was given fistula suture treatment by colonoscopy using the elastic ring, metal clips, and nylon rope (► Video 1), and this produced a satisfactory curative effect with less damage than surgery. The elastic ring is our own patented invention (► Fig. 5) (Patent number: ZL 2020 2 0016729.9, China). It is used mainly to assist in endoscopic submucosal dissection [2]. This is the first report of suturing a colonic anastomotic fistula with an elastic ring by endoscopy. The elastic ring provides one new method for suturing colonic anastomotic fistulas via colonoscopy.



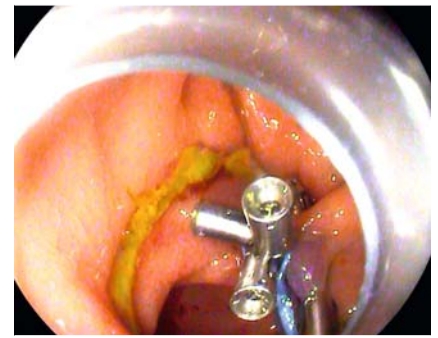► Fig. 1 One metal clip with an elastic ring was anchored on one side of the fistula.



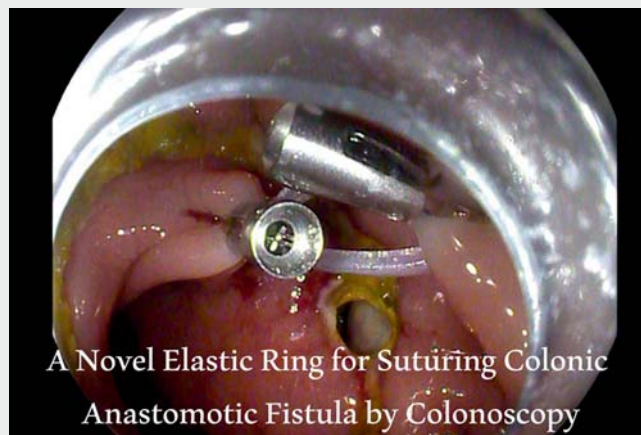► Fig. 2 A second metal clip was used to pull the elastic ring to the opposite side, and the tension from the fistula was reduced by elastic contraction force.



► Fig. 3 Metal clips were placed across the elastic ring and anchored on the mucosal tissue around the fistula.



► Fig. 4 A nylon rope was used to gather the metal clips and tighten the fistula.



► Video 1 A novel elastic ring for suturing colonic anastomotic fistula by colonoscopy.





► **Fig. 5** This elastic ring was invented by the authors under an independent invention patent.

Endoscopy_UCTN_Code_TTT_1AQ_2AG FB

Competing interests

The authors declare that they have no conflict of interest.

The authors

Shuai-qing Zhang¹, Zhou-man Yu², Bai-hui Wang¹  **Xiu-li Zuo³, Ai-jun Zhang¹, Ru-yuan Li¹** 

- 1 Department of Gastroenterology, Qilu Hospital (Qingdao), Cheeloo College of Medicine, Shandong University, Qingdao, Shandong, China
- 2 Department of General Surgery, Qilu Hospital (Qingdao), Cheeloo College of Medicine, Shandong University, Qingdao, Shandong, China
- 3 Department of Gastroenterology, Qilu Hospital of Shandong University, Jinan, Shandong, China

Corresponding author

Ru-yuan Li, MD

Department of Gastroenterology, Qilu Hospital (Qingdao), Cheeloo College of Medicine, Shandong University, 758 Hefei Road, Qingdao, Shandong, 266035, China
liruyuan163@163.com

References

- [1] Manta R, Manno M, Bertani H et al. Endoscopic treatment of gastrointestinal fistulas using an over-the-scope clip (OTSC) device: case series from a tertiary referral center. *Endoscopy* 2011; 43: 545–548
- [2] Zhang A, Song Y, Cui X et al. Application of in vivo traction-assisted resection of proximal colon lesions: a case series (with video). *Surg Endosc* 2022. doi:10.1007/s00464-022-09266-y

Bibliography

Endoscopy 2023; 55: E155–E156

DOI 10.1055/a-1953-7096

ISSN 0013-726X

published online 28.10.2022

© 2022. The Author(s).

This is an open access article published by Thieme under the terms of the Creative Commons Attribution-NonDerivative-NonCommercial License, permitting copying and reproduction so long as the original work is given appropriate credit. Contents may not be used for commercial purposes, or adapted, remixed, transformed or built upon. (<https://creativecommons.org/licenses/by-nc-nd/4.0/>)

Georg Thieme Verlag KG, Rüdigerstraße 14, 70469 Stuttgart, Germany



ENDOSCOPY E-VIDEOS

<https://eref.thieme.de/e-videos>



Endoscopy E-Videos is an open access online section, reporting on interesting cases and new techniques in gastroenterological endoscopy. All papers include a high quality video and all contributions are freely accessible online. Processing charges apply (currently EUR 375), discounts and waivers acc. to HINARI are available.

This section has its own submission website at

<https://mc.manuscriptcentral.com/e-videos>