



Trigger Wrist with Carpal Tunnel Syndrome Accompanied with Trifid Median Nerve: A Case Report and Literature Review

Sangho Oh, MD¹

¹Department of Plastic and Reconstructive Surgery, Saeson Hospital, Daejeon, Republic of Korea

Arch Plast Surg 2022;49:750–754.

Address for correspondence Sangho Oh, MD, Department of Plastic and Reconstructive Surgery, Saeson Hospital, 858, Gyeryong-ro, Jung-gu, Daejeon 34908, Republic of Korea (e-mail: fwmesser@hanmail.net).

Abstract

Trigger wrist, characterized by a clicking or snapping sensation around the wrist joint during finger or wrist motion, and bifid or trifid median nerve, which occurs in carpal tunnel syndrome along with anatomical variation of median nerve, are rare conditions. We report the case of a patient with a thickened tendon caused by severe tenosynovitis and flexor tendon subluxation to the hamate hook due to bowing of the flexor retinaculum, thereby resulting in trigger wrist as well as an anatomical median nerve variation (bifid median nerve in the right wrist and trifid median nerve in the left wrist). A 59-year-old housewife visited our hospital with bilateral fingertip numbness, tingling sensation, and aggravated severe night cramping that began 2 months ago. She also complained about trigger wrist during small finger flexion. Based on magnetic resonance imaging, ultrasonography, and nerve conduction study, trifid median nerve and bilateral severe median nerve neuropathy of the wrist were diagnosed; therefore, transverse carpal tunnel release and exploration under wide-awake anesthesia were planned. Intraoperative findings showed trifid and bifid median nerves in left and right wrists, respectively. Additionally, bowing of flexor retinaculum and severe flexor tendon tenosynovitis were observed. Tenosynovitis with thickened flexor sheath resulted in subluxation of the small finger flexor tendon above the hamate hook. After transverse carpal ligament release with antebrachial fascia release and tenosynovectomy, subluxation of the flexor tendon was resolved. At 6 months postoperatively, the tingling and dullness in fingertips also resolved, and no trigger wrist or any other complications were noted.

Keywords

- ▶ trigger wrist
- ▶ carpal tunnel syndrome
- ▶ trifid median nerve
- ▶ bifid median nerve
- ▶ median nerve neuropathy

Introduction

Trigger wrist is a rare condition that is characterized by a clicking or snapping sensation around the wrist joint during finger or wrist motion.^{1,2} There may be no pain

or painful triggering. There are various etiologies of trigger wrist, including an abnormal muscle belly; flexor sheath mass, for example, fibroma, ganglion, rheumatoid nodule, and severe tenosynovitis.^{1,3–6} In addition, the mass causing the trigger wrist makes a mass effect in the

received

June 6, 2022

accepted after revision

September 14, 2022

DOI <https://doi.org/10.1055/a-1947-2834>.
eISSN 2234-6171.

© 2022. The Korean Society of Plastic and Reconstructive Surgeons. All rights reserved.

This is an open access article published by Thieme under the terms of the Creative Commons Attribution-NonDerivative-NonCommercial-License, permitting copying and reproduction so long as the original work is given appropriate credit. Contents may not be used for commercial purposes, or adapted, remixed, transformed or built upon. (<https://creativecommons.org/licenses/by-nc-nd/4.0/>)

Thieme Medical Publishers, Inc., 333 Seventh Avenue, 18th Floor, New York, NY 10001, USA

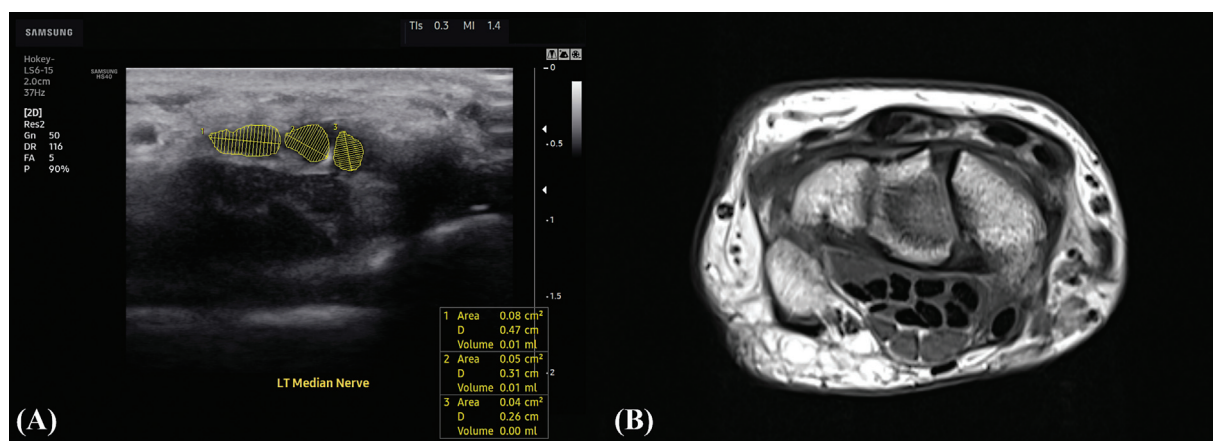


Fig. 1 (A) Trifid median nerve in the left wrist. Each median nerve diameter was 0.08, 0.05, and 0.04 cm². (B) Severe bowing of the flexor retinaculum and trifurcation of the median nerve on the left wrist.

carpal tunnel, often resulting in median nerve neuropathy.^{5,6}

Carpal tunnel syndrome, a median nerve compressive neuropathy in the wrist, is the most common neuropathy of the upper extremity.⁷ Carpal tunnel syndrome is caused by the entrapment of the median nerve caused by thickened flexor retinaculum, flexor tenosynovitis, and intracarpal tunnel mass.⁸ Moreover, anatomical variation of the median nerve can cause carpal tunnel syndrome. Bifid and trifid median nerves have been recently reported to cause carpal tunnel syndrome as anatomical variations of the median nerve. The bifid median nerve has recently been reported to have an incidence of 2.8%;⁹ however, carpal tunnel syndrome caused by the trifid median nerve is extremely rare. To the best of our knowledge, only five cases of trifid median nerve have been reported.^{7,9-12} Moreover, all previous case reports have only focused on anatomical variation and preoperative evaluation and lack other features, such as changes occurring in other structures or symptoms accompanied by this anatomical variation.

In this study, we reported the case of a patient with a trigger wrist with ipsilateral carpal tunnel syndrome caused by a trifid median nerve and contralateral carpal tunnel syndrome caused by a bifid median nerve. Further, the trifid median nerve caused anatomical changes in the flexor retinaculum. We report the symptoms and their correlation with anatomical changes and detailed intraoperative findings of our case. Patients provided informed consent for the publication of the clinical photographs included in this article.

Case

In this institutional review board-approved case report (KoNIBP P01-202203-01-031), we report the case of a 59-year-old housewife who visited our hospital for bilateral fingertip numbness, tingling sensation, and aggravated severe night cramping for 2 months. She particularly complained about the painless triggering flexor tendons in the wrist during small finger flexion (▶ **Video 1**). With a physical examination, no tenderness was noted in the A1 pulley area. During small finger flexion, snapping of a palpable mass in the wrist crease area was observed. Tinel's sign was noted as

severe for both wrists. Plain radiography revealed no absolute lesions in the carpal tunnel, such as calcification or mass lesion. High-frequency transverse musculoskeletal ultrasonography revealed a trifid median nerve in the left wrist and median nerve compression in the right wrist. The diameter of each median nerve branch in the carpal tunnel was 0.04, 0.05, and 0.08 cm², respectively, and that at the proximal wrist crease level was 0.45, 0.43, and 0.48 cm², respectively (▶ **Fig. 1**). In addition, dynamic ultrasonography revealed the subluxation of the 5th flexor superficialis tendon over the hamate hook (▶ **Video 2**). Magnetic resonance imaging of the left wrist indicated the presence of a trifid median nerve as well as bowing of the flexor retinaculum and severe flexor tenosynovitis (▶ **Fig. 1**). Nerve conduction velocity and electromyography tests revealed severe carpal tunnel syndrome in the right wrist (Bland scale V) as well as an extremely severe carpal tunnel syndrome in the left wrist (Bland scale VI).

Video 1

Flexor triggering on the wrist during small finger flexion. Online content including video sequences viewable at: <https://www.thieme-connect.com/products/ejournals/html/10.1055/a-1947-2834>.

Video 2

Subluxation of fifth flexor digitorum superficialis over the hamate hook while making a fist (red arrow). Online content including video sequences viewable at: <https://www.thieme-connect.com/products/ejournals/html/10.1055/a-1947-2834>.

To relieve wrist triggering and median nerve compression, carpal tunnel release and exploration under wide-awake

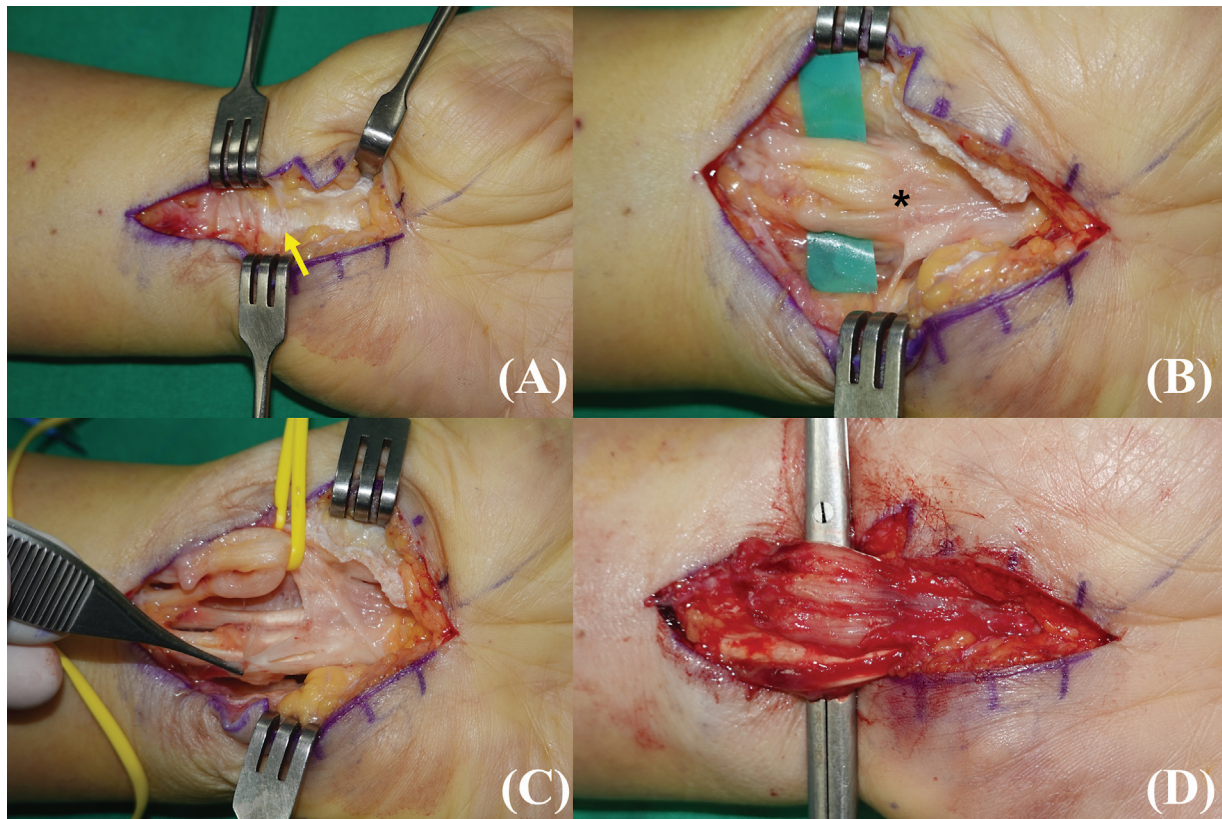


Fig. 2 (A) Bowing of the flexor retinaculum (yellow arrow). (B) Trifurcation of the median nerve in the left wrist. A trifold median nerve with severe narrowing and a compressed median nerve on the wrist crease level was observed (asterisk). (C) Severe tenosynovitis around the flexor tendon along the carpal tunnel. (D) The trifid median nerve and tendon observed after tenosynovectomy and transverse carpal ligament release.

anesthesia were planned. Intraoperative findings along the long wrist carpal incision revealed a bulged flexor retinaculum. After releasing the flexor retinaculum, a trifid median nerve with severe narrowing and a compressed median nerve on the wrist crease level was observed (►Fig. 2). Triggering flexor tendon in the wrist was caused by the subluxation of the flexor tendon superficialis out of the carpal tunnel and passing by the hamate hook (►Fig. 3). In addition, the inflamed thick flexor tendon sheath was expected to exhibit severe flexor tenosynovitis. The in-

creased thickness of the flexor tendon potentially increases the carpal tunnel volume, and its long-standing mass effect appears to have caused the flexor retinaculum to bulge and result in the subluxation of the flexor tendon. Flexor tenosynovectomy accompanied by a reduction in the carpal tunnel mass effect was required. Following flexor tenosynovectomy and transverse carpal ligament release, subluxation of the flexor tendon was resolved, and the trigger wrist was not observed under wide-awake anesthesia (►Video 3).

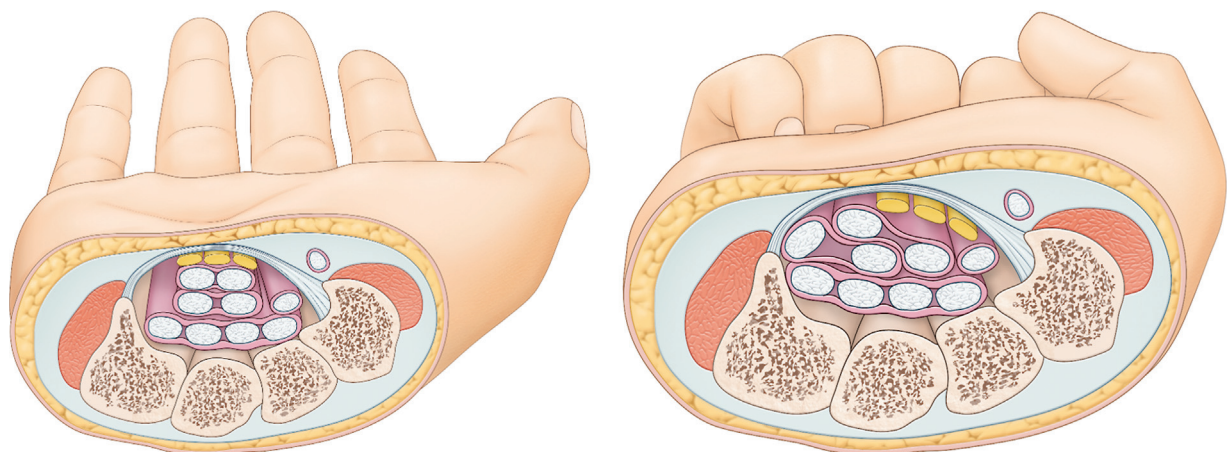


Fig. 3 Small finger flexor digitorum superficialis subluxation over the hamate hook because of the thickened tendon caused by severe tenosynovitis and bowing of the flexor retinaculum during small finger flexion.

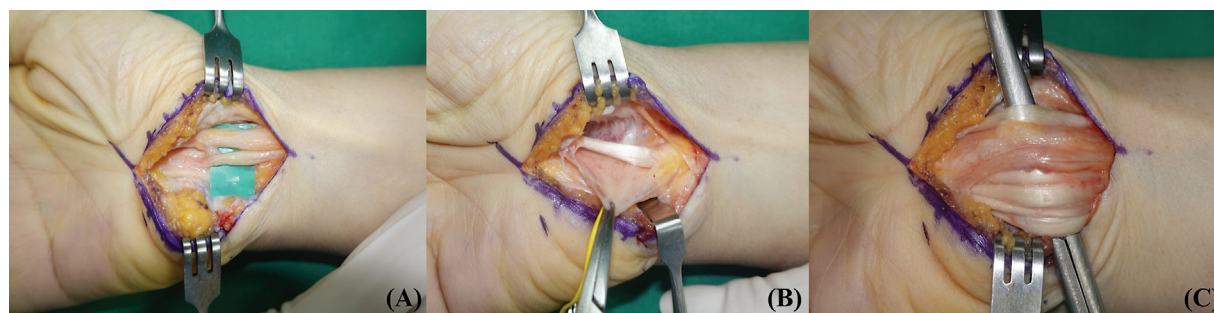

Fig. 4 (A) Bifurcation of the median nerve in the right wrist. (B) Severe tenosynovitis around the flexor tendon. (C) The bifid median nerve and flexor tendon observed after transverse carpal ligament and antebrachial fascia release.

Video 3

Trigger wrist was not observed while making a fist after tenosynovectomy and transverse carpal ligament release. Online content including video sequences viewable at: <https://www.thieme-connect.com/products/ejournals/html/10.1055/a-1947-2834>.

On the following day, the carpal tunnel on the contralateral side was released under the brachial plexus block. After releasing the flexor retinaculum, the bifid median nerve was observed. Following a long carpal tunnel incision, the bifid median nerve and radial side branch were also found to be severely compressed and narrowed on the wrist crease level. As observed on the left side, severe flexor tenosynovitis was noted; accordingly, flexor tenosynovectomy was performed (► Fig. 4).

The postoperative course was fine. Night cramping was relieved on the day after surgery, and fingertip sensation was restored at 1 week postoperatively. At 6 months postoperatively, trigger wrist, night cramping, and tingling sensation were completely resolved.

Discussion

To the best of our knowledge, this is the first case report of a patient with a trifold median nerve as well as a trigger wrist. In 1977, Lanz classified the anatomical variations in the median nerve into the following four groups: (1) the thenar branch anomaly, (2) accessory median nerve branch in the proximal carpal tunnel, (3) division of median nerve into two branches with or without median artery, and (4) accessory median nerve at the distal carpal tunnel.¹³ In this classification system, the trifold median nerve was not included in any other classifications. The trifold median nerve appears to be included in Lanz classification III; however, this aspect requires revision. In 2016, Lonie et al also stated that the Lanz classification should be revised to include the trifold median nerve.¹⁰

The diameter of each trifold median nerve was 0.04, 0.05, and 0.08 cm². According to Siddiq et al, the diameter of each trifold median nerve was 0.02, 0.05, and 0.09 cm^{2,9} and

according to Cai and Annaswamy, each nerve branch diameter was 0.03, 0.03, and 0.08 cm².¹⁴ There are no significant differences in each median nerve branch in a trifold median nerve in other cases to date; the diameter of each median nerve branch in our case was also similar to that in other cases. In particular, each median nerve diameter was 0.43, 0.45, and 0.48 cm² in the proximal wrist crease in our case. We believe that because of the thickened flexor tendon caused by severe tenosynovitis and trifold median nerve, the volume in the carpal tunnel increased, resulting in the bowing of the flexor retinaculum in the wrist crease and more severe median nerve compression in the distal area. Nerve conduction tests also indicated that the left side exhibits a more severe median nerve compression than the right side. According to Yalcin et al, the median nerve splits into three branches 5 to 6 cm proximally¹¹; in our case, the median nerve split into three branches 4 cm proximal to the carpal tunnel. Moreover, contralateral carpal tunnel release was performed and the bifid median nerve was observed. Preoperative ultrasonography did not reveal a bifurcation of the median nerve; therefore, we could not measure the median nerve thickness in the carpal tunnel. The median nerve split into two branches 7 cm proximal to the carpal tunnel.

Trigger wrist, characterized by snapping or clicking of the wrist, is a rare condition marked by a painful sensation around the wrist during wrist or finger movement.³ Suematsu et al classified the etiology of the triggering at the wrist into three mechanisms: (1) a tumor or rheumatoid nodule on the flexor tendon, (2) anomalous muscle belly in the carpal tunnel, and (3) a combination of both mechanisms.^{1,15} In our study, the trigger wrist was caused by the subluxated thickened tendon above the hamate hook. This can be classified under the type I mechanism; however, this mechanism does not include the anatomical changes of the flexor retinaculum as those observed in our case.

Park et al reported the various etiologies of this condition; almost all forms of trigger fingers are caused by a mass effect in the carpal tunnel or flexor tendon or thickening of the muscle belly due to neoplasms, such as fibroma, giant cell tumor, rheumatoid nodule, tenosynovitis, and ganglion cysts.¹ Specific findings were noted in our case; triggering did not occur by other surrounding tendons, but flexor

tendon thickening because of severe tenosynovitis and coexisted bowing of the flexor retinaculum. The bowing of the flexor retinaculum makes a space between the hamate hook and the flexor retinaculum. Therefore, subluxation of the flexor tendon over the hamate hook was observed while making a fist. It was an unknown mechanism of wrist triggering to date. After a simple transverse carpal ligament release, antebrachial fascia release, and tenosynovectomy, this condition was completely resolved. At 6 months postoperatively, trigger wrist was not observed.

The case in this study is one of the very rare cases of median nerve variation (bifid median nerve in the right wrist and trifid median nerve in the left wrist). In addition, trigger wrist due to the bowing of the flexor retinaculum occurred because of the long-standing trifid median nerve with mass effect (thickened flexor tendon) on the carpal tunnel. Surgical plans should be designed according to the mechanism and cause of the disorder. Therefore, in our case, reducing the thickness of the flexor tendon through tenosynovectomy and transverse carpal ligament release can be performed with excellent results and without any complications. Anatomical variations should be preoperatively considered to enable taking better preoperative decisions and avoid iatrogenic median nerve injuries.

Conflicts of Interest

None declared.

Acknowledgments

None.

Ethical Approval

This study was approved by the institutional review board of Korea National Institute for Bioethics Policy (IRB No. KoNIBP P01-202203-01-031).

Sources of Support

Nothing to disclose

Patient Consent

Written informed consent was obtained for publication of this article and accompanying images.

Author Contribution

Conceptualization, Data curation, Visualization, Writing -original draft and review, editing: S.H Oh.

References

- 1 Park IJ, Lee YM, Kim HM, et al. Multiple etiologies of trigger wrist. *J Plast Reconstr Aesthet Surg* 2016;69(03):335-340
- 2 Giannikas D, Karabasi A, Dimakopoulos P. Trigger wrist. *J Hand Surg Eur Vol* 2007;32(02):214-216
- 3 Smith RD, O'Leary ST, McCullough CJ. Trigger wrist and flexor tenosynovitis. *J Hand Surg [Br]* 1998;23(06):813-814
- 4 Lemon RA, Engber WD. Trigger wrist: a case report. *J Hand Surg Am* 1985;10(01):61-63
- 5 Park IJ, Lee YM, Rhee SK, Song SW, Kim HM, Choi KB. Trigger wrist. *Clin Orthop Surg* 2015;7(04):523-526
- 6 Aghasi MK, Rzetelny V, Axer A. The flexor digitorum superficialis as a cause of bilateral carpal-tunnel syndrome and trigger wrist. A case report. *J Bone Joint Surg Am* 1980;62(01):134-135
- 7 Duyum M, Yilmaz O, Ulasli AM, Asal N, Kosar U. Coexistence of trifid and bifid median nerve in a patient with bilateral carpal tunnel syndrome. *Turk Neurosurg* 2013;23(05):685-687
- 8 Gabra JN, Li ZM. Carpal tunnel cross-sectional area affected by soft tissues abutting the carpal bones. *J Wrist Surg* 2013;2(102):73-78
- 9 Siddiq MAB, Hossain Parash MT. Incidental trifid median nerve unveiled in a lactating mother. *Cureus* 2019;11(09):e5809
- 10 Lonie S, Niumsawatt V, Rozen WM. Median nerve trifurcation. *Plast Reconstr Surg Glob Open* 2016;4(11):e1129
- 11 Yalcin E, Onder B, Akyuz M. Trifid median nerve. *J Hand Surg Eur Vol* 2011;36(09):812-813
- 12 Rayegani SM, Sedighipour L, Raeissadat SA, et al. Co-occurrence of trifid and bifid median nerves in a patient with bilateral carpal tunnel syndrome. *Neurol India* 2015;63(05):788-789
- 13 Lanz U. Anatomical variations of the median nerve in the carpal tunnel. *J Hand Surg Am* 1977;2(01):44-53
- 14 Cai H, Annaswamy TM. Trifid median nerve: A rare variant in a patient with carpal tunnel syndrome. *Am J Phys Med Rehabil* 2019;98(06):e67-e68
- 15 Suematsu N, Hirayama T, Takemitsu Y. Trigger Wrist Caused by a Giant Cell Tumour of Tendon Sheath. *J Hand Surg Eur* 1985;10(01):121-123.