



# The Oblique Extended Reverse First Dorsal Metacarpal Artery Perforator Flap for Coverage of the Radial-Volar Defect of the Proximal Interphalangeal Joint in the Index Finger: A Case Report

Jeeyoon Kim, MD<sup>1</sup> Bommie Florence Seo, MD, PhD<sup>1</sup> Junho Lee, MD<sup>1</sup> Sung No Jung, MD, PhD<sup>1</sup>

<sup>1</sup>Department of Plastic and Reconstructive Surgery, Uijeongbu St. Mary's Hospital, Uijeongbu-si, Gyeonggi-do, Republic of Korea

Arch Plast Surg 2022;49:760–763.

Address for correspondence Sung No Jung, MD, PhD, Department of Plastic and Reconstructive Surgery, Uijeongbu St. Mary's Hospital, 271, Cheonbo-ro, Uijeongbu-si, Gyeonggi-do, Republic of Korea (e-mail: jsn7190@catholic.ac.kr).

## Abstract

The dorsal metacarpal artery perforator flap is a flap that rises from the hand dorsum. Owing to its reliability and versatility, this flap is used as a workhorse for finger defect. However, to cover the radial-volar defect of the proximal interphalangeal joint (PIPJ) of the index finger, a longer flap is required than before. Here, we introduce the oblique extended reverse first dorsal metacarpal artery (FDMA) perforator flap to cover the radial-volar aspect defect of the index finger. A 45-year-old man got injured to the radial-volar defect of PIPJ of the left index finger caused by thermal press machine. The wound was 2 × 1 cm in size, and the joint and bone were exposed. We used FDMA perforator from anastomosis with palmar metacarpal artery at metacarpal neck. Since the defect was extended to the volar side, the flap was elevated by oblique extension to the fourth metacarpal base level. The fascia was included to the flap, and the flap was rotated counterclockwise. Finally, PIPJ was fully covered by the flap. Donor site was primarily closed. After 12 months of operation, the flap was stable without complication and limitation of range of motion. The oblique extended reverse FDMA perforator flap is a reliable method for covering the radial-volar defect of the PIPJ of the index finger. This flap, which also has an aesthetic advantage, will be a good choice for hand surgeons who want to cover the PIPJ defect of the index finger using a nonmicrosurgical option.

## Keywords

- ▶ finger injuries
- ▶ perforator flap
- ▶ hand injuries

## Introduction

Covering the soft-tissue defect of the digits requires various surgical techniques incarnating flaps. These include the transposition flap, rotation flap, cross-finger flap, and vascular island flap methods for using non-

microsurgical flaps for soft-tissue defects in the digits. Among them, the vascular island flap is used when there is not enough soft tissue around the defect, the defect has a large size, or it requires a one-stage procedure or an early mobilization.<sup>1</sup>

received

May 19, 2022

accepted

June 30, 2022

accepted manuscript online

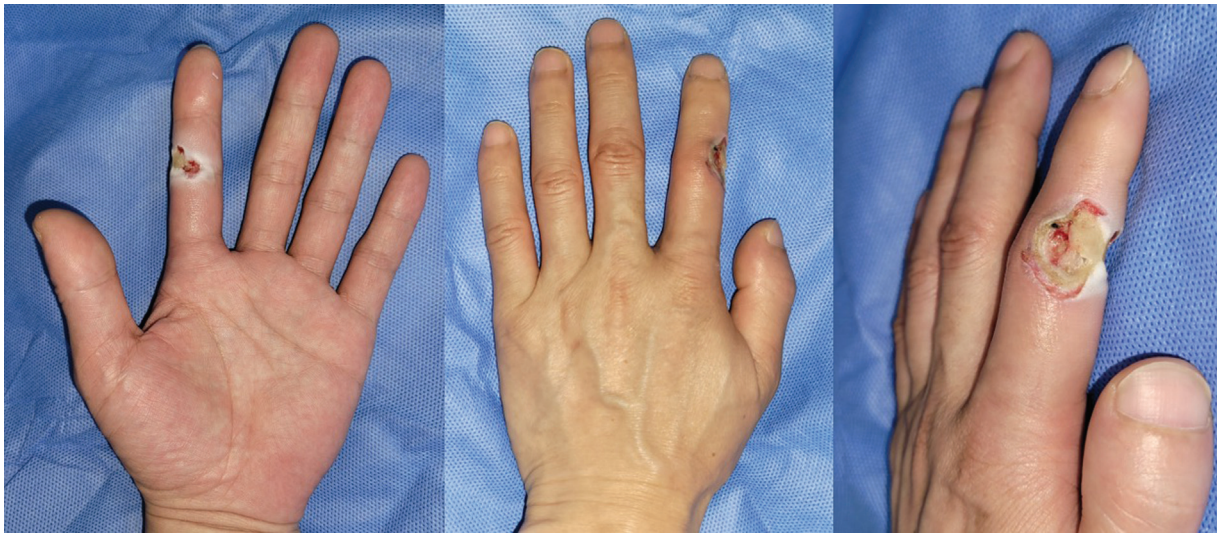
September 7, 2022

DOI <https://doi.org/10.1055/a-1938-1072>.  
eISSN 2234-6171.

© 2022. The Korean Society of Plastic and Reconstructive Surgeons. All rights reserved.

This is an open access article published by Thieme under the terms of the Creative Commons Attribution-NonDerivative-NonCommercial-License, permitting copying and reproduction so long as the original work is given appropriate credit. Contents may not be used for commercial purposes, or adapted, remixed, transformed or built upon. (<https://creativecommons.org/licenses/by-nc-nd/4.0/>)

Thieme Medical Publishers, Inc., 333 Seventh Avenue, 18th Floor, New York, NY 10001, USA



**Fig. 1** The radial-volar defect of the proximal interphalangeal joint of the left index finger was caused by a thermal press machine. It was  $2 \times 1$  cm in size and had exposed the joint and bone.

In 1990, Quaba and Davison first described the dorsal metacarpal artery (DMCA) perforator flap; it consists of an axial patterned vascular island flap that rises from the hand dorsum.<sup>2</sup> Owing to its reliability and versatility, this flap is used as a workhorse for soft-tissue defects of the finger in various locations, such as the dorsal area of the finger, palmar side of the proximal phalanx, and web spaces, to name a few.

The DMCA perforator flap is mainly used to cover defects from the index finger to the little finger using the second to fourth DMCA.<sup>1</sup> In particular, the flap using the first dorsal metacarpal artery (FDMA) is called the FDMA flap; this is mainly used for reconstructing thumb defects.<sup>3</sup> However, to cover the radial-volar defect of the proximal interphalangeal joint (PIPJ) of the index finger, a longer flap is required. Here, we introduced the oblique extended reverse FDMA perforator flap to cover the radial-volar aspect defect of the index finger.

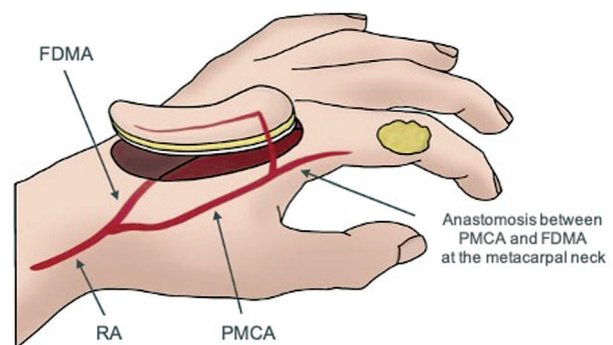
## Case

A 45-year-old man came to the emergency room with an injury to the radial-volar defect of the PIPJ of the left index finger caused by a thermal press machine (► Fig. 1). The wound was  $2 \times 1$  cm in size, and the joint and bone were exposed. He did not want a long operation time and a scar in areas other than the hand; hence, we decided to perform an oblique extended reverse FDMA perforator flap to cover the volar defect of the PIPJ.

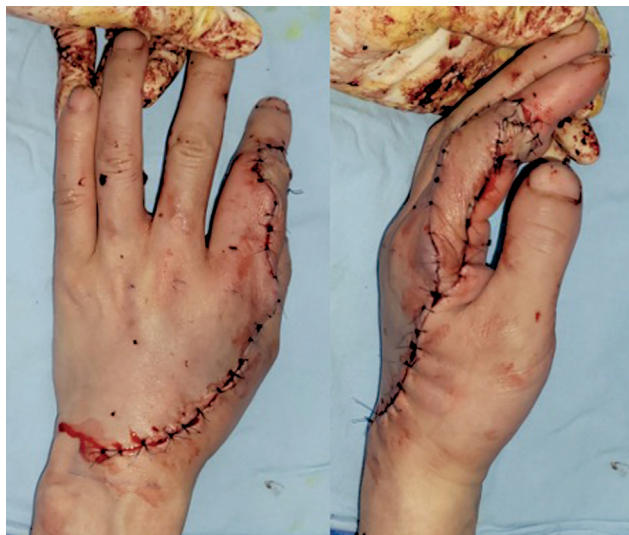
Under general anesthesia, a pinch test of the hand dorsum was performed to confirm that there was sufficient laxity of the skin. Then, the width of the flap was determined enough to close primarily of the donor site. The FDMA perforator at the neck of the second metacarpal bone where the palmar metacarpal artery (PMCA) and FDMA anastomoses was set as the pivot point, and the flap length was determined as the length from the pivot point to the PIPJ defect. The flap size was  $11 \times 1.5$  cm and was obliquely designed from the second metacarpal neck to the fourth metacarpal base, and the proximal margin did not exceed the wrist crease.

A pneumatic tourniquet was inflated, and an incision was made from the proximal of flap. FDMA originated directly from the radial artery, just distal to the extensor pollicis longus tendon. It passes deeper than the second extensor digitorum communis tendon and more superficially than the deep interosseous muscle fascia. After ligation of the FDMA origin, the elevation of the cutaneous adipofascial flap was performed, including the deep interosseous muscle fascia, to prevent damage to the venous outflow (► Fig. 2). The perforator of FDMA was found within the vicinity of the second metacarpal neck, and the flap was elevated by attaching sufficient adipose tissue without skeletonization. Then, the flap was rotated in the counterclockwise direction to release tension and prevent twists. The distal flap was fully covered with the radial-volar defect of the index finger (► Fig. 3). The donor site was then primarily closed.

After reconstruction, the flap remained stable without venous congestion. One year after surgery, the metacarpophalangeal joint had a full range of motion, and the aesthetic result was acceptable (► Fig. 4).



**Fig. 2** Schematic diagram showing intraoperative oblique extended reverse first dorsal metacarpal artery perforator flap elevation. The distal first dorsal metacarpal artery (FDMA) was preserved, and its perforator worked as a single pedicle in the flap. The fascia was included in the flap. PMCA, palmar metacarpal artery; RA, radial artery.



**Fig. 3** Immediate postoperative clinical photo. The flap was elevated by oblique extension to the fourth metacarpal base level, and the defect was fully covered.

## Discussion

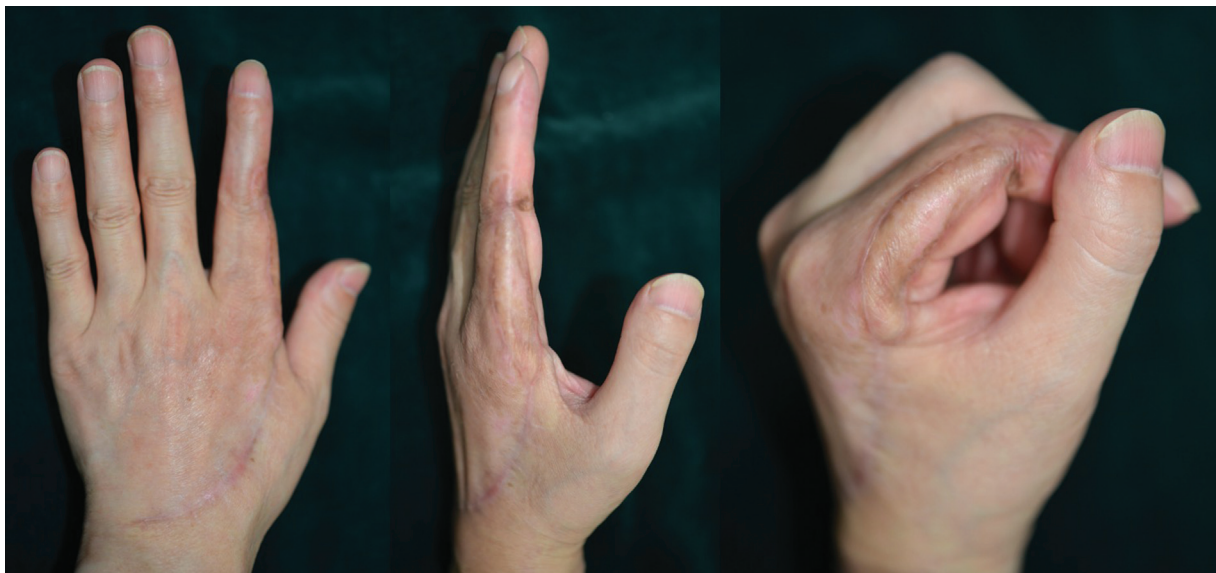The DMCA perforator flap is a flap that uses the DMCA as the pedicle and covers the defect in the finger by elevation from the hand dorsum. The hand dorsum is an appropriate donor site with appropriate color and tissue match for covering soft-tissue defects in the fingers. The DMCA flaps can be performed as a one-stage operation, and the donor is usually capable of primary closure; early mobilization is also possible after the operation.

The use of the first reverse DMCA flap was mentioned in Maruyama's study on eight flaps.<sup>4</sup> Quaba and Davison reported flap elevation using the anastomosed artery between the PMCA and DMCA around the second to fourth metacarpal neck area.<sup>2</sup> Several anatomic studies regarding the DMCA confirmed its constancy and branch variation.<sup>5,6</sup>

The FDMA has been well identified in Sherif's work as the most anatomically constant vessel in the whole DMCA.<sup>7</sup> It originates from the radial artery and usually has three branches. The flap using the FDMA perforator has only been recently studied. di Summa et al introduced the first web space defect as a propeller flap using an FDMA perforator.<sup>8</sup> However, it does not reach the PIPJ or more distal defect since its flap length was too short. Aizawa et al conducted a study to find the FDMA perforator in 29 cadavers.<sup>9</sup> FDMA was found in 27 specimens, and the most distal perforator of FDMA was located mainly in the metacarpal head and neck area.

Unlike soft-tissue defects of the other digits that conventionally use DMCA perforator flaps and FDMA flaps, the radial-volar defect of the PIPJ in the index finger has limited options in nonmicrosurgical flaps because there is no adjacent finger other than the thumb, which is the most important finger in hand function. Hence, this is rarely used as a donor site. In previous studies, Chen et al performed the dorsal homodigital island flap with the dorsal branch of the proper digital artery as the pedicle to cover pulps or tip defects of the index finger.<sup>10</sup> Similarly, Zhang et al used the transposition flap from the dorsum of the proximal phalanx to cover the volar soft-tissue defects of the PIPJ in five cases.<sup>11</sup>

In our case, unlike the aforementioned reverse DMCA flap, the oblique extended reverse FDMA perforator flap is elevated oblique proximally, and the flap spans the second to fourth metacarpal bone. Through this method, it is possible to reach the PIPJ defect that is far from the FDMA perforator of the metacarpal neck area compared with the previously introduced FDMA perforator flaps.<sup>8,9</sup> Venous congestion was prevented through elevation of the fascia. By choosing the perforator at the metacarpal neck area rather than the proximal phalanx level, the arterial supply is also more stable, and the flap is easier to elevate and has fewer complications. Proximal scars of the donor site were covered by the relaxed skin tension lines of the wrist crease, and the vertical scar and flap were biased toward the radial side of



**Fig. 4** After 12 months of operation, the flap was stable without complications.

the hand; hence, the overall scar was not visible on the front dorsal view, which was aesthetically acceptable.

The oblique extended reverse FDMA perforator flap is a reliable method for covering the radial-volar defect of the PIPJ of the index finger. It could reach a more distal wound than the conventional reverse FDMA flaps. This flap, which also has an aesthetic advantage, will be a good choice for hand surgeons who want to cover the PIPJ defect of the index finger using a nonmicrosurgical option.

#### Patient Consent

The patient provided written informed consent for the publication and the use of his images.

#### Ethical Approval

The study was approved by the Institutional Review Board of the Catholic Medical Center (IRB No. UC22ZASI0055). Patient photographic consent was obtained in written form provided by authors' institution.

#### Authors' Contributions

Conceptualization: J. K. Resources: S. N. J. Supervision: S. N. J. Visualization: S. N. J., J. K. Writing – original draft: J. K., J. L. Writing – review and editing: S. N. J., B. F. S.

#### Conflict of Interest

None declared.

#### Acknowledgment

None.

#### References

- 1 Sebastin SJ, Mendoza RT, Chong AKS, et al. Application of the dorsal metacarpal artery perforator flap for resurfacing soft-tissue defects proximal to the fingertip. *Plast Reconstr Surg* 2011;128(03):166e–178e
- 2 Quaba AA, Davison PM. The distally-based dorsal hand flap. *Br J Plast Surg* 1990;43(01):28–39
- 3 Couceiro J, Sanmartín M. The Holevich flap revisited: a comparison with the Foucher flap, case series. *Hand Surg* 2014;19(03):469–474
- 4 Maruyama Y. The reverse dorsal metacarpal flap. *Br J Plast Surg* 1990;43(01):24–27
- 5 Yang D, Morris SF. Vascular basis of dorsal digital and metacarpal skin flaps. *J Hand Surg Am* 2001;26(01):142–146
- 6 Earley MJ, Milner RH. Dorsal metacarpal flaps. *Br J Plast Surg* 1987;40(04):333–341
- 7 Sherif MM. First dorsal metacarpal artery flap in hand reconstruction. I. Anatomical study. *J Hand Surg Am* 1994;19(01):26–31
- 8 di Summa PG, Davies K, Hart A. The first dorsal metacarpal propeller perforator (FDMP) flap for finger reconstruction. *Case Reports Plast Surg Hand Surg* 2020;7(01):94–97
- 9 Aizawa T, Hirayama T, Kiyosawa T, Kobayashi Y. First dorsal metacarpal artery perforator-based propeller flap: functional anatomy and clinical application in soft-tissue defects of the dorsal hand and digits. *Surg Radiol Anat* 2022;44(02):215–221
- 10 Chen C, Tang P, Zhang X. Sensory reconstruction of a finger pulp defect using a dorsal homodigital island flap. *Plast Reconstr Surg* 2012;130(05):1077–1086
- 11 Zhang X, Shao X, Zhu M, Jiang R, Feng Y, Ren C. Repair of a palmar soft tissue defect of the proximal interphalangeal joint with a transposition flap from the dorsum of the proximal phalanx. *J Hand Surg Eur Vol* 2013;38(04):378–385