








Reconstruction of Multiple Digital Defects by Temporary Syndactylization Using a Lateral Arm Free Flap

Sae Hwi Ki, MD, PhD^{1,2}  Jin Myung Yoon, MD¹  Tae Jun Park, MD¹  M. Seung Suk Choi, MD³ 
Min Ki Hong, MD¹ 

¹ Department of Plastic and Reconstructive Surgery, Inha University Hospital, Incheon, People's Republic of Korea

² Department of Plastic and Reconstructive Surgery, School of Medicine, Inha University, Incheon, People's Republic of Korea

³ Department of Plastic and Reconstructive Surgery, Hanyang University Guri Hospital, Guri-si, Gyeonggi-do, South Korea

Address for correspondence Sae Hwi Ki, MD, PhD, Department of Plastic and Reconstructive Surgery, Inha University School of Medicine, 27 Inhang-ro, Jung-gu, Incheon, 400-711, People's Republic of Korea (e-mail: mdkee0923@gmail.com).

Arch Plast Surg 2022;49:745–749.

Abstract

Background Soft tissue defects of the multiple finger present challenges to reconstruction surgeons. Here, we introduce the use of a lateral arm free flap and syndactylization for the coverage of multiple finger soft tissue defects.

Methods This retrospective study was conducted based on reviews of the medical records of 13 patients with multiple soft tissue defects of fingers ($n=33$) that underwent temporary syndactylization with a microvascular lateral arm flap for temporary syndactylization from January 2010 to December 2020. Surgical and functional outcomes, times of flap division, complications, and demographic data were analyzed.

Results Middle fingers were most frequently affected, followed by ring and index fingers. Mean patient age was 43.58 years. The 13 patients had suffered 10 traumas, 2 thermal burns, and 1 scar contracture. Release of temporary syndactyly was performed 3 to 9 weeks after syndactylization. All flaps survived, but partial necrosis occurred in one patient, who required a local transposition flap after syndactylization release. The mean follow-up was 15.8 months.

Conclusion Coverage of multiple finger defects by temporary syndactylization using a free lateral arm flap with subsequent division offers an alternative treatment option.

Keywords

- ▶ soft tissue defects
- ▶ multiple defects
- ▶ traumatic injury
- ▶ amputation
- ▶ free flap

Introduction

Treatment of multiple soft tissue defects of the fingers is a much-debated topic. Depending on the locations and sizes of defects, several reconstructive options are available. In previous studies, multiple soft tissue defects of fingers were

reconstructed using regional flaps, multiple homodigital island flaps, multiple free flaps, and by syndactylization with various flaps such as venous free flap, fasciocutaneous flap, or thoracodorsal perforator flap.^{1–4} In this study, we introduce an alternative treatment option to deal with multiple soft tissue defects of the fingers, namely, coverage

received

April 14, 2022

accepted after revision

July 22, 2022

DOI <https://doi.org/10.1055/a-1938-0691>.

10.1055/a-1938-0691.

eISSN 2234-6171.

© 2022. The Korean Society of Plastic and Reconstructive Surgeons. All rights reserved.

This is an open access article published by Thieme under the terms of the Creative Commons Attribution-NonDerivative-NonCommercial-License, permitting copying and reproduction so long as the original work is given appropriate credit. Contents may not be used for commercial purposes, or adapted, remixed, transformed or built upon. (<https://creativecommons.org/licenses/by-nc-nd/4.0/>)

Thieme Medical Publishers, Inc., 333 Seventh Avenue, 18th Floor, New York, NY 10001, USA

with a single free lateral arm flap with temporary syndactylization and secondary release.

Methods

Patients with multiple finger defects treated with lateral arm fasciocutaneous free flaps were identified by retrospective chart review. Flaps were used to cover whole hand defects, and thus, digits were syndactylized temporarily. Two days after free flap placement, patients were encouraged to excise finger joints, except those temporary fixated with K-wire, but to move connected digits synchronously to prevent flap detachment. Syndactylized fingers were divided when flaps completely healed. Patient demographics, flap survival rate, functional outcomes, times between syndactylization and flap division, and complications were analyzed.

Results

Thirteen patients with soft tissue defects on 33 fingers were operated on from January 2010 to December 2020 for multiple digital soft tissue defects using a lateral arm fasciocutaneous free flap (►Table 1). The affected digits were 12 long, 9 ring, 7 index, and 2 little fingers and a thumb. Mean patient age was 43.58 years (range: 26–59 years), and the male to female ratio was 5.5 to 1. Etiologies were trauma in 10 patients, thermal burns in 2 patients, and joint scar contracture after trauma in 1 patient. Temporary syndactylies were divided 3 to 9 weeks after syndactylization, and mean time to division was 6.62 weeks. All flaps survived. Partial necrosis occurred in one patient, who received flap transposition and thinning during syndactyl division. None of the patients developed stiffness of wrist, elbow, or shoulder. After follow-up, range of motion (ROM) of the metacarpophalangeal joint (MPJ) was 90 degrees. ROMs of proximal interphalangeal joints (PIPJ) and distal interpha-

langeal joints (DIPJ) were limited to extents that depended on etiology and defect size. Postoperative sensory recovery was poor (>15 mm as determined by static and moving 2-point discrimination tests) (►Table 2). Mean follow-up was 15.8 months (4–28 months).

Case 1 (►Fig. 1)

A 26-year-old man suffered soft tissue defects on the dorsum of the PIP joint of the index and middle finger of the right hand caused by a grinder. After complete debridement, which involved injury of the extensor central slip, both PIP joints were exposed. Defects of the index and middle finger were covered with an $8 \times 3 \text{ cm}^2$ lateral arm fasciocutaneous free flap for temporary syndactylization. The radial proper digital artery was connected to the posterior radial collateral artery, and a dorsal vein was connected to vena comitantes. The radial side nerve of the index finger was connected to the posterior antebrachial cutaneous nerve (PABCN) of the lateral arm free flap. Reconstruction of the injured extensor central slip was covered with fascial tissue of the free flap. The flap survived completely. Syndactyl was divided 6 weeks after free flap placement. At his 9-month follow-up, the patient had full ROM of the PIPJ and slight ROM limitation of the DIPJ of the index finger. Sensory recovery of the index and middle finger was more than 15 mm as determined by the moving two-point discrimination test. The patient was able to use his right hand for normal activities and was satisfied with the aesthetic result.

Case 2 (►Fig. 2)

A 59-year-old man suffered a crushing amputation injury of all fingers of his left hand while using an industrial machine. Initially, we replanted and revascularized all fingers. The remaining wound included bone exposure of the index, middle, and ring fingers and was covered with a lateral arm fasciocutaneous free flap for temporary

Table 1 Patient data

Sex/Age	Injured fingers	Specific site	Cause of defect	Flap size (cm ²)	Timing of division (wk)
M/48	Thumb, 2F, Lt.	Thumb IPJ, index P1	Crushing injury with amputation	7×3	8
M/30	3, 4F, Lt	Fingertip	Burn	7×2.5	9
F/52	2, 3, 4F, Rt	Dorsum of middle P.	Burn	6.5×3.5	4
M/31	3, 4F, Lt	Dorsum of proximal P.	Traumatic injury	6×2.5	8
M/29	Thumb, 2, 3F, Rt.	Dorsum of fingers	Traumatic injury with amputation	10×3	6
M/40	2, 3, 4F, Lt	PIPJ. amputation	Crushing injury with amputation	8×3	6
M/59	2, 3, 4F, Rt.	Volar of proximal P.	Traumatic injury with amputation	8×3.5	6
M/40	3, 4F, Lt.	Fingertip pulp	Crushing injury with amputation	6×3	6
M/39	3, 4F, Rt.	PIPJ. amputation	Traumatic injury with amputation	5×2	8
M/43	3, 4, 5F, Rt.	Volar of middle P.	Traumatic injury with amputation	7.5×2.5	8
M/26	2, 3F, Rt.	Dorsum of PIPJ.	Traumatic injury	8×3	6
F/52	3, 4, 5F, Rt.	Volar of proximal P.	Crushing injury with amputation	6×3	8
M/34	2, 3, 4F Lt.	Volar of PIPJ	Scar contracture	8×2.5	3

Abbreviations: F, finger; IPJ, interphalangeal joint; Lt, left; P, phalanx; PIPJ, proximal interphalangeal joint; Rt, right.

Table 2 Sensory recoveries and ROMs after surgery

Sex/Age	Sensory recovery Static/moving 2-PD (mm)	ROM after surgery (degree)
M/48	Thumb: 15/13 2F: 15/15	Thumb MPJ: 0–30 2F MPJ: 0–80
M/30	Above 15	3F, 4F IPJ: 0–80
F/52	None	2F, 3F, 4F IPJ: 0–70
M/31	Above 15/ 13	3F PIPJ: 0–60 4F PIPJ: 0–70 3, 4F MPJ: 0–90 degree
M/29	Above 15	Thumb IPJ: 0–30 2F MPJ: 0–30 3F PIPJ: 0–30
M/40	2,3,4F: 15/13	2F PIPJ: 0–50, MPJ: 0–90 3F PIPJ: 0–45, MPJ: 0–80 4F MPJ: 0–60
M/59	3F:13/11 4F: Above 15/13	3, 4F PIPJ: 0–20 3, 4F MPJ 0–70
M/40	3F: Above 15 4F: 13/11	3, 4F MPJ: 0–90
M/39	3,4F: 15/13	3F DIPJ: 0, PIPJ 0–90 4F DIPJ 0–30, PIPJ 0–90
M/43	3,4F: 13/11 5F: Above 15	3F DIPJ: 0, PIPJ: 0–90 4F DIPJ: 0–60, PIPJ: 0–90 5F DIPJ: 0–15, PIPJ: 0–90
M/26	Above 15	2F PIPJ: 0–90 3F PIPJ: 0–90
F/52	Above 15	3,4F DIPJ: 0–10, PIPJ finger: 0–10 3,4F MPJ: 0–90
M/34	Above 15	2F PIPJ: 0, DIPJ: 55–70 3F PIPJ: 0, DIPJ: 60 4F PIPJ: 0, DIPJ: 40

Abbreviations: DIPJ, distal interphalangeal joint; F, finger; MPJ, metacarpophalangeal joint; PD, point discrimination; PIPJ, proximal interphalangeal joint; ROM, range of motion.

syndactylization. The artery of the flap was anastomosed to the digital artery of the ring finger and the vein of the flap was anastomosed to a dorsal subcutaneous vein. The ulnar side nerve of the ring finger was connected to the PABCN of the lateral arm free flap. Six weeks after free flap placement, the ring finger was separated and 2 weeks later, index and middle fingers were divided. The patient was able to perform active and passive motion exercises. At his 2-year follow-up, he had full ROM of the MPJ but restricted ROM of the PIPJ because the amputation occurred near the PIPJ. Sensory recovery was poor in index, middle, and ring fingers (>15 mm as determined by the moving 2-point discrimination test).

Discussion

Multiple tissue defects of fingers still present a challenge to reconstructive surgeons because of the paucity of adjacent tissues. Various methods such as skin graft, amputation, and

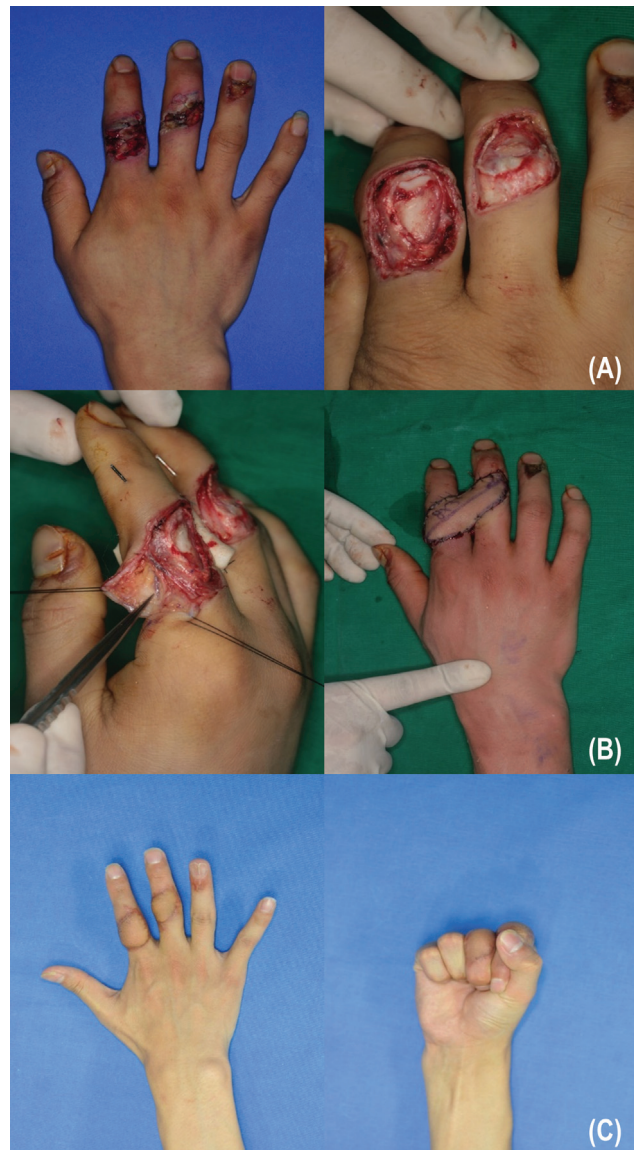


Fig. 1 Case 1. (A) Soft tissue defects of the dorsum of index and middle fingers (Lt). Full-thickness skin defect and joint exposure (Rt). (B) Recipient artery and vein of the radial side of index (Lt). A 8×3 cm²-sized lateral arm flap was used for syndactylization (Rt). (C). Postoperative dorsal view after flap division (Lt). Palmar view (Rt). Lt, left; Rt, right.

local, regional, and free flaps have been to cover single digit defects. The cross-finger flap is a popular option because elevation is straightforward, and it does not require microsurgical skills.¹ The main disadvantage of regional flaps, like cross finger flaps, is joint stiffness, which is inevitable due to immobilization before flap division. Reverse digital artery island and homodigital island flaps are reserved for soft tissue coverage of the fingertip and present risks of digital nerve damage and venous congestion.^{2,3} Flaps based on the dorsal metacarpal artery can be used to cover defects around the PIPJ and are useful, as they permit single-stage reconstruction without the need for microanastomosis.^{4,5} However, in cases of multiple finger tissue defects, the use of the dorsal metacarpal island flap artery is limited by its size. Microsurgical options for single finger defects include

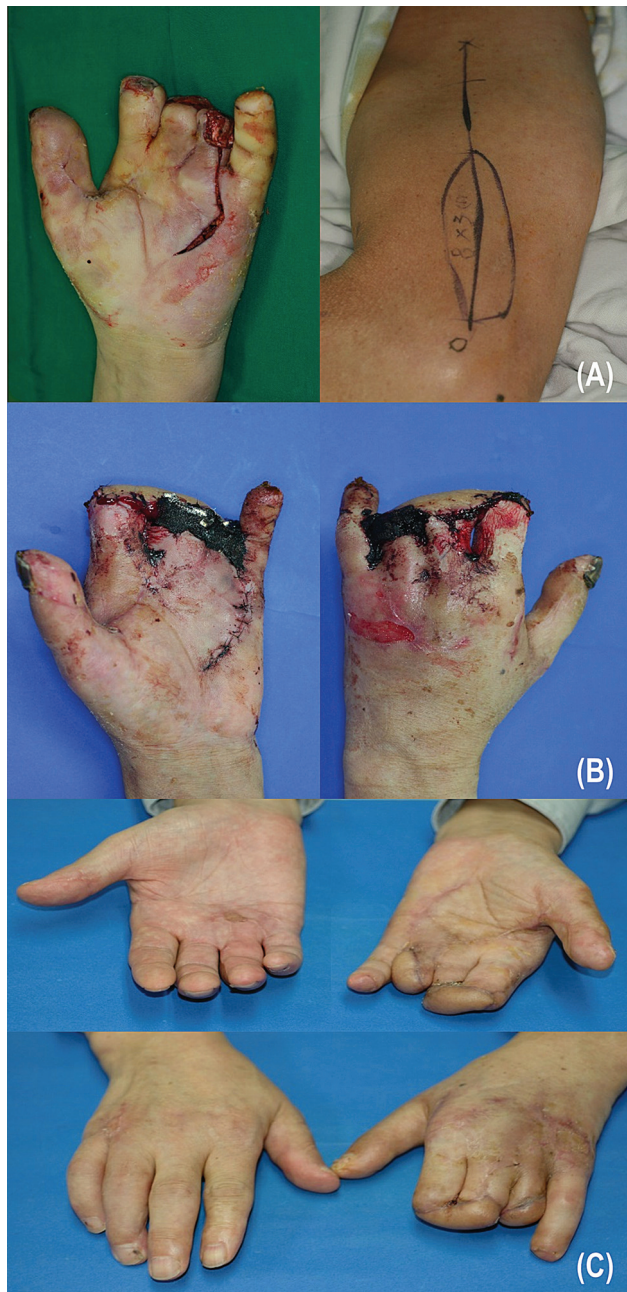

Fig. 2 Case 2. (A). Soft tissues defect of the index, middle, and ring fingers (Lt). A 8×3 cm²-sized lateral arm free flap (Rt). (B) Temporary syndactylization. Volar view (Lt). Dorsal view (Rt). (C) At 6 weeks after the free flap, the ring finger was separated. Volar view (upper). Dorsal view (lower). Lt, left; Rt, right.

arterialized venous flaps⁶ and free toe pulp flaps.⁷ Although high success rates have been reported for arterialized venous flaps, their use for finger defects is limited by safety concerns and flap monitoring difficulties.⁶ The use of a partial pulp tissue as a small free flap, as popularized in Korea and subsequently in other Asian countries, provides an elegant means of reconstructing fingertip defects and can effectively restore sensory function.⁷ However, this tissue is not suitable for covering larger defects and is not considered the option of first choice for finger dorsal defects. Although multiple free flaps can be used to cover

multiple digit defects, the procedure is lengthy and requires advanced microsurgical skills.

Pedicated groin flaps and pedicated abdominal flaps have been used to cover larger hand defects or multiple defects.⁸ Despite being a useful tool in the reconstructive surgeon armamentarium these flaps have several disadvantages, namely, bulkiness, discomfort, joint stiffness, the need for secondary surgery, and an inability to elevate the hand. Most of our patients were potential candidates for a pedicated groin flap because several defects affected single hands, but this would have required temporary immobilization and secondary procedure. Coverage of multiple digital defects with a fasciocutaneous free flap has many advantages as compared with coverage using a groin flap because patients can move the affected arm freely and elevate it to reduce postoperative swelling, and thus, are not subject to the substantial discomfort associated with the pedicated groin flap. Furthermore, joint stiffness was not a concern for our patients because unaffected joints were spared from immobilization.

Several types of fasciocutaneous free flaps, such as the anterolateral thigh flap, the thoracodorsal perforator flap, and the groin free flap, can be used to cover multiple digital defects. Although these flaps are available and popular among hand surgeons, they are too thick for covering finger defects and require additional thinning.^{9,10} Therefore, we use lateral arm fasciocutaneous free flaps for reconstruction because they are relatively thin, have constant vascular anatomy, and artery sizes are suitable for anastomoses to digital arteries.

Sensory recovery at fingertips is important after reconstructive surgery and this favors the use of reverse digital artery island flaps, homodigital neurovascular island flaps, step advancement island flaps, or toe pulp free flaps.^{1,11-14} Ideally, multiple toe pulp flap reconstruction should be used in patients with multiple fingertip defects. However, the single patient with such defects would have needed three toe pulp free flaps, which would have been challenging even for an experienced microsurgeon.

Sensory recovery results for our patients were disappointing (static 2-point discrimination test > 15 mm). Likewise, previous studies have reported relatively poor sensory recoveries after lateral arm free flap placement.^{15,16} There is some disagreement as to whether the lateral arm flap should be used as a sensory flap, as some authors have reported that the results of coaptation and reinnervation of posterior cutaneous nerves are unfavorable.^{17,18} Therefore, we considered it advisable to apply this surgical method to multiple dorsal defects of fingers rather than to fingertip defects. In our patients, most flaps were applied to the dorsal area of fingers and amputations around the PIP. When sensation be essential, sensate flap, such as sensated partial toe pulp flap would be placed in lateral arm free flap.

This retrospective study shows that a single lateral arm free flap provides useful coverage of multiple digital defects when used for temporary syndactylization. We believe the described method provides an alternative means of reconstructing multiple dorsal digital defects.

Availability of Data and Materials

Data were obtained from medical records, in strict accordance with the privacy policy and ethical code of our institute.

Ethical Approval and Consent to Participate

The study involved standard treatment regimens and approved by the Institutional Review Board (IRB NO. 2022-03-040). All procedures were performed after obtaining informed consent from all patients. The study was performed in accordance with the Declaration of Helsinki.

Patient Consent

Patients provided written informed consent for the publication and the use of their images.

Authors' Contributions

Sae Hwi Ki conceptualized the study. Tae Jun Park and Jin Myung Yoon were involved in data curation. Tae Jun Park and Jin Myung Yoon contributed to investigation. Sae Hwi Ki supervised the study. Sae Hwi Ki and Choi MSS were involved in writing—original draft.. Choi MSS and Min Ki hong contributed to writing—review and editing.

Financial Support and Sponsorship

None.

Conflicts of Interest

Sae Hwi Ki is an editorial board member of the journal but was not involved in the peer reviewer selection, evaluation, or decision process of this article. No other potential conflicts of interest relevant to this article were reported.

Acknowledgments

There is nothing special acknowledgments.

References

- Paterson P, Titley OG, Nancarrow JD. Donor finger morbidity in cross-finger flaps. *Injury* 2000;31(04):215–218
- Han SK, Lee BI, Kim WK. The reverse digital artery island flap: clinical experience in 120 fingers. *Plast Reconstr Surg* 1998;101(04):1006–1011, discussion 1012–1013
- Arsalan-Werner A, Brui N, Mehling I, Schlageter M, Sauerbier M. Long-term outcome of fingertip reconstruction with the homodigital neurovascular island flap. *Arch Orthop Trauma Surg* 2019; 139(08):1171–1178
- Gregory H, Heitmann C, Germann G. The evolution and refinements of the distally based dorsal metacarpal artery (DMCA) flaps. *J Plast Reconstr Aesthet Surg* 2007;60(07):731–739
- Vuppalapati G, Oberlin C, Balakrishnan G. “Distally based dorsal hand flaps”: clinical experience, cadaveric studies and an update. *Br J Plast Surg* 2004;57(07):653–667
- Woo SH, Kim KC, Lee GJ, et al. A retrospective analysis of 154 arterialized venous flaps for hand reconstruction: an 11-year experience. *Plast Reconstr Surg* 2007;119(06):1823–1838
- Lee DC, Kim JS, Ki SH, Roh SY, Yang JW, Chung KC. Partial second toe pulp free flap for fingertip reconstruction. *Plast Reconstr Surg* 2008;121(03):899–907
- Al-Qattan MM, Al-Qattan AM. Defining the indications of pedicled groin and abdominal flaps in hand reconstruction in the current microsurgery era. *J Hand Surg Am* 2016;41(09):917–927
- Adani R, Tarallo L, Marcoccio I, Cipriani R, Gelati C, Innocenti M. Hand reconstruction using the thin anterolateral thigh flap. *Plast Reconstr Surg* 2005;116(02):467–473, discussion 474–477
- Kim SW, Lee HJ, Kim JT, Kim YH. Multiple-digit resurfacing using a thin latissimus dorsi perforator flap. *J Plast Reconstr Aesthet Surg* 2014;67(01):74–80
- Sérane-Fresnel J, Lafosse T, Amsallem L, Chaves C, Delpit X, Chassat R, Masméjean EH. Fingertip reconstruction by palmar bipedicular island flap in long fingers (modified neurovascular Tranquilli-Leali flap): A dual-center study. *Hand Surg Rehabil* 2020 Feb;39(01):59–64
- Atasoy E, Ioakimidis E, Kasdan ML, Kutz JE, Kleinert HE. Reconstruction of the amputated finger tip with a triangular volar flap. A new surgical procedure. *J Bone Joint Surg Am* 1970;52(05):921–926
- Katz RD. The anterograde homodigital neurovascular island flap. *J Hand Surg Am* 2013;38(06):1226–1233
- Evans DM, Martin DL. Step-advancement island flap for fingertip reconstruction. *Br J Plast Surg* 1988;41(02):105–111
- Ki SH. Lateral arm free flap with preservation of the posterior antebrachial cutaneous nerve. *Ann Plast Surg* 2016;76(05):517–520
- Ulusal BG, Lin YT, Ulusal AE, Lin CH. Free lateral arm flap for 1-stage reconstruction of soft tissue and composite defects of the hand: a retrospective analysis of 118 cases. *Ann Plast Surg* 2007; 58(02):173–178
- Hage JJ, Woerdeman LA, Smeulders MJ. The truly distal lateral arm flap: rationale and risk factors of a microsurgical workhorse in 30 patients. *Ann Plast Surg* 2005;54(02):153–159
- Hennerbichler A, Etzer C, Gruber S, Brenner E, Papp C, Gaber O. Lateral arm flap: analysis of its anatomy and modification using a vascularized fragment of the distal humerus. *Clin Anat* 2003;16(03):204–214