

# EUS-guided radiofrequency ablation of pancreatic/peripancreatic tumors and oligometastatic disease: an observational prospective multicenter study



## Authors

Mariana Figueiredo Ferreira<sup>1,2</sup>, Rodrigo Garces-Duran<sup>3</sup>, Pierre Eisendrath<sup>2</sup>, Jacques Devière<sup>1</sup>, Pierre Deprez<sup>3</sup>, Laurent Monino<sup>3</sup>, Jean-Luc Van Laethem<sup>\*1</sup>, Ivan Borbath<sup>\*3</sup>

## Institutions

- 1 Department of Gastroenterology, Hepatopancreatology and Digestive Oncology, Erasme University Hospital, Université Libre de Bruxelles, Belgium
- 2 Department of Gastroenterology, Hepatopancreatology and Digestive Oncology, Saint-Pierre University Hospital, Université Libre de Bruxelles, Belgium
- 3 Department of Gastroenterology, Hepatopancreatology and Digestive Oncology, Cliniques Universitaires St. Luc, Université Catholique de Louvain, Belgium

submitted 2.5.2022

accepted after revision 9.8.2022

published online 10.8.2022

## Bibliography

Endosc Int Open 2022; 10: E1380–E1385

DOI 10.1055/a-1922-4536

ISSN 2364-3722

© 2022. The Author(s).

This is an open access article published by Thieme under the terms of the Creative Commons Attribution-NonDerivative-NonCommercial License, permitting copying and reproduction so long as the original work is given appropriate credit. Contents may not be used for commercial purposes, or adapted, remixed, transformed or built upon. (<https://creativecommons.org/licenses/by-nc-nd/4.0/>)

Georg Thieme Verlag KG, Rüdigerstraße 14,  
70469 Stuttgart, Germany

## Corresponding author

Mariana Figueiredo Ferreira, MD, Department of Gastroenterology, Hepatopancreatology and Digestive Oncology Erasme Hospital, 808 Route de Lennik, 1070 Brussels, Belgium  
Fax: +3225556559  
[mariana.figueiredo.pro@gmail.com](mailto:mariana.figueiredo.pro@gmail.com)

## ABSTRACT

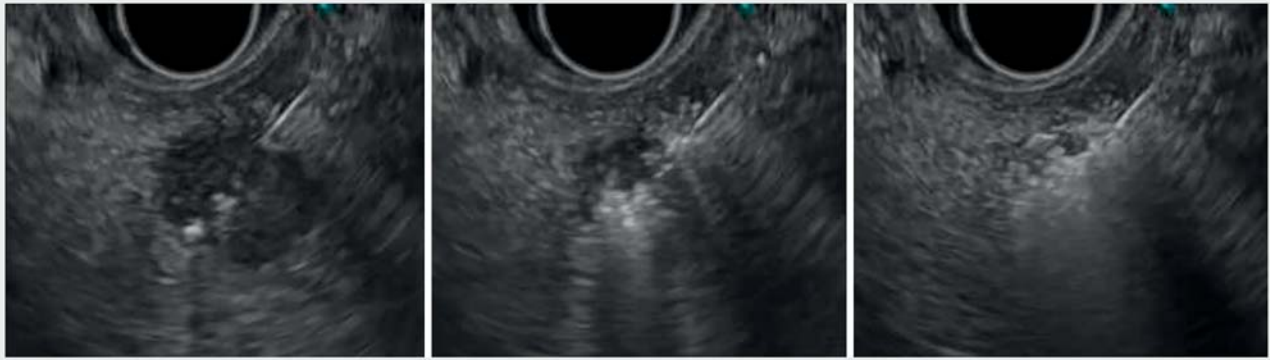
**Background and study aims** Endoscopic ultrasound-guided radiofrequency ablation (EUS-RFA) is an emerging and minimally invasive technique that seems promising for treatment of focal pancreatic and peripancreatic lesions. Our aim was to prospectively evaluate the feasibility, safety, and technical and clinical success of pancreatic and extra-pancreatic EUS-RFA.

**Patients and methods** We prospectively collected clinical and technical data for all patients who underwent EUS-RFA at two Belgian academic centers from June 2018 to February 2022. Feasibility, adverse events (AEs), and follow-up were also assessed.

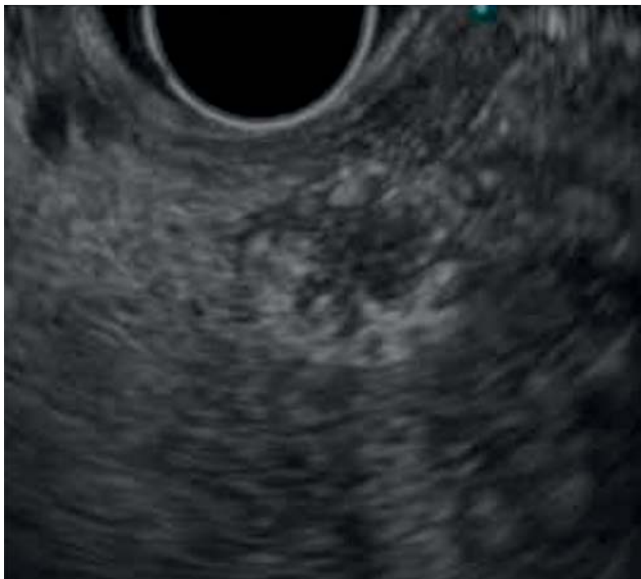**Results** Twenty-nine patients were included, accounting for 35 lesions: 10 non-functioning neuroendocrine tumors (29%), 13 pancreatic insulinomas (37%), one adenocarcinoma (3%), and 11 intra-pancreatic and extra-pancreatic metastatic lesions (31%). Technical success was achieved in 100% of cases, with a median of three power applications per lesion (interquartile range 2). The majority of patients (59%) presented no collateral effects, three (10.3%) developed non-severe acute pancreatitis, and four (14%) had mild abdominal pain. At 6 months follow-up (n=25), 36% of patients showed radiological complete response, 16% presented a significant partial response and 48% showed < 50% decrease in diameter. At 12 months (n=20), 30% showed complete necrosis and 15% >50% decrease in diameter. Hypoglycemia related to insulinoma was immediately corrected in all 13 cases, with no recurrence during follow-up.

**Conclusions** EUS-RFA is feasible, safe, and effective for treatment of pancreatic and peripancreatic tumors. Larger and longer multicenter prospective studies are warranted to establish its role in management of focal pancreatic lesions and oligometastatic disease. Symptomatic insulinoma currently represent the best indication.

\* These authors share last authorship.



► **Fig. 1** The RFA 19G tip of the needle is inserted into the target lesion under direct EUS visualization to reach its distal part. The generator is then activated to deliver 50 watts of energy, resulting in lesion ablation. This process is interrupted when echogenic bubbles appear (“steam popping”) at the proximal part of the lesion. Ablated tissue immediately becomes hyperechoic. Additional needle passes may be performed and the tip of the needle may be repositioned as much as needed so as to cover the most target tissue possible.



► **Fig. 2** Final result, immediately after EUS-RFA application.

## Introduction

The incidence of pancreatic tumors has been increasing, at least partly due to the latest advances in the field of diagnostic imaging, which now more often reveal asymptomatic pancreatic lesions (“incidentalomas”) [1, 2]. Currently, surgical resection still remains the only curative treatment option for focal pancreatic lesions, including pancreatic ductal adenocarcinomas (PDACs), pancreatic neuroendocrine tumors (pNETs), pancreatic cystic lesions, and even small metastases from other specific cancers such as renal cell carcinoma (RCC). However, when dealing with non-functional small pNETs, surgery can be considered too hazardous for treating a relatively benign pathology and surveillance can be an alternative strategy [3].

Pancreatic metastases are still fairly rare, but when detected, RCC remains the most common primary tumor [4]. Local thera-

pies can be considered as part of the standard treatment in this context [5], with pancreatic resection still being the prevailing option to control pancreatic metastasis and avoid compressive symptoms. However, not all patients are fit enough to undergo pancreatectomy [4]. EUS-RFA seems to be a promising alternative for hyper-vascularized tumors such as RCCs, as suggested by recently published reports [6].

Also, when it comes to more aggressive lesions or metastatic ones of uncertain behavior, the affected patients are often frail and not eligible for surgery, which is why a less invasive and locally ablative technique could be of major interest for these situations, too.

Endoscopic ultrasound-guided radiofrequency ablation (EUS-RFA) is a recently developed technique that allows the delivery of specific amounts of energy directly inside a target neoplastic lesion, resulting in both coagulative necrosis and enhancement of the local immune response within the tumor [7]. To date, the safety, feasibility, and effectiveness of this technique in treatment of pancreatic and peripancreatic tumors has been suggested by a limited number of small case series (maximum 31 patients) [8, 9].

In this case series, we report 35 cases of pancreatic and extra-pancreatic lesions treated with EUS-RFA in 29 patients, with the aim of evaluating the feasibility, safety, and technical and clinical success of the technique in our two academic centers.

## Patients and methods

### Study design

This was a prospective, multicenter, observational study (local Ethics Committee approval number P2019/457/B406201941502). We prospectively collected and analyzed clinical and technical data for all consecutive patients treated with EUS-RFA between June 2018 and February 2022 at two Belgian academic hospitals (Erasmus University Hospital and Cliniques Universitaires Saint-Luc). Statistical descriptive analyses

were performed using SPSS software version 25 (IBM SPSS, New York, United States).

The Institutional Ethics Committees of all centers approved the study protocol, which was created in accordance with ethical guidelines of the 1975 Declaration of Helsinki. Prior signed consent was obtained in all cases. All authors had access to the gathered data and approved the final manuscript.

## Patient selection

All indications for surgical or endoscopic management were discussed by an expert multidisciplinary board (including gastroenterologists, surgeons, radiologists, oncologists and pathologists).

All included patients had histologically proven pNETs (functional or non-functional), PDAC or metastatic lesions. All the lesions were  $\leq 30$  mm and periluminal, located in the pancreatic gland or in close proximity to it. Disease stage and tumor histologic differentiation or grade (according to Ki-67 index and mitotic count) were assessed whenever appropriate, according to European Society of Medical Oncology guidelines [10, 11].

Patients with at least one of the following criteria were considered ineligible for EUS-RFA and were thus excluded: large (peri-)pancreatic tumors ( $> 3$  cm), multiple metastatic disease, progressive uncontrolled oncological disease, biliary obstruction without endoscopic biliary drainage, general contraindications for general anesthesia, uncontrolled infections and pacemaker.

## Technical aspects

The procedures were routinely performed by experienced endoscopists (experience with  $> 200$  EUS examinations [12]), using a linear EUS scope (GFUCT180, Olympus, Hamburg, Germany). Patients were either under deep sedation or general anesthesia and they all received both infection and pancreatitis prophylaxis (intravenous antibiotic and rectal nonsteroidal anti-inflammatory, respectively), prior to treatment.

EUS-RFA was performed according to the procedure description by Barthet et al [7], using a 19-gauge internally cooled electrode needle with 10-mm exposed tip, (EUSRA) and at least one power application of 50 watts was performed, through a VIVA COMBO\* RF generator (Taewoong/STARMED, Koyang, Korea-imported in Belgium by Prion medical). The needle was carefully inserted into the target lesion, while maintaining a distance of at least 2 mm from the bilio-pancreatic ducts and vascular structures, after Doppler assessment (► Fig. 1). The procedure was considered complete when echogenic bubbles occurred (“steam popping”), meaning that the tissue impedance had increased to more than 100 Ohms (► Fig. 2). As there still is no standard protocol for procedure duration, ablation time was not predetermined and varied between patients.

## Follow-up

All patients remained in the hospital for observation for at least 24 to 48 hours. Clinical follow-up was planned at 1, 6, and 12 months. Imaging follow-up with magnetic resonance imaging, computed tomography (CT) scan or EUS was systematically planned at 6 and 12 months after the procedure.

## Outcomes

Technical success was defined by successful introduction of the needle within the target lesions with safe margins from the surrounding vital structures (to prevent any thermal damages) and application of RFA based on impedance [7].

Clinical success was defined as a complete (100%) or significant ( $> 50\%$ ) reduction in lesion diameter and/or equivalent development of a hypodense region (necrosis) on CT scan, in case of non-functional pNETs, PDACs or metastatic lesions. In case of functional pNETs, improvement in hormone-related symptoms was also considered, in keeping with the previously cited criteria [7].

Secondary AEs also were documented. These included bleeding (if blood transfusion and/or local treatment by endoscopy or arterial embolization was required), acute pancreatitis (defined accordingly to the revised Atlanta classification [13]), post-procedure pain or fever ( $> 37.5^\circ\text{C}$ ) and any other noticeable event observed during the follow-up period.

## Results

A total of 29 patients were enrolled, accounting for 35 lesions treated (► Table 1). The studied population included 13 men (45%) and 16 women (55%), with a median age of 59 years old (interquartile range [IQR] 29). Treatment indications were diverse, ranging from PDAC (2.9%), non-functioning pNET (28.6%) and highly symptomatic pancreatic insulinoma (37.1%), to pancreatic renal and pulmonary cancer metastasis (28.6% and 2.9%, respectively) and, finally, one gastric cancer left adrenal metastasis (2.9%). With regard to pNET cases, the majority (83%) were low-grade lesions ( $\text{ki67} < 3\%$ ).

Two patients harbored multiple pancreatic lesions: the first presented with six RCC metastatic lesions (ranging from 7 to 12 mm, most located in the pancreatic head), treated consecutively in two EUS-RFA sessions within a 6-month interval; the second patient presented with two non-functioning pNETs (measuring 7 and 12 mm, located in the pancreatic body), both treated in the same EUS-RFA session.

The technical and clinical response/success were evaluated independently for each lesion.

Mean lesion size was 14.4 mm (SD 6.2), range from 6.5 to 30 mm. Most of them were located in the pancreatic head (54.3%), followed by the pancreatic body (31.4%) and tail (8.6%). There were two other locations, including a peripancreatic lymphadenopathy and, as previously stated, a left adrenal metastatic lesion. Technical success was achieved in 100% of cases, with a median number of three power applications per lesion (IQR 2).

There were no serious AEs observed, with only three mild acute pancreatitis cases (10.3%) reported. Other minor AEs also were documented (► Table 2).

At 6-month follow-up ( $n = 25$ ), 52% of lesions presented radiological signs of significant response, including 36% of cases already showing complete necrosis (► Table 3). There was only one case with no response observed, as the lesion (a RCC metastasis) did not show any signs of shrinkage. Of the 15 pNET

► **Table 1** Baseline characteristics of 35 lesions from 29 included patients.

<b>n = 29 patients</b>	
<b>Hospital</b>	
▪ Cliniques Saint-Luc	19 (65.5%)
▪ CUB Erasme	10 (34.5%)
Median age (y)	59 (IQR 23)
Female patients	16 (55%)
n = 35 lesions	
<b>Indication for procedure</b>	
▪ Functional pNET (insulinoma) <sup>1</sup>	13 (37.1%)
▪ Non-functional pNET <sup>1</sup>	10 (28.6%)
▪ PDAC	1 (2.9%)
▪ Metastatic lesion	11 (31.4%)
Mean lesion size (mm)	14.4 (SD 6.2)
<b>Lesion location</b>	
▪ Pancreatic head	19 (54.3%)
▪ Pancreatic body	11 (31.4%)
▪ Pancreatic tail	3 (8.6%)
▪ Non-pancreatic locations <sup>2</sup>	2 (5.7%)
NET, neuroendocrine tumor; pNET, pancreatic neuroendocrine tumor; PDAC, pancreatic ductal adenocarcinoma.	
<sup>1</sup> Concerning NET lesions, a significant majority (83%) were low-grade lesions (ki67 < 3%), one was an intermediate grade NET (ki67 = 3%–20%) and there were three NETs for which this information was missing in pathology report.	
<sup>2</sup> Lymphadenopathy at site post-distal pancreatectomy (PDAC recurrence) and one left adrenal metastasis.	

► **Table 2** Technical data.

Technical success (n = 35)	100%
Median number of power applications per lesion (n = 35)	3 (IQR 2)
<b>Complication rate (n = 29)</b>	
▪ Mild pain	4 (13.8%)
▪ Mild acute pancreatitis	3 (10.3%)
▪ Other non-severe adverse effects <sup>1</sup>	5 (17.2%) <sup>1</sup>
IQR, interquartile range.	
<sup>1</sup> One minor bleed, one case of main pancreatic duct stenosis, one case of post-procedural fever, one case of gastric wall hematoma, and one case of post-anesthesia urinary retention.	

lesions with follow-up at 6 months, 11 (73.3%) showed a significant response (46.6% with complete necrosis and 26.7% with >50% size reduction), while only two of 11 metastatic lesions showed some degree of response. At 12-month follow-up (n = 20), there were six cases (30%) still showing complete response, three lesions (15%) with >50% decrease in diameter, and 11 (55%) with <50% decrease, when compared to lesion initial size. Of the pNET lesions, 54.5% still had a complete response at this point in follow-up (n = 11), compared with 11.1% for the other lesion group (n = 9). Finally, regarding clinical response, hypoglycemia related to insulinoma was immediately corrected after the procedure in all 13 cases (100%), with no recurrence of symptoms during follow-up (median of 9.5 months – IQR 16).

► **Table 3** Follow up.

	<b>Total</b>	<b>pNET</b>	<b>Non-pNET</b>
6-month follow-up	(n = 25 <sup>1</sup> )	(n = 15)	(n = 10)
▪ Complete necrosis <sup>2</sup>	9 (36%)	7 (46.6%)	1 (1%)
▪ >50% necrosis <sup>2</sup>	4 (16%)	4 (26.7%)	0 (0%)
▪ <50% necrosis <sup>23</sup>	12 (48%)	4 (26.7%)	9 (90%)
12 months follow-up	(n = 20 <sup>4</sup> )	(n = 11)	(n = 9)
▪ Complete necrosis <sup>2</sup>	6 (30%)	6 (54.6%)	1 (1%)
▪ >50% necrosis <sup>2</sup>	3 (15%)	3 (27.2%)	0 (0%)
▪ <50% necrosis <sup>23</sup>	11 (55%)	2 (18.2%)	8 (80%)
Complete clinical response in functional pNET	–	(n = 13)	
Median follow-up = 9.5 months (IQR 16)		13 (100%)	

pNET, pancreatic neuroendocrine tumor; IQR, interquartile range.

<sup>1</sup> Two cases were lost to follow-up, two skipped the 6 months evaluation due to logistical impediments and six cases still had <6 months follow-up duration.

<sup>2</sup> Necrosis = reduction of the tumor size and/or its replacement by a hypodense region on computed tomography scan.

<sup>3</sup> One case of a renal cancer metastasis showing no response to treatment.

<sup>4</sup> Four cases were considered lost to follow-up and 11 still had <12 months follow-up duration.

## Discussion

An upward trend in incidence of pancreatic tumors is being increasingly reported [1, 2]. To date, surgical resection is still considered to be the only curative treatment, even though it has a poor safety profile and frequently is associated with AEs (10% to 58% rate of pancreatic fistula, 18% rate of delayed gastric emptying, 6% of postoperative bleeding and 3%-6% in-hospital mortality rate) [14, 15].

EUS-RFA has recently been proposed as a less invasive, safer, and effective treatment option for selected pancreatic neoplasms [7, 16]. However, large multicenter studies are still lacking, with data coming mostly from small case series (31 lesions studied in a single study) [7, 17]. With the aim of addressing this shortage of data, we created a multicenter prospective registry of all EUS-RFA procedures performed at two expert Belgian centers.

With regard to feasibility and technical success, our results are quite comparable with most of the previously published case series, with a technical success rate of 100% [17, 18]. Some authors have mentioned the risk of anatomical limitations, leading to certain difficulties in successfully maneuvering the EUS needle into the target lesion [9]. However, given the high rates of success, this does not seem to be a significant limitation for this technique.

Regarding safety, EUS-RFA remains a safe treatment choice, without any severe AEs observed. Nevertheless, in our series, there were still three cases (10%) of acute pancreatitis, one of which probably related to close proximity between the lesion and the main pancreatic duct. In that setting, some authors have recommended a supplemental prophylactic measure, which is leaving a minimum distance of 5 mm between the needle tip and the pancreatic duct so as to avoid post-procedure pancreatitis [19].

From an imaging perspective, we documented a clinical success rate of 52% at 6-month ( $n=25$ ) and 45% at 12-month ( $n=20$ ) follow-up. Two-thirds of the lesions that did not respond significantly to EUS-RFA treatment were RCC metastasis. In fact, of the nine intrapancreatic RCC metastases treated, only one showed significant response with development of complete necrosis. Chanez et al have recently reported on the largest series of EUS-RFA treatment for RCC pancreatic metastases, including 12 patients and a total of 21 lesions [6]. Focal control rates at 6 and 12 months were 84% and 73%, respectively, including patients with complete response, partial (>30%) response, and stable disease (6 months: 26.3%, 31.6%, 26.3% and 12 months: 40%, 33.3%, 0%, respectively). These favorable results contrast with those from our study, for which there may be multiple explanations. First, Chanez et al used different response evaluation methods and criteria, emphasizing the disease's progression control and not its actual regression, as was the case in our study. Also, all 12 included patients had previously undergone nephrectomy, with 75% presenting with an early tumor (T1/T2) and 58% presenting no other sites of metastasis. Finally, 66% of the enrolled patients also received additional treatment with vascular endothelial growth factor receptor-tyrosine kinase inhibitor, in association with EUS-RFA,

making it difficult to draw conclusions about the efficacy of the latter as an isolated treatment.

With regard to the two non-RCC metastases also included in our cohort, complete necrosis was achieved in only one case (intrapancreatic metastasis of lung cancer). The other was a left adrenal metastasis from a gastric adenocarcinoma, which only showed a mild and transient response, in the context of systemic disease progression (with development of other secondary lesions).

Altogether, and even though EUS-RFA has already been reported as a treatment option in metastatic settings [20, 21], our results clearly illustrate the importance of careful evaluation and selection of candidates before treatment so that the procedure can have a real positive impact in the evolution of clinical and oncology care. In certain contexts, EUS-RFA could be a good local therapy option in a multimodal treatment strategy for oligometastatic disease (for example, in association with a systemic treatment or as a way to reduce the size of metastases and eventually allow for subsequential surgical resection). Nevertheless, further studies are needed to establish the best role for it in these cases.

Finally, functioning pNETs seem to be the best indication for EUS-RFA treatment. A recent systematic review and meta-analysis that included 53 cases of pNET revealed a pooled clinical success rate (symptomatic improvement along with decrease in size and necrosis) ranging from 83% to 100% [17]. We have already reported preliminary results of the significant benefit of RFA to patients with insulinoma [22]. Here, all 13 patients with insulinomas exhibited an immediate and sustained complete clinical response, with no symptoms of hypoglycemia recurring during follow-up, at the cost of very low toxicity. These results are identical to those of other investigators [16, 18] in a larger patient series.

The limitations of our study include the limited number of patients included (even if this number is higher than all previously published series) and the relatively short follow-up period. Also, the optimal methods and timing for response evaluation still remain to be established and may differ from the follow-up strategy we adopted. Thus, larger studies with longer follow-up are still necessary to evaluate the long-term efficacy of EUS-RFA and to better determine its role for treatment of pancreatic tumors and oligometastatic diseases.

## Conclusions

We report the largest series to date, addressing the efficacy and safety of RFA in solid pancreatic lesions. In our hands, EUS-RFA was shown to be a feasible, safe and effective procedure for treatment of pancreatic and peripancreatic tumors. Accuracy of response determination requires further evaluation and longer follow-up. Symptomatic insulinoma currently represents the best indication for this treatment.

## Competing interests

The authors declare that they have no conflict of interest.

## References

- [1] Lee DW, Kim MK, Kim HG. Diagnosis of pancreatic neuroendocrine tumors. *Clin Endosc* 2017; 50: 537–545
- [2] Tanaka M, Fernández-del Castillo C, Kamisawa T et al. Revisions of international consensus Fukuoka guidelines for the management of IPMN of the pancreas. *Pancreatol* 2017; 17: 738–753
- [3] Sachs T, Pratt WB, Callery MP et al. The incidental asymptomatic pancreatic lesion: nuisance or threat? *J Gastrointest Surg* 2009; 13: 405–415
- [4] Ballarin R. Pancreatic metastases from renal cell carcinoma: The state of the art. *World J Gastroenterol* 2011; 17: 4747
- [5] Dabestani S, Marconi L, Hofmann F et al. Local treatments for metastases of renal cell carcinoma: a systematic review. *Lancet Oncol* 2014; 15: e549–e561
- [6] Chanez B, Caillol F, Ratone J-P et al. Endoscopic ultrasound-guided radiofrequency ablation as an future alternative to pancreatotomy for pancreatic metastases from renal cell carcinoma: a prospective study. *Cancers* 2021; 13: 5267
- [7] Barthelet M, Giovannini M, Lesavre N et al. Endoscopic ultrasound-guided radiofrequency ablation for pancreatic neuroendocrine tumors and pancreatic cystic neoplasms: a prospective multicenter study. *Endoscopy* 2019; 51: 836–842
- [8] Okasha H, Naga Y, El Sherbiny M. EUS-guided radiofrequency ablation: Where we are? *Endosc Ultrasound* 2020; 9: 277
- [9] Scopelliti F, Pea A, Conigliaro R et al. Technique, safety, and feasibility of EUS-guided radiofrequency ablation in unresectable pancreatic cancer. *Surg Endosc* 2018; 32: 4022–4028
- [10] Ducreux M, Sa Cuhna A, Caramella C et al. Cancer of the pancreas: ESMO Clinical Practice Guidelines for diagnosis, treatment and follow-up. *Ann Oncol* 2015; 26: v56–v68
- [11] Pavel M, Öberg K, Falconi M et al. Gastroenteropancreatic neuroendocrine neoplasms: ESMO Clinical Practice Guidelines for diagnosis, treatment and follow-up. *Ann Oncol* 2020; 31: 844–860
- [12] Wani S, Han S, Simon V et al. Setting minimum standards for training in EUS and ERCP: results from a prospective multicenter study evaluating learning curves and competence among advanced endoscopy trainees. *Gastrointest Endosc* 2019; 89: 1160–1168.e9
- [13] Banks PA, Bollen TL, Dervenis C et al. Classification of acute pancreatitis – 2012: revision of the Atlanta classification and definitions by international consensus. *Gut* 2013; 62: 102–111
- [14] Jilesen APJ, van Eijck CHJ, in't Hof KH et al. Postoperative complications, in-hospital mortality and 5-year survival after surgical resection for patients with a pancreatic neuroendocrine tumor: a systematic review. *World J Surg* 2016; 40: 729–748
- [15] Busquets J, Fabregat J, Jorba R et al. Tratamiento quirúrgico del adenocarcinoma pancreático mediante duodenopancreatometomía cefálica (Parte 1). Complicaciones postoperatorias en 204 casos en un centro de referencia. *Cir Esp* 2010; 88: 299–307
- [16] Oleinikov K, Dancour A, Epshtein J et al. Endoscopic ultrasound-guided radiofrequency ablation: a new therapeutic approach for pancreatic neuroendocrine tumors. *J Clin Endocrinol Metab* 2019; 104: 2637–2647
- [17] Dhaliwal A, Kolli S, Dhindsa BS et al. Efficacy of EUS-RFA in pancreatic tumors: Is it ready for prime time? A systematic review and meta-analysis *Endosc Int Open* 2020; 08: E1243–E1251
- [18] de Nucci G, Imperatore N, Mandelli ED et al. Endoscopic ultrasound-guided radiofrequency ablation of pancreatic neuroendocrine tumors: a case series. *Endosc Int Open* 2020; 08: E1754–E1758
- [19] Choi J-H, Seo D-W, Song TJ et al. Endoscopic ultrasound-guided radiofrequency ablation for management of benign solid pancreatic tumors. *Endoscopy* 2018; 50: 1099–1104
- [20] Crinò SF, D'Onofrio M, Bernardoni L et al. EUS-guided radiofrequency ablation (EUS-RFA) of solid pancreatic neoplasm using an 18-gauge needle electrode: feasibility, safety, and technical success. *J Gastrointest Liver Dis* 2018; 27: 67–72
- [21] Malikowski T, Gleeson FC, Block M et al. Mo1268 Endoscopic Ultrasound Guided Radiofrequency Ablation (EUS-RFA): Initial Assessment of Safety and Efficacy. *Gastrointest Endosc* 2017; 85: AB484
- [22] Furnica RM, Deprez P, Maiter D et al. Endoscopic ultrasound-guided radiofrequency ablation: An effective and safe alternative for the treatment of benign insulinoma. *Ann Endocrinol* 2020; 81: 567–571