

# Influence of Lung Reconstruction Algorithms on Interstitial Lung Pattern Recognition on CT

## Einfluss von Lungenrekonstruktionsalgorithmen auf die Erkennung von interstitiellen Lungenmustern in der Computertomografie



### Authors

Jeremias B. Klaus<sup>1,2</sup>, Stergios Christodoulidis<sup>3</sup>, Alan A. Peters<sup>1</sup>, Cynthia Hourscht<sup>1</sup>, Laura I. Loebelenz<sup>1</sup>, Jaro Munz<sup>1</sup>, Christophe Schroeder<sup>1</sup>, Dominik Sieron<sup>4</sup>, Dionysios Drakopoulos<sup>4</sup>, Severin Stadler<sup>5</sup>, Johannes T. Heverhagen<sup>1</sup>, Helmut Prosch<sup>6</sup>, Adrian Huber<sup>1</sup>, Moritz Pohl<sup>7</sup>, Stavroula G. Mougiakakou<sup>3</sup>, Andreas Christe<sup>1,4</sup>, Lukas Ebner<sup>1</sup>

### Affiliations

- 1 Department of Diagnostic, Interventional and Pediatric Radiology, Inselspital, Bern University Hospital, University of Bern, Switzerland
- 2 Institute of Forensic Medicine, University of Bern, Bern, Switzerland
- 3 ARTORG Center for Biomedical Engineering Research, University of Bern, Switzerland
- 4 Department of Radiology, Division City and County Hospitals, INSELGROUP, Bern University Hospital, University of Bern, Bern, Switzerland
- 5 Bern University, University of Bern, Switzerland
- 6 Department of Biomedical Imaging and Image-guided Therapy, Medical University of Vienna, Austria
- 7 Institute of Medical Biometry, University of Heidelberg, Heidelberg, Germany

### Key words

CT, thorax, CT-high resolution, diagnostic radiology, technical aspects

received 16.11.2021

accepted 09.05.2022

published online 06.09.2022

### Bibliography

Fortschr Röntgenstr 2023; 195: 47–54

DOI 10.1055/a-1901-7814

ISSN 1438-9029

© 2022. The Author(s).

This is an open access article published by Thieme under the terms of the Creative Commons Attribution-NonDerivative-NonCommercial License, permitting copying and reproduction so long as the original work is given appropriate credit. Contents may not be used for commercial purposes, or adapted, remixed, transformed or built upon. (<https://creativecommons.org/licenses/by-nc-nd/4.0/>)

Georg Thieme Verlag KG, Rüdigerstraße 14,  
70469 Stuttgart, Germany

### Correspondence

Jeremias B Klaus

Department of Interventional, Pediatric and Diagnostic Radiology, Inselspital Bern, Freiburgstrasse 8, 3010 Bern, Switzerland

Tel.: +41/031/632 24 35

jeremias.klaus@insel.ch

### ABSTRACT

**Background** Despite current recommendations, there is no recent scientific study comparing the influence of CT reconstruction kernels on lung pattern recognition in interstitial lung disease (ILD).

**Purpose** To evaluate the sensitivity of lung (i70) and soft (i30) CT kernel algorithms for the diagnosis of ILD patterns.

**Materials and Methods** We retrospectively extracted between 15–25 pattern annotations per case (1 annotation = 15 slices of 1 mm) from 23 subjects resulting in 408 annotation stacks per lung kernel and soft kernel reconstructions. Two subspecialized chest radiologists defined the ground truth in consensus. 4 residents, 2 fellows, and 2 general consultants in radiology with 3 to 13 years of experience in chest imaging performed a blinded readout. In order to account for data clustering, a generalized linear mixed model (GLMM) with random intercept for reader and nested for patient and image and a kernel/experience interaction term was used to analyze the results.

**Results** The results of the GLMM indicated, that the odds of correct pattern recognition is 12% lower with lung kernel compared to soft kernel; however, this was not statistically significant (OR 0.88; 95%-CI, 0.73–1.06;  $p=0.187$ ). Furthermore, the consultants' odds of correct pattern recognition was 78% higher than the residents' odds, although this finding did not reach statistical significance either (OR 1.78; 95%-CI, 0.62–5.06;  $p=0.283$ ). There was no significant interaction between the two fixed terms kernel and experience. Intra-rater agreement between lung and soft kernel was substantial ( $\kappa=0.63 \pm 0.19$ ). The mean inter-rater agreement for lung/soft kernel was  $\kappa=0.37 \pm 0.17/\kappa=0.38 \pm 0.17$ .

**Conclusion** There is no significant difference between lung and soft kernel reconstructed CT images for the correct pattern recognition in ILD. There are non-significant trends indicating that the use of soft kernels and a higher level of experience lead to a higher probability of correct pattern identification.

#### Key points:

- There is no significant difference between lung and soft kernel reconstructed CT images for the correct pattern recognition in interstitial lung disease.
- There are even non-significant tendencies that the use of soft kernels lead to a higher probability of correct pattern identification.
- These results challenge the current recommendations and the routinely performed separate lung kernel reconstructions for lung parenchyma analysis.

#### Citation Format

- Klaus JB, Christodoulidis S, Peters AA et al. Influence of Lung Reconstruction Algorithms on Interstitial Lung Pattern Recognition on CT. *Fortschr Röntgenstr* 2023; 195: 47–54

## ZUSAMMENFASSUNG

**Hintergrund** Trotz den aktuellen Empfehlungen gibt es keine aktuelle wissenschaftliche Studie, welche den Einfluss von CT-Rekonstruktionskerneln auf die Erkennung von Mustern der interstitiellen Lungenerkrankungen (ILD) vergleicht.

**Ziel** Untersuchung der Sensitivität von scharfen Lungen- (i70) und weichen Weichteil- (i30) CT-Rekonstruktionskerneln zur Diagnose von ILD-Mustern.

**Material und Methoden** Retrospektiv wurden von 23 Probanden 15–25 Muster annotiert (1 Annotation = 15 Schichten à 1 mm), was 408 Annotations-Stapel pro Lungen- und Weichteilkernel ergab. 2 subspezialisierte Thorax-Radiologen definierten den Referenzstandard im Konsens. 4 Assistenzärzte, 2 Thorax-Fellows und 2 Fachärzte mit 3–13 Jahren Erfahrung

in der Radiologie beurteilten die Daten verblindet. Aufgrund der mehrfach geclusterten Daten wurde ein generalisiertes lineares gemischtes Modell (GLMM) mit den Interaktionstermen Kernel/Erfahrung zur Analyse verwendet.

**Ergebnisse** Die Resultate des GLMM deuteten eine um 12% niedrigere Treffsicherheit für die korrekte Mustererkennung an beim Verwenden des Lungenkernels im Vergleich zum Weichteilkernel, jedoch erreichten die Resultate keine statistische Signifikanz (OR 0.88; 95%-CI, 0.73–1.06;  $p = 0.187$ ). Des Weiteren zeigten die Fachärzte eine um 78% höhere Wahrscheinlichkeit der korrekten Mustererkennung im Vergleich zu den Assistenzärzten, doch auch dieses Resultat war nicht statistisch signifikant (OR 1.78; 95%-KI 0.62–5.06;  $p = 0.283$ ). Die Intra-rater-Übereinstimmung war substantiell ( $\kappa = 0.63 \pm 0.19$ ), die gemittelte Inter-rater-Übereinstimmung für Lungen-/Weichteilkernel betrug  $\kappa = 0.37 \pm 0.17 / \kappa = 0.38 \pm 0.17$ .

**Schlussfolgerung** Insgesamt gab es keinen signifikanten Einfluss von CT-Kernel oder Erfahrung des befundenden Radiologen auf die korrekte Erkennung von ILD-Mustern. Es gibt nicht-signifikante Trends, dass die Verwendung eines Weichteilkernels und eine größere Erfahrung zu einer höheren Wahrscheinlichkeit der korrekten Mustererkennung führen.

#### Kernaussagen:

- Es besteht kein signifikanter Unterschied zwischen mit Lungen- und Weichteilkernel-rekonstruierten CT-Bildern für die korrekte Erkennung von ILD-Mustern.
- Es gibt sogar nicht-signifikante Trends, dass die Verwendung des Weichteilkernels mit höherer Wahrscheinlichkeit zu einer korrekten Mustererkennung führt.
- Diese Ergebnisse stellen die aktuellen Empfehlungen und die routinemässig durchgeführten separaten Lungenkernelrekonstruktionen für die Analyse des Lungparenchyms in Frage.

## Introduction

High-resolution computed tomography (CT) has been established as a cornerstone in the diagnosis and follow-up of interstitial lung disease (ILD) [1]. Interstitial lung disease presents with a distinct array of CT imaging patterns in a certain distribution [2, 3].

CT is an essential diagnostic test in the diagnosis of suspected idiopathic pulmonary fibrosis (IPF). With the release of novel recommendations by the Fleischner Society as well as the ATS/ERS/JRS/ALAT, the role of CT became even more apparent [1, 4, 5]. In the appropriate clinical context and the presence of the usual interstitial pneumonia (UIP) pattern on chest CT, a confident diagnosis of IPF can be achieved [6]. Growing evidence supports the assumption that also a “probable UIP” pattern, while lacking the typical honeycombing appearance, predicts the presence of IPF with substantial likelihood [1, 5]. Therefore, the stratification into the diagnostic categories of UIP based on CT are a crucial task for radiologists. Consequently, an utmost critical step in the diagnosis

of ILD is the correct identification of the CT patterns present on a particular scan.

To achieve optimized spatial resolution, CT scans of the lungs are reconstructed with edge-enhancing reconstruction algorithms maximizing contrast. Using lung kernels for the assessment and measurement of lung nodules as well as for the diagnosis of ILD has been recommended by several publications [1, 7, 8]. However, the lung kernel simultaneously increases image noise [9]. Previously published results showed that computer-aided detection (CAD) applications exhibit better results when used along with soft reconstruction kernels [10]. We noticed that these soft kernels, which are designed to elevate tissue contrast while reducing noise, are increasingly applied in the clinical routine to assess the lung parenchyma. Various studies have shown that reconstruction kernels and other technical parameters have a substantial impact on image perception [11–16].

Despite the wide endorsement of using lung kernel reconstruction algorithms for the diagnosis of chest CT patterns, there is no

recent evidence supporting those recommendations. Results published prior to the introduction of helical CT in the early 1990s indicated the beneficial use of lung kernel reconstructions on chest CT [9, 17–19]. Despite the advances in CT technique, to our knowledge no systematic investigation of image reconstruction algorithms and their impact on lung parenchymal assessment has been conducted.

The purpose of this study was to directly compare the radiologists' sensitivity for the classification of image patterns on chest CT using lung- and soft kernels. We used a subset of CT patterns linked to the UIP pattern. In order to reflect a broad range of clinical scenarios, we involved radiologists with various levels of experience.

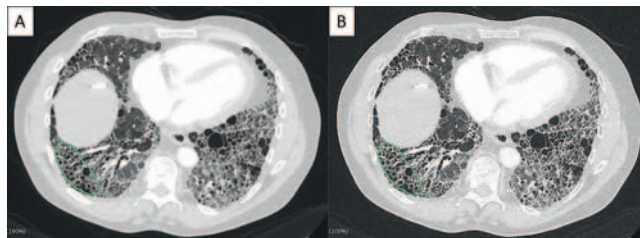
## Materials and Methods

The local ethics review board (IRB) approved this retrospective study. Twenty-three chest CT scans were retrospectively selected from the local ILD database from our tertiary care center. All included patients had a multidisciplinary team (MDT) diagnosis of IPF or NSIP (nonspecific interstitial pneumonia, including idiopathic and secondary NSIP on CT in patients with connective tissue disease) between January 2018 and May 2018. CT scans were acquired on a 128-MDCT scanner (Somatom Definition Flash, Siemens Healthcare) with iterative reconstruction (IRIS, Siemens Healthcare) and an integrated detector system (Stellar, Siemens Healthcare). Chest CT scans were performed with 100 kVp and 100 Reference mAs. FOV was kept constant at 32 cm. The slice reconstruction thickness was 1 mm. For raw dataset processing, level three iteration was applied. Axial slices were reconstructed with two different kernels (i30 and i70) at a slice thickness of 1 mm for interpretation. Multiplane reconstructions were not performed.

The following inclusion criteria were applied: 1) Patients with ILD-board approved usual interstitial pneumonia (UIP) or nonspecific interstitial pneumonia (NSIP); 2) The scans included soft and lung kernel raw data reconstructions; 3) Diagnostic image quality (no image artifacts). In total, we included 23 consecutive patients with interstitial lung disease (13 patients with UIP pattern, 10 patients presenting with NSIP pattern). The CT scans were anonymized and transferred to a separate database for further pattern assessment.

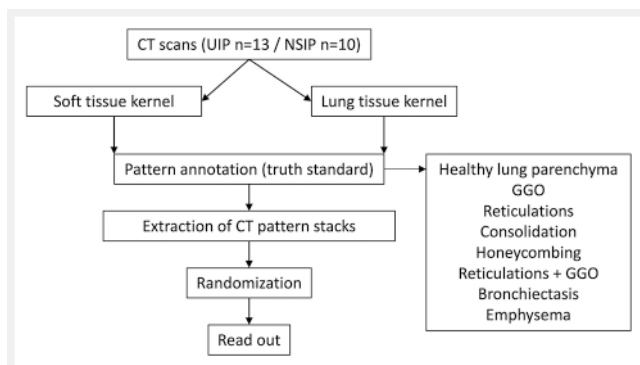
### Standard of Reference

Two subspecialized chest radiologists (AC, LE) with 12 and 20 years of experience in chest imaging reviewed the CT scans with soft kernels as well as lung kernels. Window level and width were set at of -500 HU and 1500 HU, respectively. On these scans, the chest radiologists annotated eight typical CT patterns deemed critical: healthy lung parenchyma, ground glass opacification, reticulations, consolidation, honeycombing, reticulations in combination with ground glass opacification, bronchiectasis, and emphysema (► Fig. 1). The open-source software Slicer 4.10.2 (<http://www.slicer.org>) was used for color annotating each slice. 15–25 areas per case were selected. The continuous annotated areas were used to create a stack of 15 consecutive slices for radiological evaluation (1 stack = 15 contiguous slices of 1 mm), resulting in a database



► **Fig. 1** Reader interface. Two subspecialized chest radiologists defined the ground truth for CT patterns. Annotated CT image stacks were created (15 slices, 1 mm slice thickness). Readers were asked to name the encircled CT pattern, in this case honeycombing. **A:** soft kernel; **B:** lung kernel.

► **Abb. 1** Reader interface. 2 subspezialisierte Thorax-Radiologen haben den Referenzstandard für die Muster definiert. Annotierte CT-Stapel wurden erstellt (15 Schichten, 1 mm Schichtdicke). Die Reader sollten die eingekreisten Muster benennen, in diesem Beispiel Honigwabennmuster. **A:** Weichteilkern; **B:** Lungenkern.



► **Fig. 2** Study design flowchart.

► **Abb. 2** Studiendesign-Flowchart.

containing 816 image stacks (408 soft kernel, 408 lung kernel). Within each stack, the predefined CT pattern was marked for further readout. After the completion of the annotation, a consensus panel among the chest radiologists resolved discrepancies. The amount of the selected patterns matched the frequencies of the patterns in the real UIP and NSIP cases.

### Image Analysis

Eight independent readers blinded to the patient diagnosis and annotated patterns performed the readout. The readers were two board-certified radiologists with 12 and 13 years of experience, two radiology fellows (one thoracic radiology fellow, one fellow in abdominal imaging) with four and five years of experience, respectively, and four residents with three to four years of training. Each reader received an individually randomized database of the CT cases. It should be noted that the presentation sequence of the soft and the lung kernel was also randomly assigned. The readout was performed using Slicer software. On each pre-annotated CT stack, readers were asked to determine the particular CT pattern highlighted. Readers recorded the patterns. A synopsis of the study design is depicted in ► Fig. 2.

## Statistics

In order to account for data clustering, a generalized linear mixed model (GLMM) with random intercept for reader and nested for patient and image with interaction term for the fixed effects kernel and experience was used to analyze the results. The investigated binary endpoint was the correct pattern recognition (0 = no, 1 = yes). The model accounts for the repeated measures of reader, patient and image. The analysis was performed using R Software version 4.0.4. Intra-rater (lung versus soft kernel) agreement and inter-rater agreement were calculated according to the weighted Kappa statistic for the lung kernel and the soft kernel separately. The following classifications of Kappa levels were used: slight ( $\kappa \leq 0.20$ ), fair (0.21–0.40), moderate (0.41–0.60), substantial (0.61–0.80), and almost perfect agreement ( $\kappa \geq 0.81$ ). Kappa levels were compared using correlation coefficient testing (z-statistic). The significance level was set to 0.05. MedCalc version 15.0 (MedCalc Software, Ostend, Belgium) and SPSS (IBM, Armonk, New York, USA) were utilized.

## Results

The eight radiologists scored in total 80 healthy lung parenchyma regions, 22 ground glass patterns, 67 regions with reticulations, 29 areas presenting with consolidation, 86 cases of honeycombing, 65 cases showing reticulations and ground glass, as well as 23 annotations of bronchiectasis and 36 emphysema cases (3264 classifications in lung and 3264 classifications in soft kernel images) (► Fig. 3).

### Individual Reader Analysis

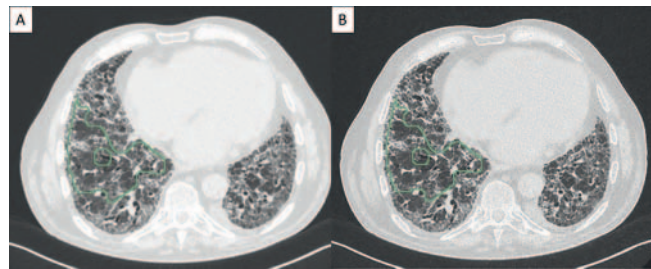
Individual pattern sensitivities of all readers are shown in ► Table 1. Individual per reader analysis did not demonstrate significant differences in pattern sensitivities comparing lung kernel versus soft kernel, except for one resident, who detected significantly more emphysema pattern using soft kernel images ( $p = 0.0455$ ) and one consultant, who detected more reticulation with ground glass opacities on lung kernel images. The pooled results of all readers demonstrated an overall pattern sensitivity of 77.8% for lung kernel and 76.3% for soft kernel ( $p = 0.0838$ ).

### Generalized Linear Mixed Model

The results of the GLMM (► Table 2) indicated, that the probability of correct pattern recognition is 12% lower with lung kernel compared to soft kernel; however, this finding did not reach statistical significance (OR 0.88; 95%-CI, 0.73–1.06;  $p = 0.187$ ). Analysis per experience level showed highest frequencies of correct pattern detection by consultants, followed by residents and fellows. The consultants' odds of correct pattern recognition was 78% higher than the residents' odds, although this finding did not reach statistical significance either (OR, 1.78; 95%-CI, 0.62–5.06;  $p = 0.283$ ). The results indicated no significant interaction between the fixed terms kernel and experience.

### Missed Cases

The misclassified cases are depicted in ► Fig. 4. For the lung kernel reconstruction, readers tended to falsely classify emphysema



► Fig. 3 Reticular pattern. The green marking denotes the annotated pattern. Note that the bronchiectasis in the center of the annotation is not included. A: soft kernel; B: lung kernel.

► Abb. 3 Retikulation. Die grüne Markierung umkreist das zu beurteilende Muster. Hier wurde die Bronchiektase in der Mitte der Annotation nicht inkludiert. A: Weichteilkern; B: Lungenkern.

as healthy lung parenchyma, honeycombing was rated as reticulation, and ground glass opacities in combination with reticulations were scored as showing reticulation or ground glass and vice versa (► Fig. 4A). In soft kernel reconstructions, more accurate classification of emphysema was observed. The hyper- and hypoattenuation in the ground glass pattern and normal lung was mistaken for emphysema using the soft reconstruction kernel. Also, reticulations were scored as ground glass opacification and reticulation (► Fig. 4B).

### Intra-Rater Agreement

The overall intra-rater agreement between the lung kernel and the soft kernel was substantial ( $\kappa = 0.63 \pm 0.19$ ). The consultants showed a significantly higher agreement ( $\kappa = 0.89 \pm 0.18$ ) compared to the fellow radiologists ( $\kappa = 0.56 \pm 0.08$ ;  $p < 0.0001$ ). The moderate agreement among the fellow radiologists was significantly better than among the residents ( $\kappa = 0.44 \pm 0.04$ ;  $p = 0.0003$ ).

The mean inter-rater agreement for all patterns on the lung kernel did not vary significantly from the agreement on the soft kernel images  $\kappa = 0.38 \pm 0.17$  and  $\kappa = 0.37 \pm 0.17$ ;  $p = 0.64$ ), although, they differed among the three experience levels (► Table 3).

## Discussion

Chest CT with lung kernel reconstruction for ILD pattern detection is widely recommended. However, the effect of lung kernel reconstruction algorithms on pattern recognition has not recently been investigated.

Accurate pattern recognition on CT scans is a prerequisite in ILD diagnosis. Many patients with IPF are diagnosed with CT imaging only, avoiding the potential risks of invasive tissue sampling [1, 20–22]. This is especially important, as subjects with possible IPF are prone to develop an acute exacerbation associated with high mortality [23–25]. Therefore, optimization of interpretation parameters and imaging standards is essential.

The detection of honeycombing as a hallmark of the UIP pattern is an important marker for clinical decision-making. In a multidisci-

► **Table 1** Individual pattern sensitivities of all readers.

► **Tab. 1** Individuelle Muster-Sensitivitäten aller Reader.

Pattern (ground truth)	Kernel	Total n	R1		R2		R3		R4		F1		F2		C1		C2		Sens all			
			n	%	n	%	n	%	n	%	n	%	n	%	n	%	n	%	n	%	n	%
1	Normal lung	80	80	100%	79	99%	80	100%	79	100%	77	96%	80	96%	70	88%	74	93%	74	93%	97%	
1	Normal lung	80	79	99%	77	96%	79	99%	77	96%	74	93%	80	93%	72	90%	74	93%	74	93%	96%	P = 0.2301
2	GGO	22	19	86%	15	68%	18	82%	20	91%	14	64%	16	73%	8	36%	20	91%	20	91%	74%	
2	GGO	22	18	82%	17	77%	18	82%	16	73%	15	68%	16	73%	7	32%	20	91%	20	91%	72%	P = 0.7103
3	Reticulation	67	56	84%	46	69%	60	90%	49	73%	45	67%	59	88%	47	70%	58	87%	58	87%	78%	
3	Reticulation	67	49	73%	37	55%	54	81%	52	78%	39	58%	53	79%	51	76%	58	87%	58	87%	73%	P = 0.0172*
4	Consolidation	29	29	100%	28	97%	29	100%	28	97%	27	93%	22	76%	22	76%	29	100%	29	100%	92%	
4	Consolidation	29	29	100%	27	93%	28	97%	28	97%	27	93%	21	72%	25	86%	29	100%	29	100%	92%	P = 0.8231
5	Honeycombing	86	65	76%	58	67%	61	71%	72	84%	56	65%	45	52%	77	90%	84	98%	84	98%	75%	
5	Honeycombing	86	64	74%	55	64%	54	63%	65	76%	50	58%	42	49%	73	85%	83	97%	83	97%	71%	P = 0.0024*
6	GGO+RET	65	39	60%	20	31%	28	43%	27	42%	21	32%	28	43%	42	65%	42	65%	57	88%	50%	
6	GGO+RET	65	36	55%	15	23%	39	60%	34	52%	16	25%	36	55%	36	55%	36	55%	57	88%	52%	P = 0.6082
7	Bronchiectasis	23	22	96%	20	87%	21	91%	21	91%	19	83%	17	74%	18	78%	22	96%	22	96%	87%	
7	Bronchiectasis	23	21	91%	18	78%	23	100%	19	83%	22	96%	19	83%	18	78%	22	96%	22	96%	88%	P = 0.8501
8	Emphysema	36	18	50%	32	89%	31	86%	25	69%	36	100%	29	81%	8	22%	36	100%	36	100%	75%	
8	Emphysema	36	25	69%	32	89%	32	89%	32	89%	36	100%	29	81%	7	19%	36	100%	36	100%	80%	P = 0.0350*
	All	408	328	80%	298	73%	328	80%	321	79%	295	72%	296	73%	292	72%	380	93%	380	93%	77.8%	
	All	408	321	79%	278	68%	327	80%	323	79%	279	68%	296	73%	289	71%	379	93%	379	93%	76.3%	P = 0.0442*
				P = 0.4764		P = 0.0476		P = 1.0000		P = 0.9141		P = 0.0894		P = 0.9049		P = 0.7277		P = 1.0000		P = 1.0000		

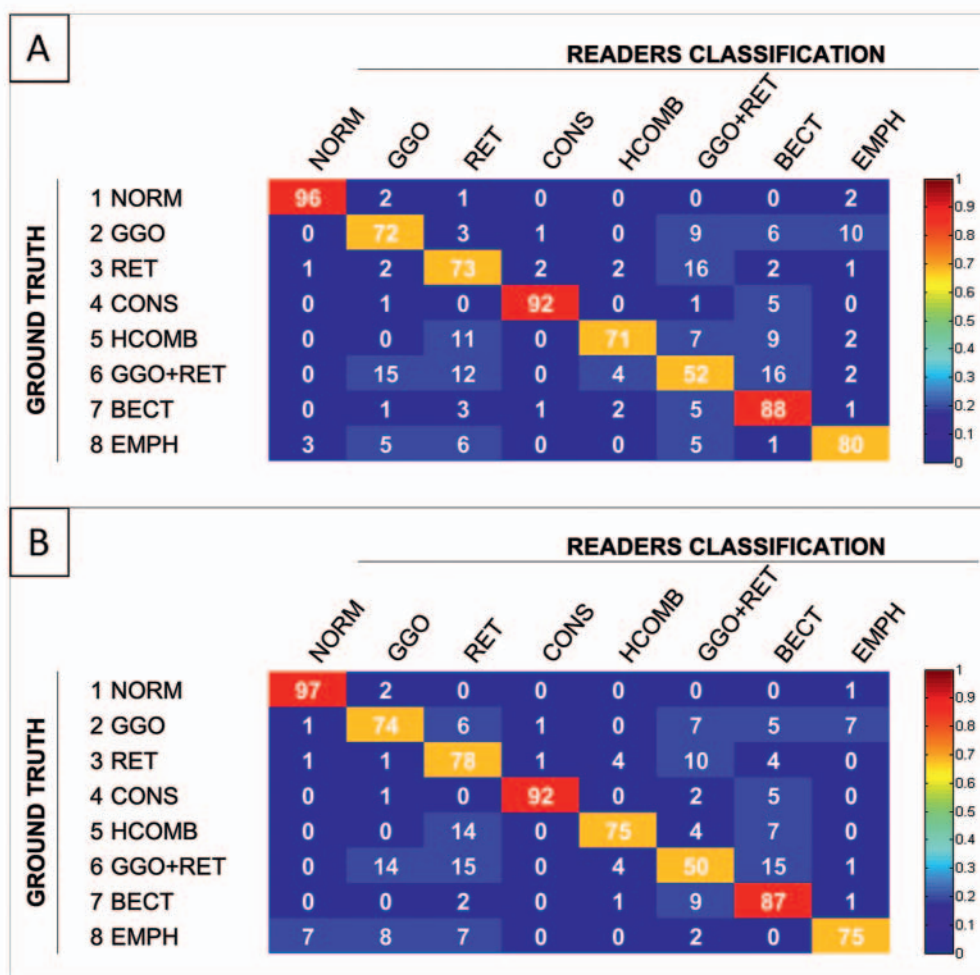
Note: R: resident#; F: fellow#; C: consultant#; GGO: Ground Glass Opacity; RET: reticulation.



► **Table 2** Generalized Linear Mixed Model.► **Tab. 2** Generalisiertes lineares gemischtes Modell.

Variable	Terms	Odds Ratio	95% CI	p-value
CT kernel	lung kernel vs. soft kernel	0.880	0.729–1.064	0.187
Reader experience	fellow vs. resident	0.641	0.227–1.809	0.401
	consultant vs. resident	1.775	0.623–5.060	0.283

Note: CI: confidence interval.

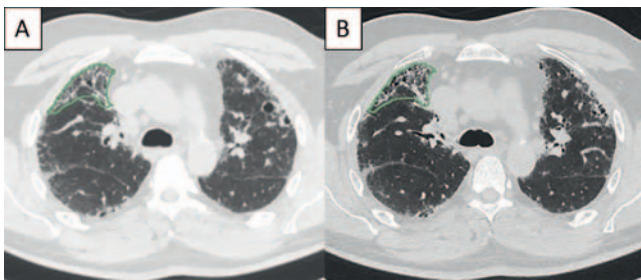
► **Fig. 4** Confusion matrix across all readers. Misclassified patterns are highlighted in light blue. **A:** soft kernel; **B:** lung kernel. NORM: normal lung; GGO: ground glass opacity; RET: reticulation; CONS: consolidation; HCOMB: honeycombing; BECT: bronchiectasies; EMPH: emphysema.► **Abb. 4** Wahrheitsmatrix. Falsch klassifizierte Muster sind hellblau hervorgehoben. **A:** Weichteilkern; **B:** Lungenkern. NORM: normales Lungenparenchym; GGO: Milchglasverdichtung; RET: Retikulation; CONS: Konsolidation; HCOMB: Honigwabemuster; BECT: Bronchiektasen; EMPH: Emphysem.

► **Table 3** Dependence of rater agreement (kappa) on experience.

► **Tab. 3** Erfahrungsabhängigkeit der Rater-Übereinstimmung (kappa).

	INTER rater agreement						INTRA rater agreement					
	Lung kernel			Soft kernel			P	Lung vs. soft kernel				
	kappa	±	SD	kappa	±	SD		kappa	±	SD	P	
R (residents):	0.46	±	0.09	0.45	±	0.08	0.77	0.44	±	0.04		
F (fellows):	0.25	±	0.05	0.22	±	0.05	0.61	0.56	±	0.08	<b>0.0003</b>	(R vs. F)
C (consultants):	0.05	±	0.04	0.04	±	0.04	0.89	0.89	±	0.18	<b>&lt;0.0001</b>	(F vs. C)
All:	0.38	±	0.17	0.37	±	0.17	0.64	0.63	±	0.19		

Note: SD: standard deviation; P: *p*-value according to comparison of correlation coefficient.



► **Fig. 5** Faint honeycombing pattern in the right upper lobe. A: soft kernel; B: lung kernel.

► **Abb. 5** Dezent es Honigwabenmuster im rechten Oberlappen. A: Weichteilkernel; B: Lungenkernel.

plinary team setting, this allows for the confident diagnosis of IPF [26–28]. To diagnose a typical UIP pattern on CT requires the presence of honeycombing in a basal and subpleural distribution. Although the sensitivity for honeycombing in our study was moderate, this is in alignment with previous reports [29, 30]. In the recently published ATS/ERS/JRS/ALAT criteria for UIP CT patterns, the role of CT in the diagnosis of IPF was expanded substantially. This is based on growing evidence that the typical UIP pattern with honeycombing represents a late-stage disease and that the probability of microscopic UIP is high in patients showing a probable UIP pattern on CT. Recent literature showed that, in the right clinical context and MDT approach, those cases could also be diagnosed as IPF with high confidence with CT alone [1, 6]. We expected the benefit of a higher spatial resolution with lung kernel reconstructions to be superior to soft kernel reconstructions for the correct classification of interstitial lung patterns (► **Fig. 5**). The results of the utilized model reveal that the odds for correct pattern identification using lung kernel reconstructions is in fact 12 % lower compared to tissue kernel without reaching statistical significance. However, these findings challenge current recommendations for the diagnosis of interstitial lung disease as they indicate non-superiority of the lung kernel over the soft kernel.

The experienced consultants demonstrated the highest intra-rater agreement which equals the highest consistency between the lung kernel and the soft kernel.

Several limitations warrant discussion. First, we built an artificial reading scenario with annotated image stacks, and we only evaluated the effect of the different kernel reconstructions on pattern recognition, not the effect on the final diagnosis when reading the whole CT scan. This might not reflect an actual reading environment. However, this allowed us to isolate the effect of different spatial resolution algorithms on pattern classification. Second, our readers were blinded, not only to the MDT discussion and distribution, but also to clinical background information (age, patient history, smoking status, etc.). Although this is also critical information, we did not target a clinical diagnosis. For determining the CT pattern sensitivity and the kernel-effect in isolation, the focused approach was deemed suitable. Third, we used a limited subset of CT patterns. In this evaluation, we focused on patterns that are most critical for UIP diagnosis. For this evaluation, we used kernels with relatively high frequency (i70). It should be noted that many institutions use more mid-frequency enhancement for lung reading. The impact of the mid-frequency lung kernel reconstruction was not investigated in the present study. Fourth, the same pattern was selected multiple times in a specific patient. This could represent potential clustering. However, a generalized linear mixed model was designed to account for this problem. Fifth, we had a relatively low count of 8 different readers, so only few observations in the 3 experience levels, which limits the meaningfulness of the per experience analysis.

## Conclusion

In conclusion, we found that there is no significant difference between lung and soft kernel reconstructed CT images for the correct pattern recognition in interstitial lung disease. There are non-significant trends that the use of soft kernels and a higher level of experience lead to a higher probability of correct pattern identification.

## Clinical Relevance

Accurate identification of interstitial lung patterns on CT is pivotal in the diagnosis of interstitial lung disease. Our results show that soft kernel reconstructions are comparable to or maybe even better than lung kernel reconstructions for the correct identification of interstitial lung patterns. This finding could have major impact on clinical practice, as it questions the current recommendations and the routinely performed separate lung kernel reconstructions for lung parenchyma analysis. Provided that the observations are confirmed in further studies, these additional lung kernel reconstructions could be omitted, which could save large amounts of data storage space.

## Conflict of Interest

The authors declare that they have no conflict of interest.

## References

- [1] Lynch DA, Sverzellati N, Travis WD et al. Diagnostic criteria for idiopathic pulmonary fibrosis: a Fleischner Society White Paper. *Lancet Respir Med* 2018; 6: 138–153. doi:10.1016/S2213-2600(17)30433-2
- [2] Lynch DA, Travis WD, Müller NL et al. Idiopathic interstitial pneumonias: CT features. *Radiology* 2005; 236: 10–21. doi:10.1148/radiol.2361031674
- [3] Ebner L, Christodoulidis S, Stathopoulou T et al. Meta-analysis of the radiological and clinical features of Usual Interstitial Pneumonia (UIP) and Nonspecific Interstitial Pneumonia (NSIP). *PLoS One* 2020; 15. doi:10.1371/journal.pone.0226084
- [4] Raghu G, Collard HR, Egan JJ et al. An Official ATS/ERS/JRS/ALAT Statement: Idiopathic pulmonary fibrosis: Evidence-based guidelines for diagnosis and management. *Am J Respir Crit Care Med* 2011; 183: 788–824. doi:10.1164/rccm.2009-040GL
- [5] Raghu G, Remy-Jardin M, Myers JL et al. Diagnosis of idiopathic pulmonary fibrosis An Official ATS/ERS/JRS/ALAT Clinical practice guideline. *Am J Respir Crit Care Med* 2018; 198: e44–e68. doi:10.1164/rccm.201807-1255ST
- [6] Funke-Chambour M, Guler SA, Geiser T et al. New radiological diagnostic criteria: Impact on idiopathic pulmonary fibrosis diagnosis. *Eur Respir J* 2019; 54. doi:10.1183/13993003.00905-2019
- [7] Mayo JR. CT evaluation of diffuse infiltrative lung disease: Dose considerations and optimal technique. *J Thorac Imaging* 2009; 24: 252–259. doi:10.1097/RTI.0b013e3181c227b2
- [8] Bankier AA, MacMahon H, Goo JM et al. Recommendations for measuring pulmonary nodules at CT: A statement from the Fleischner society. *Radiology* 2017; 285: 584–600. doi:10.1148/radiol.2017162894
- [9] Mayo JR, Webb WR, Gould R et al. High-resolution CT of the lungs: An optimal approach. *Radiology* 1987; 163: 507–510. doi:10.1148/radiology.163.2.3562834
- [10] Christe A, Leidolt L, Huber A et al. Lung cancer screening with CT: Evaluation of radiologists and different computer assisted detection software (CAD) as first and second readers for lung nodule detection at different dose levels. *Eur J Radiol* 2013; 82. doi:10.1016/j.ejrad.2013.08.026
- [11] Ravenel JG, Leue WM, Nietert PJ et al. Pulmonary nodule volume: Effects of reconstruction parameters on automated measurements – A phantom study. *Radiology* 2008; 247: 400–408. doi:10.1148/radiol.2472070868
- [12] Takagi S, Nagase H, Hayashi T et al. Combined multi-kernel chest computed tomography images optimized for depicting both lung and soft tissue. *Clin Imaging* 2014; 38: 104–108. doi:10.1016/j.clinimag.2013.11.009
- [13] Solomon J, Mileto A, Nelson RC et al. Quantitative features of liver lesions, lung nodules, and renal stones at multi-detector row CT examinations: Dependency on radiation dose and reconstruction algorithm. *Radiology* 2016; 279: 185–194. doi:10.1148/radiol.2015150892
- [14] Ebner L, Roos JE, Christensen JD et al. Maximum-intensity-projection and computer-aided-detection algorithms as stand-alone reader devices in lung cancer screening using different dose levels and reconstruction kernels. *Am J Roentgenol* 2016; 207: 282–288. doi:10.2214/Am J Roentgenol.15.15588
- [15] Gallardo-Estrella L, Lynch DA, Prokop M et al. Normalizing computed tomography data reconstructed with different filter kernels: effect on emphysema quantification. *Eur Radiol* 2016; 26: 478–486. doi:10.1007/s00330-015-3824-y
- [16] Alikhani B, Jamali L, Raatschen HJ et al. Impact of CT parameters on the physical quantities related to image quality for two MDCT scanners using the ACR accreditation phantom: A phantom study. *Radiography* 2017; 23: 202–210. doi:10.1016/j.radi.2017.03.013
- [17] Murata K, Khan A, Rojas KA et al. Optimization of computed tomography technique to demonstrate the fine structure of the lung. *Invest Radiol* 1988; 23: 170–175. doi:10.1097/00004424-198803000-00003
- [18] Zwirowich CV, Terriff B, Muller NL. High-spatial-frequency (bone) algorithm improves quality of standard CT of the thorax. *Am J Roentgenol* 1989; 153: 1169–1173. doi:10.2214/ajr.153.6.1169
- [19] Hopper KD, Kasales CJ, Mahraj R et al. Routine use of a higher order interpolator and bone algorithm in thoracic CT. *Am J Roentgenol* 1996; 167: 947–949. doi:10.2214/ajr.167.4.8819390
- [20] Swensen SJ, Aughenbaugh GL, Myers JL. Diffuse lung disease: Diagnostic accuracy of CT in patients undergoing surgical biopsy of the lung. *Radiology* 1997; 205: 229–234. doi:10.1148/radiology.205.1.9314990
- [21] Raghu G, Mageto YN, Lockhart D et al. The accuracy of the clinical diagnosis of new-onset idiopathic pulmonary fibrosis and other interstitial lung disease: A prospective study. *Chest* 1999; 116: 1168–1174. doi:10.1378/chest.116.5.1168
- [22] Hunninghake GW, Bridget Zimmerman M, Schwartz DA et al. Utility of a lung biopsy for the diagnosis of idiopathic pulmonary fibrosis. *Am J Respir Crit Care Med* 2001; 164: 193–196. doi:10.1164/ajrccm.164.2.2101090
- [23] Kondoh Y, Taniguchi H, Kawabata Y et al. Acute exacerbation in idiopathic pulmonary fibrosis: Analysis of clinical and pathologic findings in three cases. *Chest* 1993; 103: 1808–1812. doi:10.1378/chest.103.6.1808
- [24] Collard HR, Moore BB, Flaherty KR et al. Acute exacerbations of idiopathic pulmonary fibrosis. *Am J Respir Crit Care Med* 2007; 176: 636–643. doi:10.1164/rccm.200703-463PP
- [25] Collard HR, Ryerson CJ, Corte TJ et al. Acute exacerbation of idiopathic pulmonary fibrosis an international working group report. *Am J Respir Crit Care Med* 2016; 194: 265–275. doi:10.1164/rccm.201604-0801CI
- [26] Sumikawa H, Johkoh T, Ichikado K et al. Usual interstitial pneumonia and chronic idiopathic interstitial pneumonia: Analysis of CT appearance in 92 patients. *Radiology* 2006; 241: 258–266. doi:10.1148/radiol.2411050928
- [27] Akira M, Inoue Y, Kitaichi M et al. Usual interstitial pneumonia and non-specific interstitial pneumonia with and without concurrent emphysema: Thin-section CT findings. *Radiology* 2009; 251: 271–279. doi:10.1148/radiol.2511080917
- [28] Walsh SLF, Calandriello L, Sverzellati N et al. Interobserver agreement for the ATS/ERS/JRS/ALAT criteria for a UIP pattern on CT. *Thorax* 2016; 71: 45–51. doi:10.1136/thoraxjnl-2015-207252
- [29] Watadani T, Sakai F, Johkoh T et al. Interobserver variability in the CT assessment of honeycombing in the lungs. *Radiology* 2013; 266: 936–944. doi:10.1148/radiol.12112516
- [30] Siemienowicz ML, Kruger SJ, Goh NSL et al. Agreement and mortality prediction in high-resolution CT of diffuse fibrotic lung disease. *J Med Imaging Radiat Oncol* 2015; 59: 555–563. doi:10.1111/1754-9485.12314