

Underwater endoscopic submucosal dissection and hybrid endoscopic submucosal dissection as rescue therapy in difficult colorectal cases



Authors

Paolo Cecinato¹, Matteo Lucarini¹, Chiara Campanale¹, Francesco Azzolini², Fabio Bassi¹, Romano Sassatelli¹

Institutions

- 1 Unit of Gastroenterology and Digestive Endoscopy, Azienda USL-IRCCS di Reggio Emilia, Italy
- 2 Unit of Digestive Endoscopy, Vita-Salute San Raffaele University, Milan, Italy

submitted 27.11.2021

accepted after revision 20.4.2022

Bibliography

Endosc Int Open 2022; 10: E1225–E1232

DOI 10.1055/a-1882-4306

ISSN 2364-3722

© 2022. The Author(s).

This is an open access article published by Thieme under the terms of the Creative Commons Attribution-NonDerivative-NonCommercial License, permitting copying and reproduction so long as the original work is given appropriate credit. Contents may not be used for commercial purposes, or adapted, remixed, transformed or built upon. (<https://creativecommons.org/licenses/by-nc-nd/4.0/>)

Georg Thieme Verlag KG, Rüdigerstraße 14,
70469 Stuttgart, Germany

Corresponding author

Paolo Cecinato, MD, Unit of Gastroenterology and Digestive Endoscopy, Azienda USL-IRCCS di Reggio Emilia, 42123

Reggio Emilia, Italy

Fax: +39-0522-295941

paolo.cecinato@ausl.re.it

ABSTRACT

Background and study aims Colorectal endoscopic submucosal dissection (ESD) is still not widely used due to its technical difficulty and the risk of complications. Rescue therapies such as hybrid ESD (H-ESD) have been proposed for very difficult cases, as has underwater ESD (U-ESD). This study evaluated the safety and efficacy of H-ESD and U-ESD in difficult cases.

Patients and methods The hospital charts of consecutive patients referred for colorectal ESD between January 2014 and February 2021 because they were considered difficult cases were retrospectively analyzed. The primary outcome of the study was en bloc resection rate; secondary outcomes were the rate of complete resection, procedure speed, and incidence of adverse events (AEs).

Results Fifty-nine colorectal neoplasms were considered, 22 of which were removed by U-ESD and 37 by H-ESD. The en bloc resection rate in the U-ESD group was 100%, while it was 59.5% in the H-ESD group. Dissection speed was 17.7mm²/min in the U-ESD group and 8.3mm²/min in the H-ESD group. The AE rate was low in the U-ESD group and moderately high during H-ESD (5% and 21.6%, respectively; and perforation rate 0% and 10.8%, respectively). Larger lesions were treated with U-ESD, while more fibrotic ones were treated with H-ESD.

Conclusions U-ESD and H-ESD are both effective and safe techniques in difficult colorectal situations. U-ESD is particularly effective and fast for large lesions when it is not possible to obtain comfortable knife position, while H-ESD is more suitable for very fibrotic lesions.

Introduction

Endoscopic submucosal dissection (ESD) is a minimally invasive approach that allows en bloc resection of colorectal lesions [1]. This technique provides a high en bloc resection rate, accurate histological evaluation, and a low rate of local recurrence compared to conventional endoscopic mucosal resection (EMR) [2, 3]. However, colorectal ESD is still not widely used due to its

technical difficulty, the risk of complications, and the time required to perform the procedure [4, 5].

There are two key points concerning the technical difficulty of ESD: 1) maintaining the position of the scope while approaching the neoplasm; and 2) the difficulty in distinguishing between the submucosal and the muscular layers.

Maintaining a stable position during the procedure is crucial to reducing procedure time and risk of perforation. Stability, which can be affected by respiratory movements, heartbeat,

and paradoxical movements of the colonoscope, makes it possible to progress with the dissection following the correct plane with the right inclination of the knife.

Tissue traction and good submucosal exposure during dissection, which can be affected mainly by gravity and the degree of submucosal fibrosis, are also important for an effective, safe dissection. To improve submucosal exposure, use of clips or an additional thin endoscope for traction of the tumor have been explored, but these solutions sometimes require cumbersome additional devices [6, 7].

Bordillon et al. recently demonstrated that the double-clip traction technique yields good results in terms of procedure speed and oncological outcomes [8]. Hybrid ESD (H-ESD) and underwater ESD (U-ESD) are two alternative techniques particularly suitable for challenging situations.

In H-ESD, the tumor is resected with a snare after circumferential incision and partial submucosal dissection. H-ESD simplifies the procedure when the submucosal layer is unclear or not easily approachable. This technique has been shown to be as effective and safe as standard ESD, even for rescue therapy in difficult situations [9–11].

U-ESD consists of performing an ESD in water or saline immersion. During immersion, the “floating” effect can provide good traction for submucosal dissection. Moreover, water irrigation ensures constant hydration of the submucosal layer, limiting the need for injection. Furthermore, the underwater image is magnified by the refractive index of water, working as a sort of zoom that allows more precise recognition of the dissection line [12–15].

In this study, we retrospectively evaluated the safety and effectiveness of these techniques as rescue therapy in difficult situations.

Patients and methods

Patients

This study was a retrospective analysis of prospectively collected data. All consecutive patients who underwent ESD because of a nonrecurrent colorectal neoplasm at Arcispedale Santa Maria Nuova (Reggio Emilia, Italy) between January 2014 and December 2020 were considered. All procedures were retrospectively evaluated and only those patients that were considered “difficult cases” were included in the analysis.

Lesions at high risk of significant fibrosis were excluded, as were post-EMR or postsurgical recurrence, dysplastic lesions of inflammatory bowel disease, and submucosal lesions.

A lesion was considered a “difficult case” when at least one of these conditions was present:

1. Very unstable position due to respiratory movements, heartbeat, or paradoxical movement of the colonoscope that could not be corrected by colonoscope maneuvers or by changing the patient’s decubitus position.
2. Uncomfortable inclination of the knife due to the lesion’s location (e.g. retroplical position) or anatomical condition that could not be improved by colonoscope maneuvers or by changing the patient’s decubitus position.

3. Severe submucosal fibrosis associated with moderate colonoscope instability or suboptimal inclination of knife, resulting in high risk of perforation.
4. Onset of clinical instability due to symptomatic perforation or intestinal overdistension.

In these difficult cases, U-ESD or H-ESD was performed as an alternative rescue therapy.

Pre-procedure, intra-procedure and post-procedure data for all patients were collected. Pre-procedure data included age, sex, American Society of Anesthesiologists (ASA) Physical Status Classification, lesion diameter and area and morphology of lesions, classified as protruded (0-Is, Isp), superficial (0-IIa, IIc) or laterally spreading tumor (LST) granular type (LST-G), or non-granular type (LST-NG). Intra-procedure data included procedure time, intraprocedural perforation and severity of submucosal fibrosis, which was classified as F0 (no fibrosis), F1 (mild fibrosis appearing as a white web-like structure in the blue submucosal layer) or F2 (severe fibrosis appearing as an absence of submucosal layer and white structure between mucosal and muscularis propria) [16]. Post-procedure data included histology of the resected specimen, en bloc resection, complete resection, late perforation and late bleeding, fever with bacteremia, post-polypectomy syndrome, need for surgery, recurrence, and follow-up.

All patients provided written informed consent to ESD. This retrospective study was approved by our Institutional Reviewer Board and thereafter by the Area Vasta Emilia Nord Ethics Committee on 14 January 2021. This study was registered on ClinicalTrials.gov on March 3, 2021 (NCT04780256).

Outcomes

The primary outcome of the study was en bloc resection rate, defined as resection of the neoplasm in a single piece. Secondary outcomes included the rate of complete resection, procedure speed, and incidence of adverse events (AEs). Complete resection was defined as tumor resection in a single piece with negative lateral and vertical margins. Procedure speed (mm^2/min) was calculated by dividing the area of the resected specimen (mm^2) by procedure time (minutes). Procedure time was calculated starting from the first submucosal injection until complete detachment of the neoplasm. The resected specimen area was calculated using the ellipse formula: $\text{area} (\text{mm}^2) = \text{longest length} (\text{mm}) \times \text{shortest length} (\text{mm}) \times 0.25 \times 3.14$. AEs included intraprocedural perforation, delayed perforation, delayed bleeding, post-polypectomy syndrome, and fever with bacteremia. Intraprocedural perforation was defined as the section of the colorectal muscular layer with direct visualization of peritoneal fat or retroperitoneal space. Delayed perforation was defined as presence of free air in the peritoneal or retroperitoneal space detected by abdominal radiography or abdominopelvic CT after colorectal ESD achievement. Delayed bleeding was defined as overt hematochezia or melena arising from the resection site during the 6 hours after completion of colorectal ESD. Post-polypectomy syndrome was defined as development of abdominal pain, fever, leucocytosis, and peritoneal inflammation in the absence of perforation. Fever with

bacteremia was defined as body temperature over 37.5 °C associated with bacteremia.

Statistical analysis

Categorical variables, expressed as proportions, were analyzed using the Fisher exact test or chi-squared test (χ^2). Continuous variables, expressed as means with standard deviations, were analyzed using the Student's *t*-test. $P < 0.05$ was considered statistically significant. All data analyses were performed using Microsoft Excel (Microsoft).

ESD technique and 'difficult cases'

All procedures were performed by two endoscopists (P.C. and F.A.) who had performed about 20 colorectal ESDs by the time of the first enrolled case.

Patients fasted for at least 12 hours before ESD and were monitored with pulse oximetry during the procedure. All patients were treated under sedation with fentanyl and midazolam administered by an anesthesiologist, and in selected cases with propofol. A continuous electrocardiography was also performed on patients with known cardiovascular disease or arrhythmias and during sedation with propofol.

All procedures were performed using a single-channel Fujifilm zoom gastroscope or slim zoom colonoscope (EG-760Z or EC-760ZP; Fujifilm, Tokyo, Japan) with an attached transparent tip hood (ST hood, DH-29CR or Top hood, SHM; Fujifilm, Tokyo, Japan). Several types of electrosurgical knives were used for dissection: a water jet system-assisted knife (HybridKnife; Erbe, Tübingen, Germany) or electrosurgical knife without water jet system (DualKnife, Triangle Tip Knife, KD-10-Q; Olympus, Tokyo, Japan) connected to an electrosurgical unit (VIO 3 and VIO 200D; Erbe) with carbon dioxide insufflation. In H-ESD, a single-use 15-mm or 25-mm diameter electrosurgical snare was used (Snare Master; Olympus, Tokyo, Japan) to complete the resection.

Choice of knife type was based on operator preference and to device availability. Power settings were the same for all knives used and for both techniques. Normally the "endocut q effect 3" setting was used for both mucosal incision and submucosal dissection. In case of well-vascularized submucosa, the "swift coagulation effect 3" or "spray coagulation effect 4" setting was used. When the submucosa was affected by severe fibrosis, the "endocut I" or "endocut Q" setting was used. Usually in case of bleeding, hemostatic forceps were used with the "soft coagulation effect 6" setting. During H-ESD, the electrosurgical snare was used with the "endocut q effect 2" setting.

Before starting the procedure, a Boston Bowel Preparation Scale [17] score of 9 was required to ensure good visualization of the lesion and to reduce the risk of infectious adverse events. Saline with a small amount of indigo carmine and epinephrine (0.8 mL of indigo carmine and 1 mg of adrenaline in 500 mL of saline) was used to lift the submucosa off the muscle layer. Haemostatic forceps (Hot Biopsy; Olympus, Japan) to treat and prevent bleeding were used only in cases of evident vessels.

Conventional ESD

In our center, colorectal ESDs are almost always conducted according to conventional ESD or to the tunnel technique [18, 19].

The detailed steps of conventional ESD are as follows: 1) the lesion is placed at 5 o'clock; 2) a circumferential incision of the lesion is made; 3) a progressive dissection of the lesion following the first incision and working forward or in retroversion is performed; and 4) complete removal of the lesion is obtained.

The detailed steps of the tunnel technique are as follows: (1) the lesion is placed at 5 o'clock; 2) a first incision on the proximal side of the lesion is made; 3) a second incision on the distal side of the lesion is made; 4) dissection of the lesion from the distal incision to the proximal incision is performed, creating a tunnel; 5) the dissection is widened within the tunnel toward the lateral margins; and 6) lateral margins are cut to permit the removal of the lesion.

H-ESD

The detailed steps of the H-ESD are as follows: 1) a circumferential mucosal incision and partial submucosal dissection is performed; 2) submucosal dissection is concluded when approximately 15 to 20 mm of the lesion remains attached to the muscular layer; 3) a snare is inserted into the circumferential partial dissection; and 4) the lesion is resected (► Fig. 1).

U-ESD

The detailed steps of the U-ESD are as follows: (1) the lesion is placed on the antigravity side; 2) colonic segment of interest is filled with water; and 3) steps of the conventional or of the tunnel technique are performed (► Fig. 2).

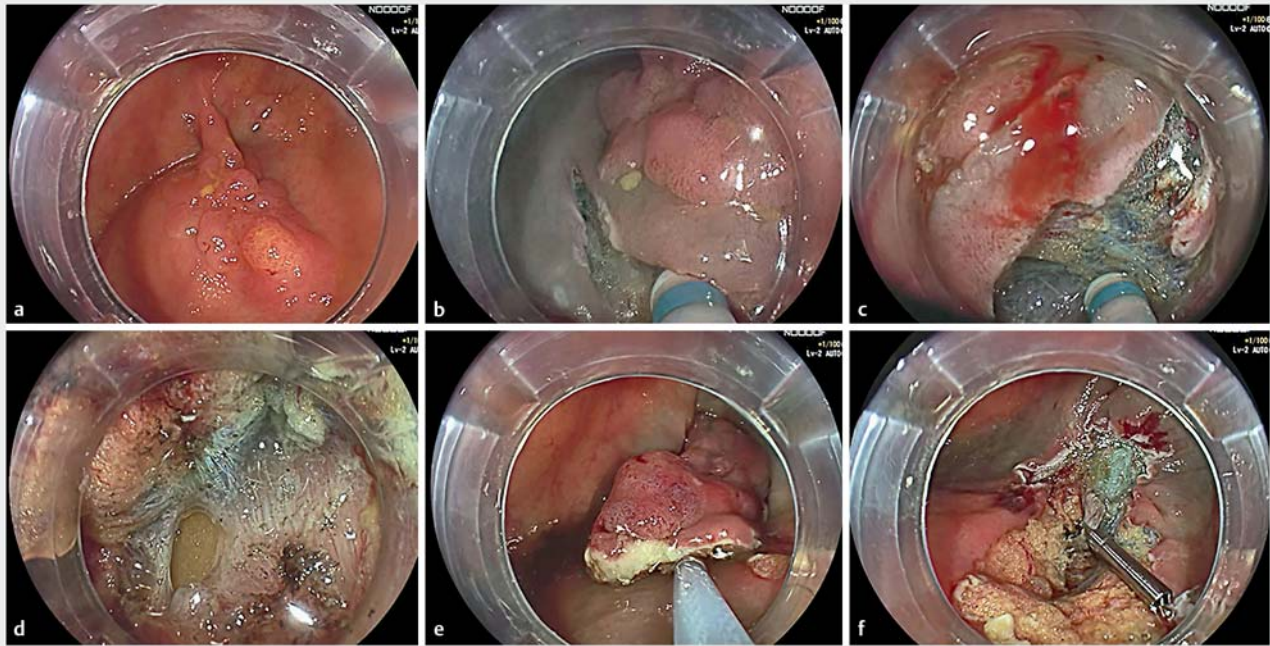
The choice of whether to perform H-ESD or U-ESD is made as a rescue therapy, so almost always when the ESD has already started and severe fibrosis, instable position and/or clinical instability are observed.

After resection, an adequate assessment of the defect is performed to identify the presence of any prominent vessels or muscular layer injuries; prominent vessels are coagulated with diathermic forceps, while muscular defects and perforation are closed with clips.

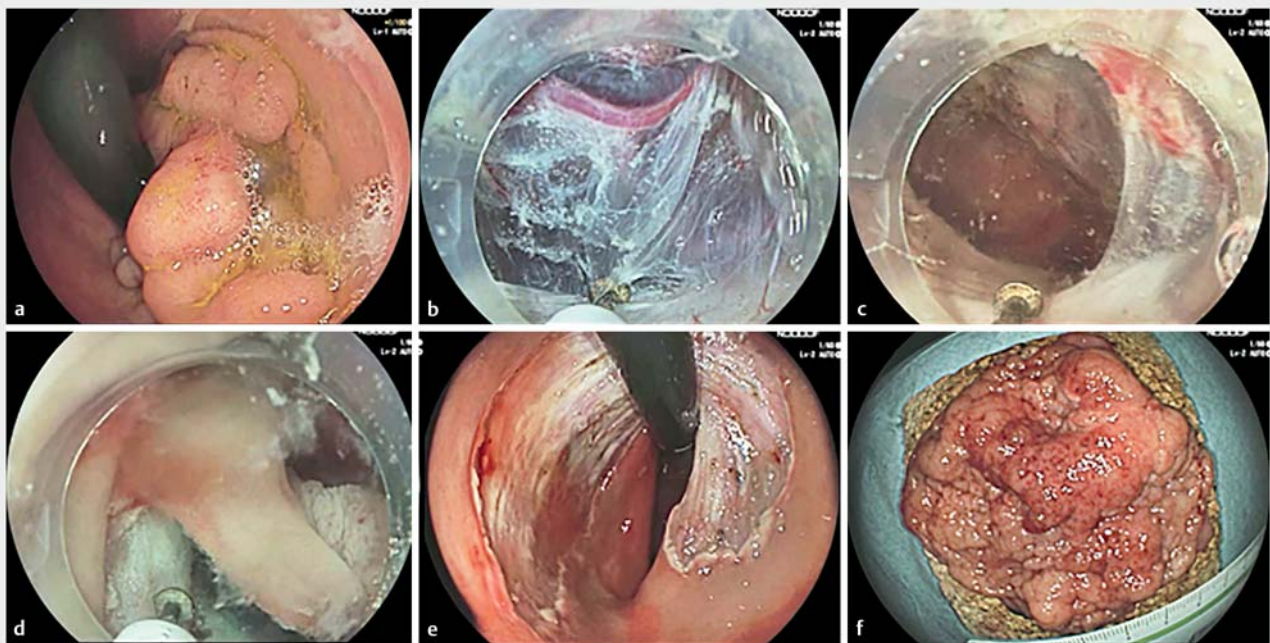
Results

Patient characteristics

Between January 2014 and February 2021, 261 colorectal lesions were removed by ESD in 254 patients at the Arcispedale Santa Maria Hospital (Reggio Emilia, Italy). Seventy-five recurrent adenomas after endoscopic resection, three dysplastic lesions of inflammatory bowel diseases, and nine submucosal tumors were excluded (► Fig. 1). Of the 174 lesions remaining, 59 (in 56 patients) were considered "difficult cases" and were included in the study. Twenty-two lesions were removed by U-ESD in 22 patients and 37 by H-ESD in 36 patients. In one patient, two lesions were removed by H-ESD, and in two other patients, two lesions were removed, one by U-ESD and one by H-ESD (► Fig. 3).



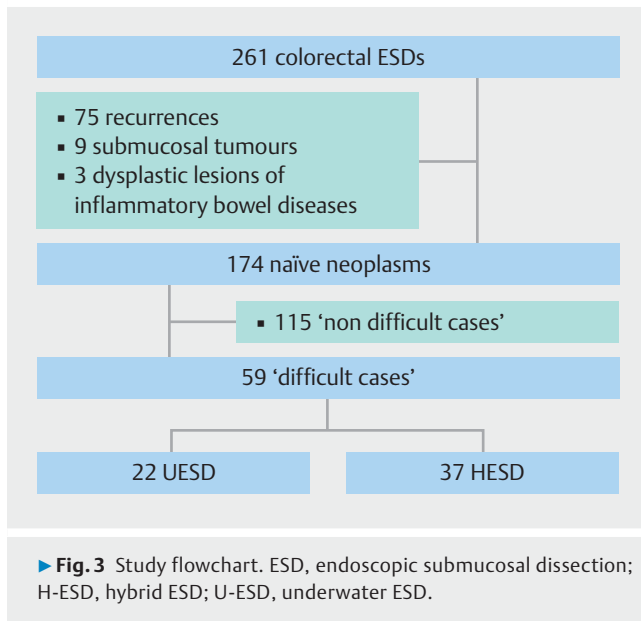
► **Fig. 1** Steps in hybrid ESD. **a** View of a laterally spreading tumor-granular type of the ascending colon. **b** Circumferential incision was started. **c** Partial submucosal dissection was performed which encountered discrete fibrosis. **d** Perforation occurred. **e** The perforation was closed with a clip, and the neoplasm was fully captured with the snare and resected. **f** View after resection.



► **Fig. 2** Steps in underwater ESD. **a** View of a laterally spreading rectal tumor-granular type. **b** Underwater endoscopic submucosal dissection. **c** Tunnel was performed. **d** Lateral margins were cut. **e** View after resection. **f** Neoplasm resected en bloc.

Baseline characteristics of the enrolled patients and lesions are reported in ► **Table 1**. U-ESD and H-ESD lesion characteristics are shown in ► **Table 2**.

The hybrid technique was mainly used in cases of unstable position (14 cases) and severe fibrosis associated with unstable or suboptimal position (11 cases) and less frequently in cases of



uncomfortable position of the knife (7 cases) and clinical instability due to intestinal overdistension or perforation (5 cases). The underwater technique was chosen mainly in cases of markedly unstable position (6 cases) or uneasy angle between the knife and the dissection plane (13 cases) and less frequently in cases of severe submucosal fibrosis (1 case) or clinical instability (2 cases). The difference between the two techniques was significant when the reason for rescue therapy was uncomfortable position of the knife ($P=0.002$) and presence of severe submucosal fibrosis ($P=0.022$).

Most lesions were located in the right colon (55.9%); U-ESD was performed for 68.2% of granular lesions and H-ESD was used for 56.8% of non-granular ones.

Submucosal fibrosis was prevalent in the analyzed population (F1-F2 in 74.6% of patients) and severe fibrosis (F2) was significantly more frequent in lesions removed by H-ESD (29.7% vs 4.5%, $P=0.022$).

Neoplasms removed by U-ESD were significantly larger than those removed by H-ESD (44.5 mm vs 26.6 mm; $P<0.001$).

Histological findings from resected lesions are described in ► **Table 1**. There was no significant difference in histological types between the two groups.

Study outcomes

Outcomes of the two techniques are summarized in ► **Table 3**.

The en bloc resection rate was 100% for U-ESD and 59.5% for H-ESD. Dissection speed was 17.7 mm²/min for U-ESD and 8.3 mm²/min for H-ESD. The rate of AEs was low in the U-ESD group and moderately high in the H-ESD group (5% and 21.6%, respectively), such as the perforation rate (0% and 10.8%, respectively).

Follow-up was available for 13 patients treated with U-ESD and for 20 with H-ESD, with mean values of 9.4 and 16.3 months, respectively. No patient had recurrence in the U-ESD group, while only one patient had a local recurrence after H-ESD. In this patient, the procedure was very long due to recur-

► **Table 1** Baseline characteristics of the enrolled patients and lesions.

Age, years, mean \pm SD	69.4 \pm 10.5
Sex (male/female)	36/20
ASA score, n (%)	
▪ 1,2	44/56 (78.6)
▪ 3	12/56 (21.4)
Tumor site, n (%)	
▪ Right colon	33/59 (55.9)
▪ Left colon	12/59 (20.4)
▪ Rectum	14/59 (23.7)
Macroscopic type, n (%)	
▪ LST-G	26/59 (44.1)
▪ LST-NG	28/59 (47.4)
▪ Sessile	5/59 (8.5)
Major diameter, mm, mean (SD)	33.3 (17.7)
Specimen area, cm ² , mean (SD)	7.9 (9.3)
Fibrosis, n (%)	
▪ F0	15/59 (25.4)
▪ F1	32/59 (54.2)
▪ F2	12/59 (20.4)
Pathological diagnosis, n (%)	
▪ LGD	7/59 (11.9)
▪ HGD	34/59 (57.6)
▪ pT1	18/59 (30.5)
ASA, American Society of Anesthesiologists; LST, laterally spreading tumour; G, granular; NG, non-granular; SD, standard deviation; LGD, low-grade dysplasia; HGD, high-grade dysplasia.	

rent bleeding and difficult sedation, and the neoplasm was removed with H-ESD in a piecemeal fashion. The recurrence was subsequently successfully treated with ESD.

Discussion

This retrospective analysis demonstrates that U-ESD and H-ESD are both effective and safe as rescue therapy in difficult colorectal ESD. U-ESD yields a better en bloc resection rate than does H-ESD and, although this was not a comparison trial, it also appeared to be faster, with an average procedure speed similar to the standard technique [15].

In this series of patients, most of the resected lesions were in the right colon. ESD in the colon is complex and challenging and requires that the operator be experienced. The main factors that make it difficult are position stability and clear visualization of the submucosal layer. Furthermore, colonic ESD can be even more technically complex because of anatomical positions that are not easily accessible, such as flexures and retro-

► **Table 2** Comparison of lesion characteristics between underwater ESD and hybrid ESD.

	Underwater ESD n = 22	Hybrid ESD n = 37	P value ¹
Location, n (%)			0.415
▪ Right colon	10 (45.5)	23 (62.2)	0.211
▪ Left colon	5 (22.7)	7 (18.9)	0.725
▪ Rectum	7 (31.8)	7 (18.9)	0.260
Macroscopic type, n (%)			
▪ LST-NG	7 (31.8)	21 (56.8)	0.063
▪ LST-G	15 (68.2)	11 (29.7)	0.004
▪ Sessile	0	5 (13.5)	0.146
Fibrosis, n (%)			0.001
▪ F0	11 (50)	4 (10.8)	0.001
▪ F1	10 (45.5)	22 (59.5)	0.296
▪ F2	1 (4.5)	11 (29.7)	0.022
Area, cm ² , mean (SD)	13.2 (11.7)	4.8 (5.4)	<0.001
Major diameter, mm, mean (SD)	44.5 (17.8)	26.6 (14.1)	<0.001
Pathological diagnosis, n (%)			0.303
▪ LGD	1 (4.5)	6 (15)	0.240
▪ HGD	15 (68.2)	19 (50)	0.205
▪ T1	6 (27.3)	12 (35)	0.677
Follow-up available, n (%)	13 (59.1)	20 (54.5)	
▪ Follow-up, month, mean (SD)	9.4 (4.3)	16.3 (11.9)	0.011
Reason for rescue therapy n (%)			
▪ Very unstable position	6 (27.3)	14 (37.9)	0.407
▪ Uncomfortable inclination of the knife	13 (59.1)	7 (18.9)	0.002
▪ Severe submucosal fibrosis	1 (4.5)	11 (29.7)	0.022
▪ Clinical instability due to intestinal overdistension or perforation	2 (9.1)	5 (13.5)	0.702

ESD, endoscopic submucosal dissection; LST, laterally spreading tumour; G, granular; NG, non-granular; SD, standard deviation; LGD, low-grade dysplasia; HGD, high-grade dysplasia.

¹ χ^2 test when $n \geq 5$; Fisher exact test when $n < 5$; T-student for; unpaired two-tailed t-test used for comparison of means.

plical site. Finally, the procedure can be challenging because of a patient's clinical instability due to intestinal overdistension or symptomatic perforation.

In these difficult situations, various techniques have been proposed to facilitate exposure of the submucosal plane, position stability, and lesion visualization and to speed up the procedure. Good results have been obtained with traction techniques that, through the use of surgical threads and clips or specific devices, allow the operator to expose the submucosal plane during the procedure, facilitating dissection even when the submucosa is poorly represented or very fibrotic, as in recurrent adenomas and initially infiltrating neoplasms [6–8]. However, these techniques do not improve stability of position

and they require specific devices that are not always available. Concerning the stability of the instrument, a double-balloon endoluminal intervention platform has been proposed to improve stability during complex ESD procedures [20]. The limits of this technique are need for a specific device, its cost, and the specific learning curve.

H-ESD and U-ESD do not require specific devices and can be performed in any situation. H-ESD involves a partial submucosal dissection of the lesion followed by resection with a conventional snare. This technique aims to speed up resection, especially in unstable positions, and to reduce risk of perforation when the submucosal layer is poorly represented. The underwater technique, the effectiveness of which has already been

► **Table 3** Outcomes of underwater and hybrid ESD.

	Underwater ESD n=22	Hybrid ESD n=37
En bloc resection (%)	22 (100)	22 (59.5)
Complete resection (%)	22 (100)	20 (54.5)
Adverse events (%)	1 (5)	8 (21.6)
▪ Perforation	0	4 (10.8)
▪ Bleeding	0	4 (10.8)
▪ Bacteremia	1 (5)	1 (2.7)
Procedure speed, mm ² /min, mean (SD)	17.7 (11.6)	8.3 (4.9)
▪ Recurrence, n (%)	0 (0%)	1 (2.7%)

ESD, endoscopic submucosal dissection.

amply demonstrated for EMR, consists of performing an ESD after filling the colon tract of interest with water.

In this preliminary experience, we investigated the effectiveness and safety of U-ESD and H-ESD as rescue treatment in difficult cases.

The two techniques are very different, and thus, cannot be compared. For example, lesions size appears to be significantly different, with lesions treated with U-ESD being significantly larger. Furthermore, granular LSTs are more represented in the group of patients treated with U-ESD and non-granular ones in the H-ESD group. Finally, lesions treated with H-ESD have a higher incidence of submucosal fibrosis than those treated with U-ESD. These differences are likely due to the fact that small and fibrotic lesions were preferentially removed en bloc by a hybrid technique. An interesting finding is that non-granular LSTs appear to have a larger fibrotic component than do granular ones, but this observation deserves to be confirmed by larger series.

U-ESD showed a high rate of en bloc resection and a high resection speed, which are consistent with results of other published experiences [12–15].

Recently, there has been emerging interest in water-aided endoscopic resection, and underwater EMR has become an increasingly recognized technique for resection of mucosal colorectal lesions [21, 22]. This technique has also been applied to ESD with excellent results, such as those we obtained. In particular, the high en bloc resection rate and speed of dissection, despite the challenging situations, and use of this technique mainly in lesions with uncomfortable angle of the knife (e.g. retroflex lesions) could be explained by some of its advantages: 1) the “floating” effect, which works as a traction technique throughout the procedure; 2) continuous hydration of the submucosal layer, which improves visualization and reduces the need of injection; 3) magnification of the image due to the refractive index (1.3) helps to distinguish between the layers and to isolate submucosal vessels; and 4) filling the colon with water instead of gas stabilizes the scope position and renders it less responsive to a patient’s breathing movements, making the

procedure more tolerable, and it respects the physiological conformation, reducing the obstacle represented by the colorectal folds and by the colonic angulations.

In contrast, H-ESD was associated with a low en bloc resection rate and was used mainly in lesions with severe submucosal fibrosis. Submucosal fibrosis, when severe and associated with a nonoptimal position, makes the submucosal plane unrecognizable. In these situations, use of H-ESD was preferred to reduce the risk of perforation. Previous studies that considered H-ESD as rescue therapy reported an en bloc resection rate ranging from 64% to 66%. The principal mechanism that explains this result could be insufficient partial submucosal dissection, which can cause slipping of the snare, especially when submucosal fibrosis is relevant, leading to failed en bloc resection [9].

Regarding AEs, the perforation rate was 0% in the U-ESD group and 10.8% in the H-ESD group; however, the difference was not statistically significant ($P=0.286$) because of the smaller sample size. The perforation rate in the H-ESD group was slightly higher, probably because the population investigated was made up of only difficult cases, with a high number of cases with severe submucosal fibrosis [16]. Furthermore, two perforation cases were allocated to the H-ESD group because this technique was carried out as a rescue treatment option when perforation and pain occurred during conventional ESD. In any event, all perforations were successfully managed, with no need for further surgery.

Despite the very low risk of perforation observed with the underwater technique, a debated point in literature is represented by the risk of peritoneal spread of neoplastic cells with fluids in case of perforation. This risk is only hypothetical and has not been proven; therefore, long-term follow-up studies are needed to evaluate this concern.

In a mean follow-up of 9.4 months for U-ESD and 16.3 months for H-ESD, only one patient (H-ESD group) had a recurrence. This was a particularly complex procedure, with severe intraprocedural bleeding that considerably lengthened the procedural time. The recurrence was subsequently treated with an ESD, and no further residue was observed at subsequent follow-up.

Our study has several limitations, the first being its retrospective nature. Second, the two groups were small and heterogeneous and, therefore, not comparable. But the most obvious potential study flaw is the historical bias; we tested the bias by comparing the outcome of the first 20 ESDs enrolled with the last 20 ESDs. The comparison did not show any significant differences, and we could exclude any learning curve effect on the final outcome (en bloc resection of first 20 cases vs last 30 cases: 95% vs 95%, respectively, $P=1$; switch to hybrid ESD of first 20 cases vs last 30 cases: 10% vs 20%, respectively, $P=0.661$). For these reasons, the results of this study should be considered as preliminary results that should be validated in prospective studies.

Conclusions

U-ESD and H-ESD are both effective, safe techniques to be considered in difficult colorectal situations. The underwater technique seems to guarantee a high en bloc resection rate and good speed of execution, especially in large granular lesions, and mainly when an uncomfortable approach to the lesion is encountered, whereas H-ESD can be useful for little non-granular lesions with severe submucosal fibrosis.

Competing interests

The authors declare that they have no conflict of interest.

Clinical trial

ClinicalTrials.gov
NCT04780256
TRIAL REGISTRATION: Single-Center, Observational, Retrospective Cohort study at <https://www.clinicaltrials.gov/>

References

- [1] Saito Y, Uraoka T, Yamaguchi Y et al. A prospective, multicenter study of 1111 colorectal endoscopic submucosal dissections (with video). *Gastrointest Endosc* 2010; 72: 1217–1225
- [2] Tanaka S, Kashida H, Saito Y et al. JGES guidelines for colorectal endoscopic submucosal dissection/endoscopic mucosal resection. *Digestive Endosc* 2015; 27: 417–434
- [3] Fujiya M, Tanaka K, Dokoshi T et al. Efficacy and adverse events of EMR and endoscopic submucosal dissection for the treatment of colon neoplasms: a meta-analysis of studies comparing EMR and endoscopic submucosal dissection. *Gastrointest Endosc* 2015; 81: 583–595
- [4] Hayashi N, Tanaka S, Nishiyama S et al. Predictors of incomplete resection and perforation associated with endoscopic submucosal dissection for colorectal tumors. *Gastrointest Endosc* 2014; 79: 427–435
- [5] Sato K, Ito S, Kitagawa T et al. Factors affecting the technical difficulty and clinical outcome of endoscopic submucosal dissection for colorectal tumors. *Surg Endosc* 2014; 28: 2959–2965
- [6] Sakamoto N, Osada T, Shibuya T et al. Endoscopic submucosal dissection of large colorectal tumors by using a novel spring-action SO clip for traction (with video). *Gastrointest Endosc* 2009; 69: 1370–1374
- [7] Uraoka T, Kato J, Ishikawa S et al. Thin endoscope-assisted endoscopic submucosal dissection for large colorectal tumors (with videos). *Gastrointest Endosc* 2007; 66: 836–839
- [8] Bordillon P, Pioche M, Wallenhorst T et al. Double-clip traction for colonic endoscopic submucosal dissection: a multicenter study of 599 consecutive cases (with video). *Gastrointest Endosc* 2021; 94: 333–343
- [9] Okamoto K, Muguruma N, Kagemoto K et al. Efficacy of hybrid endoscopic submucosal dissection (ESD) as a rescue treatment in difficult colorectal ESD cases. *Dig Endosc* 2017; 29: 45–52
- [10] McCarty TR, Bazarbashi AN, Thompson CC et al. Hybrid endoscopic submucosal dissection (ESD) compared with conventional ESD for colorectal lesions: a systematic review and meta-analysis. *Endoscopy* 2021; 53: 1048–1058
- [11] Bae JH, Yang DH, Lee S et al. Optimized hybrid endoscopic submucosal dissection for colorectal tumors: a randomized controlled trial. *Gastrointest Endosc* 2016; 83: 584–592
- [12] Yoshii S, Akasaka T, Hayashi Y et al. “Underwater” endoscopic submucosal dissection: a novel method for resection in saline with a bipolar needle knife for colorectal epithelial neoplasia. *Surg Endosc* 2018; 32: 5031–5036
- [13] Nagata M. Usefulness of underwater endoscopic submucosal dissection in saline solution with a monopolar knife for colorectal tumors (with videos). *Gastrointest Endosc* 2018; 87: 1345–1353
- [14] Cecinato P, Bassi F, Sereni G et al. Underwater endoscopic submucosal dissection of a non-granular laterally spreading tumor of the hepatic flexure. *Endoscopy* 2020; 52: E426–E427
- [15] Harada H, Nakahara R, Murakami D et al. Saline-pocket endoscopic submucosal dissection for superficial colorectal neoplasms: a randomized controlled trial (with video). *Gastrointest Endosc* 2019; 90: 278–287
- [16] Matsumoto A, Tanaka S, Oba S et al. Outcome of endoscopic submucosal dissection for colorectal tumors accompanied by fibrosis. *Scand J Gastroenterol* 2010; 45: 1329–1337
- [17] Calderwood AH, Jacobson BC. Comprehensive validation of the Boston Bowel Preparation Scale. *Gastrointest Endosc* 2010; 72: 686–692
- [18] Zou J, Chai N, Linghu E et al. Efficacy and safety of endoscopic submucosal tunnel dissection for rectal laterally spreading tumors. *Surg Endosc* 2021; 35: 4356–4362
- [19] Yang JL, Gan T, Zhu LL et al. Endoscopic submucosal tunnel dissection: a feasible solution for large superficial rectal neoplastic lesions. *Dis Colon Rectum* 2017; 60: 866–871
- [20] Ismail MS, Bahdi F, Mercado MO et al. ESD with double-balloon endoluminal intervention platform versus standard ESD for management of colon polyps. *Endosc Int Open* 2020; 8: E1273–E1279
- [21] Choi AY, Moosvi ZM, Shah S et al. Underwater versus conventional endoscopic mucosal resection for colorectal polyps: a systematic review and meta-analysis. *Gastrointest Endosc* 2021; 93: 378–389
- [22] Maida M, Sferrazza S, Murino A et al. Effectiveness and safety of underwater techniques in gastrointestinal endoscopy: a comprehensive review of the literature. *Surg Endosc* 2021; 35: 37–51