

Cystic endometrial hyperplasia and uterine adenocarcinoma in two miniature pigs

Zystische Endometriumshyperplasie und uterines Adenokarzinom bei zwei Minipigs



Authors

Sophie Dürlinger¹, Christian Knecht¹, Michaela Gumpenberger², René Brunthaler³, Andrea Ladinig¹, Sabine Schäfer-Somi⁴



Institutes

- 1 University Clinic for Swine, Department for Farm Animals and Veterinary Public Health, University of Veterinary Medicine Vienna, Austria
- 2 Diagnostic Imaging, Department for Companion Animals and Horses, University of Veterinary Medicine Vienna, Austria
- 3 Institute for Pathology, Department of Pathobiology, University of Veterinary Medicine Vienna, Austria
- 4 Platform Artificial Insemination and Embryo Transfer, Department for Companion Animals and Horses, University of Veterinary Medicine Vienna, Austria

Schlüsselwörter

Schwein, Ovariohysterektomie, Uterusadenokarzinom, glandulär-zystische Endometriumshyperplasie

Key words

Pig, ovariectomy, uterine adenocarcinoma, cystic endometrial hyperplasia

received 07.02.2022

accepted 05.05.2022

Bibliografie

Tierarztl Prax Ausg G Grosstiere Nutztiere 2022; 50: 333–339

DOI 10.1055/a-1877-4487

ISSN 1434–1220

© 2022. The Author(s).

This is an open access article published by Thieme under the terms of the Creative Commons Attribution-NonDerivative-NonCommercial-License, permitting copying and reproduction so long as the original work is given appropriate credit. Contents may not be used for commercial purposes, or adapted, remixed, transformed or built upon. (<https://creativecommons.org/licenses/by-nc-nd/4.0/>)

Georg Thieme Verlag KG, Rüdigerstraße 14,
70469 Stuttgart, Germany

Korrespondenzadresse

Sophie Dürlinger

Klinik für Schweine

Veterinärmedizinische Universität Wien

Veterinärplatz 1

1210 Wien

Österreich

sophie.duerlinger@vetmeduni.ac.at

ZUSAMMENFASSUNG

Aufgrund der stetig steigenden Beliebtheit von Minipigs als Haustiere, werden diese immer häufiger in der Praxis vorgestellt. Neben Routinemaßnahmen wie Klauenkorrektur, Impfung und antiparasitärer Behandlung gehören auch Diagnostik und Therapie erkrankter Minipigs zu den gängigen Tätigkeiten in der tierärztlichen Praxis. In den letzten Jahren wurden vermehrt pathologische Veränderungen des weiblichen Geschlechtsstraktes unkastrierter Minipigs beobachtet. Auch in der internationalen Literatur finden sich einige Fallberichte zu diesem Thema. Im vorliegenden Fallbericht werden das diagnostische Verfahren und die Ovariohysterektomien von 2 13-jährigen weiblichen Minischweinen detailliert beschrieben. In beiden Fällen wurden ein Uterusadenokarzinom bzw. ein Uteruskarzinom sowie eine glandulär-zystische Hyperplasie des Endometriums (HGCE) diagnostiziert.

ABSTRACT

Due to the increasing popularity of minipigs as pets, the frequency of presentation to the veterinarian is increasing as well. In addition to routine measures such as claw trimming, vaccination and antiparasitic treatment, diagnostics, and therapy of diseased minipigs are also common activities in the veterinary practice. In recent years, we have noticed more and more pathological changes of the female genital tract of uncastrated minipigs. There are also some case reports available in the international literature in this regard. The following case report describes the diagnostic procedures and ovariectomies of 2 13-year-old female minipigs in detail. In these cases, uterine adenocarcinoma, and uterine carcinoma, respectively, combined with cystic endometrial hyperplasia (CEH) of the endometrium were diagnosed.

Introduction

Miniature pigs, also called minipigs, are varieties of the domesticated pig, *Sus scrofa domestica*, and are considered as highly interesting laboratory animals for human research, because of their similarity in anatomy and physiology [1][2]. However, over the years they became popular pets as well [3].

In the Austrian animal husbandry regulation, pigs are classified as minipigs, if, due to their breed, they do not exceed a body weight of 120 kg as adult animals [4]. The owners are often not aware that adult animals can achieve a rather high body weight, which can result in a challenge to keep and handle these animals. However, it is important to know, that the same legal requirements regarding animal transportation, identification, and medication as to food-producing animals apply to minipigs, which are kept as companion animals. Unlike in horses, there is no possibility to change this status.

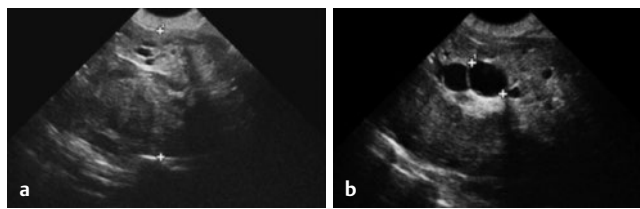
In contrast to pigs kept as farm animals, minipigs often reach a relatively high age of 15 to 20 years as pets, which can be accompanied by diseases that are typical of older age, such as neoplasia [1][5]. Like in many other neoplasias, the incidence of uterine tumors increases significantly with the age of the animals. This could be the reason why tumors are rarely diagnosed in farm animals, which are slaughtered at a relatively young age [6][7]. It has been described that in 32 female, ovariectomized minipigs, uterine lesions, such as cystic endometrial hyperplasia, leiomyoma, leiomyosarcoma, adenocarcinoma, adenoma and adenomyosis were more often found in older animals [8]. There are already several case reports describing uterine leiomyoma, uterine adenocarcinoma, and cystic endometrial hyperplasia of the endometrium (CEH) in minipigs aged between 8 and 16 years. In these cases, the symptoms usually started unspecific and ranged from reduced general behavior, anorexia, and weight loss to lameness, abdominal distension, and vaginal discharge [5][8][9][10][11][12][13]. Due to the non-specific symptoms, genital tumors are often diagnosed very late. In some of the case reports, the neoplasms were even diagnosed too late and euthanasia was indicated [5][9][11][12].

The following case report describes in detail the diagnostic procedure and the ovariectomies in 2 13-year-old female minipigs, which were siblings and kept by the same owner. In both cases, successful ovariectomy was performed after the tentative diagnosis of a uterine pathology; the clinical symptoms were variable and unspecific, and sonography was essential for decision-making. Finally, a uterine adenocarcinoma and a uterine carcinoma, in both cases combined with cystic hyperplasia of the endometrium, were diagnosed. This case report shall help practitioners to be able to diagnose and treat these animals correctly, and to advise owners concerning the prophylaxis.

Case 1

Anamnesis and clinical examination

During a routine home visit for vaccination, antiparasitic treatment and claw trimming, the owner of 2 13-year-old female minipigs reported recurrent vaginal discharge in 1 of her 2 minipigs. The minipigs had a body weight of 44 and 46.3 kg, respectively and were never bred. Due to the bloody vaginal discharge, a brief examination with a mobile ultrasound device was done, but an exact dia-



► **Fig. 1** Sonography of the abdomen. **a** Pathological uterine horn base: The picture shows the uterine mass with a diameter of 5.57 cm, circumscribed by the white crosses. The structure is inhomogeneous, with many cysts inside the tissue (Apparature: Esaote MyLab, probe: 6.6 Mhz). **b** Endometrial cyst: A large cyst inside the uterine mass is circumscribed by white crosses. The diameter was 1.69 cm. The uterine lumen was in part filled with these cysts. Source: S. Schäfer-Somi.

► **Abb. 1** Sonographie des Abdomens. **a** Pathologisches Uterushorn: Die Abbildung zeigt die Masse in der Gebärmutter mit einem Durchmesser von 5,57 cm, die durch die weißen Kreuze markiert ist. Die Struktur ist inhomogen, mit zahlreichen Zysten im Inneren des Gewebes (Gerät: Esaote MyLab, Sonde: 6,6 Mhz). **b** Endometriumzyste: Eine große Zyste im Inneren der Gebärmutter ist durch weiße Kreuze markiert. Der Durchmesser betrug 1,69 cm. Das Uteruslumen war zum Teil mit diesen Zysten ausgefüllt. Quelle: S. Schäfer-Somi.

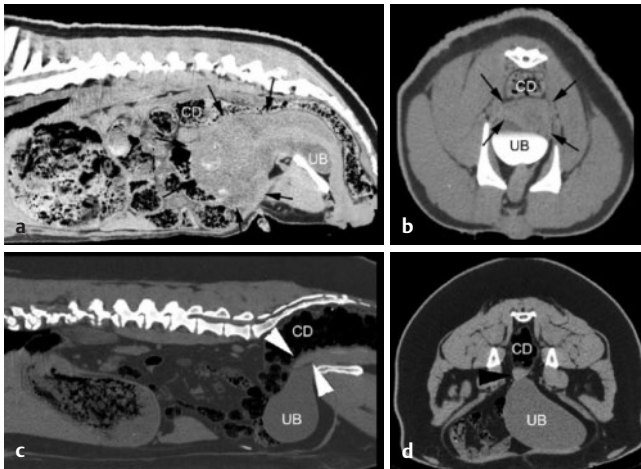
gnosis could not be made at this time. Therefore, a vaginal swab for cytology and bacteriological examination was taken. Since the animal did not show any other clinical symptoms, the owner was advised to contact the veterinarian immediately in case of clinical symptoms or changes in behavior. The cytological examination revealed presence of high grade degenerated leucocytes in the discharge. Ten days later, there was still vaginal discharge visible but unlike before, it seemed purulent. This was in accordance with the bacteriological results of the vaginal swab; high grade *Streptococcus dysgalactiae* or *canis*, *Staphylococcus chromogenes* and medium grade *Pseudomonas* sp. were found. Due to the persistent vaginal discharge and the bacteriological findings, the minipig was referred to the University Clinic for Swine at the University of Veterinary Medicine in Vienna (Austria) for further diagnostic work up.

Further examinations

The minipig was admitted to the University Clinic for Swine and a clinical examination was done which revealed only physiological findings. Furthermore, an ultrasound was performed: the urinary bladder appeared physiological, but was surrounded by a heterogeneous structure, which was in part highly hyperechogenic and in part showed cystic changes with a diameter of up to 2 cm. The uterine diameter was in part more than 5 cm (► **Fig. 1**).

An infectious inflammation of the uterus in combination with a polycystic ovarian syndrome was considered as the most likely differential diagnosis. In the cytological examination of the vaginal fluid, a high number of leukocytes and erythrocytes were found. Based on the results of the ultrasound examination, a laparotomy was considered.

Four days later, the minipig was anesthetized and a preoperative contrast enhanced computed tomography was performed to gain additional information about the situs for surgery, to rule out additional pathological changes and partially for scientific purposes.



► **Fig. 2** Sagittale (a, b) und transversale (c, d) CT-Bilder im Weichteilfenster (a, c kontrastverstärkt) von 2 Schweinen. Abbildungen a und c zeigen das Tier aus Fall 1, b und d das Tier aus Fall 2, 2 Jahre nach der Operation. Pfeile zeigen die Masse in der Gebärmutter von Fall 1, Pfeilspitzen zeigen den Gebärmutterstumpf von Patientin 2. UB: Harnblase (kontrastverstärkt in c), CD: Colon descendens. Quelle: M. Gumpenberger

► **Abb. 2** Sagittale (a, b) und transversale (c, d) CT-Bilder im Weichteilfenster (a, c kontrastverstärkt) der 2 Schweine. Abbildungen a und c zeigen das Tier aus Fall 1, b und d das Tier aus Fall 2, 2 Jahre nach der Operation. Die Pfeile zeigen die Masse in der Gebärmutter von Fall 1, Pfeilspitzen zeigen den Gebärmutterstumpf von Patientin 2. UB: Harnblase (kontrastverstärkt in c), CD: Colon descendens. Quelle: M. Gumpenberger.

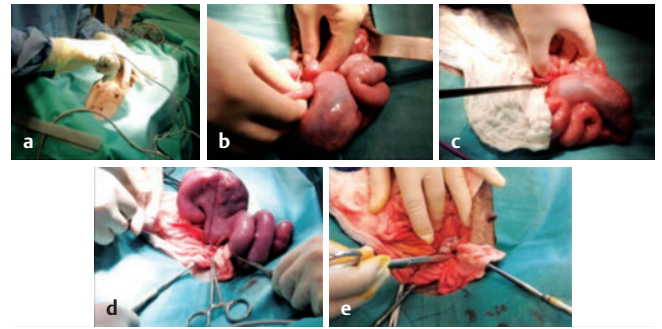
For general anesthesia, the pig was premedicated with azaperone (1.5 mg/kg) and ketamine (10 mg/kg) intramuscularly. The trachea was intubated with an appropriately sized cuffed endotracheal tube. General anaesthesia was maintained with isoflurane (Vetflurane, Virbac S. A., France) in oxygen using a circle breathing system connected to an anaesthesia machine (Leon Plus, Löwenstein Medical, Germany). Heart rate, electrocardiogram, pulse oximetry, respiratory rate, inspired and expired concentrations of oxygen, carbon dioxide and volatile anaesthetic agent, as well as oesophageal temperature were monitored continuously (Intellivue MP60, Philips, Germany) and registered every 5 minutes. To ensure adequate analgesia, 0.2 mg/kg butorphanol was administered intravenously at the beginning of surgery. Since the range of drugs for pigs is limited, in this case isoflurane and butorphanol were used off-label according to the Veterinary Medicines Control Act.

In the contrast enhanced computed tomography, a large, well-circumscribed, heterogeneous mass in the caudal abdomen and pelvic cavity was found (~14 cm length and ~9 cm width). This mass showed multiple irregular mineralizations in the cranial portion and multifocal cystic non-enhancing areas. The bladder was dislocated to caudal and the descending colon to cranial (► **Fig. 2**).

The main differential diagnoses were neoplasia or cystic endometrial hyperplasia. Based on the findings of computed tomography, removal of the well demarcated mass seemed possible.

Surgical procedure

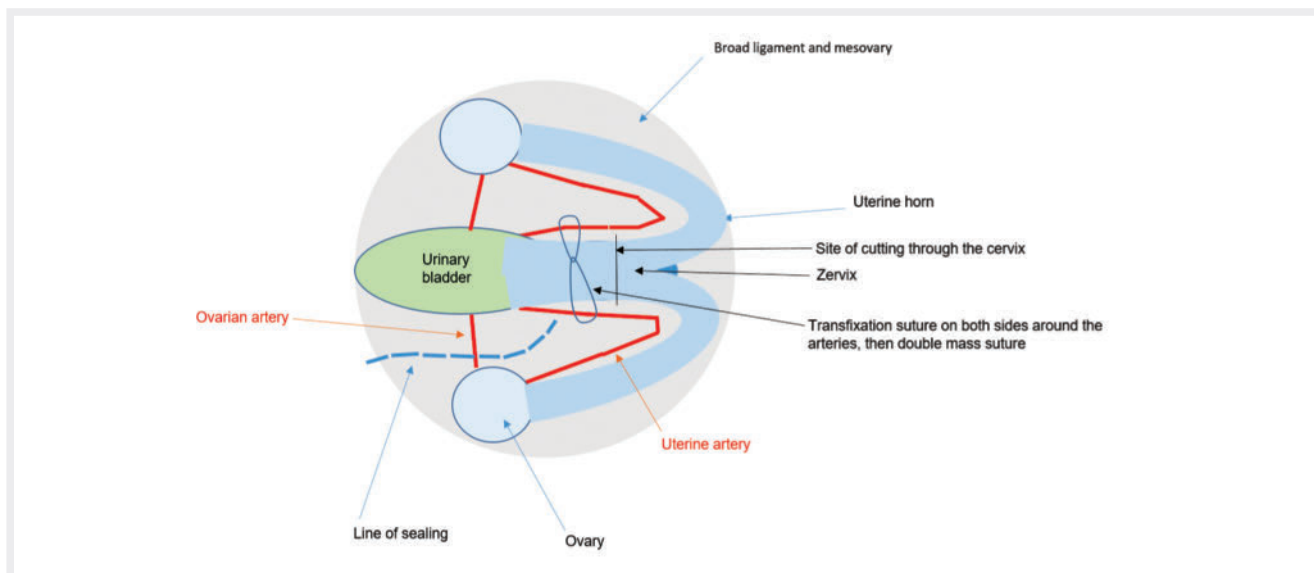
The skin and subcutaneous tissue were incised in the ventral midline by using a sealer (► **Fig. 3a**). The abdominal wall was opened



► **Fig. 3** Surgical procedure. **a** Skin incision using a sealer: A skin incision was made with the sealer, and then the fat departed manually onto the fascia. The abdominal wall was opened by using a scalpel, however, before the peritoneum was opened, it was lifted by use of two forceps, to prevent organ lesions. **b** Uterine horns, mass in the left horn base and ovary: Note the enlarged uterine horns with variable diameter. On the ovaries, cysts were present. **c** Sealing of the mesovary, ovarian artery and mesometrium using LigaSure™: The sealing device (LigaSure™) is positioned under the uterine tube (salpinx) which has to be completely removed, then the mesovary is sealed and cut. The picture shows that the distance between mesovary and cervix is very short; care must be taken not to lacerate the uterine artery by chance. **d** Fixed mass suture situated without penetration of the uterine lumen (seromuscular transfixation), then a double mass suture was placed behind the cervix. Material: monofil, resorbable (Biosyn 0; Medtronic, Meerbusch, Germany). **e** Cervical stump after excision of mucus membranes and Lembert suture: The stump was cleaned from mucous membranes and disinfected before closure with a continuous suture. This was done to reduce the size and to prevent adhesions. Source: S. Schäfer-Somi.

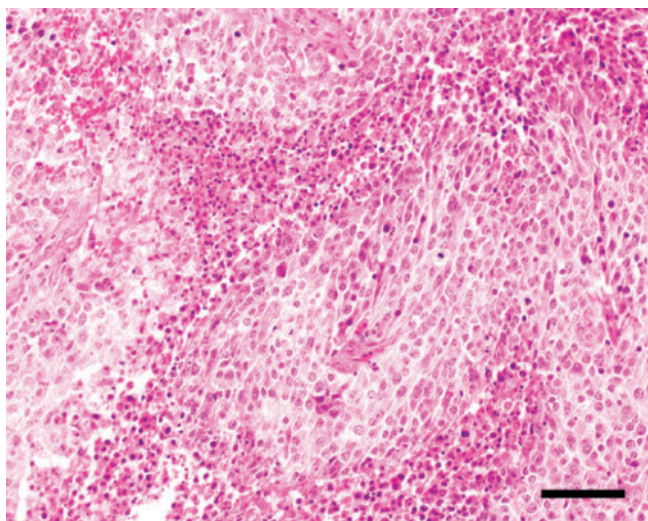
► **Abb. 3** Chirurgisches Verfahren. **a** Hautschnitt unter Verwendung eines Sealers: Mit dem Sealer wurde ein Hautschnitt vorgenommen und das subkutane Fett wurde manuell bis auf die Faszie abgetragen. Bevor das Bauchfell mit einem Skalpell eröffnet wurde, wurde es mit zwei Pinzetten angehoben, um Verletzungen der Organe zu vermeiden. **b** Uterushörner, Masse an der linken Hornbasis und am Eierstock: Man beachte die vergrößerten Uterushörner mit variablem Durchmesser. An den Eierstöcken waren Zysten zu sehen. **c** Versiegelung des Mesovars, der Ovarialarterie und des Mesometriums mit LigaSure™: Das Versiegelungsgerät (LigaSure™) wird unter dem Eileiter (Salpinx) positioniert, der vollständig entfernt werden muss, dann wird das Mesovar versiegelt und durchtrennt. Das Bild zeigt, dass der Abstand zwischen Mesovar und Gebärmutterhals sehr kurz ist; es muss darauf geachtet werden, dass die Gebärmutterarterie nicht verletzt wird. **d** Massenligatur kaudal der Zervix: Die linke und rechte Gebärmutterarterie wurden ohne Durchdringung des Gebärmutterlumens ligiert (seromuskuläre Transfixation), dann wurde eine doppelte Massenligatur hinter dem Gebärmutterhals platziert. Material: monofil, resorbierbar (Biosyn 0; Medtronic, Meerbusch, Deutschland). **e** Gebärmutterhalsstumpf nach Exzision der Schleimhäute und Lembert-Naht: Der Stumpf wurde von Schleimhäuten befreit und desinfiziert, bevor er mit einer fortlaufenden Naht verschlossen wurde. Dies erfolgte zur Verkleinerung des Stumpfes und zur Vermeidung von Verwachsungen. Quelle: S. Schäfer-Somi.

over a length of 15 cm starting between the last mammary complexes. Both uterine horns were pulled into the operation field. The uterine horns had a diameter of about 2 cm, were filled with fluid and areas of hard consistency were palpable inside both horns. In the left uterine horn, close to the corpus uteri, a mass (diameter



► **Fig. 4** Simplified scheme showing the view into the abdomen. After placing a clamp on the ovarian artery, the sealing device (LigaSure™) cuts through the artery, through the mesovary and broad ligament. When the LigaSure™ reaches the uterine artery which is situated close to the cervix, care must be taken not to harm the artery by chance. Because of the large diameter of the artery, it is strongly recommended not to seal the vessel but to place a transfixation suture around the artery (on both sides) and to put a mass suture around the cervix. The scheme and the pictures show how narrow the organs are situated complicating the procedure. Furthermore, the uterine artery is sometimes difficult to see but can be palpated. Because of the thickness and especially in case of tissue edema, the tissue has to be thoroughly sealed. Source: S. Schäfer-Somi.

► **Abb. 4** Vereinfachtes Schema, das den Blick ins Abdomen zeigt. Nach dem Anbringen einer Klemme an der Arteria ovarica schneidet das Versiegelungsgerät (LigaSure™) durch die Arterie, durch das Mesovar und das breite Ligament. Wenn der LigaSure™ die Arteria uterina erreicht, die sich in der Nähe des Gebärmutterhalses befindet, muss darauf geachtet werden, dass die Arterie nicht verletzt wird. Wegen des großen Durchmessers der Arterie wird dringend empfohlen, das Gefäß nicht zu versiegeln, sondern eine Transfixationsnaht um die Arterie (auf beiden Seiten) zu legen und eine Massennaht um den Gebärmutterhals zu legen. Das Schema und die Bilder zeigen, wie eng die Organe liegen, was den Eingriff erschwert. Zudem ist die Arteria uterina manchmal schwer zu sehen, kann aber ertastet werden. Aufgrund der Dicke des Gewebes und vor allem im Falle eines Ödems muss das Gewebe sorgfältig versiegelt werden. Quelle: S. Schäfer-Somi.



► **Fig. 5** Papillary carcinoma with focal necrosis and hemorrhage (H&E staining, bar = 1000 µm). Source: R. Brunthaler.

► **Abb. 5** Papillarkarzinom mit fokalen Nekrosen und Blutungen (H&E-Färbung, Balken = 1000 µm). Quelle: R. Brunthaler.

5 × 10 cm) of hard consistency with partially very thin wall was localized (► **Fig. 3b**). On both ovaries, corpora lutea and cysts of 1 cm diameter were detected. A bipolar sealer for vessel sealing (LigaS-

ure™; Medtronic, Meerbusch, Germany) was used to seal the mesovaries and the mesometrium of both sides until the cervix was reached (► **Fig. 3c** and ► **Fig. 4**). Caudal of the cervix, the left and right uterine artery were sutured and a double mass suture was placed by using monofile resorbable material (Biosyn 0; Medtronic, Meerbusch, Germany) (► **Fig. 3d**). The cervical mucus membranes were removed and the stump disinfected with iodine. The stump was in addition closed by using PDS® 3–0 (Johnson & Johnson Medical Products GmbH, Vienna, Austria) and a continuous Lembert suture (► **Fig. 3e**). The abdomen was controlled and since no bleeding was detected, the wound was sutured continuously (Kürschner suture) by using Polysorb™ 2–0 (Covidien Austria GmbH, Brunn/Gebirge, Austria) for the peritoneum, then muscle and fascia, and PDS 2–0 for the subcutis, respectively. The skin was sutured intracutaneously using Polysorb 3–0.

A formalin-fixed sample of the degenerated uterine tissue was examined pathohistologically.

Diagnosis

The pathohistological examination of the uterine tissue resulted in a poorly differentiated, therefore highly malignant papillary to tubular carcinoma with multifocal necrosis and haemorrhage (► **Fig. 5**). At some sites, a focal differentiation to squamous epithelium was seen. Multiple vessel infiltration of the carcinoma were also detectable.

The uterine mucosa was interspersed with many fluid-filled cysts with a diameter of up to 0.8 cm, which is typical for cystic hyperplasia of the endometrium (CEH) (► Fig. 6).

Case 2

Anamnesis and clinical examination

One week after the ovariectomy of the related partner-pig, the second 13-year-old female minipig started to show purulent vaginal discharge. The owner was advised to take the animal to the University Clinic for Swine at the University of Veterinary Medicine in Vienna for examination. The clinical examination revealed physiological findings; however, the vaginal discharge was purulent as proven by the cytological examination, indicating secondary bacterial infection.

During the sonographical examination, enlarged uterine horns with a variable diameter up to 10 cm and large fluid filled cysts inside the endometrium were seen. On the ovaries, round anechogenic and hypoechogenic structures up to 0.5 cm in diameter were visible.

The preliminary diagnosis was CEH/pyometra and the minipig was prepared for ovariectomy.

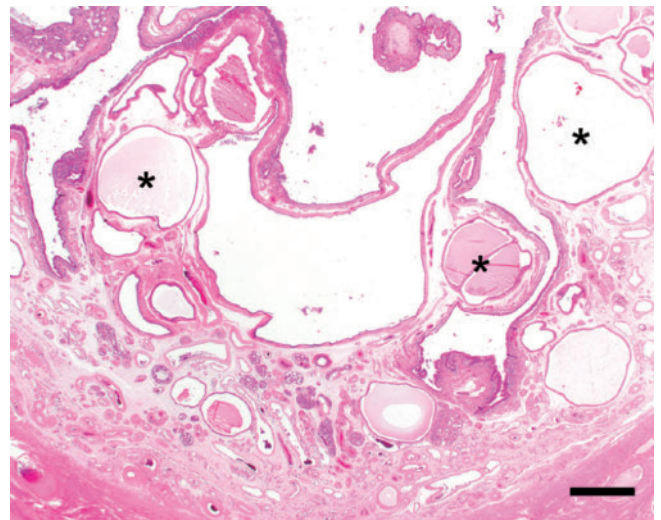
Surgical procedure

The abdominal wall was opened as described above. A 5 × 7 cm mass was localized in the corpus uteri and in the middle of the right uterine horn. The consistency was hard, the uterine wall thin and the serosa showed a dark reddish color with fibrinous coatings. Both horns were fluid filled with a diameter of 2–10 cm and some areas showed hard consistency as well. Both ovaries had corpora lutea and cysts with a diameter of 0.5 cm. The ovariectomy and wound closure were performed as described above. A formalin-fixed sample of the uterine tissue was submitted to the pathohistological examination. Another sample was examined bacteriologically.

Diagnosis

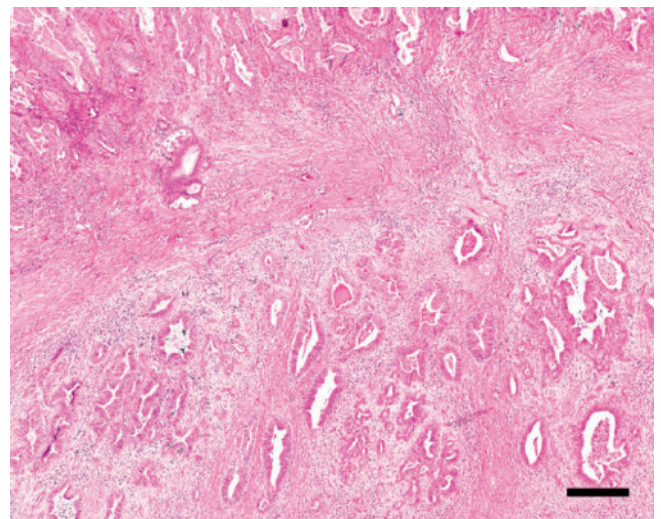
The pathohistological examination revealed a well-differentiated adenocarcinoma of the endometrium with a papillary pattern and pleomorphism of the tumor cells. The irregularly arranged epithelial cell nests were accompanied by purulent inflammatory reaction and necrosis. In several locations the tumor extended into the myometrium, forming a dense and fibrous connective tissue stroma (► Fig. 7). Additionally, in the immediate vicinity of the adenocarcinoma, strongly dilated endometrial cysts containing small amounts of secretion in the lumen as well as a flattened epithelium could be seen, which are characteristic for cystic hyperplasia of the endometrium (► Fig. 6). The bacteriological finding was high grade *Streptococcus equi subsp. zooepidemicus*.

In both cases the animals received antibiotic treatment (Amoxicillin 7 mg/kg and clavulanic acid 1,75 mg/kg) during the surgery. Post-surgery, the animals were clinically examined, and the surgical wounds were assessed daily. The animals received antibiotic treatment and pain medication (Meloxicam 0,4 mg/kg) for a period of three days after surgery. In both cases, the surgical wound healed properly, no more vaginal discharge occurred, and the animals recovered well. Five days after the respective surgery, the animals could be discharged from the clinic.



► Fig. 6 Endometrium with cystic dilated uterine glands (asterisk) (H&E staining, bar = 300 µm). Source: R. Brunthaler.

► Abb. 6 Endometrium mit zystisch erweiterten Gebärmutterdrüsen (Sternchen) (H&E-Färbung, Balken = 300 µm). Quelle: R. Brunthaler.



► Fig. 7 Adenocarcinoma of the endometrium (H&E staining, bar = 80 µm). Source: R. Brunthaler.

► Abb. 7 Adenokarzinom des Endometriums (H&E-Färbung, Balken = 80 µm). Quelle: R. Brunthaler

Discussion

In general, the term “miniature” in miniature pigs is interpreted differently. Minipigs often grow significantly larger than their owners expect and have a life expectancy of 15–20 years, which exceeds the age expected by the owners [1]. Therefore, owners and veterinarians of minipigs have to deal with diseases, which are typical for older age, such as for example neoplasia [5].

As in our case, symptoms of uterine pathologies are often very unspecific [9]. This complicates the diagnosis and leads to the fact that the frequency of genital/uterine tumors in female pigs is often underestimated. It should be kept in mind that neoplasms of the

genital tract in female minipigs, especially in older animals, can be considered as a differential diagnosis for infectious diseases and that they have to be excluded by further diagnostic measures, such as ultrasound examination. In many cases, the diagnosis can also be complicated by the lack of experience of minipig owners in handling and keeping the animals. Many owners are not properly informed before purchasing a minipig and are therefore unaware that minipigs also need routine veterinary care. These circumstances often result in not seeking help from a veterinarian until serious medical problems occur [14]. Furthermore, in many areas, there are hardly any veterinarians specialized in minipigs.

In case of a young minipig, oophorectomy, ovariohysterectomy or immunocastration shortly after puberty should be considered a routine procedure, since the risk of anesthesia increases with the age of the animal and the surgery itself can be much more complicated in case of pathological uterine changes compared to a physiological uterus. The operation is easily done with a sealing device like LigaSure™; this requires significantly less time and causes significantly less bleeding than the ovariohysterectomy of a miniature pig with CEH, especially when the latter is complicated by bacterial infections and ovarian cysts.

The here described operation method is highly effective in the prevention of bleeding; however, the thickness of the tissue (mesovary, mesometrium) and the tissue edema sometimes caused by ovarian cysts, require utmost care and thorough sealing or suturing. When the thickness of the tissue exceeds 8 mm, an additional suture is recommended. In young healthy animals, these problems will barely occur and the use of LigaSure™ for ovariectomy is highly recommendable.

As an alternative option to surgical castration of minipigs, immunocastration should be kept in mind. For male pigs, there is a commercial vaccine against gonadotropin releasing hormone (GnRH) available (Improvac®, Zoetis, Belgium). It is used in male pigs as an alternative to surgical castration in order to reduce the boar odor, which occurs in uncastrated boars after sexual maturity, and the typical boar behavior. In males, immunized against GnRH, the production of LH and FSH is reduced, which results in reduction of the production of sexual hormones by the testes [15]. It is assumed that the immunization against GnRH in female pigs also reduces LH and FSH production, thus having similar effects on the female gonads and suppressing the estrus [16].

In Austria, Improvac® has not been licensed for the use in female pigs until now, but in a few other countries, such as Spain, Canada and several Central and South American countries it has been licensed for female pigs as well [17].

However, it should be kept in mind that for immunocastration the application of the vaccine has to be repeated regularly. Conventionally raised, food-producing male pigs, which are fattened in about 6 months, are usually injected subcutaneously with 2 doses at least 4 weeks apart, the 2. dose is administered between 3 and 10 weeks before slaughter [17]. In case of the Iberian pigs, which are slaughtered for ham production with an age of about 14–15 months, 3 injections are usually sufficient [16]. It still has to be figured out, how often an application of a gonadotropin-releasing-factor-analogue should be performed in pigs, which reach a relatively high age as pets. In addition, it has to be considered that for

repeated injections in certain intervals the compliance between pet-owners and veterinarians must be assured.

Since more and more cases of female pigs with pathological uteri were presented to our clinic in recent years and some similar case reports have already been described in the literature, it seems important to draw attention to this clinical picture and its consequences. For the 2 pigs in this case report, the ovariohysterectomy was performed in time, in other cases and as described in other reports, the pigs were often presented too late [5][9][11][12]; therefore, sepsis and/or metastases are frequent consequences.

In conclusion, CEH, pyometra and uterine tumors often occur in minipigs that are not used for breeding. The incidence increases with increasing age. Regular prophylactic examinations including abdominal sonography are recommendable, as in other pets. Ovariectomy or immunocastration of healthy female minipigs at the age of 6 months would be desirable to effectively prevent uterine neoplasia and cystic endometrial hyperplasia. The use of a vaccine for long-term immunocastration of young female minipigs is currently under investigation.

CONCLUSION FOR PRACTICE

Regular prophylactic examinations including abdominal sonography in minipigs kept as pets are recommendable, because CEH, pyometra and uterine tumors often occur in pigs that are not used for breeding. To effectively prevent uterine neoplasia and especially cystic endometrial hyperplasia, ovariectomy or immunocastration of healthy female minipigs may be considered. So far, no negative late effects of castration of female minipigs are known.

Conflict of interest

The authors declare no conflict of interest.

References

- [1] Tynes VV. Miniature Pet Pig Behavioral Medicine. *Vet Clin North Am Exot Anim Pract* 2021; 24: 63–86. DOI: 10.1016/j.cvex.2020.09.004
- [2] Rozkot M, Václavková E, Belková J. MINIPIGS AS LABORATORY ANIMALS – REVIEW. *Research in Pig Breeding* 2015; 9: 10–14.
- [3] Sipos W, Schmoll F, Stumpf I. Minipigs and potbellied pigs as pets in the veterinary practice--a retrospective study. *J Vet Med A Physiol Pathol Clin Med* 2007; 54: 504–511. DOI: 10.1111/j.1439-0442.2007.00968.x
- [4] Verordnung der Bundesministerin für Gesundheit und Frauen über die Mindestanforderungen für die Haltung von Pferden und Pferdeartigen, Schweinen, Rindern, Schafen, Ziegen, Schalenwild, Lamas, Kaninchen, Hausgeflügel, Straußen und Nutzfischen (1. Tierhaltungsverordnung); BMGF (Bundesministerium für Gesundheit und Frauen) 2004
- [5] Augustijn M, Kuller W, Kimpfler S et al. Neoplasms of the genital tract in a Vietnamese potbellied pig. *Tijdschr Diergeneeskde* 2010; 135: 4–7.

- [6] Anderson LJ, Sandison AT. Tumours of the female genitalia in cattle, sheep and pigs found in a British abattoir survey. *J Comp Pathol* 1969; 79: 53–63. DOI: 10.1016/0021-9975(69)90027-9
- [7] Akkermans JP, van Beusekom WJ. Tumors and tumor-like lesions in the genitalia of sows. *Vet Q* 1984; 6: 90–96. DOI: 10.1080/01652176.1984.9693918
- [8] Ilha MR, Newman SJ, van Amstel S et al. Uterine lesions in 32 female miniature pet pigs. *Vet Pathol* 2010; 47: 1071–1075. DOI: 10.1177/0300985810382522
- [9] Holtig D, Nickoll I, Kauffold J et al. [Uterine neoplasia in two geriatric miniature pet pigs – diagnostics and therapy. Two case reports]. *Tierarztl Prax Ausg K Kleintiere Heimtiere* 2015; 43: 427–433. DOI: 10.15654/TPK-141018
- [10] Golbar H, Izawa T, Kuwamura M et al. Uterine adenocarcinoma with prominent desmoplasia in a geriatric miniature pig. *J Vet Med Sci* 2010; 72: 253–256. DOI: 10.1292/jvms.09-0372
- [11] Harmon BG, Munday JS, Crane MM. Diffuse cystic endometrial hyperplasia and metastatic endometrial adenocarcinoma in a vietnamese pot-bellied pig (*Sus scrofa*). *J Vet Diagn Invest* 2004; 16: 587–589. DOI: 10.1177/104063870401600618
- [12] Munday JS, Stedman NL. Uterine leiomyomas in two Vietnamese pot-bellied pigs (*Sus scrofa*). *Vet Pathol* 2002; 39: 580–583. DOI: 10.1354/vp.39-5-580
- [13] Preissel AK, Brugger N, Stassen T et al. [Treatment of a uterine adenocarcinoma in a miniature pig by ovariohysterectomy]. *Schweiz Arch Tierheilkd* 2009; 151: 229–232. DOI: 10.1024/0036-7281.151.5.229
- [14] Tynes VV. Behavior problems of pet pigs. *Vet Clin North Am Small Anim Pract* 1997; 27: 667–690. DOI: 10.1016/s0195-5616(97)50059-3
- [15] Bonneau M, Dufour R, Chouvet C et al. The effects of immunization against luteinizing hormone-releasing hormone on performance, sexual development, and levels of boar taint-related compounds in intact male pigs. *J Anim Sci* 1994; 72: 14–20. DOI: 10.2527/1994.72114x
- [16] Dalmau A, Velarde A, Rodriguez P et al. Use of an anti-GnRF vaccine to suppress estrus in crossbred Iberian female pigs. *Theriogenology* 2015; 84: 342–347. DOI: 10.1016/j.theriogenology.2015.03.025
- [17] Poulsen Nautrup B, Van Vlaenderen I, Mah CK. The effect of immunization against gonadotropin-releasing factor in market gilts: Meta-analyses of parameters relevant for pig producers, pork packers and retailers/consumers. *Res Vet Sci* 2020; 131: 159–172. DOI: 10.1016/j.rvsc.2020.04.012