

Endoscopic marsupialization for severe candy cane syndrome: long-term follow-up



Authors

Ricardo Rio-Tinto¹, Sara Teles de Campos¹, Susana Marques¹, Miguel Bispo¹, Paulo Fidalgo¹, Jacques Devière^{1,2}

Institutions

- 1 Digestive Diseases Unit, Champalimaud Foundation, Lisbon, Portugal
- 2 Department of Gastroenterology, Hepatopancreatology, and Digestive Oncology, Erasme Hospital, Université Libre de Bruxelles, Brussels, Belgium

submitted 25.4.2022

accepted after revision 30.5.2022

published online 3.6.2022

Bibliography

Endosc Int Open 2022; 10: E1159–E1162

DOI 10.1055/a-1869-2680

ISSN 2364-3722

© 2022. The Author(s).

This is an open access article published by Thieme under the terms of the Creative Commons Attribution-NonDerivative-NonCommercial License, permitting copying and reproduction so long as the original work is given appropriate credit. Contents may not be used for commercial purposes, or adapted, remixed, transformed or built upon. (<https://creativecommons.org/licenses/by-nc-nd/4.0/>)

Georg Thieme Verlag KG, Rüdigerstraße 14, 70469 Stuttgart, Germany

Corresponding author

Ricardo Rio-Tinto, Digestive Diseases Unit, Champalimaud Foundation, Lisbon, Portugal, Av. Brasília, 1400-038 Lisboa, Portugal

Fax: +351210480200

ricardo.riotinto@fundacaochampalimaud.pt

Candy cane syndrome (CCS) is a clinical condition that may occur after gastrectomy or gastric bypass when an excessively long or mispositioned blind jejunal loop proximal to the anastomosis is left in place. Preferential food passage in this loop results in symptoms such as fullness, pain, reflux, regurgitation, and postprandial vomiting.

Surgical resection of the dilated loop is technically complex, and morbidity limits its use in fragile patients. An endoscopic approach, using dedicated active magnets, has recently been shown to be effective in the medium-term.

We present here the case of a 71-year-old woman who underwent endoscopic treatment for the first time. She presented with intractable vomiting, food intolerance, and cachexia due to CCS after total gastrectomy for gastric cancer. Surgical treatment was not an option in such a high-risk patient, and she accepted treatment with a novel endoscopic approach using a double-magnet device followed by septotomy to marsupialize the blind loop. Her symptoms completely resolved and she regained weight.

We report here the patient's clinical outcomes at 3 years, which suggest that endoscopic marsupialization for CCS is not only effective in the short term but also provides long-term clinical benefit.

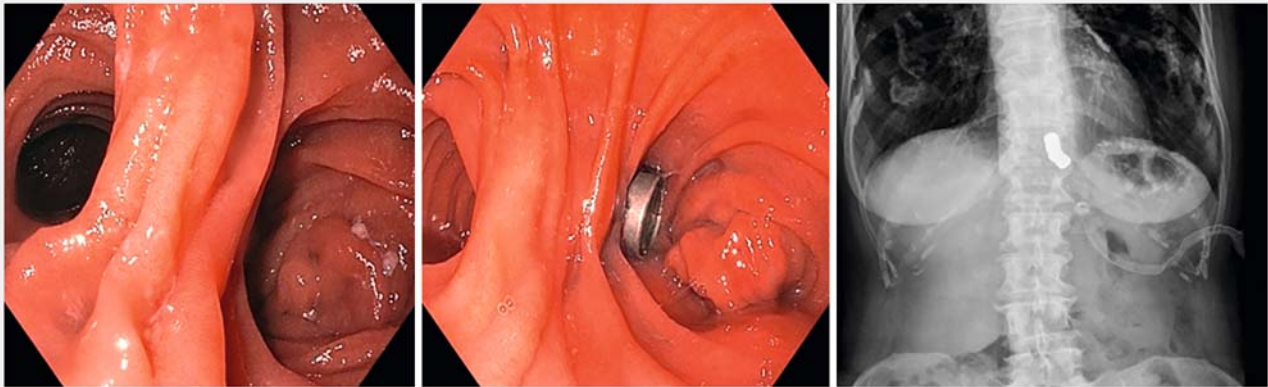
Introduction

Candy cane syndrome (CCS) is a clinical condition that occurs after gastrectomy or gastric bypass and end-to-side anastomosis between the esophagus or the remaining stomach and the small bowel [1–4].

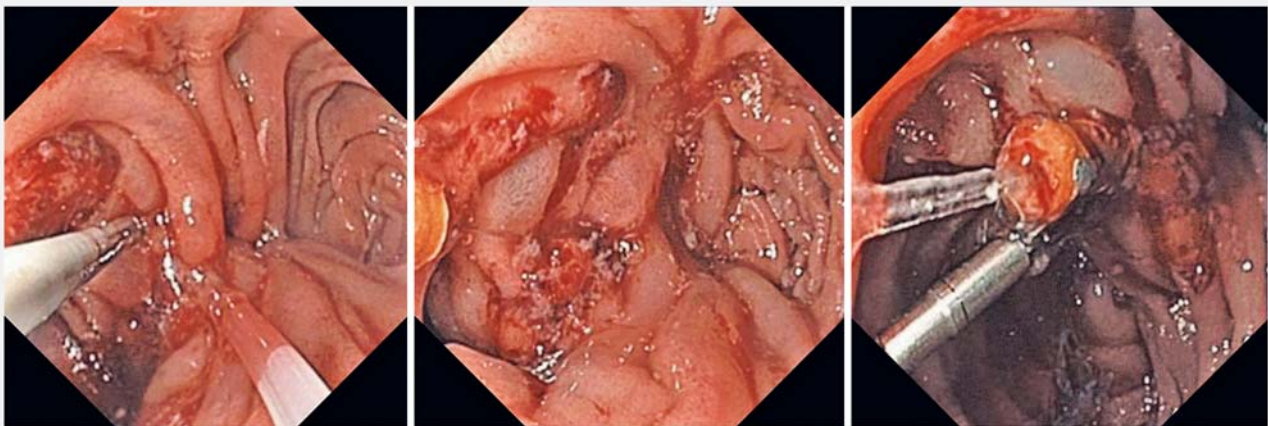
The pathophysiology of CCS appears to be predominantly mechanical, due to an excessively long or mispositioned blind loop proximal to the anastomosis, which promotes food passage into this loop, increasing pressure and causing dilatation of this segment, leading to the characteristic symptoms of the syndrome: fullness, pain, reflux, regurgitation, postprandial vomiting and, eventually, food intolerance and cachexia [1–8].

This condition, first referred to as “candy cane syndrome” in 2007, appears to be an underappreciated surgical complication, but it has been increasingly reported, likely due to the increase in gastric bypass surgery for obesity [1,3,4,8]. Some case reports and small series of CCS suggest that treatment by surgical resection of the dilated loop achieves good results, but they have also emphasized the technical complexity of revisional surgery due to adhesions, which limits the possibility of surgical treatment in fragile patients [1–4].

Anecdotal cases of CCS treatment with a lumen-apposing stent (n=1) or suturing devices (n=2) have been reported and we recently reported medium-term results of a pilot series using active magnets for afferent loop marsupialization [6–9].



► Fig. 1 Magnet placement over septum: endoscopy and X-ray (T1)



► Fig. 2 Septotomy after magnet migration: endoscopy (T2).

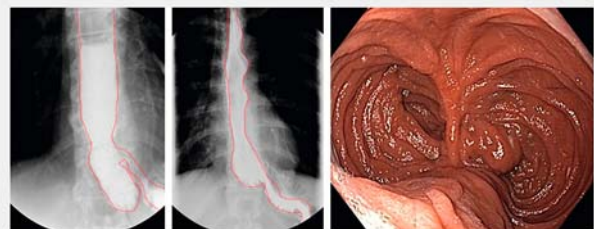
We report here 3-year results of the first patient with CCS treated by magnet-assisted endoscopic septotomy.

Clinical case

A 71-year-old woman presented with persistent postprandial vomiting and cachexia (body mass index 11,96 [31 kg\1.61 m²]) 26 months after total gastrectomy with Roux-en-Y anastomosis for diffuse-type gastric carcinoma and seeking a second opinion. Previous surgical pathology revealed a pT1N1 signet-ring cell carcinoma and adjuvant chemotherapy was initiated, but due to persistent postprandial vomiting and food intolerance, chemotherapy was suspended 4 months after surgery and progressive weight loss was observed.

Follow-up examination revealed no evidence of local or distant recurrence. Imaging revealed a dilated esophagus and no contrast progression, although no clear obstruction was seen.

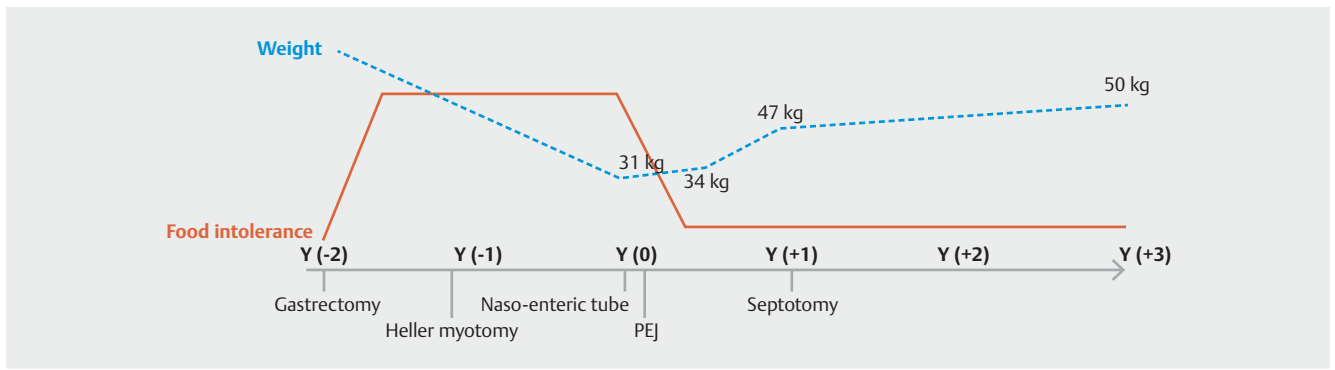
Ten months after surgery, esophageal manometry revealed spastic achalasia and the patient underwent Heller laparoscopic esophageal myotomy without clinical improvement.



► Fig. 3 Contrast X-ray before (left) and after septotomy (center), and control endoscopy 3 months after treatment (right).

She was then referred for nutritional and psychiatric consultations for persistent food intolerance, postprandial vomiting, and progressive weight loss; her weight dropped from 66 kg to 31 kg in the following months.

At this point, she came to us for consultation, and upon reviewing the case, we were able to rule out several causes for the patient's symptoms: malignancy recurrence, primary esopha-



► **Fig. 4** Timeline for patient treatment: Y(0) represents the time of our first intervention (Y: Year).

geal motility disorders, anastomotic stenosis, primary malabsorption, and even a psychiatric disorder.

Considering the patient's symptoms, previous endoscopies, and findings from contrast x-ray, we hypothesized that she had a CCS. Because she had severe cachexia contraindicating any intervention, we planned a stepwise diagnostic and treatment approach: 1. We first placed a nasoenteric tube for 2 weeks as a proof-of-concept and, for the first time in almost 3 years, the patient gained 3 kg and experienced no vomiting after enteral feeding; 2. Because we wanted to improve the patient's general condition before proposing definitive treatment, we placed a percutaneous jejunal tube (PEJ), which resulted in an additional 13-kg weight gain over the next 10 months; 3. After discussing the pros and cons with the patient, we proposed an endoscopic treatment to marsupialize the jejunal blind loop by cutting the septum between the blind loop and the efferent loop, thus marsupializing the afferent jejunal loop. After obtaining the informed consent of the patient, we performed the third step in two endoscopic procedures: First we placed two magnets like those previously used for gastro-jejunal anastomosis (Cook Magnetic Anastomosis Device (MAD)(Wilson-Cook Medical Inc., Winston-Salem, North Carolina, United States) under endoscopic and radiological control on each side of the septum (T1) to induce serosa-to-serosa apposition and compression anastomosis (► **Fig. 1**) [10, 11]. 4. At a second endoscopy (T2) 1 week later, the septum was cut with a Zimmon Needle Knife (Wilson-Cook Medical Inc., Winston-Salem, North Carolina, United States) and the incision edges were closed with endoclips, as shown in ► **Fig. 2**. Finally, we removed the PEJ tube 1 week after the endoscopic treatment was completed, as the patient had resumed oral intake with good tolerance, and she gradually gained another 3 kg within 1 month. At follow-up endoscopy and contrast X-ray 3 months after treatment, a complete and stable septotomy was achieved (► **Fig. 3**). No complications were noted, and at 3 years follow-up, the patient was free of symptoms and her weight had stabilized (50 kg) (► **Fig. 4**).

Discussion

This case is an example of how CCS remains poorly recognized and underdiagnosed or misdiagnosed due to ignorance of this condition. However, CCS manifestations have been described to be common after gastrectomy [8]. When CCS symptoms are recognized, they can be relieved by surgical intervention. However, this procedure is technically challenging if repeated abdominal surgeries are performed [1–4].

An endoscopic approach to the treatment of CCS using active magnets and slow incisions has been described, with excellent medium-term success [9]. However, long-term results are not yet available with this promising technique. Because our patient was the first to be treated with magnet-induced pressure necrosis and subsequent dissection in a life-threatening situation, it seems relevant to underscore that this endoscopic marsupialization resulted in relief of symptoms more than 3 years after initial treatment. This is another step toward considering the endoscopic approach as the first therapeutic step for CCS.

Competing interests

The authors declare that they have no conflict of interest.

References

- [1] Dallal RM, Cottam D. "Candy cane" Roux syndrome – a possible complication after gastric bypass surgery. *Surg Obes Relat Dis* 2007; 3: 408–410
- [2] Aryaie AH, Fayezizadeh M, Wen Y et al. "Candy cane syndrome:" an underappreciated cause of abdominal pain and nausea after Roux-en-Y gastric bypass surgery. *Surg Obes Relat Dis* 2017; 13: 1501–1505
- [3] Khan K, Rodriguez R, Saeed S et al. A Case series of candy cane limb syndrome after laparoscopic Roux-en-Y gastric bypass. *J Surg Case Rep* 2018; 2018: rjy244
- [4] Kamocka A, McGlone ER, Pérez-Pevida B et al. Candy cane revision after Roux-en-Y gastric bypass. *Surg Endosc* 2020; 34: 2076–2081
- [5] Razjouyan H, Tilara A, Chokhavatia S. Dysphagia after total gastrectomy. *Am J Gastroenterol* 2015; 110: S262–S263

- [6] Granata A, Cicchese N, Amata M et al. “Candy cane” syndrome: a report of a mini-invasive endoscopic treatment using OverStitch, a novel endoluminal suturing system. *Endoscopy* 2019; 51: E16–E17
- [7] Wundsam HV, Kertesz V, Bräuer F et al. Lumen-apposing metal stent creating jejuno-jejunostomy for blind pouch syndrome in patients with esophago-jejunostomy after gastrectomy: a novel technique. *Endoscopy* 2020; 52: E35–E36
- [8] Greenberg I, Braun D, Eke C et al. Successful treatment of “candy cane” syndrome through endoscopic gastrojejunal anastomosis revision. *Clin J Gastroenterol* 2021; 14: 1622–1625
- [9] Rio-Tinto R, Huberland F, Van Ouysel P et al. Magnet and wire remodeling for the treatment of candy cane syndrome: first case series of a new approach (with video). *Gastrointest Endosc* 2022: S0016-5107(21)01941-6 doi:10.1016/j.gie.2021.12.027
- [10] van Hooft JE, Vleggaar FP, Le Moine O et al. Endoscopic magnetic gastroenteric anastomosis for palliation of malignant gastric outlet obstruction: a prospective multicenter study. *Gastrointest Endosc* 2010; 72: 530–535
- [11] Bouchard S, Huberty V, Blero D et al. Magnetic compression for treatment of large oesophageal diverticula: a new endoscopic approach for a risky surgical disease? *Gut* 2015; 64: 1678–1679