

# Multiple Drug Hypersensitivity in a Small Child with DRESS Syndrome – A Case Report

## Multiple Arzneimittelreaktionen bei einem Kleinkind mit DRESS Syndrom – Ein Fallbericht



### Introduction

Drug reaction with eosinophilia and systemic symptoms (DRESS) belongs to the group of severe cutaneous adverse reactions. Here we report a case of drug hypersensitivity against multiple antibiotics with DRESS in a young child with necrotizing pneumonia.

### Case Report

A 23-month-old girl was admitted to hospital due to dry cough, fever up to 40.2 degrees and breathlessness since 5 days. The girl had never received any antibiotic therapy. Chest x-ray displayed infiltration in the right lower lobe with pleural effusion. Streptococcus throat swab test and nasal metapneumovirus RNA were positive. Complicated pneumonia was diagnosed and therapy with vancomycin, cefuroxime, paracetamol and salbutamol inhalation started. In the following days, pleural effusion enlarged and respiration deteriorated, thus closed pleural drainage was placed for 4 days, draining 70 ml of serous effusion. Antibiosis was switched to ceftriaxone and azithromycin. Respiratory symptoms improved, however recurrent fever attacks and increased infection parameters persisted (leucocytes up to 26 G/l, CRP up to 5.5 mg/dl). Antibiotic therapy was switched again to gentamycin and meropenem on day 14. As shortly thereafter a lung abscess in the right lower lobe was revealed by CT, antibiotic therapy was ultimately switched to tazobactam/piperacillin and clindamycin on day 16. Consecutively, the child became afebrile within 24 hours, laboratory infection parameter decreased rapidly and clinical symptoms disappeared.

Thirteen days after last change of antibiotics, the girl unexpectedly developed high fever again. Paracetamol was restarted, and

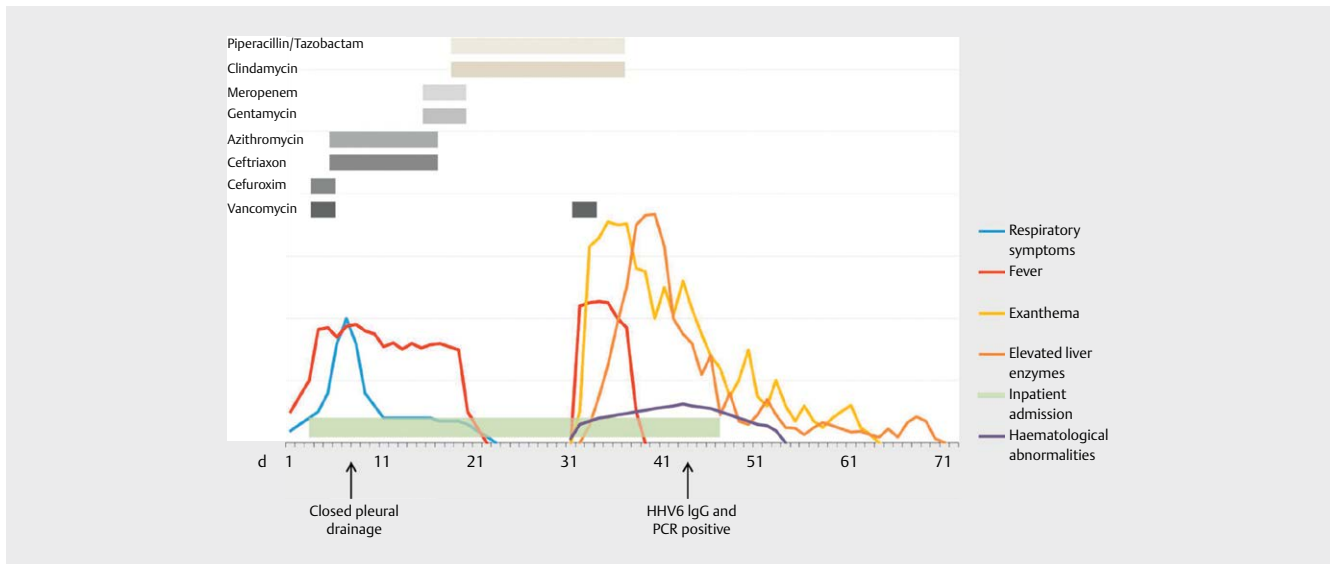
vancomycin added to antibiotic regimen. A couple of hours after the first application of vancomycin, a pruritic morbilliform rash appeared, spreading from the lower legs. On the following day, during the fourth application of vancomycin, exanthema deteriorated, now showing an intense redness nearly affecting the entire body surface with additional facial edema. Additionally, general clinical status was further impaired with malaise, fatigue, high fever up to 42 degrees and tachycardia. Vancomycin was stopped without improvement of symptoms. Meanwhile, liver enzymes increased rapidly up to a maximum of AST 1445 U/l, ALT 395 U/l,  $\gamma$ -GT 103 U/l and LDH 7099 U/l and liver synthesis capacity decreased (PT 65%, aPTT 62 s, factor II 47%, factor IX 36%, ATIII activity 72%). Abdominal ultrasound showed a slightly increased liver size with normal structure and blood flow. Leucopenia (min 2.3 G/l) with neutropenia and relative lymphocytosis (86%) with atypical lymphocytes were detected. At day 12 after onset of skin symptoms, eosinophilia developed (16%), and viral testing for HHV6 was positive (PCR and IgG positive, IgM negative). Screening for other causes of fever or hepatic damage (virology, anti-nuclear-antibodies, repeated blood cultures, urine test, chest x-ray, drug serum levels and stool culture) remained negative as was screening for other organ involvement (creatinine, TSH, fT4, cardiac enzymes, cardiac ultrasound and ECG) (for details, see ► **Table s1**, supplementary appendix). Thoracic CT scan showed regression of pneumonia and pleural effusion.

According to the RegiSCAR scoring system, which classifies suspected cases of DRESS syndrom into definite, probable, possible or no case according to presence or absence of specific clinical symptoms (Kardaun SH et al., Br J Dermatol 2007; 156: 609–11, ► **Table s2**, supplementary appendix), a

definite diagnosis of DRESS syndrome was made with a total score of 6 points. Clindamycin and piperacillin/tazobactam treatment was stopped after 17 days of application and 4 days after onset of exanthema, as was paracetamol, and the girl was left without any further antibiotic treatment. Fever decreased, liver enzymes increased for one (AST, ALT) or three ( $\gamma$ GT) more days, then gradually decreased as well. Likewise, the pruritic rash ameliorated but an undulating course with repeated strong relapses continued for the next weeks. The patient was discharged on day 14 after DRESS development, skin rash continued for another 2–3 weeks and liver function was normalized 5 weeks after discharge (► **Fig. 1**). Respiratory symptoms did not reoccur in a follow-up period of twelve months.

In order to identify the culprit drug, patch test with all applied antibiotics was performed 5 months after resolution of symptoms as recommended (► **Table 1**). Patch testing is advocated as first-line diagnostic in DRESS to ascertain the causative drug, since it is safe and shows high specificity, albeit moderate sensitivity (31–64%) (Barbaud A et al., Br J Dermatol 2013; 168: 555–62, Pinho A et al., J Eur Acad Dermatol Venereol 2017; 31: 280–87). Our patient displayed positive reactivity to both clindamycin and tazobactam/piperacillin on day 1 and 2. A follow-up patch test with multiple beta-lactam antibiotics to exclude cross-reactivity was performed 5 months later. Interestingly, strong reactivity to all penicillin-related antibiotics (penicillin, ampicillin, amoxicillin; (► **Table 1**, ► **Fig. 1**), but not to cephalosporins was detected, indicating T-cell interaction with penicillin-specific side chains.

DRESS, coined in 1996 by Bocquet H et al., (Semin Cutan Med Surg. 1996; 15: 250–7), is characterized by an extensive rash, sys-



► Fig. 1 Time course of antibiotic exposure and clinical symptoms.

► Table 1 Results of the epicutaneous patch test

Drug	Result	
	24 h	48 h
<b>Clindamycin</b>	+	++
<b>Tazonam/Piperacillin</b>	+	++
Meropenem	-	-
Ceftriaxon	-	-
Cefuroxim	-	-
Azithromycin	-	-
Vancomycin	-	-
Refobacin	-	-
<b>Penicillin</b>	+/-	++
<b>Ampicillin</b>	+/-	+
<b>Amoxicillin</b>	+/-	+

Table 1 legend: Epicutaneous patch tests; Epicutaneous patch tests performed 5 and 10 months after resolution of symptoms showed positivity to two of the applied antibiotics (clindamycin and tazonam/piperacillin), as well as cross-reactivity to other non-applied penicillin-related antibiotics (penicillin, ampicillin, amoxicillin)

temic symptoms and organ manifestation and differs from other hypersensitivity reactions by its' protracted time course, usually starting late after drug administration and persisting for weeks after drug discontinuation. It has been shown to be associated with a higher risk of multiple drug allergy (10–25%) compared to other drug hypersensitivity reactions (Bardaud A et al., *Br J Dermatol.* 2013; 168: 555–62, Pichler WJ, *Curr Opin Allergy Clin Immunol.* 2002; 2:

301–5). Nevertheless, reports on multiple drug allergies are rare, and in clinical practice, the differentiation between drug-induced flare-ups, cross-reactivity, both also common in DRESS, and real multiple drug hypersensitivity (MDH) is difficult. The term MDH describes clinically well-defined drug hypersensitivity reactions elicited by two or more chemically distinct (thus structurally non-related) drugs, which can be confirmed by positive in vitro or skin tests and which

do not disappear after DRESS has cleared (Gex-Collet C et al., *J Investig Allergol Clin Immunol* 2005; 15: 293–6). Our patient has obviously developed both, a real MDH against two structurally different antibiotics (clindamycin, piperacillin/tazobactam), as well as a strong cross-reactivity against multiple other penicillin-related antibiotics. Due to limited availability, piperacillin and tazobactam were not tested separately, but skin test positivity to diverse penicillins in a patient who had never before received antibiotics together with the higher immunogenicity of piperacillin over tazobactam strongly suggests piperacillin to be the culprit agent.

Pathophysiology behind DRESS is still not entirely clear, however, models to explain both the distinct laboratory and clinical features of the disease have been described. The allo-immune model of p-i-HLA in DRESS syndrome links the strong allo-like polyclonal T cell stimulation observed during DRESS to abnormalities of regulatory T cells, which consecutively can explain HHV virus reactivation, the protracted course of the disease, and the risk for multiple drug hypersensitivities as well as autoimmune phenomena in the follow-up period (Pichler WJ. *Curr Opin Allergy Clin Immunol.* 2002; 2: 301–5, Pichler WJ et al., *Int Arch Allergy Immunol.* 2015; 168: 13–24, Cho YT et al., *Int J Mol Sci.* 2017; 18). Both, the observed HHV-6 reactivation as well as the MDH in our patient thus might result from the same

strong lymphocyte activation. The detection of HHV-6 reactivation in our 23 month-old patient seems untypical, however not implausible, as HHV-6 immunization usually takes place in the first two years of life (Okuno T et al., *J Clin Microbiol* 1989; 27: 651–3).

Therapy of DRESS mainly consists of cessation of culprit drugs, topical skin treatment with corticosteroids and systemic administration of corticosteroids in case of severe organ manifestation. In our patient, waiver of systemic corticosteroids despite severe liver involvement was decided in order to avoid complications after stop of antibiotics of lung abscess after 17 days. Instead, the patient received only large-scale topical corticosteroids (0.1 % methylprednisolone). Nonetheless, DRESS healed rapidly without complications or sequelae, supporting previous observations that prompt discontinuation of the culprit drug might have a positive effect on outcome (Matoussi N et al., *J Investig Allergol Clin Immunol*. 2017; 27: 144–46).

In summary, we report the occurrence of a typical DRESS-syndrome in a very young child. The occurrence of multiple drug allergy as well as multiple cross-reactivities together with HHV6-reactivation is unique at this young age. All potentially causative drugs were discontinued within 3 days after occurrence of symptoms and the patient fully recovered without sequelae despite waiver of systemic corticosteroid use.

Awareness of this form of severe drug hypersensitivity is crucial in order to avoid delayed diagnosis and poor outcome also in young patients. Multiple drug hypersensitivity should be considered and identified in patients receiving more than one DRESS-eliciting agent to equip the patient with correct drug avoidance recommendations.

## Contributor's Statement

Conceived the concept: S. Gruber, L. Gona-Höpler Performed diagnostic procedures: C. Bangert, S. Diesner, K. Schmidthaler Data interpretation and manuscript drafting: Z. Szepefalusi

## Authors

**Saskia Gruber<sup>1</sup>, Livia Gona-Hoepler<sup>2</sup>,  
Christine Bangert<sup>3</sup>, Susanne C Diesner<sup>4</sup>,  
Klara Schmidthaler<sup>4</sup>, Zsolt Szepefalusi<sup>4</sup>**

## Affiliations

- 1 Department of Pediatrics and Adolescent Medicine, Division of Pediatric Pulmonology, Allergology and Endocrinology, Comprehensive Center Pediatrics, Medical University of Vienna, Vienna, Austria
- 2 Pediatrics and Adolescent Medicine, Division of Pediatric Pulmonology, Allergology and Endocrinology, Comprehensive Center Pediatrics, Medical University of Vienna, Wien, Austria
- 3 Dermatology, Medical University of Vienna, Vienna, Austria
- 4 Pediatrics and Adolescent Medicine, Division of Pediatric Pulmonology, Allergology and Endocrinology, Comprehensive Center Pediatrics, Medical University of Vienna, Vienna, Austria

- 3 Dermatology, Medical University of Vienna, Vienna, Austria
- 4 Pediatrics and Adolescent Medicine, Division of Pediatric Pulmonology, Allergology and Endocrinology, Comprehensive Center Pediatrics, Medical University of Vienna, Vienna, Austria

## Correspondence

Prof. Zsolt Szepefalusi  
Medical University Vienna  
Pediatrics  
Währinger Gürtel 18-20  
1090 Vienna  
Austria  
Tel.: 0043-1-40400-3188  
Fax: 0043-1-40400-3189  
zsolt.szepefalusi@meduniwien.ac.at

published online 04.07.2022


## Bibliography

*Klin Padiatr* 2023; 235: 52–54  
DOI 10.1055/a-1857-5062  
ISSN 0300-8630

© 2022. The Author(s).

This is an open access article published by Thieme under the terms of the Creative Commons Attribution-NonDerivative-NonCommercial-License, permitting copying and reproduction so long as the original work is given appropriate credit. Contents may not be used for commercial purpose, or adapted, remixed, transformed or built upon. (<https://creativecommons.org/licenses/by-nc-nd/4.0/>)

Georg Thieme Verlag, Rüdigerstraße 14,  
70469 Stuttgart, Germany

 **Supplementary Material** is available under <https://doi.org/10.1055/a-1857-5062>