

Concepts in the Establishment of Interdisciplinary Ultrasound Centers: The Role of Radiology

Konzepte im Aufbau von interdisziplinären Ultraschallzentren: Die Rolle der Radiologie

Authors

Dirk Andre Clevert¹, Ernst Michael Jung², Marc-André Weber³ , Markus Herbert Lerchbaumer⁴ , Winfried Willinek^{5, 6}, Thomas Fischer⁴

Affiliations

- 1 Institut für Klinische Radiologie, Campus Grosshadern, Klinikum der Universität München Großhadern, München, Germany
- 2 Institut für Röntgendiagnostik, Universitätsklinikum Regensburg, Germany
- 3 Universitätsmedizin Rostock, Diagnostische und Interventionelle Radiologie, Rostock, Germany
- 4 Department of Radiology, CharitéCentrum 6 Diagnostische und interventionelle Radiologie und Nuklearmedizin, Berlin, Germany
- 5 3. Center for Radiology, Neuroradiology, Sonography and Nuclear Medicine, Krankenhaus der Barmherzigen Brüeder, Trier, Germany
- 6 Radiology, University of Bonn, Germany

Key words

education, ultrasound, economics, medical

received 23.05.2021

accepted 12.04.2022

published online 18.07.2022

Bibliography

Fortschr Röntgenstr 2022; 194: 1322–1332

DOI 10.1055/a-1853-7443

ISSN 1438-9029

© 2022, Thieme. All rights reserved.

Georg Thieme Verlag KG, Rüdigerstraße 14, 70469 Stuttgart, Germany

Correspondence

Herr Prof. Thomas Fischer

Institut für Radiologie, Charité Campus Mitte, Universitätsmedizin Berlin, Schumannstraße 20/21, 10117 Berlin, Germany

Tel.: +49/30/4 50 62 72 38

Fax: +49/30/4 50 52 79 09

thom.fischer@charite.de

ABSTRACT

Background Ultrasound (US) is widely used as a fast and cost-efficient first-choice imaging technique without relevant side effects for a variety of diagnostic tasks. Due to technical advances, more complex and sophisticated methods such as color-

coded duplex ultrasound, image fusion, contrast-enhanced ultrasound (CEUS), and ultrasound-guided interventions have become increasingly important in diagnostic algorithms.

Method This study presents an overview of all aspects regarding the establishing of an interdisciplinary US center based on five representative examples in Germany. These aspects include topics of ultrasound education, research, economics, and administration.

Results The goal of an interdisciplinary US center is to bundle the use of equipment, staff, rooms, and infrastructure resources (optimization of equipment availability and use of new techniques) to expand the range of examinations, to promote resident training, and to boost continuing medical education of residents. This should result in better patient care and has additionally improved patient care while considering the added value for the participating institutions involved. Interdisciplinary US centers allow a reduction of the number of US devices needed in a hospital and more efficient use of available equipment through bedside time optimization by central organization within interdisciplinary management. The focused application of special US techniques such as CEUS or image fusion for complex, difficult interventions as well as the training and education of younger colleagues in using these techniques is centrally organized by experts and can be improved through the multidisciplinary experience available.

Conclusion Organizational structures, sharing of materials, and standardization of diagnostic reports facilitate and accelerate cooperation with the referring specialty.

Key Points:

- Interdisciplinary US centers foster clinical collaboration, research, and jointly organized, standardized training.
- Economic aspects include optimization of available equipment, use of the latest US techniques, and centralization of organizational structures.
- Common terminology and standardized reporting increase the satisfaction of referring doctors

Citation Format

- Clevert DA, Jung EM, Weber M et al. Concepts in the Establishment of Interdisciplinary Ultrasound Centers: The Role of Radiology. *Fortschr Röntgenstr* 2022; 194: 1322–1332

ZUSAMMENFASSUNG

Hintergrund Die Sonografie (Ultraschall/US) wird als schnell verfügbare und kosteneffiziente Bildgebung der ersten Wahl ohne relevante Nebenwirkungen für eine Vielzahl von Fragestellungen genutzt. Durch den technischen Fortschritt gewinnen komplexere Methoden wie die Farbduplexsonografie, Bildfusion und Kontrastmittelsonografie (CEUS) sowie interventionelle Verfahren unter sonografischer Bildführung zunehmend an Bedeutung im diagnostischen Algorithmus.

Methode In diesem Überblick sind sämtliche Aspekte im Aufbau eines interdisziplinären US-Zentrums anhand von 5 Beispielen in Deutschland dargestellt. Diese umfassen Themen der Ausbildung, Forschung, Ökonomie und Administration.

Ergebnisse Ziel eines interdisziplinären US-Zentrums ist es, apparative, personelle, räumliche und infrastrukturelle Ressourcen zu bündeln (Optimierung der Geräteverfügbarkeit und Nutzung neuer Techniken), das Untersuchungsspektrum

zu erweitern und die ärztliche Fort- und Weiterbildung zu verbessern. Damit sollte zusätzlich eine bessere und schnellere Patientenversorgung unter Beachtung der Wertschöpfung für die beteiligten Einrichtungen gewährleistet sein. Durch Bündelung in Ultraschallzentren gelingen eine Reduzierung der Geräteanzahl und eine Zeitoptimierung der Nutzung von vorhandenen Systemen und Equipment. In Ultraschallzentren ist die fokussierte Anwendung spezieller US-Techniken wie CEUS und Bildfusion für schwierige Interventionen sowie die Ausbildung und das Heranführen jüngerer Kollegen an diese Techniken zentral besser verfügbar.

Schlussfolgerung Durch die Etablierung interdisziplinärer Ultraschall-Zentren mit zentralen Organisationsstrukturen, gemeinsamer Nutzung von Materialien und Vereinheitlichung der Befundung werden die Effektivität und Effizienz der Ultraschalldiagnostik verbessert.

Introduction

Ultrasound (US) has become established in recent decades as an imaging method for quick and noninvasive diagnosis. US can be used for quick clinical orientation. A more complex method, i. e., the image fusion technique (US plus computed tomography [CT], US plus magnetic resonance imaging [MRI]) can also be used for targeted interventions, for example. As in all other imaging methods, an appropriate technique, training using the technique, and a rational interpretation of the results in the clinical context are decisive for using and benefiting from the method [1]. Guidelines for ultrasound are primarily provided in regulations for specialist training and in the ultrasound agreement of the National Association of Statutory Health Insurance Physicians for the individual areas of specialization. 10 years ago, organ-based ultrasound imaging included the abdominal region (75%), the thyroid (10%), and other locations, e. g., musculoskeletal system, vascular system, and mammary gland (15%) [1]. Today, particularly as a result of multimodal use (B-mode, duplex, elastography, contrast-enhanced ultrasound (CEUS)), there are numerous new applications in almost all organ systems e. g., for the characterization of focal liver lesions [2], in urogenital diagnosis of the testes, prostate, and kidneys [3–5], for assessing the large abdominal vessels after placement of a stent prosthesis [6–8], and for evaluating the musculoskeletal system [9]. The establishment of CEUS and elastography [3, 9] as well as the targeted use of the improved B-mode image quality, US image fusion, and 4D sonography resulted in the introduction of the term “multiparametric ultrasound” (mpUS) [10]. The term includes new technological applications already used in connection with targeted prostate imaging and biopsy. In recent years, primarily as a result of the implementation of metric parameters, mpUS has been used scientifically and clinically in US shear wave elastography and CEUS [4, 10]. Due to the expertise regarding other imaging modalities (X-ray, CT, MRI) inherent in radiology and to the possibilities presented by new fusion techniques, radiology plays a particularly important role and is therefore predestined to further develop ultrasound [11].

In addition to rapid technical advances in ultrasound, the targeted and time-intensive training of ultrasound specialists, the personnel-intensive staffing of small ultrasound departments, and availability for on-call duty are an urgent problem in many departments in Germany [11]. Equipment fleets are maintenance- and cost-intensive and are outdated in some cases. Different areas of application require different device classes and a differentiated innovation speed in the case of reinvestment. A possible strategic solution to this structural problem could be interdisciplinary collaboration in an interdisciplinary ultrasound center. The following discusses the concept for establishing an interdisciplinary US center based on the example of five existing centers at maximum care hospitals and university hospitals in Germany.

Basic principles

Ultrasound diagnosis is one of the main pillars of diagnostic imaging in all areas of medicine and is an indispensable part of the daily routine. However, this broad use resulted in wasted resources. For example, many hospitals have a substantial number of ultrasound systems from various manufacturers that are not adequately used. Prior to the creation of ultrasound centers, ultrasound was available on a decentralized basis resulting in departments with diverse ultrasound systems with different operating functions and equipment available only for specific medial issues. By creating ultrasound centers, the number of devices can be reduced, and more efficient use of available equipment can be ensured through bedside time optimization by central organization within interdisciplinary management. Centralized ultrasound centers improve the focused use of US techniques like CEUS and image fusion for difficult interventions as well as the training of young colleagues in these techniques.

Nonetheless, many disciplines insist on maintaining an independent “ultrasound department” often consisting of only one or two US systems with the justification of specialist training authorization for their particular area of specialization. However, there is certainly

► **Table 1** Main goals of an ultrasound center.

Topic	Main goals
Department	Optimization of equipment availability and availability of the latest US technology
	Establishment of standardized clinical pathways including ultrasound
Economy	Centralized planning regarding personnel, consumable materials, and equipment
	Joint organization of events involving referring physicians
	Concentration of organizational structures
	Targeted use of financial resources, prevention of duplicate examinations
Training	Use of common standards (standardized terminology, standardized examination techniques, standardized reporting)
	Jointly organized and standardized training and quality control
	Prevention of duplicate examinations with improved training
	Increase of diagnostic quality in the hospital
Research	Support of interdisciplinary collaboration
	Use and implementation of the latest US methods in research and subsequently in the clinical routine
	Raising of third-party funding through interdisciplinary research projects

The table shows the main goals of an (interdisciplinary) ultrasound center and the main points structured according to topic.

also an element of possessiveness. Gynecology and cardiology departments in particular require special applications which complicates interdisciplinary use since most high-end US systems are based on innovations in CEUS and elastography [12]. This means that the number of US systems available in a hospital is above the actually needed capacity and economic capacity utilization is not ensured. This also increases service and maintenance costs. To date, almost every department in a large hospital has performed ultrasound independently with their own US systems, personnel, and organizational structures. The disadvantages of such a system are obvious: In light of decreasing resources and the cost pressure of the DRG system, only a few departments can afford modern and powerful high-end devices. However, due to the improved image quality and diagnostic significance, such devices have become essential in spite of the high price (up to 150 000 euros per system depending on the equipment). The individual departments are usually responsible for their own quality assurance so that organization is limited. On-site applications in the OR, emergency departments, and intensive care units require mid-class systems and small portable systems. However, duplicate examinations and multiple patient transfers increase costs while reimbursement remains the same due to the DRG system. Portfolio standardization is being per-

formed in diverse areas, e. g., regarding materials in angiography, by radiology, cardiology, and vascular surgery. This effort (additionally triggered by the possibility of certification as an interdisciplinary vascular center, <https://www.drg.de/de-DE/1285/interdisziplinare-gefaesszentren-der-drg/>) also plays a role in the establishment and certification (<https://www.degum.de/service/zertifizierte-abteilungenzentren.html>) of ultrasound centers. Moreover, interdisciplinary centralization also allows standardization and better control of hygiene quality standards for ultrasound [13].

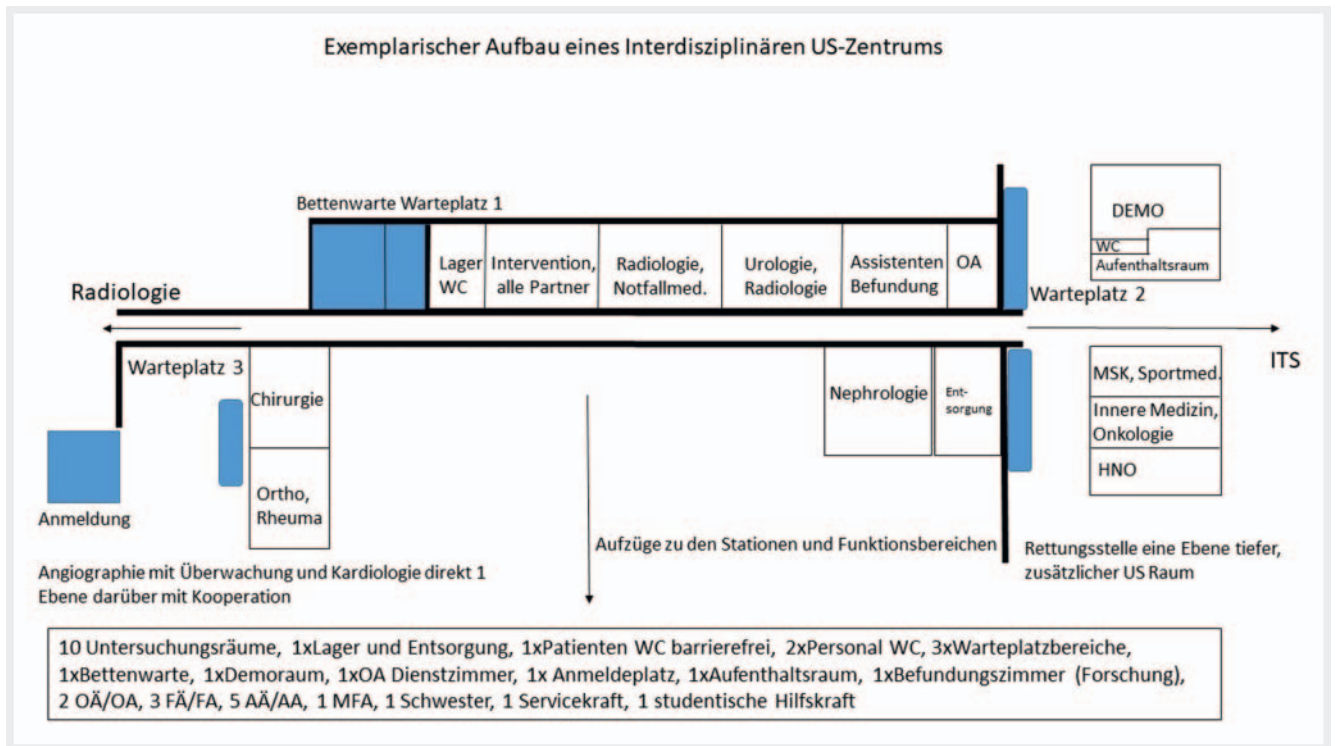
Objective of ultrasound centers

In 2004 previously separate functional areas in surgery, radiology, and gastroenterology were merged in German centers to form one interdisciplinary ultrasound center thereby creating a basic model that was later implemented at other sites in Germany. The goal was to bundle shared resources, to expand the examination spectrum, and to improve training. With respect to DRGs, better and faster patient care under consideration of the added value for participating facilities should also be ensured. There are strategic main goals that can be transferred to existing centers and to the creation of interdisciplinary ultrasound centers (► **Table 1**).

Implementation

There are initially restructuring costs for setting up suitable examination rooms if existing structures can be used and the room structure only needs to be adapted for optimized examination and reporting workflows. The capacity of work areas should be adapted according to the size of the US center and the participating departments and to examination demand. In addition to pragmatic solutions, e. g., separation of work areas, special attention should be paid to lighting conditions, air conditioning, ventilation, and a dedicated area for reporting. In addition, corresponding data cables (fiber-optic cables) or WLAN connections for connecting to the hospital's internal RIS/PACS system are recommended.

When setting up an ultrasound center, examinations performed by different areas of specialization must be networked. The goal is central documentation of ultrasound examinations, recording of services, and archiving of images and reports. The particular requirements of the individual disciplines must be taken into consideration. Therefore, endoscopic images should also be able to be viewed in the viewer when collaborating with gastroenterology and visceral surgery. In addition to patient care (basic archive), a teaching and research archive should also be created. In the case of dedicated CEUS examinations and research, 4000 images per examination are not rare. However, as a result, patients can be spared further examinations in individual cases and MRI or CT slots can consequently be used for other patients while maintaining the same diagnostic accuracy depending on the particular medical issue [14, 15]. The existing IT infrastructure must be taken into consideration and included with the corresponding interfaces. The plan to be implemented must satisfy the corresponding approvals and requirements for a medical product. All ultrasound devices from various manufacturers are to be connected in an ultrasound center. Depending on which workflow makes the most sense for the various



► **Fig. 1** Structure of an interdisciplinary ultrasound center using the Charité Berlin as an example.

departments, the system must provide the option of saving and retrieving data from either a PACS (Picture Archiving and Communication System) or a local archive. Connection to the radiology/hospital information system (RIS/HIS) with DICOM Worklist connection to ensure standardized assignment of the central patient ID is required.

In addition to image viewing, data processing, and saving, the system should also allow reporting. Further modalities, e. g. heart catheter examinations, can be displayed in the viewer. Cardiological, radiological, and CEUS-specific evaluations as well as the digital documentation of examination movies must be ensured by a modern IT structure in order to achieve simultaneous comparison with previous examinations. However, this feature is not yet fully supported by some PACS systems optimized for CT and MRI. The costs for the data processing connection are determined by the existing infrastructure. Depending on the size of the center and scope of the existing usable IT infrastructure, an investment between 8500 and 500 000 euros could be required for a complete hospital IT solution with inclusion of up to 100 ultrasound systems. In our experience, the basic costs for the startup of a US center was between 27 500 and 40 500 euros. ► **Fig. 1** shows an example of a possible basic structure or the creation of a US center (interdisciplinary US center of the Charité).

Ultrasound systems

When merging ultrasound areas, US systems are typically integrated resulting in costs for connecting to the RIS/PACS system (3000–7000 euros per device). A further cost factor is the fleet of equipment and the maintenance/servicing thereof. In the case of a

central solution, high-end devices are typically used with mid-range devices also being used but to a lesser extent. As a result of portfolio standardization, maintenance costs can be reduced and less used ultrasound transducers (e. g. hockey stick for tendons and ligaments) can be used for multiple US systems if they are spatially close together in an ultrasound center. Less variety means a better purchase price per device and lower maintenance costs. Expensive, high-resolution, and 3 D/4 D ultrasound transducers can be used on an interdisciplinary basis. Increasingly portable devices in tablet form and in the form of smartphone transducers (“the stethoscope of the 21st century”) that are suitable for examinations at the patient bedside are advantageous for interdisciplinary use in the clinical routine. The almost ubiquitous use of ultrasound, also referred to as point-of-care ultrasound (POCUS – the physician goes to the patient), greatly facilitates the use and distribution of ultrasound and accelerates the decision process in the clinical routine [16].

As a result of the pressure to innovate in this device class, devices can already be outdated after 3–5 years in disciplines like radiology and cardiology. This results in options for managing the entire fleet of equipment of a hospital. The DEGUM additionally provides the option of checking the device type according to manufacturer so that the device can be easily classified as class I to III (<http://www.degum.de/service/geraetelisten.html>).

In addition to calling for bids for a greater number of devices resulting in better pricing, the reduction of the number of devices and the systematic decommissioning of outdated systems are definite advantages. Therefore, awarding can be adjusted to urgency and be controlled centrally. One possible approach is the delivery of new systems only when one or ideally two old devices are decommissioned (2:1 rule). The pricing models with US manufactur-

ers range from technology partnerships to standard calls for bids with inspection of samples and short-term leasing contracts for high-end systems. The advantage of an intelligent contract is the definition of a “flat rate” for which the hospital can effectively budget with stipulations regarding a technology/innovation guarantee and service (even including transducer replacement contingents).

Basic systems are portable and can be effectively integrated in the inpatient routine. This results in a system hierarchy within the hospital and should be adapted to the DEGUM level concept for training (<http://www.degum.de/sektionen/radiologie/mehrstuflenkonzept-zertifizierung.html>).

Administration

Prior to introducing centers, a centralized examination request system should be implemented. For example, appointment slots can be set up by the responsible physicians in 15 to 30-minute intervals. The control center schedules examinations using a DICOM Worklist from the RIS and/or HIS on the relevant device based on the medical issue and type of examination. This centralized method of registering US examinations facilitates and accelerates collaboration with the referring discipline (contact partner). Patient transport to the center could be coordinated using an electronic order system. This system should be operated to ensure the coverage during on-call duty. The required consumable materials can be ordered by the control center in a centralized and digital manner. Cost-intensive consumable materials like puncture needles and radiofrequency ablation needles as well as drainage tubes and medication (US contrast agent) should be ordered as a special request and be approved by the responsible modality manager.

A joint cost center should be created for billing. Incurred costs can be billed equally to each relevant department or alternative cost structuring models can be negotiated. The material costs of a US center are relatively low, not including US contrast agent (approx. 85–90 euros per unit). The billing model should be coordinated and communicated in advance.

Revenue within a center can be distributed among the departments as agreed upon based on internal treatment charges. Indirect and direct revenue must be recorded according to service and originator. Indirect revenue result, for example, from DRG revenue in the case of an internal treatment charge, from revenue from contracts with university outpatient clinics, and from emergency care provided by the Association of Statutory Health Insurance Physicians. Direct revenue can result, for example, from inpatient elective services, outpatient private insurance services, outpatient specialist care services, and from scientific studies. Shared funding can be used to fund positions for doctors in rotation after the deduction of usage fees or flat-rate training fees. Ultrasound services to be rendered independently within the statutory health insurance system (primarily authorization of an individual, authorization of an institution, and outpatient specialist care services) and services performed for patients receiving elective services or for self-paying patients must be contractually regulated in advance to ensure legal compliance (n.b.: personal service provision).

Radiology as an interdisciplinary discipline and a department usually without beds in Germany must ensure that revenue are

not allocated to departments with beds while costs are billed to radiology. Documentation taking into consideration revenue and billing potential must be included in the RIS and HIS. A sample model calculation is shown in ► **Fig. 2**. The cost calculation is specified as the effective device usage time (x euros/minute). The specified times then correspond to the selected organizational structure (*blinded*) [17].

Organizational structure

The organizational structure at the center regarding physicians for every subspecialization can consist of one attending physician and residents in rotation from the participating disciplines (3–6 months). For example, the goal can be to provide the foundation for receiving the DEGUM training certificate during rotation [11]. The attending physician in charge of the ultrasound center is responsible for the organizational workflow and is available for interventions, CEUS, and special questions (e. g., intraoperative ultrasound). This ensures that routine examinations can be performed within 24 hours of admission and emergency examinations can be performed immediately. The duty roster and rotation schedule of the center must be coordinated with each participating department. On the one hand, this can be achieved by having residents in rotation work at the US center for a defined period of time without on-call duty in their own department. On the other hand, on-call duty can be completed at the relevant department in coordination with the scheduler for the corresponding absence periods at the US center. Ultrasound during the night shift can be performed in a bundled and centralized manner by on-call radiologists, e. g., in emergency departments. This requires on-call radiologists to be trained at the US center with respect to all necessary sonographic questions. Every resident from the participating departments does a rotation during training at the interdisciplinary ultrasound center. This will help to ease the burden on radiology during the night shift. Already trained physicians in the emergency department are able to perform basic examinations. For verification, a rapid release performed on the next day by the responsible attending physician of the ultrasound center could be implemented as a quality assurance measure.

Training and specialist training

An objective of the ultrasound working group of the German Radiological Society is to promote the importance of ultrasound in specialization in radiology. The rotation of residents from the various disciplines would ensure standardized training according to DEGUM guidelines [11]. This includes at least 800 documented examinations under supervision and serves as a training concept in the module system (► **Table 2**). This ensures that the ultrasound training needed for specialist training (e. g. internal medicine, radiology, surgery) with a focus on abdominal ultrasound is implemented in a competent and comprehensive manner, which can be achieved, for example, by using a level system within a US center (► **Fig. 3**). In addition to internal training and specialist training, the center should offer ultrasound courses (ideally with a DEGUM level III course instructor) with corresponding rooms for presentations and presentation of findings in collaboration

Beispielszenario: Kosten- Erlösrechnung (*Näherungswerte*)

Modellrechnung

Annahmen: Die Kostenberechnung erfolgt über die **effektive Gerätenutzungszeit** (x Euro/Minute)

- die Gesamtpersonalkosten werden der **effektiven Gerätenutzungszeit** zugeordnet
- die Gesamtsachkosten (incl. Wartung, Service u. Instandhaltung) werden der **effektiven Gerätenutzungszeit** zugeordnet
- die speziellen Sachkosten (Implantate / MR - Kontrastmittel) werden der **einzelnen Untersuchung** zugeteilt
- die Kosten außerhalb der Kernarbeitszeit werden der **effektiven Gerätekerndnutzungszeit** zugeordnet
- die Wartungskosten Investition werden den Geräten **pro Minute** zugeordnet
- die (Wieder-) Anschaffungskosten Investition werden den Geräten **pro Minute** zugeordnet

Untersuchung	Vergleich		
	Erlös (€) (GOÄ 1,8 - fach) inkl. Zusatzserie	ca. - Kosten ("Vollkosten") (€)	Ergebnis (€)
CT Abdomen KM	435,41	340,00	95,41
MRT Abdomen KM	653,01	380,00	273,01
SONO Abdomen KM	118,00	97,00	21,00

► **Fig. 2** Example of cost-revenue accounting scenario. Overview of individual cost parameters and comparison between multiple modalities using contrast-enhanced abdominal examination as an example. Abbreviations: CT: computed tomography; MRI: magnetic resonance imaging; US: ultrasound.

with the state chambers of physicians, the ultrasound working group, and the DEGUM academy according to the DEGUM guidelines. An interdisciplinary ultrasound center should also be able to function as a training center for the CEUS certificate of the German Radiological Society (<https://www.ag-ultraschall.drg.de/de-DE/3885/fortbildungszertifikat-ceus-fuer-radiologen/>). By providing courses, the center can partly offset its operating costs.

In addition to establishing new methods like CEUS and elastography, training in further applications of these techniques is also provided [18]. Course programs are aimed not only at experts but also at novices, e. g., in emergency ultrasound (learning FAST and eFAST [19]). Training on simulators was also successfully tested as part of this concept and can greatly simplify the introduction to sonographic findings. For example, the differences between normal sonoanatomy and selected simple pathological findings can be of particular interest. The improved diagnostic performance (calculated by score) in the diagnostic ultrasound examination of patients after simulation-based training has already been shown scientifically in a randomized study [20].

In addition, medical students can be trained in ultrasound according to established guidelines (medical curriculum) [21]. The introductory ultrasound course can be offered as a basic course with the corresponding DEGUM certificate (for accredited curricular teaching). Students can thus learn the basics and then be repeatedly introduced to organ systems. The courses should be in-

structed by the responsible attending physician or the resident on rotation in the ultrasound center. Examination of the abdomen, neck, peripheral vascular system, and the thyroid should be considered a practice-oriented concept of student training.

Student training in US can be ensured by curricular teaching and accompanying peer teaching groups (sono working groups, Sono4You, Sono4Students). The training of student US tutors should thus be performed in a centralized manner via the US centers by experts from various disciplines (in clinical electives) to ensure the necessary quality.

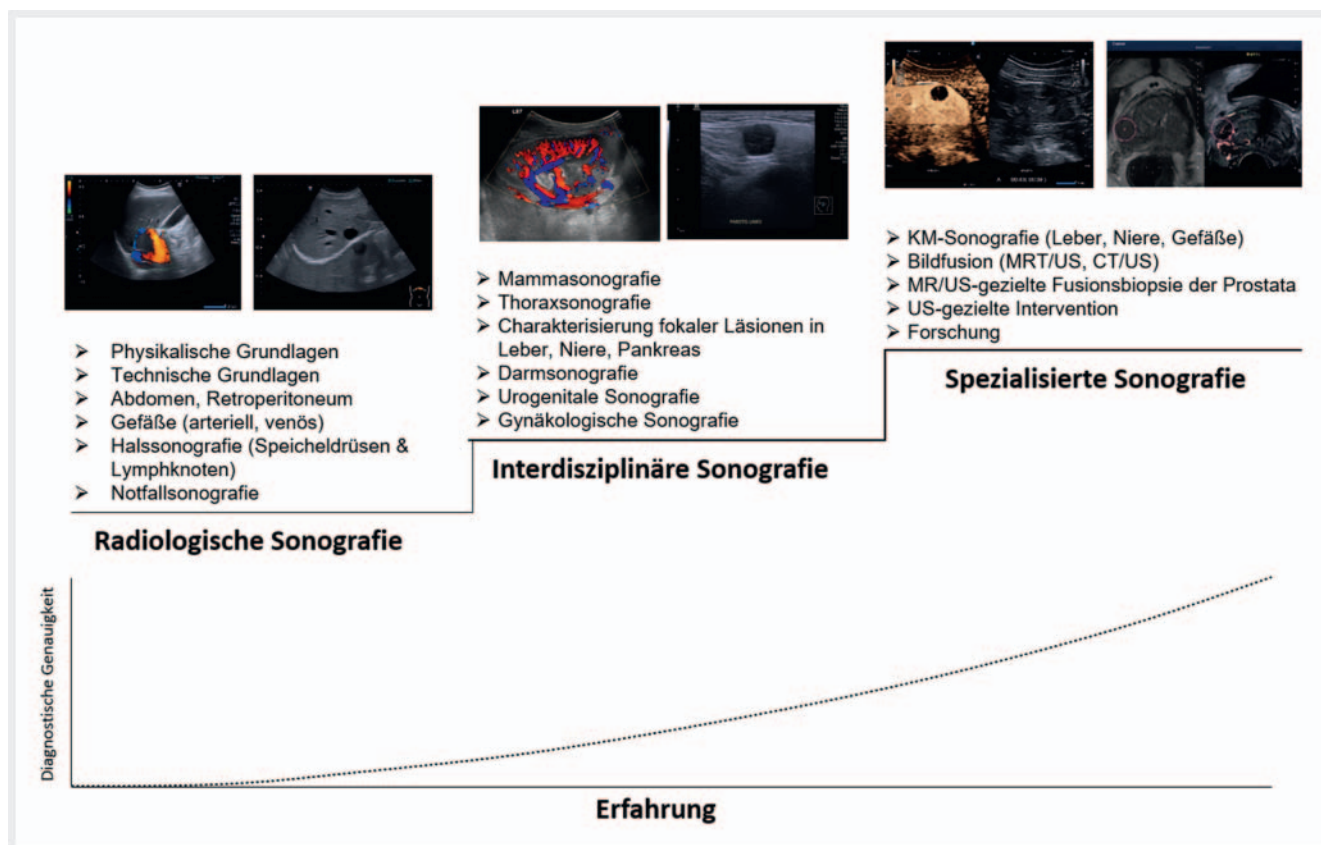
Quality assurance

Reporting must be standardized, for example, using predefined structured reporting templates under the supervision of specialists or attending physicians. Residents from the departments should be able to participate in specialist training events at the center. Key metrics here are the ultrasound technique, typical standard settings, report quality, and discussion of interactive case examples. The significant improvement in communication between physicians from different departments due to direct daily collaboration in the ultrasound center should not be underestimated.

► **Table 2** Overview of examples of DEGUM modules.

Contrast-enhanced ultrasound part I (basics, guidelines, procedure, common focal liver lesions, future prospects for kidneys and bowel)
Contrast-enhanced ultrasound part II (optimized device settings, safety aspects, rarer malignant and benign liver findings, other organs)
GI tract
Vascular imaging, abdomen
Thyroid
Chest ultrasound
Interventional ultrasound
Perioperative and intensive care ultrasound
Special emergency ultrasound
Differential diagnosis acute abdomen
Thrombosis diagnosis
Elastografie
Bowel ultrasound

Overview of the course structure according to the module system of the DEGUM (German Society for Ultrasound in Medicine) in collaboration with internal medicine, radiology, surgery, and working groups (https://www.degum.de/fileadmin/dokumente/aktuelles/Abdomensonografie_Kursstruktur/DEGUM_Module_Tabelle_3.pdf)



► **Fig. 3** Example of a US training level system within an interdisciplinary US center. The basics of B-mode ultrasound and color-coded Doppler ultrasound in relevant organ systems (focus on abdomen, vascular system, emergency) are initially learned. The basics are followed by imaging of specific organs (e. g. renal transplant, characterization of focal lesions, ultrasound of the reproductive organs, etc.). Finally, special US techniques like CEUS, US image fusion, and US intervention are taught. Increasing knowledge of new US skills and greater experience improve the diagnostic accuracy of ultrasound imaging of organs. Abbreviations: US refers to ultrasound.

► **Table 3** Key figures and structure of US centers.

US centers in alphabetical order						Key figures and structure
Berlin	Munich	Regensburg	Rostock	Trier		
11 departments (ENT, internal polyclinic, urology, orthopedics, hemat oncology, nephrology, surgery, rheumatology, sports medicine, emergency medicine, radiology)	14 departments (surgery, gynecology, cardiac surgery, ENT, internal medicine, nephrology, cardiology, pulmonology, neurosurgery, neurology, orthopedics, trauma surgery, urology, radiology)	10 departments (internal medicine 1 gastroenterology, med 2 oncology, rheumatology, infectious diseases, nephrology, surgery, radiology, pediatrics, ENT, plastic surgery)	9 departments (radiology incl. pediatric and neuroradiology, general medicine, pediatrics, cardiology, gastroenterology, pulmonology, endocrinology, nephrology, surgery)	11 departments (general medicine, surgery, gynecology, cardiac surgery, internal medicine, cardiology, pulmonology, neurosurgery, neurology, orthopedics, trauma surgery, urology)		How many departments, which departments, and how are they involved?
Management: Board-certified radiologist (22 years of US experience, DEGUM level 3) Management of subspecialty: Board-certified internist (30 years of US experience, DEGUM level 2), management of subspecialty: Emergency medicine (20 years of US experience, DEGUM level 3)	Management: Board-certified radiologist (19 years of US experience, DEGUM level 3) Management of subspecialty: Board-certified internist (5 years of US experience)	Management: Board-certified radiologist (30 years of experience, 2 × DEGUM level III, head of the committee on vascular ultrasound of the Association of Statutory Health Insurance Physicians in Bavaria, reference center for familial prevalence of breast cancer)	<ul style="list-style-type: none"> Management in dual role as board-certified radiologist+ specialist in internal medicine and angiology, phlebology (US course instructor of the Medical Association Mecklenburg Western Pomerania) Management of subspecialty: board-certified radiologist with specialization in neuroradiology (DEGUM 3, CEUS) Management of subspecialty: specialist in pediatrics + radiology with specialization in pediatric radiology (head of clinical internships for the Medical Association Mecklenburg Western Pomerania, CEUS) Management of subspecialty: board-certified radiologist (head of clinical internships for Medical Association Mecklenburg Western Pomerania) 	Management: Board-certified radiologist (attending physician; 23 years of US experience) Board-certified surgeon (33 years of US experience, DEGUM level 3) Board-certified internist (28 years of US experience, DEGUM level 2)		Managers and representatives in the form of colleagues with board certification, number of years of US experience, qualifications of trainers (DEGUM)
4 × level 3 2 × level 2 8 × level 1	1 × level 3 3 × level 1	1 × level 3 2 × level 2 7 × level 1	1 × level 3 1 × level 2 Medical Association Mecklenburg Western Pomerania: 1 × III, 2 × II Specifically in Mecklenburg Western Pomerania: only ultrasound qualifications granted by the State Chamber of Physicians Mecklenburg Western Pomerania are recognized for service provision and billing	1 × level 3 4 × level 2 2 × level 1		Total DEGUM certifications

► **Table 3** (Continuation)

US centers in alphabetical order					Key figures and structure	
Berlin	Munich	Regensburg	Rostock	Trier		
6 high-end devices 4 mid-class systems 2 portable systems Technology partnership, service control via the US committee for the entire company	6 high-end devices 2 mid-class systems Technology partnership, service control via the US committee for the entire department	6 high-end devices 4 mid-class systems 2 portable systems Technology partnership, service control via the US committee for the entire department	5 high-end devices 4 mid-class devices Technology partnership/scientific cooperation, general contract for full service, ultrasound committee for the entire company	10 high-end devices including endosonography 12 portable systems Technology partnership Technology guarantee/re-regular reinvestment Service contract structure	Number of devices in equipment classes shown here	Philosophy of device/manufacturer selection: a manufacturer with general contract? Technology partnership? Technology guarantee/regular reinvestment? Service contract structure
10 examination rooms with a size of 15m ² –34 m ² 2 management rooms 1 conference room 1 break room 1 registration site	6 examination stations in 3 rooms with a size of 25m ² –40 m ² 1 management room 1 conference room 1 break room 1 registration site 1 presentation room	6 examination rooms with a size of 15m ² –34 m ² 1 management room 1 conference room 1 break room 1 registration site	7 US stations 5 waiting rooms (separate for sitting and lying) 1 control room 1 monitoring area together with angiography	7 examination rooms with a size of 12 m ² to 45 m ² 3 management room 1 conference room 1 break room 1 registration site	Room size, room design	
8, 2, 1 In 5 years 21 physicians received DEGUM qualification	5, -, 1 In 5 years 3 physicians received DEGUM qualification	5, -, 2 In 5 years 10 physicians received DEGUM qualification	2.0 full-time attending physicians, 4.0 full-time residents (including 1 full-time specialist) Responsible for ultrasound training (with focus on abdominal US) for specialist training in radiology, surgery, pediatric surgery, general medicine, internal medicine, pediatrics (approx. 7 p. a.). 2–3 physicians/year receiving technical qualification from Medical Association Mecklenburg Western Pomerania (DEGUM less relevant in Mecklenburg Western Pomerania) Additionally active as examiner for ultrasound qualification in Medical Association Mecklenburg Western Pomerania (approx. 12 examinations/year)	9, -, 11 5 physicians received DEGUM qualification (3 * DEGUM 2, 2 * DEGUM 1)	Personnel structure (medical service, radiographer, medical assistant) How many physicians (and also radiographers/medical assistants) trained during which time frame? How many physicians obtained DEGUM certification?	
DICOM worklist, all images in the PACS, RIS as primary system	DICOM worklist, all images in the PACS, RIS as primary system	DICOM worklist, all images in the PACS, RIS as primary system	DICOM worklist, all images in the PACS, RIS as primary system	Reporting system with image transfer, worklist, order entry, RIS as primary system, all images in PACS	IT specifics	

<p>► Table 3 (Continuation)</p> <p>US centers in alphabetical order</p>						
		Munich	Regensburg	Rostock	Trier	Key figures and structure
Berlin	2007, 2017 start-up	2005	2007	2016. DEGUM-qualified training center since 2017	2006	How long has the center existed?
	Approx. 24 000 examinations per year	Approx. 18 000 examinations per year	Approx. 24 000	Complete spectrum excl. heart and female genitals	Approx. 35 000 examinations per year	Spectrum of examinations with annual number of cases
	> 50 publications in 5 years, > 100 presentations	2017–2021, 119 publications in 5 years, > 160 presentations	> 50 publications in 5 years, > 100 presentations	Ø 4 publications/year, Approx. 8 presentations/year	Approx. 15 publications, approx. 220 presentations	How many publications and presentations did the center produce?
	Approx. 5 million euros	Approx. 2.1 million euros	Approx. 500 000 euros	250 000 euros	Approx. 250 000 euros	Third-party funding
<p>Overview of infrastructure, training, and research of the individual ultrasound centers</p>						

Research

Joint research projects can create new momentum. For example, W2 radiology professors can manage the ultrasound center as has already been successfully implemented in Munich and Berlin. Increased scientific US activities in radiology can occur as part of doctoral work during medical education. A current focus of ultrasound research is CEUS and quantitative elastography (strain or shear wave elastography) and in the future also molecular imaging [22, 23]. As a result of collaboration within interdisciplinary ultrasound centers, interdisciplinary research and animal experiments can be conducted [23, 24]. The creation of an interdisciplinary image database based on standardized US protocols can significantly improve research both internally as well as nationally.

In addition to research regarding CEUS, multimodal imaging approaches currently also play an important role and require networking of research partners. This resulted in projects supported by the German Research Society, such as the junior research academy with the title “Biophysical Foundations of Medical Imaging”, that were successfully jointly implemented (URL: <https://www.dgmp.de/DE/DE/426/dfg-nachwuchsakademie-biophysikalische-grundlagen-der-medizinischen-bildgebung>). Elastography features of liver fibrosis were examined on a preclinical and clinical basis [25]. Further research topics include breast cancer [26, 27] and prostate cancer, where CEUS can support the evaluation of focal lesions for targeted biopsy [4, 23, 28]. As a result of the interdisciplinary collaboration between urology, radiology, and pathology, an approach for the real-time fusion of MRI and US image data for targeted prostate biopsy was developed [4, 28]. There have been joint clinical decisions and research projects, e. g., with vascular surgery on the topic of endoleak diagnosis. ► **Table 3** provides an overview of the structure of five existing US centers in Germany.

Outlook

Establishing interdisciplinary ultrasound centers results in further potential for economic optimization. Therefore, the DEGUM multicenter study PRIMUS published in 2012 [14] was able to show that the length of hospital stay can be reduced from 8 to 5 days by using US within the first 24 hours in the emergency department. In some cases, inpatient admission can be avoided, and the number of outpatient treatments can be reduced. The effect on possible therapeutic consequences and targeted diagnostics is thus high.

In light of this, with good structural and result quality, centralized interdisciplinary US can play a role equal to that of other cross-sectional imaging methods and can be integrated in the DRG-based system of the hospital. According to Busch [29], “ultrasound specialists with certified expertise and high-quality equipment” work in an imaging center (i. e., the radiology department) “giving ultrasound the status of a reference method”. However, the value of ultrasound as a reference method should be viewed in the context of all cross-sectional imaging methods. The multimodal cross-sectional imaging competence inherently present in radiology predestines radiology to have a leadership role in the establishment, organization, and management of an ultrasound center. Our radiology society would be well advised to promote openness to an interdisciplinary ultra-

sound center managed by radiology. Thus, feelings of possessiveness among individual departments can be overcome and centralized US can be effectively merged with the other modalities.

When establishing a centralized interdisciplinary ultrasound center, the challenge is to coordinate the centralization of the ultrasound modality with specific organ- and disease-related processes in a deliberate manner depending on the local conditions and requirements of the hospital. Functional areas (often organized on an interdisciplinary and centralized basis) have been created in many departments in recent years and are spatially and organizationally oriented on the clinical pathway of the patient. Examples include interdisciplinary outpatient breast cancer centers and outpatient vascular centers. A high volume of patients and examinations could limit the ability of an ultrasound center to provide comprehensive sonographic resources.

Conflict of Interest

The authors declare that they have no conflict of interest.

References

- [1] Schnur S. Rationelle Ultraschalldiagnostik Grundlagen und problemorientierte Anwendung. 1st ed Berlin Heidelberg: Springer-Verlag; 2001
- [2] Clevert DA, Paprottka PM, Helck A et al. Image fusion in the management of thermal tumor ablation of the liver. *Clin. Hemorheol. Microcirc* 2012; 52: 205–216
- [3] Trottmann M, Marcon J, D'anastasi M et al. The role of VTIQ as a new tissue strain analytics measurement technique in testicular lesions. *Clin. Hemorheol. Microcirc* 2014; 58: 195–209
- [4] Maxeiner A, Stephan C, Durmus T et al. Added Value of Multiparametric Ultrasonography in Magnetic Resonance Imaging and Ultrasonography Fusion-guided Biopsy of the Prostate in Patients with Suspicion for Prostate Cancer. *Urology* 2015; 86: 108–114
- [5] Lerchbaumer MH, Auer TA, Marticorena GS et al. Diagnostic performance of contrast-enhanced ultrasound (CEUS) in testicular pathologies: Single-center results. *Clin. Hemorheol. Microcirc* 2019; 1–11
- [6] Clevert DA, Paprottka P, Sommer WH et al. The Role of Contrast-Enhanced Ultrasound in Imaging Carotid Arterial Diseases. *Semin. Ultrasound, CT MRI* 2013; 34: 204–212
- [7] Gürtler VM, Sommer WH, Meimarakis G et al. A comparison between contrast-enhanced ultrasound imaging and multislice computed tomography in detecting and classifying endoleaks in the follow-up after endovascular aneurysm repair. *J. Vasc. Surg* 2013; 58: 340–345
- [8] Sommer WH, Becker CR, Haack M et al. Time-resolved CT angiography for the detection and classification of endoleaks. *Radiology* 2012; 263: 917–926
- [9] Fischer C, Krix M, Weber MA et al. Contrast-Enhanced Ultrasound for Musculoskeletal Applications: A World Federation for Ultrasound in Medicine and Biology Position Paper. *Ultrasound Med. Biol* 2020; 46: 1279–1295
- [10] Sidhu PS. Multiparametric Ultrasound (MPUS) Imaging: Terminology Describing the Many Aspects of Ultrasonography. *Ultraschall Med* 2015; 36: 315–317
- [11] Weber MA, Delorme S. Sonografische Weiterbildung auf dem Weg zum radiologischen Facharzt: Konzepte und Herausforderungen. *Radiologe* 2017; 57: 967–972
- [12] Sidhu P, Cantisani V, Dietrich C et al. The EFSUMB Guidelines and Recommendations for the Clinical Practice of Contrast-Enhanced Ultrasound (CEUS) in Non-Hepatic Applications: Update 2017 (Long Version). *Ultraschall Der Medizin – Eur. J. Ultrasound* 2018; 39: e2–e44
- [13] Müller T, Martiny H, Merz E et al. DEGUM recommendations on infection prevention in ultrasound and endoscopic ultrasound. *Ultraschall Der Medizin* 2018; 39: 284–303
- [14] Schuler A, Karbe T, Vasilakis D et al. Primär Ultraschall als Bildgebung in der Notaufnahme. Endergebnisse der PRIMUS-Studie (DEGUM Multicenter-Studie). *Ultraschall Der Medizin – Eur. J. Ultrasound* 2012; 33: A901
- [15] Westwood M, Joore M, Grutters J et al. Contrast-enhanced ultrasound using SonoVue(R) (sulphur hexafluoride microbubbles) compared with contrast-enhanced computed tomography and contrast-enhanced magnetic resonance imaging for the characterisation of focal liver lesions and detection of liver m. *Health Technol. Assess* 2013; 17: 1–243
- [16] Rice JA, Brewer J, Speaks T et al. The POCUS Consult: How Point of Care Ultrasound Helps Guide Medical Decision Making. *Int. J. Gen. Med* 2021; 14: 9789–9806
- [17] Wüstner M, Mertiny E, Busch HP. Arbeitsweise eines interdisziplinären Ultraschallzentrums - Ein neuer Weg zu professioneller Ultraschalldiagnostik. *Kliniker* 2012; 41: 47–51
- [18] Säfteiu A, Gilja OH, Sidhu PS et al. The EFSUMB Guidelines and Recommendations for the Clinical Practice of Elastography in Non-Hepatic Applications: Update 2018. *Ultraschall Der Medizin* 2019; 40: 425–453
- [19] Osterwalder J, Mathis G, Hoffmann B. New Perspectives for Modern Trauma Management – Lessons Learned from 25 Years FAST and 15 Years E-FAST. *Ultraschall Der Medizin* 2019; 40: 560–583
- [20] Østergaard ML, Rue Nielsen K, Albrecht-Beste E et al. Simulator training improves ultrasound scanning performance on patients: a randomized controlled trial. *Eur. Radiol* 2019; 29: 3210–3218
- [21] Ertl-Wagner B, Barkhausen J, Mahnken A et al. White Paper: Radiological Curriculum for Undergraduate Medical Education in Germany. *RoFo Fortschritte Auf Dem Gebiet Der Röntgenstrahlen Und Der Bildgeb. Verfahren* 2016; 188: 1017–1023
- [22] Klotz LV, Gürkov R, Eichhorn ME et al. Perfusion characteristics of parotid gland tumors evaluated bycontrast-enhanced ultrasound. *Eur. J. Radiol* 2013; 82: 2227–2232
- [23] Fischer T, Thomas A, Tardy I et al. Vascular endothelial growth factor receptor 2-specific microbubbles for molecular ultrasound detection of prostate cancer in a rat model. *Invest. Radiol* 2010; 45: 675–684
- [24] Nikolaou K, Cyran CC, Lauber K et al. Präklinische Bildgebung im Tiermodell bei strahlentherapie. *Radiologe* 2012; 52: 252–262
- [25] Tzschätzsch H, Ipek-Ugay S, Nguyen Trong M et al. Multifrequency time-harmonic elastography for the measurement of liver viscoelasticity in large tissue windows. *Ultrasound Med. Biol* 2015; 41: 724–733
- [26] Durmus T, Stöckel J, Slowinski T et al. The hyperechoic zone around breast lesions – An indirect parameter of malignancy. *Ultraschall Der Medizin* 2014; 35: 547–553
- [27] Fischer T, Grigoryev M, Bossenz S et al. Sonografische Mikrokalkdetektion – Potenzial einer neuen Methode. *Ultraschall Der Medizin* 2012; 33: 357–365
- [28] Maxeiner A, Fischer T, Schwabe J et al. Contrast-Enhanced Ultrasound (CEUS) and Quantitative Perfusion Analysis in Patients with Suspicion for Prostate Cancer. *Ultraschall Der Medizin – Eur. J. Ultrasound* 2019; 40: 340–348
- [29] Busch H. Kosteneffizienz eines modernen Imaging Centers. *RöFo – Fortschritte Auf Dem Gebiet Der Röntgenstrahlen Und Der Bildgeb. Verfahren* 2013; 185: RKSP307_2