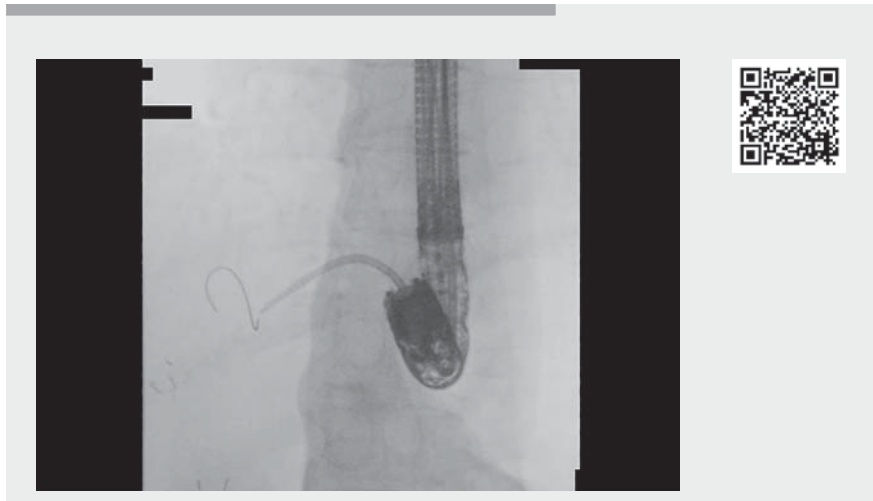


Endoscopic ultrasound-guided hepaticogastrostomy using a novel drill dilator

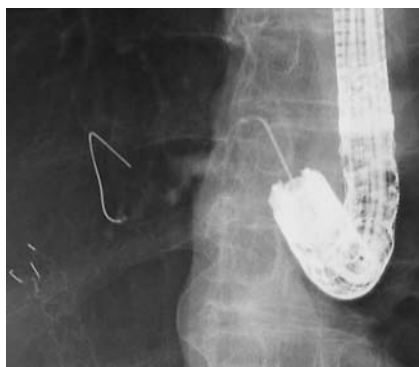OPEN
ACCESS



► **Fig. 1** Tip and handle of the novel Tornus ES drill dilator.



► **Video 1** Endoscopic ultrasound-guided hepaticogastrostomy using the novel Tornus ES drill dilator.



► **Fig. 2** A 0.018-inch guidewire was inserted, but the guidewire was very curved.

Endoscopic ultrasound-guided hepaticogastrostomy (EUS-HGS) is an alternative to endoscopic retrograde cholangiopancreatography when the latter has failed [1–3]. Using a 22-gauge needle, 0.018-inch guidewire, and forward-viewing EUS, EUS-HGS is easier and safer to perform [4]. However, in some cases fistula dilation is difficult, because a 0.018-inch guidewire is relatively soft. Recently, we used a novel drill dilator

(Tornus ES, Asahi Intecc) for EUS-HGS in a difficult case of this kind (► **Fig. 1**). Here, we describe technical tips for fistula dilation using this tool.

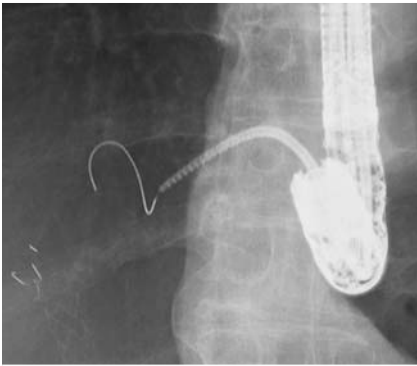
A 64-year-old man underwent endoscopic metallic stenting and percutaneous transhepatic biliary drainage for malignant hepatic hilar obstruction due to hepatocellular carcinoma. However, left intrahepatic bile duct drainage failed, and he was referred to our hospital for EUS-HGS. The intrahepatic bile duct was visualized from the stomach under forward-viewing EUS guidance (GF-UC260, Olympus). The intrahepatic bile duct was punctured using a 22-gauge needle [Expect Slimline (SL), Boston Scientific], and a 0.018-inch guidewire (Fielder, Asahi Intecc) was inserted. A contrast medium was injected, allowing the intrahepatic bile duct to be observed. The guidewire was curved, because the angle between the puncture route and the intrahepatic bile duct was relatively sharp due to the atrophy of the left hepatic parenchyma (► **Fig. 2**). Therefore, the Tornus was selected for fistula dilation (► **Video 1**). To

dilate the fistula, the Tornus was turned clockwise and easily advanced (► **Fig. 3**). After dilation, it was easily removed by counterclockwise turning. A double-lumen cannula (Uneven Double Lumen Cannula, Piolax Medical Devices) was inserted, and a contrast medium was injected. Hemobilia due to the hepatocellular carcinoma was observed (► **Fig. 4**). Finally, deployment of an 8-mm, fully covered metallic stent (Covered BileRush Advance, Piolax Medical Devices) was successfully carried out (► **Fig. 5**). The present case demonstrates that Tornus is useful for fistula dilation in difficult cases of EUS-HGS.

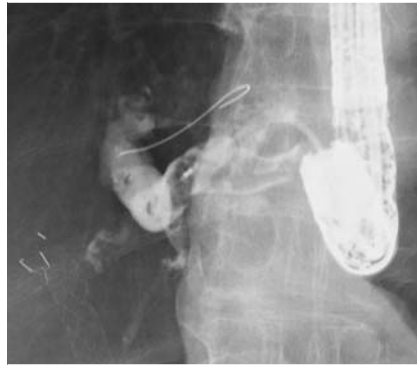
Endoscopy_UCTN_Code_TTT_1AS_2AD

Competing interests

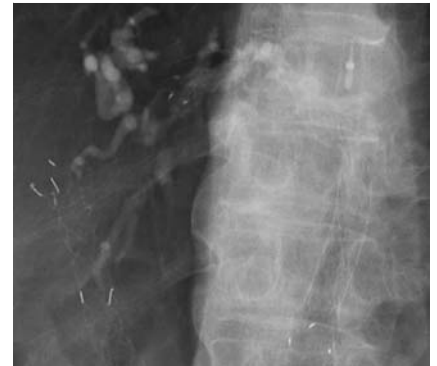The authors declare that they have no conflict of interest.



► **Fig. 3** The fistula was dilated using the Tornus ES.







► **Fig. 4** Hemobilia due to hepatocellular carcinoma was observed.



► **Fig. 5** Deployment of a fully covered metallic stent was successfully carried out.

The authors

Masanori Yamada  **Kazuo Hara**  **Shin Haba** 
Nobumasa Mizuno, Takamichi Kuwahara,
Nozomi Okuno  **Yasuhiro Kuraishi**
 Department of Gastroenterology, Aichi Cancer Center, Nagoya, Japan

Corresponding author

Kazuo Hara, MD
 Department of Gastroenterology, Aichi Cancer Center, 1-1 Kanokoden, Chikusa-ku, Nagoya 464-8681, Japan
 khara@aichi-cc.jp

References

- [1] Boulay BR, Lo SK. Endoscopic ultrasound guided biliary drainage. *Gastrointest Endosc Clin N Am* 2018; 28: 171–185
- [2] Isayama H, Nakai Y, Itoi T et al. Clinical practice guidelines for safe performance of endoscopic ultrasound/ultrasonography-guided biliary drainage. *J Pancreat Sci* 2019; 26: 249–269

- [3] Ogura T, Higuchi K. Technical review of developments in endoscopic ultrasound-guided hepaticogastrostomy. *Clin Endosc* 2021; 54: 651–659
- [4] Hara K, Okuno N, Haba S et al. How to perform EUS-guided hepaticogastrostomy easier and safer. *J Hepatobiliary Pancreat Sci* 2020; 27: 563–564

Bibliography

Endoscopy 2022; 54: E856–E857
 DOI 10.1055/a-1838-3682
 ISSN 0013-726X
 published online 30.5.2022
 © 2022. The Author(s).

This is an open access article published by Thieme under the terms of the Creative Commons Attribution-NonDerivative-NonCommercial License, permitting copying and reproduction so long as the original work is given appropriate credit. Contents may not be used for commercial purposes, or adapted, remixed, transformed or built upon. (<https://creativecommons.org/licenses/by-nc-nd/4.0/>)
 Georg Thieme Verlag KG, Rüdigerstraße 14, 70469 Stuttgart, Germany



ENDOSCOPY E-VIDEOS
<https://eref.thieme.de/e-videos>



Endoscopy E-Videos is an open access online section, reporting on interesting cases and new techniques in gastroenterological endoscopy. All papers include a high quality video and all contributions are freely accessible online. Processing charges apply (currently EUR 375), discounts and waivers acc. to HINARI are available.

This section has its own submission website at <https://mc.manuscriptcentral.com/e-videos>